

Indications and Specific Surgical Techniques in Crohn's Disease

Claudia Seifarth Martin E. Kreis Jörn Gröne

Department of General, Visceral- and Vascular Surgery, Charité – University Medicine, Campus Benjamin Franklin, Berlin, Germany

Keywords

Crohn's Disease · Surgery · Immunosuppression · Risk assessment

Summary

Background: Crohn's disease (CD) as one of the major entities of chronic inflammatory bowel diseases can affect all segments of the gastrointestinal tract but occurs most often in the small bowel, the terminal ileum, the colon, and the rectum. Typical symptoms include tiredness, lower abdominal pain, fever, and diarrhea, which are initially treated by conservative measures. Most patients will eventually develop complications such as fistulas, abscesses, or strictures. Surgery is often unavoidable in these cases. **Methods:** This review considers studies on the treatment of CD, published from 1979 up to now. The literature regarding the course, complications, and surgical therapy of CD was reviewed. Searches were performed in PubMed, using the following key words: CD, surgery, immunosuppression, guidelines, malnutrition as well as appropriate sub-items. In most cases the literature is limited to detailed information on specific therapeutic or diagnostic topics. Moreover, many studies are designed retrospectively and with a small number of patients. Additionally, our long-standing experience with patients suffering from CD is taken into consideration in this review. **Results:** There is a wide variety of indications for surgery in CD which includes complications like strictures, fistulas and abscess formation, neoplasia, or refractoriness to medical therapy. The risk of developing complications is about 33% after 5 years, and 50% after 20 years. Furthermore, one-third of CD patients need surgical therapy within the first 5 years of diagnosis. The treatment requires close cooperation between gastroenterologists and surgeons. When indi-

cated, surgery should be performed in a 'conservative' fashion, i.e. as limited as possible, in order to achieve the required result and to avoid small bowel syndrome.

Conclusion: This article provides a complete overview of indications and specific surgical treatment in patients with CD. Surgery is typically indicated when complications of CD occur. An interdisciplinary collaboration is necessary in order to ensure optimal indications and timing of surgery. This is of paramount importance to achieve the ultimate goal, i.e. a good quality of life of the patients.

© 2015 S. Karger GmbH, Freiburg

Indications for Surgical Treatment of Crohn's Disease

Chronic inflammatory bowel diseases (IBD) comprise Crohn's disease (CD) and ulcerative colitis, as well as conditions with overlapping pathologic features, i.e. so-called indeterminate colitis. Patients with CD suffer from abdominal pain and diarrhea. CD can involve the whole gastrointestinal tract but predominantly affects the terminal ileum, the colorectum, and the perianal region. For initial treatment immune-suppressive or immune-modulating drugs are available. Neither medical nor surgical intervention can cure the disease. Therefore, the aim of treatment is to induce and maintain remission of the disease in order to reduce symptoms and increase the patients' quality of life.

If medical treatment fails, surgery is needed. Patients with CD often require multiple intestinal surgery [1, 2]. However, it is sometimes difficult to choose the right time for terminating medical treatment and initiating surgical treatment. Especially during the last decade, a wide range of medication was looked into with

effective symptom reduction and increased quality of life. Medical treatment is sometimes unnecessarily prolonged by gastroenterologists. Additionally, patients often dislike the thought of an operation. This can result in delayed surgery, which in turn can lead to increased morbidity due to the patient's weakened condition [3, 4].

Despite improved conservative treatment methods, complications such as abscesses, fistulas, and stenosis can occur during the course of the disease. In these cases surgery is strictly indicated. The occurrence of dysplasia or cancer and of emergencies such as uncontrollable bleeding or perforation presents further indications for surgical treatment.

In contrast to ulcerative colitis, which may be ultimately cured by proctocolectomy, CD frequently recurs and cannot be completely cured. After surgery a subgroup of patients will experience further attacks during the course of the disease [5]. Clinical recurrence rates in the range of 10–30% are described in the literature for the first year after surgery. The risk increases to 60% in the course of 10 years after the operation [5]. A well-defined risk management is necessary to choose the best available therapy at present. At times, surgical risks must be weighed against those of long-term medication. To avoid short bowel syndrome, the central aspect of surgical strategies in CD consists of the limited resection of symptomatic bowel districts only.

Risk Assessment

Despite a wide range of medical treatment options, including corticoids, immunosuppressives like cyclosporine, immunomodulators like thioprine and TNF-alpha antibodies, a majority of patients with CD will need surgery during their life. Many of them undergo surgery while receiving immunosuppressive medication [4]. Its effect on the postoperative outcome is diversely discussed in the literature. There are some data showing that the combination of corticoids and other immunosuppressives like 6-mercaptopurine or azathioprine seems to have no influence on postoperative complications [6]. However, prednisolone with a dose higher than 20 mg or equivalent significantly increases the risk of septic complications such as surgical site infections, sepsis, and anastomotic leakage [6, 7]. In case of preoperative treatment with infliximab, studies have demonstrated conflicting data concerning complication rates. In a systematic review, preoperative infliximab treatment was associated with increased postoperative complications [8]. Others describe no significant increase after use of anti-TNF-alpha agents either 12 weeks or ≤ 14 days prior to surgery [9]. Further investigation is necessary concerning these inconsistent data.

In addition, malnutrition, anemia, past surgery, and emergency surgery are associated with an inferior postoperative outcome. If possible, these conditions should be improved preoperatively including parenteral nutrition. Immunosuppressive medication, particularly with regard to corticoids, should be stopped before surgery as early as justifiable. In case of emergency a higher risk of complications, such as anastomotic leakage, has to be expected. In order to control potential complications in these poor conditions,

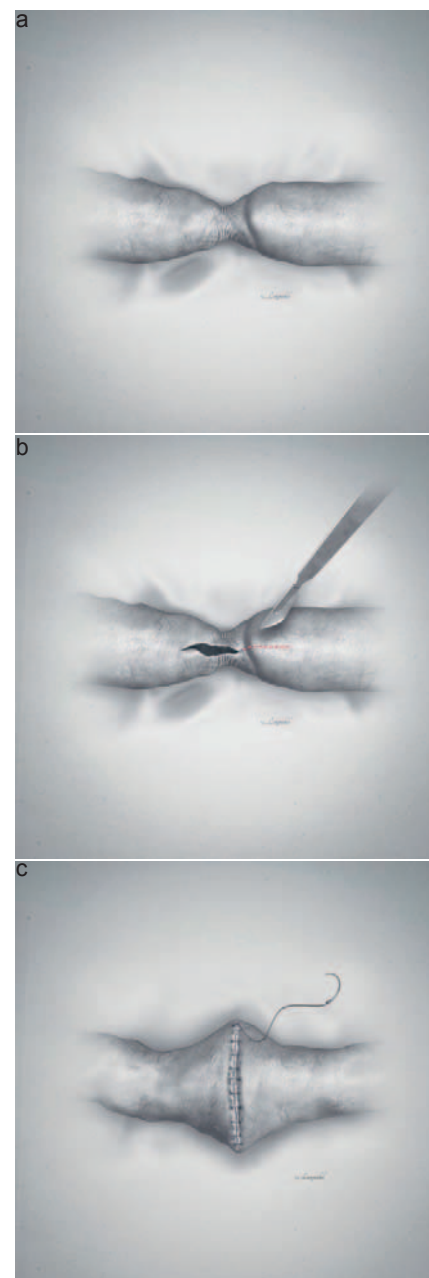


Fig. 1. a-c Surgical technique of stricturoplasty (graphics designed by R. and S. Langnickel).

ostomy or resection with diversion should be considered – at least as an individual interdisciplinary decision for each patient.

Stricturoplasty

The majority of patients with CD require surgery during some point in their life. Repeated extended bowel resections could result in short bowel syndrome with the consequence of malabsorption and life-threatening malnutrition. Stricturoplasty as an alternative surgical technique enables the widening of the stricture without loss of small intestine. The principle of stricturoplasty was initially performed in peptic ulcers. In 1982, Lee and Papaioannou [10] first described the use of stricturoplasty in patients with CD-associated strictures.

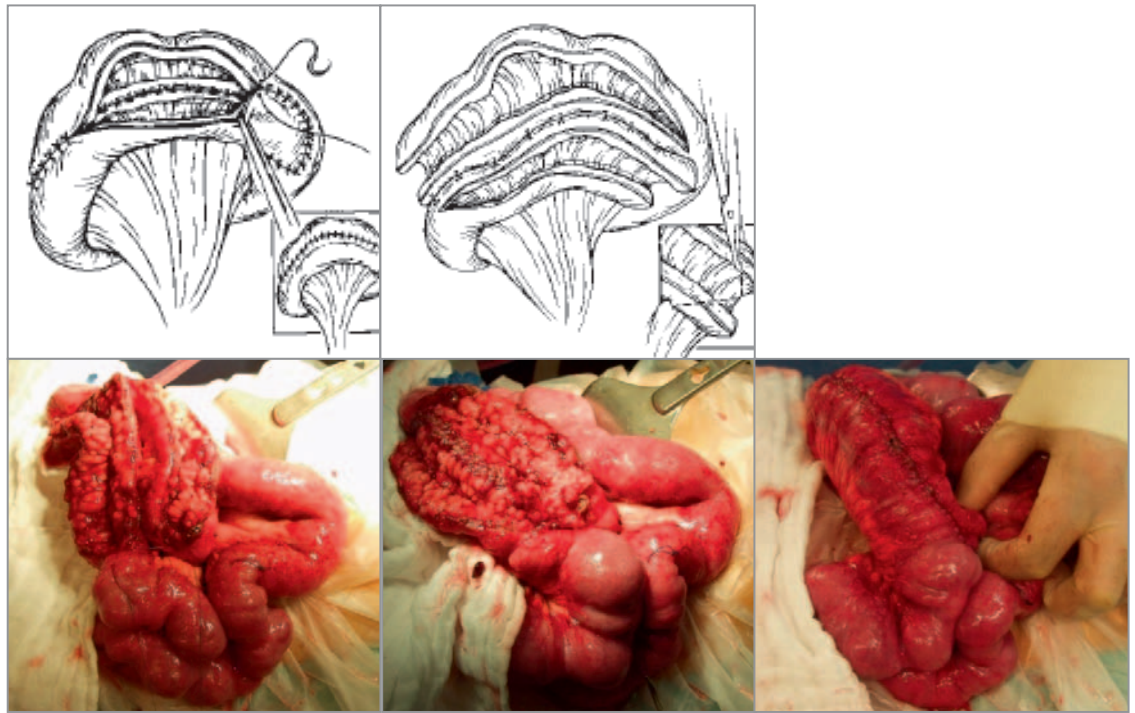


Fig. 2. Strictureplasty by Michelassi.

Strictureplasty should be performed in patients with many small bowel strictures in one long bowel segment as well as in patients with a history of prior resections and high risk for short bowel syndrome. Except in the case of long strictures, every stricture can be treated by strictureplasty. Strictures in the area of the ileocecal valve have to be treated by ileocecal resection. Contraindications for strictureplasty are acute inflammatory attacks with fistula, abscess, or perforation and signs of malignancy [11]. Strictureplasty is specified as safe and feasible in small bowel segments of the jejunum and ileum [11]. There is not enough data concerning strictures in the duodenum and colon. Therefore, these bowel segments should be treated by segmental resection or – in exceptional cases – by bypass [12, 13].

The treatment of choice for stenosis of less than 10 cm is the so-called Heineke-Mikulicz strictureplasty [12, 13]. Here, a longitudinal incision is made across the stricture and then closed transversely (fig. 1). Additionally, the so-called Finney strictureplasty is available. The longitudinal incision of the stricture is closed in a side-to-side technique. Additionally, a side-to-side isoperistaltic strictureplasty was described by Michelassi and colleagues [14]. This type of strictureplasty allows treatment of strictures as long as 20 cm (fig. 2). The decision whether to resect or to use these techniques of strictureplasties depends on the anatomic situation of the patient as well as on the surgeon's expertise.

Ileocecal Resection

When CD affects the small bowel, the main target is the terminal ileum. Scarred stenosis is a common consequence of recurring inflammation. Short stenoses can be treated by endoscopic dilata-

tion. Primarily, inflammatory stenoses are treated conservatively. Surgery is indicated in patients with refractory obstruction (failed medical or endoscopic treatment) [15]. The surgical procedure of choice is then ileocecal resection (fig. 3). The method of restoration of bowel continuity is widely discussed. End-to-end and side-to-side anastomosis are distinguished, and early postoperative outcomes are comparable with regard to anastomotic leakage or surgical site infections [16]. There is a potential risk of recurrent inflammatory activity after ileocecal resection. Approximately 20% of patients develop symptomatic stenoses. Up to 45% of the above-mentioned patients need further surgery [17]. Until now, none of the usually performed anastomotic techniques can be favored with regard to recurrence of CD at the anastomotic site [18].

A laparoscopic approach is preferable for ileocecal resection in patients with CD. In our department, the method of choice is minimally invasive surgery when indicated. The advantages of laparoscopic operations are enhanced recovery after surgery, better cosmetic results, less postoperative pain, less postoperative ileus, and shorter hospital stay. An additional incision for bowel extraction might be necessary in patients with complex interenteric fistula systems or conglomerate tumors. Creation of a stoma can be an additional safety measure when inflammation is present within the resection margins. As many of these patients are treated with immunosuppressive medication, ostomy can provide a safe surgical approach for the postoperative course [19].

Colectomy and Proctocolectomy

Over 60% of patients with CD suffer from colonic involvement. An isolated colitis Crohn occurs in 20% of these patients, and half

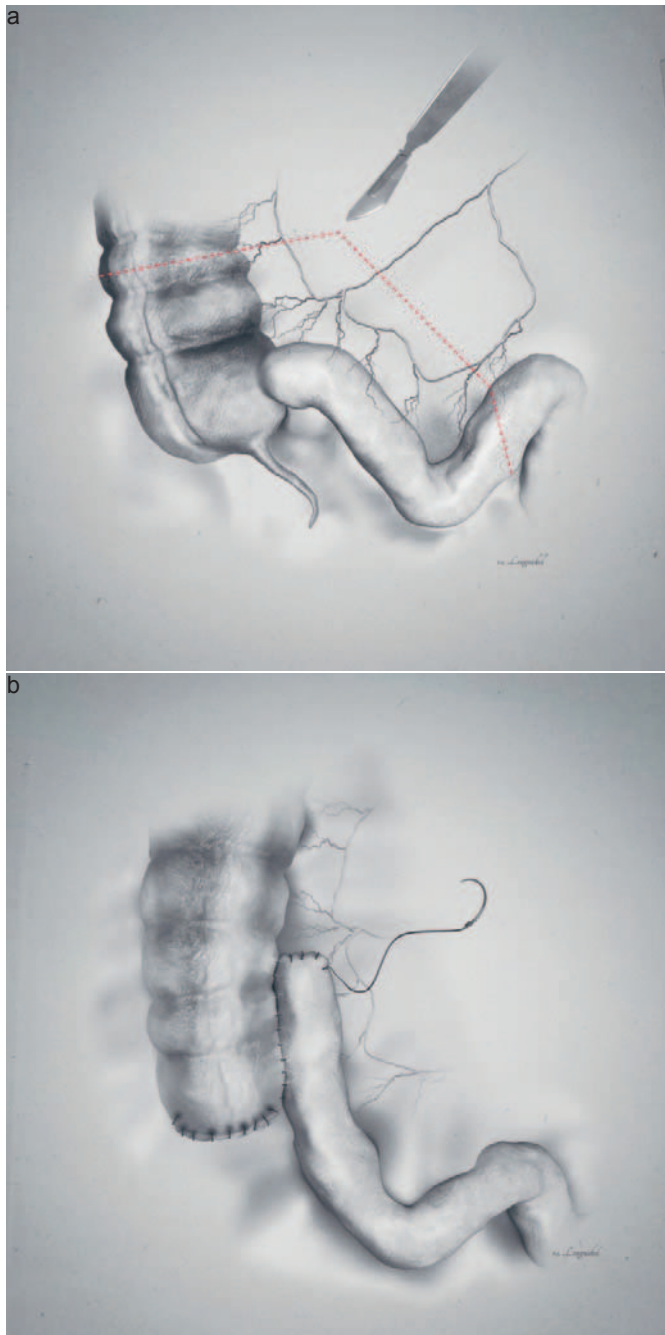


Fig. 3. **a** Ileocecal resection and **b** side-to-side anastomosis (graphics designed by R. and S. Langnickel).

of them suffer from rectal or perineal attacks [20, 21]. Differentiated surgical options have to be discussed, depending on the extent of colonic involvement.

Different surgical procedures for patients with extended colitis Crohn are available. In an emergency (bleeding, perforation), a subtotal colectomy should be performed [22]. Here, a rectal stump and an end ileostomy are used. After a recovery period, a restoration of bowel continuity can be performed. Patients with minimal or no rectal CD involvement can undergo ileorectal anastomosis. In cases of rectal disease with persistent proctitis or fistula/abscess formations, however, a delayed proctocolectomy should be per-

formed [23]. This results in a permanent ileostomy for the patient but is effectively the safest way of surgical treatment for colonic Crohn. Furthermore, the risk of developing colorectal cancer is eliminated.

Complete proctocolectomy and end ileostomy is the procedure of choice for patients with refractory pancolitis, proctitis, perianal fistula/abscess formation, and anal incontinence [20]. The affected bowel is completely removed, providing symptom relief and a definitely reduced risk of recurrence in other bowel districts and cancer [24]. Despite these advantages, the healing of the perineal wound and incidental pelvic nerve injury remain problematic aspects of this surgical procedure [25]. Up to 10% of patients develop surgical site infections [26]. Sexual dysfunction and/or incontinence can occur as a consequence of pelvic nerve damage and is noted in a small number of patients [19, 25].

For colectomy and proctocolectomy as well as segmental resection, a laparoscopic approach is possible. In an emergency (bleeding, perforation, toxic colon), open surgery is the treatment of choice.

Limited segment resections are possible in a small number of patients suffering only from segmental colonic affection. Furthermore, there is a high risk of recurrent colonic attacks with further surgical intervention. Additionally, consideration needs to be given to the percentage of patients with CD-associated colorectal cancer (5–6 patients) [27]. Therefore, investigative surveillance should be carried out in patients with a remaining colorectum. However, the advantage of segmental colon resection is the retaining of bowel function and the avoidance of stoma.

Anorectal Crohn's Disease

The anorectum is affected in 30% of patients with CD [28, 29]. 92% of patients with colorectal disease develop fistulas [29]. The risk of perineal manifestation increases with disease duration. Up to 10% of patients develop fistulas within 5 years, and up to 25% after 20 years [30–32].

Treatment of fistulas remains an interdisciplinary challenge. The dimension of inflammation should be evaluated by endoscopy, anal endosonography, and magnetic resonance imaging. Once CD involvement of the anorectum has been diagnosed, the gastroenterologist should initiate medical therapy. Beside antibiotics, a wide range of immunosuppressive medication is available for conservative treatment [33].

Fistulas can be classified into simple or complex fistulas. They are further categorized by their course, with regard to the anal sphincter: intersphincteric, transsphincteric, suprasphincteric, and superficial fistulas (fig. 4). Symptomatic perianal fistulas with abscess formation require surgical intervention. The first step to be taken is abscess incision and drainage of fistulas. If not already the case, medical therapy should be initiated as a next step. Ostomy can prove necessary in cases of active proctitis and fecal incontinence. If the rectal mucosa shows no signs of CD involvement, delayed surgical treatment can be performed. Good results are docu-

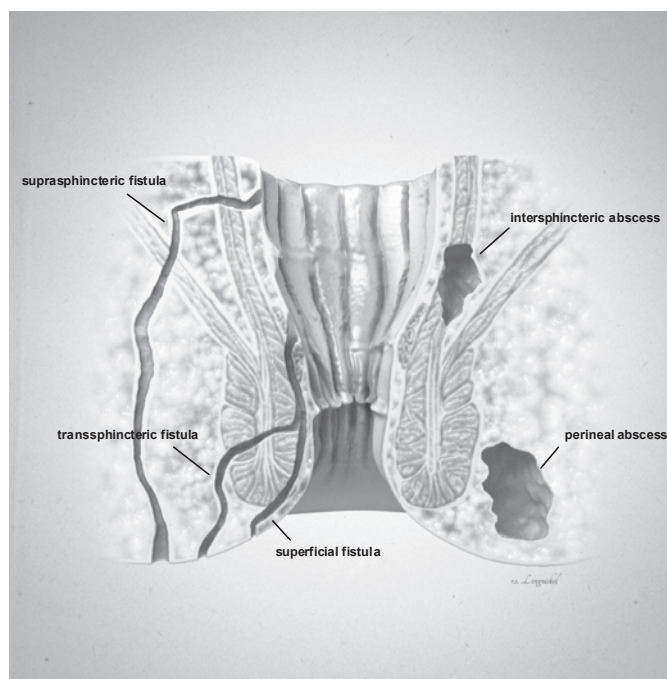


Fig. 4. Anorectal fistulas and abscesses (graphics designed by R. and S. Langnickel).

mented for fistulotomy in simple superficial fistulas with a healing rate of 80–100% [34]. However, fistulotomy is not indicated if the anal sphincter is involved, due to a high rate of postoperative fecal incontinence. Fistula healing is markedly reduced to 27% in case of active proctitis [35].

As a surgical option for fistula closure, the insertion of an endorectal advancement flap or a muscle flap can be considered. They are also used in complicated fistulas such as the rectovaginal course of the tract. Here, the internal opening of the fistula is excised and occluded or advanced by autologous mucosa-muscle tissue from the rectum. Both procedures are comparable as far as clinical and functional results are concerned [36]. Healing rates, in general, differ from 70–90% [37–39]. In contrast, healing is reduced in CD-associated fistulas. Recurrence rates of 20% are described [35]. However, ostomy is suggested in case of any surgical therapy due to rectovaginal fistulas.

Because of the high recurrence rate, there are further therapeutic strategies available. For example, closure of fistula using fibrin glue represents another option but is highly controversial. The glue consists of fibrinogen and thrombin and is injected in the fistula tract to fill and seal it. Healing rates show a wide range from ≤ 50 up to over 80% in the literature with regard to simple or CD-associated fistulas [40–42]. This method has some success but is not as effective as in fistulas not associated with CD [43].

The results after closure using a fistula plug show a success rate with a wide range from 20 to over 90% in two review studies. Although easy to use, the differing success rate means that this technique is not generally used in CD fistulas. The main failure rate results from plug loss in the postoperative course [32, 44, 45].

Proctectomy is required in patients with a refractory course after extended medical and surgical therapy as well as with complex anal fistula formation or proctitis. Sandborn et al. [34] describe a proctectomy rate of 10–20% for these patients. In addition, this procedure should be performed in the case of CD-associated anorectal cancer.

Ostomy

Generally, ostomy can be performed to increase the quality of life (e.g. rectovaginal fistulas), as a protective move in reconstructive CD surgery, or as permanent ostomy (e.g. proctectomy). In detail, there is a wide range of indications for stoma creation in patients with CD, such as perianal and ano-/rectovaginal fistulas, strictures, incontinence, and refractory proctitis.

Treatment of perianal fistulas ranges from conservative strategies and minimal surgery (seton/fistulotomy) to definitive surgery with closure of the fistula tract or even proctectomy and finally diversion. Indications for ostomy in perianal fistula burden comprise temporary bags to i) restore quality of life (e.g. vaginal delivery in ano-/rectovaginal fistulas) and ii) to protect complex reconstructive surgery (e.g. gracilis muscle interposition) as well as definitive end ostomy in refractory fecal incontinence due to sphincter destruction and refractory proctitis. Furthermore, in complicated or complex fistulas combined with proctocolitis, intensified medical treatment following ostomy may be indicated as an individual salvage procedure to control inflammation. There are reports that new medicals, like biologicals, can improve the healing process and increase the chance for stoma closure in combination with a transient stoma. Infliximab was shown to reduce the secretion of fistulas. Present et al. [46] could show a 56–68% reduction of draining fistulas and a 38–55% fistula closure in patients with intra-abdominal and perianal fistulas treated with 5–10 mg infliximab per kilogram body weight. However, the literature is conflicting on this topic as some studies could not show any benefit of biologicals to avoid permanent stoma creation in perianal CD [47].

The treatment of rectovaginal fistulas (excision, fistula closure – Martius flap, gracilis flap, drainages, or fibrin glue) is often unsatisfying and associated with high recurrence rates from 25 to 50% [48–52]. There is some advice that the combined treatment of ostomy and immunosuppressives (e.g. TNF-alpha inhibitors) could increase the healing rate. However, data are rare and conflicting. Therefore, an ostomy is commonly required [53].

A further indication for stoma creation is severe proctitis. Diverting ostomy can be performed to reduce mucosal infection and secretion. After stoma creation, local therapy such as rectal foams can be applied and combined with general immunosuppressive medication, if necessary. In case of complex proctitis with fistula and abscess formations or cancer, proctectomy and permanent ostomy is indicated.

Patients with recurrent perianal affection are known to have an increased risk for gradually developing fecal incontinence. Reduced quality of life, gluteal skin infections, and social depression often lead to stoma construction.

Anorectal CD also involves strictures. These are categorized into inflammatory or fibrotic and reversible or irreversible types by the Cardiff classification [54]. Literature concerning the therapy of anorectal strictures in CD remains rare [55, 56]. In a multivariate analysis, the presence of colonic disease and anal canal stricture were predictors of permanent diversion [56]. The risk of permanent diversion for patients with CD was 33 times higher in the presence of both colonic disease and anal canal stenosis. Interestingly, patients with anal stricture who performed self-dilation of these strictures were less likely to require diversion. Moreover, Brochard et al. [55] reported increased stricture healing rates when treated with TNF-alpha antagonists.

Furthermore, permanent ostomy might prove necessary, for instance when resection is not possible or when patients are unsuitable for anesthesia. Similarly, ostomy should be considered in patients with major resections in the past, extensive adhesions, or possible short bowel syndrome. An ostomy can also be temporarily used as a bridge to definitive surgical treatment. The combination of stoma creation and immunosuppressive medication can help patients to recover and can avoid extended resections. However, some studies could not find any positive effect of biologicals such as TNF-alpha inhibitors on healing rates and no benefit regarding stoma closure [57]. The need for ostomy in severe perianal CD affection ranges between 31 and 49% [56–58]. Additionally, stoma closure rates are as low as 20–50% in patients with perianal CD affection [57–59]. This is mainly related to the persistence of proctitis or the

recurrence of fistulas. In case of transient ostomy, stoma closure can be performed 6–12 weeks after the definitive operation.

Conclusion

A wide range of indications for surgery exists in patients with CD. Many sophisticated techniques are available. Considering that CD cannot be cured, indications for surgery have to be strict and surgery should be performed as limited and minimally invasive as possible. Close cooperation between surgeons and gastroenterologists is important for first-line conservative treatment, induction therapy, and maintenance of remission.

Acknowledgment

CS, MK, and JG designed this study. All authors read and approved the final manuscript.

The authors thank Susann Power and Stephanie Bues for their translational support of the manuscript. Special thanks go to Sebastian and Robert Langnickel for their creativity in the design of the graphics.

Disclosure Statement

Claudia Seifarth, Martin E. Kreis, and Jörn Gröne have no conflicts of interest or financial ties to disclose.

References

- Romberg-Camps MJL, Dagnelie PC, Kester ADM, et al: Influence of phenotype at diagnosis and of other potential prognostic factors on the course of inflammatory bowel disease. *Am J Gastroenterol* 2009;104:371–383.
- Singleton JW, Law DH, Kelley ML, et al: National Co-operative Crohn's Disease Study: adverse reactions to study drugs. *Gastroenterology* 1979;77:870–882.
- Bemelman WA, Allez M: The surgical intervention: earlier or never? *Best Pract Res Clin Gastroenterol* 2014;28:497–503.
- Eisner F, Küper MA, Ziegler F, et al: Impact of perioperative immunosuppressive medication on surgical outcome in Crohn's Disease (CD). *Z Gastroenterol* 2014;52:436–440.
- Lee YW, Lee K-M, Chung WC, et al: Clinical and endoscopic recurrence after surgical resection in patients with Crohn's disease. *Intest Res* 2014;12:117–123.
- Aberra FN, Lewis JD, Hass D, et al: Corticosteroids and immunomodulators: postoperative infectious complication risk in inflammatory bowel disease patients. *Gastroenterology* 2003;125:320–327.
- Yamamoto T, Allan RN, Keighley MR: Risk factors for intra-abdominal sepsis after surgery in Crohn's disease. *Dis Colon Rectum* 2000;43:1141–1145.
- Kopylov U, Ben-Horin S, Zmora O, et al: Anti-tumor necrosis factor and postoperative complications in Crohn's disease: systematic review and meta-analysis. *Inflamm Bowel Dis* 2012;18:2404–2413.
- Nørgård BM, Nielsen J, Qvist N, et al: Pre-operative use of anti-TNF- α agents and the risk of post-operative complications in patients with Crohn's disease – a nationwide cohort study. *Aliment Pharmacol Ther* 2013;37:214–224.
- Lee EC, Papaioannou N: Minimal surgery for chronic obstruction in patients with extensive or universal Crohn's disease. *Ann R Coll Surg Engl* 1982;64:229–233.
- Hesham W, Kann BR: Strictureplasty. *Clin Colon Rectal Surg* 2013;26:80–83.
- Campbell L, Ambe R, Weaver J, et al: Comparison of conventional and nonconventional strictureplasties in Crohn's disease: a systematic review and meta-analysis. *Dis Colon Rectum* 2012;55:714–726.
- Yamamoto T, Fazio VW, Tekkis PP: Safety and efficacy of strictureplasty for Crohn's disease: a systematic review and meta-analysis. *Dis Colon Rectum* 2007;50:1968–1986.
- Michelassi F, Balestracci T, Chappell R, Block GE: Primary and recurrent Crohn's disease. Experience with 1379 patients. *Ann Surg* 1991;214:230–238; discussion 238–240.
- Solberg IC, Vatn MH, Høie O, et al: Clinical course in Crohn's disease: results of a Norwegian population-based ten-year follow-up study. *Clin Gastroenterol Hepatol* 2007;5:1430–1438.
- Zurbuchen U, Kroesen AJ, Knebel P, et al: Complications after end-to-end vs. side-to-side anastomosis in ileocecal Crohn's disease – early postoperative results from a randomized controlled multi-center trial (ISRCTN-45665492). *Langenbecks Arch Surg* 2013;398:467–474.
- Yamamoto T: Factors affecting recurrence after surgery for Crohn's disease. *World J Gastroenterol* 2005;11:3971–3979.
- McLeod RS, Wolff BG, Ross S, et al: Recurrence of Crohn's disease after ileocolic resection is not affected by anastomotic type: results of a multicenter, randomized, controlled trial. *Dis Colon Rectum* 2009;52:919–927.
- Seifarth C, Ritz JP, Pohlen U, et al: Therapy of complicated Crohn's disease during pregnancy – an interdisciplinary challenge. *Int J Colorectal Dis* 2014;29:645–651.
- Hedrick TL, Friel CM: Colonic Crohn disease. *Clin Colon Rectal Surg* 2013;26:84–89.
- Loftus EV, Schoenfeld P, Sandborn WJ: The epidemiology and natural history of Crohn's disease in population-based patient cohorts from North America: a systematic review. *Aliment Pharmacol Ther* 2002;16:51–60.
- Hyman NH, Cataldo P, Osler T: Urgent subtotal colectomy for severe inflammatory bowel disease. *Dis Colon Rectum* 2005;48:70–73.
- Longo WE, Oakley JR, Lavery IC, et al: Outcome of ileorectal anastomosis for Crohn's colitis. *Dis Colon Rectum* 1992;35:1066–1071.
- Amiot A, Gornet J-M, Baudry C, et al: Crohn's disease recurrence after total proctocolectomy with definitive ileostomy. *Dig Liver Dis* 2011;43:698–702.
- Ilnyckyj A: Surgical treatment of inflammatory bowel diseases and pregnancy. *Best Pract Res Clin Gastroenterol* 2007;21:819–834.

- 26 Goligher JC: The long-term results of excisional surgery for primary and recurrent Crohn's disease of the large intestine. *Dis Colon Rectum* 1985;28:51–55.
- 27 Choi PM, Zelig MP: Similarity of colorectal cancer in Crohn's disease and ulcerative colitis: implications for carcinogenesis and prevention. *Gut* 1994;35:950–954.
- 28 Safar B, Sands D: Perianal Crohn's disease. *Clin Colon Rectal Surg* 2007;20:282–293.
- 29 Schwartz DA, Loftus EV, Tremaine WJ, et al: The natural history of fistulizing Crohn's disease in Olmsted County, Minnesota. *Gastroenterology* 2002;122:875–880.
- 30 Cosnes J, Cattan S, Blain A, et al: Long-term evolution of disease behavior of Crohn's disease. *Inflamm Bowel Dis* 2002;8:244–250.
- 31 Roberts PL, Schoetz DJ, Pricolo R, Veidenheimer MC: Clinical course of Crohn's disease in older patients. A retrospective study. *Dis Colon Rectum* 1990;33:458–462.
- 32 Lewis RT, Bleier JIS: Surgical treatment of anorectal Crohn disease. *Clin Colon Rectal Surg* 2013;26:90–99.
- 33 Dejaco C, Harrer M, Waldhoer T, et al: Antibiotics and azathioprine for the treatment of perianal fistulas in Crohn's disease. *Aliment Pharmacol Ther* 2003;18:1113–1120.
- 34 Sandborn WJ, Fazio VW, Feagan BG, et al: AGA technical review on perianal Crohn's disease. *Gastroenterology* 2003;125:1508–1530.
- 35 Nordgren S, Fasth S, Hultén L: Anal fistulas in Crohn's disease: incidence and outcome of surgical treatment. *Int J Colorectal Dis* 1992;7:214–218.
- 36 Athanasiadis S, Nafe M, Köhler A: Transanal rectal advancement flap versus mucosa flap with internal suture in management of complicated fistulas of the anorectum (Article in German). *Langenbecks Arch Chir* 1995;380:31–36.
- 37 Hull TL, Fazio VW: Surgical approaches to low anovaginal fistula in Crohn's disease. *Am J Surg* 1997;173:95–98.
- 38 Kodner IJ, Mazor A, Shemesh EI, et al: Endorectal advancement flap repair of rectovaginal and other complicated anorectal fistulas. *Surgery* 1993;114:682–689; discussion 689–690.
- 39 Sher ME, Bauer JJ, Gelernt I: Surgical repair of rectovaginal fistulas in patients with Crohn's disease: transvaginal approach. *Dis Colon Rectum* 1991;34:641–648.
- 40 Cintron JR, Park JJ, Orsay CP, et al: Repair of fistulas-in-ano using fibrin adhesive: long-term follow-up. *Dis Colon Rectum* 2000;43:944–949; discussion 949–950.
- 41 Swinscoe MT, Ventakasubramaniam AK, Jayne DG: Fibrin glue for fistula-in-ano: the evidence reviewed. *Tech Coloproctol* 2005;9:89–94.
- 42 Zmora O, Neufeld D, Ziv Y, et al: Prospective, multicenter evaluation of highly concentrated fibrin glue in the treatment of complex cryptogenic perianal fistulas. *Dis Colon Rectum* 2005;48:2167–2172.
- 43 Loungnarath R, Dietz DW, Mutch MG, et al: Fibrin glue treatment of complex anal fistulas has low success rate. *Dis Colon Rectum* 2004;47:432–436.
- 44 Garg P, Song J, Bhatia A, et al: The efficacy of anal fistula plug in fistula-in-ano: a systematic review. *Colorectal Dis* 2010;12:965–970.
- 45 O'Riordan JM, Datta I, Johnston C, Baxter NN: A systematic review of the anal fistula plug for patients with Crohn's and non-Crohn's related fistula-in-ano. *Dis Colon Rectum* 2012;55:351–358.
- 46 Present DH, Rutgeerts P, Targan S, et al: Infliximab for the treatment of fistulas in patients with Crohn's disease. *N Engl J Med* 1999;340:1398–1405.
- 47 Uzzan M, Stefanescu C, Maggiori L, et al: Case series: does a combination of anti-tnf antibodies and transient ileal fecal stream diversion in severe Crohn's colitis with perianal fistula prevent definitive stoma? *Am J Gastroenterol* 2013;108:1666–1668.
- 48 Hannaway CD, Hull TL: Current considerations in the management of rectovaginal fistula from Crohn's disease. *Colorectal Dis* 2008;10:747–755; discussion 755–756.
- 49 El-Gazzaz G, Hull T, Mignanelli E, et al: Analysis of function and predictors of failure in women undergoing repair of Crohn's related rectovaginal fistula. *J Gastrointest Surg* 2010;14:824–829.
- 50 Joo JS, Weiss EG, Noguera JJ, Wexner SD: Endorectal advancement flap in perianal Crohn's disease. *Am Surg* 1998;64:147–150.
- 51 Halverson AL, Hull TL, Fazio VW, et al: Repair of recurrent rectovaginal fistulas. *Surgery* 2001;130:753–757; discussion 757–758.
- 52 Ozuner G, Hull TL, Cartmill J, Fazio VW: Long-term analysis of the use of transanal rectal advancement flaps for complicated anorectal/vaginal fistulas. *Dis Colon Rectum* 1996;39:10–14.
- 53 Gaertner WB, Madoff RD, Spencer MP, et al: Results of combined medical and surgical treatment of rectovaginal fistula in Crohn's disease. *Colorectal Dis* 2011;13:678–683.
- 54 Hughes LE: Clinical classification of perianal Crohn's disease. *Dis Colon Rectum* 1992;35:928–932.
- 55 Brochard C, Siproudhis L, Wallenhorst T, et al: Anorectal stricture in 102 patients with Crohn's disease: natural history in the era of biologics. *Aliment Pharmacol Ther* 2014;40:796–803.
- 56 Galandiuk S, Kimberling J, Al-Mishlab TG, Stromberg AJ: Perianal Crohn disease: predictors of need for permanent diversion. *Ann Surg* 2005;241:796–801; discussion 801–802.
- 57 Mueller MH, Geis M, Glatzle J, et al: Risk of fecal diversion in complicated perianal Crohn's disease. *J Gastrointest Surg* 2007;11:529–537.
- 58 Hong MKH, Craig Lynch A, Bell S, et al: Faecal diversion in the management of perianal Crohn's disease. *Colorectal Dis* 2011;13:171–176.
- 59 Gu J, Valente MA, Renzi FH, Stocchi L: Factors affecting the fate of faecal diversion in patients with perianal Crohn's disease. *Colorectal Dis* 2015;17:66–72.