

Oral rehabilitation of a young patient with hypohidrotic ectodermal dysplasia: A clinical report

ANUROOPA A., JAFAR ABDULLA, LOVELY M.

Abstract

Ectodermal dysplasia (ED) represents a group of patients with mild to severe congenital and developmental anomalies. Dentists are the first person to identify ED in young patients. The impairment is not just the form and function but extends to the social outlook as well as the psychology of the affected individual. This case report describes management of ED with a long-span fixed partial denture fabricated using a Broadrick flag.

Keywords: Custom made Broadrick flag, curve of spee, ectodermal dysplasia

Introduction

Ectodermal dysplasia (ED) comprises of a large, heterogeneous group of inherited disorders in which two or more structure derived from embryonic ectoderm are affected, i.e., skin, hair, nails, nerve cells, sweat glands, part of eye and ear as well as dentition. Thurman published the first case report in 1848 while the term “Ectodermal dysplasia” was coined by Weech in 1929. The frequency of different EDs in a given population is highly variable with a prevalence of seven cases per 10 000 births. Clinically, they are classified as hypohidrotic and hidrotic type of ED. The most common EDs are X-linked recessive hypohidrotic ED (Christ-Siemens-Touraine syndrome) and hidrotic ED (Clouston syndrome).^[1] Hypohidrotic ED represents with hypodontia or anodontia, hypotrichosis, and hypohidrosis or anhidrosis. Hidrotic type of ED is more severe form presented with sensitivity to heat, frequent high fevers and is associated with more dental defects. Significant oral findings include hypodontia (80%), loss of occlusal vertical dimension, protuberant lips, and lack of normal alveolar ridge development.^[1] Affected males have agenesis of primary and permanent teeth, whereas heterozygous females have agenesis of permanent teeth.^[2]

Tooth malformations such as conical teeth and taurodontism of the molars are common findings, whereas oligodontia is a key feature in hypohidrotic ED.^[3] This case report emphasizes on the prosthetic management of ED by enhancing the appearance and function through full mouth rehabilitation with a long-span fixed partial denture designed using a custom made Broadrick flag.

Case Report

A 17-year-old female patient reported to the Department of Prosthodontics, SreeMookambika institute of Dental Sciences, Kulasekharam, Tamilnadu, with the complaint of absence of upper and lower front teeth. Extraoral examination showed mild facial dysmorphism, depressed nasal bridge, and protuberant lips [Figure 1].

Intraoral examination revealed dry mucosa with partial anodontia and conical-shaped canines and premolars. Occlusal examination revealed class I molar occlusal relation on left quadrants, whereas there was no occlusion on right quadrant [Figure 2]. Radiographic examination showed wide pulp chambers in all the teeth with a thin layer of dentin and

Department of Prosthodontics including Crown and Bridge and Implantology, Sree Mookambika Institute of Dental Sciences, Kulasekharam, Tamil Nadu, India

Correspondence: Dr. Anuroopa A., 28/5B Anubhavan, North Street, Marthandam, Kanyakumari, Tamilnadu – 629165, India. E-mail: anushenbi@yahoo.co.in

| Access this article online | |
|---|-------------------------------------|
| Quick Response Code: | Website: www.contempclindent.org |
|  | DOI: 10.4103/0976-237X.95101 |



Figure 1: Extraoral examination

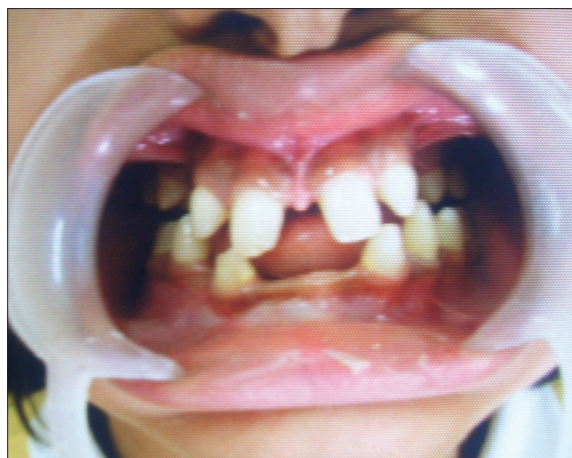


Figure 2: Intraoral examination

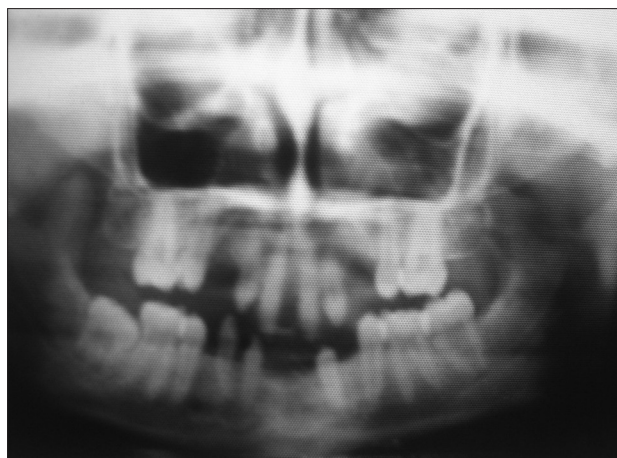


Figure 3: Radiographic examination

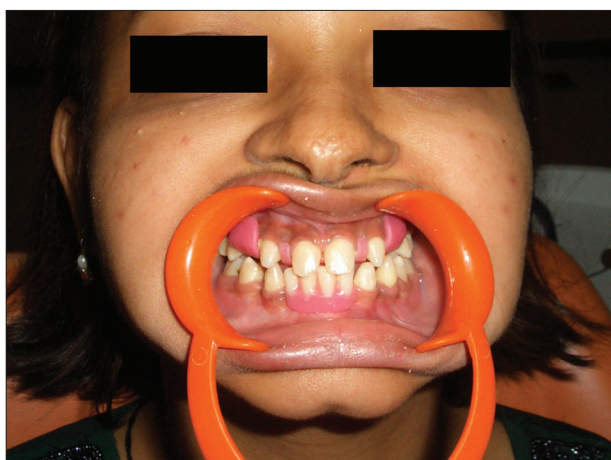


Figure 4: After orthodontic correction

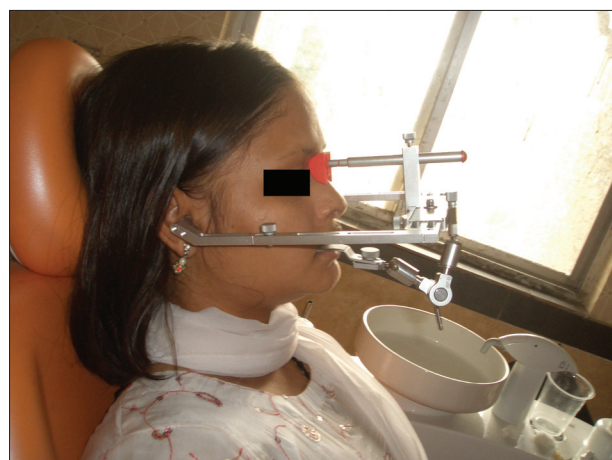

Figure 5: Facebow transfer

enamel [Figure 3]. The provisional diagnosis was ED and the treatment plan was ruled out to be orthodontic correction of occlusal relation followed by esthetic rehabilitation of the partially edentulous situation using long-span bridges in both maxillary and mandibular arch.

Orthodontic correction was done after which [Figure 4] a diagnostic impression (zelgan2002) was made and face bow transfer [Figure 5] was done. An interocclusal (virtual bite registration paste) record was used to articulate casts in Amman Girbach Artex semi adjustable AP type articulator. A custom made Broadrick flag was fabricated using autopolymerizing acrylic resin (DPI self cure powder, The Bombay Burmah Trading Corporation, Mumbai) [Figure 6]. This was attached to the upper member of the articulator using a resin jig and occlusal plane as well as curve of spee was determined. A curve of spee is an arc of curve that passes through the cusp tip of mandibular teeth to condyle; it is possible to locate the center of curve on the flag using a compass. For this, two reference points were taken into consideration, the distal slope of mandibular canine as anterior reference point and the distal inclines of the distobuccal cusp of last molar as the posterior reference

point. The arms of the compass were spread at four inches and were placed on the posterior reference point and an arc was drawn over the flag. The procedure was repeated by placing the compass on the anterior reference point and another arc was drawn on the flag to obtain an intersection point which is the proposed center of the curve of Spee. The compass is placed over this intersection point on the flag and a curve is scribed onto the occlusal surface of the lower teeth which represents the actual occlusal plane of the patient. This arc was transferred to the patient's mouth during tooth preparation using an acrylic stent. Conservative tooth preparation was done in all teeth with knife edge finish line except the second molars which had an open apex. Master impression was made using putty wash technique (Aquasil) followed by facebow transfer and articulation.

Temporization was done using tooth color acrylic resin bridge [Figure 6] (OPI The Bombay Burman Trading Corporation Ltd). Wax pattern was fabricated and the occlusal plane was verified using the Broadrick flag. Casting was done, followed by verification of the metal coping in the patient's mouth [Figure 7].



Figure 6: Custom made Broadrick flag

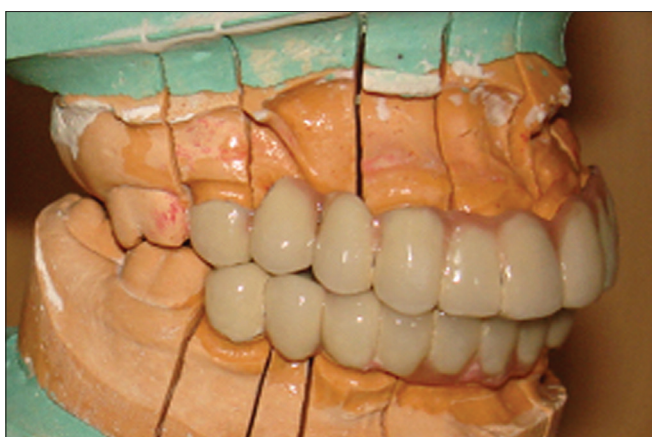

Figure 8: Prosthesis in the articulator

Porcelain shade selected prior to tooth preparation was applied to form a long-span 12-unit Maxillary and 11-unit mandibular bridge [Figure 8]. A canine-guided occlusion was the occlusal scheme given in this patient. The bridges were cemented using GIC type I (GC, Gold Label Glass Ionomer, Luting, Lining Cement GC Corporation Tokyo, Japan). Occlusion was verified using articulating paper (unident instruments (India) pvt ltd). Oral hygiene instructions were given and a periodic review was done every three months [Figure 9].

Discussion

Prosthodontic management of an ED patient includes fabrication of complete or partial removable prostheses, over dentures with or without tooth preparation, or overdenture with or without attachments, long-span fixed partial denture prosthesis, and dental implants.^[4-7] The placement of implants in growing children is not recommended in the maxilla, where the implants can be submerged by the downward growth of investing tissues. Implant placement can be considered in anterior mandible as the growth of anterior mandible is completed by 3 years of age. A limiting factor is that it is necessary to remake the prostheses to accommodate

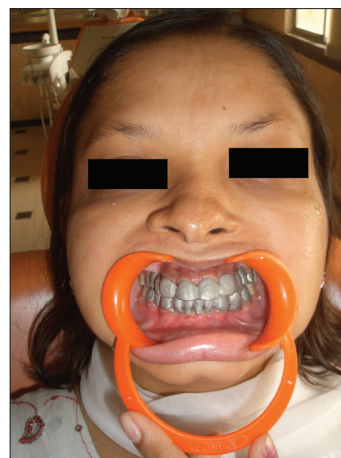

Figure 7: Metal try-in

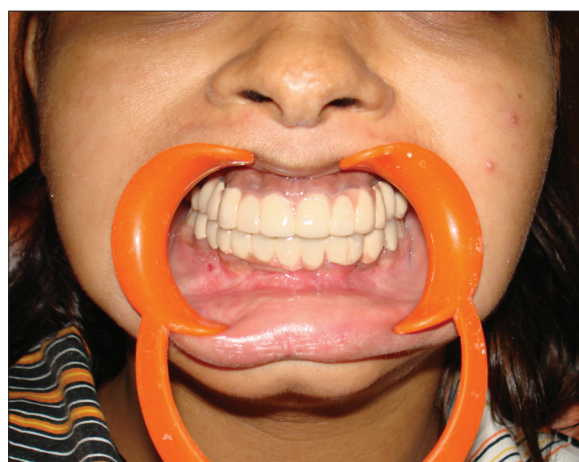

Figure 9: Completed prosthesis

changes in occlusal plane as the person grows.^[8] Hence, removable of denture is the suggested treatment modality for young patients due to rapid growth of the jaws, while the underdeveloped ridges may affect the retention and stability. If fewer teeth are present, a tooth supported over denture or an overdenture with attachment can be advised.

Once the full growth is attained, a fixed partial denture or and endosseous implant therapy can be performed in these patients. Lack of bone density, knife edge mandible ridge which requires bone grafting for the placement of implants precluded the use of implants in the present case scenario.

In this case scenario, the treatment philosophy followed is the full mouth rehabilitation using simultaneous restoration of both the arches as advocated by Bailey, Grubb, Linkow, Sendax, and Kazis.^[9,10] Full mouth rehabilitation with long-span fixed partial denture resulted in improvement of the function, esthetics, and the psychosocial confidence of the patient. The challenge to restorative dentist when restoring posterior dentition is to obtain the most suitable position and orientation of the posterior occlusal scheme where the natural curve of spee is deranged. Broadrick flag is a simple

tool which provides a close approximation of patients' original occlusal curve, thereby permitting an ideal occlusal reconstruction.^[11,12]

Summary and Conclusion

A full mouth rehabilitation therapy was provided for a patient suffering from ED which restored the form, function, esthetics, and confidence of the affected individual.

References

- Guckes AD, Scurria MS, King TS, McCarthy GR, Brahim JS. Prospective clinical trial of dental implants in persons with ectodermal dysplasia. *J Prosthet Dent* 2002;88:21-5.
- Lexner MO, Bardow A, Hertz JM, Nielsen LA, Kreiborg S. Anomalies of tooth formation in hypohidrotic ectodermal dysplasia. *Int J Paediatr Dent* 2007;17:10-8.
- Schalk-van der Weide Y, Beemer FA, Faber JA, Bosman F. Symptomatology of patients with oligodontia. *J Oral Rehab* 1994;21:247-61.
- Lakomski J, Kobiela K, Kobiela A, Trzeciak WH. Correcting facial dysmorphism in a patient with anhidrotic ectodermal dysplasia – A clinical report. *J Prosthet Dent* 1998;80:524-6.
- Escobar V, Epker BN. Alveolar bone growth in response to endosteal implants in two patients with ectodermal dysplasia. *Int J Oral Maxillofac Surg* 1998;27:445-7.
- Peñarrocha-Diago M, Uribe-Origone R, Rambla-Ferrer J, Guarinos-Carbó J. Fixed rehabilitation of a patient with hypohidrotic ectodermal dysplasia using zygomatic-implants. *Oral Surg Oral Med Oral Pathol Oral Radiol Endodontology* 2004;98:161-5.
- Pae A, Kim K, Kim HS, Kwon KR. Over denture restoration in growing patient with hypohidrotic Ectodermal dysplasia- A clinical report. *Quintessence Int* 2011;42:235-8.
- Rad AS, Siadat H, Monzavi A, Mangoli AA. Full mouth rehabilitation of Hypohidrotic Ectodermal Dysplasia patient with dental implants: A clinical Report. *J Prosthodont* 2007;16:209-13.
- Kumar SN, Patil NP, Guttai SS, Nadiger RK. Full mouth rehabilitation of severely attrited dentition: A case report. *NY State Dent J* 2010;76:47-50.
- Suri S, Carmichael RP, Tompson BD. Tompson Simultaneous functional and fixed appliance therapy for growth modification and dental alignment prior to prosthetic habilitation in hypohidrotic ectodermal dysplasia: A clinical report. *J Prosthet Dent* 2004;92:428-33.
- Craddock HL, Lynch CD, Franklin P, Youngson CC, Manogue M. A study of the proximity of the Broadricks ideal occlusal curve in dentate patients. *J Oral Rehabil* 2005;32:895-900.
- Tarjan I, Gabris K, Rozsa N. Early prosthetic treatment of patients with ectodermal dysplasia: A clinical report. *J Prosthet Dent* 2005;93:419-24.

How to cite this article: Anuroopa A, Abdulla J, Lovely M. Oral rehabilitation of a young patient with hypohidrotic ectodermal dysplasia: A clinical report. *Contemp Clin Dent* 2012;3:S33-6.

Source of Support: Nil. **Conflict of Interest:** None declared.

Author Help: Reference checking facility

The manuscript system (www.journalonweb.com) allows the authors to check and verify the accuracy and style of references. The tool checks the references with PubMed as per a predefined style. Authors are encouraged to use this facility, before submitting articles to the journal.

- The style as well as bibliographic elements should be 100% accurate, to help get the references verified from the system. Even a single spelling error or addition of issue number/month of publication will lead to an error when verifying the reference.
- Example of a correct style
Sheahan P, O'leary G, Lee G, Fitzgibbon J. Cystic cervical metastases: Incidence and diagnosis using fine needle aspiration biopsy. *Otolaryngol Head Neck Surg* 2002;127:294-8.
- Only the references from journals indexed in PubMed will be checked.
- Enter each reference in new line, without a serial number.
- Add up to a maximum of 15 references at a time.
- If the reference is correct for its bibliographic elements and punctuations, it will be shown as CORRECT and a link to the correct article in PubMed will be given.
- If any of the bibliographic elements are missing, incorrect or extra (such as issue number), it will be shown as INCORRECT and link to possible articles in PubMed will be given.