



Contents lists available at ScienceDirect

International Journal of Surgery Case Reports

journal homepage: www.casereports.com

Amyand's hernia complicated with appendix perforation treated by two-stage surgery consisting of laparoscopic appendectomy followed by elective inguinal hernioplasty: A case report

Ryujiro Akaishi^{a,b,*}, Ryuichi Nishimura^{a,b}, Kiminari Naoshima^a, Shukichi Miyazaki^a

^a Department of Surgery, Iwate Prefectural Chubu Hospital, 17-10 Murasakino, Kitakami-shi, Iwate 024-8507, Japan

^b Department of Surgery, Tohoku University Graduate School of Medicine, 1-1 Seiryō-machi, Aoba-ku, Sendai, Miyagi 980-8574, Japan

ARTICLE INFO

Article history:

Received 31 January 2018

Received in revised form 5 April 2018

Accepted 15 April 2018

Available online 21 April 2018

Keywords:

Amyand's hernia

Appendix perforation

Laparoscopic appendectomy

Inguinal hernioplasty

Case report

ABSTRACT

INTRODUCTION: An inguinal hernia with an incarcerated appendix is defined as Amyand's hernia, and it is relatively rare. Amyand's hernia complicated with appendicitis, especially perforated appendicitis, is even rarer. Postoperative surgical site infection (SSI) is a dangerous complication, especially in Amyand's hernia with appendix perforation. The selection of an appropriate surgical approach is necessary to prevent postoperative SSI. Here, we report a case of Amyand's hernia complicated with appendix perforation that was successfully managed using a two-stage surgical approach consisting of laparoscopic appendectomy followed by elective inguinal hernioplasty.

PRESENTATION OF CASE: A 70-year-old male presented with fever and right lower quadrant pain from the day before.

After the patient was diagnosed with acute appendicitis within a right inguinal hernia, emergency laparoscopy was performed. The appendix was incarcerated in the right internal inguinal ring and perforated at the base. We decided to take a two-stage surgical approach to avoid postoperative SSI and performed only laparoscopic appendectomy. No postoperative complications occurred. Inguinal hernioplasty was performed 1 month after the first operation. There were no adhesions in the preperitoneal space, and no adverse events occurred postoperatively.

CONCLUSIONS: A two-stage surgical approach consisting of laparoscopic appendectomy followed by elective inguinal hernioplasty was used successfully to treat Amyand's hernia complicated with appendix perforation without causing postoperative SSI.

© 2018 The Author(s). Published by Elsevier Ltd on behalf of IJS Publishing Group Ltd. This is an open access article under the CC BY-NC-ND license (<http://creativecommons.org/licenses/by-nc-nd/4.0/>).

1. Introduction

The incidence of appendicitis within an inguinal hernia is rare, at 0.1%, and that of perforated appendicitis is even rarer, at 0.01% [1,2]. The inflammatory status of the vermiform appendix determines the surgical approach and the type of hernia repair [2]. Losanoff and Basson have distinguished four basic types of Amyand's hernia, which should be treated differently [3].

The use of laparoscopic surgery for both diagnostic and therapeutic purposes in Amyand's hernia has recently become a new trend [2,4–6]. Most reported cases of Amyand's hernia treated laparoscopically have involved either a healthy or an inflamed appendix [4,5,7–9]. Very few cases of Amyand's hernia with appendix perforation have used laparoscopy as a therapeutic tool

[10]. Postoperative SSI is a major concern, especially in perforated cases. Initiating the operation with laparoscopic transabdominal approach enables to confirm whether the appendix is perforating or not and gives the alternative of elective hernioplasty. Furthermore, by applying two separate routes of laparoscopic transabdominal and inguinal approach, applying appendectomy and hernioplasty in two separate periods, may be useful to prevent postoperative SSI in Amyand's hernia with appendix perforation. Here, we report a case of Amyand's hernia complicated with appendix perforation which was successfully managed using a two-stage surgical approach consisting of laparoscopic appendectomy followed by elective inguinal hernioplasty. This work has been reported in line with the SCARE criteria [11].

2. Presentation of the case

A 70-year-old male with a medical history of hypertension and diabetes mellitus presented with fever and right lower quadrant pain from the day before. Right lower quadrant abdominal and right inguinal tenderness were observed on physical examination.

Abbreviation: SSI, surgical site infection.

* Corresponding author at: Department of Surgery, Tohoku University Graduate School of Medicine, 1-1 Seiryō-machi, Aoba-ku, Sendai, Miyagi 980-8574, Japan.

E-mail address: ryujiro.a@surg.med.tohoku.ac.jp (R. Akaishi).

<https://doi.org/10.1016/j.ijscr.2018.04.019>

2210-2612/© 2018 The Author(s). Published by Elsevier Ltd on behalf of IJS Publishing Group Ltd. This is an open access article under the CC BY-NC-ND license (<http://creativecommons.org/licenses/by-nc-nd/4.0/>).

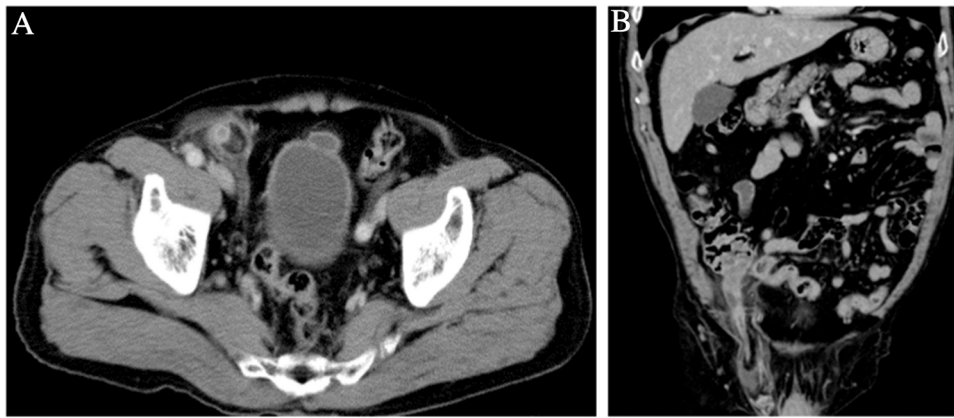


Fig. 1. Abdominal contrast-enhanced computed tomography images. Inflamed appendix incarcerated into the right inguinal canal.

The laboratory findings showed indicated inflammation, as reflected by a white blood cell count of 14,960/ μ l and a C-reactive protein level of 14.5 mg/dl. Abdominal X-ray revealed no abnormal findings. Contrast-enhanced abdominal computed tomography showed inflammation around the cecum and the appendix, and the appendix was incarcerated in the right inguinal canal (Fig. 1a, b).

After the patient was diagnosed with acute appendicitis within a right inguinal hernia, emergency laparoscopy was performed. The appendix was incarcerated in the right internal inguinal ring (Fig. 2a, b). We gently retracted the appendix from the inguinal ring. The appendix was perforated at the base with an abscess around the cecum (Fig. 2c). We decided to repair the inguinal hernia after the

appendectomy to avoid postoperative SSI. Laparoscopic appendectomy was performed, and the abdomen was irrigated with normal saline. A drain was placed at the rectovesical pouch via the stump. There were no postoperative complications, and the patient was discharged 6 days after the operation.

One month after the first operation, we selected inguinal hernioplasty to repair the right inguinal hernia considering the effects of the inflammation, such as the adhesions of the abdominal cavity. We verified that the preperitoneal space was free from adhesion and placed the direct Kugel patch without difficulty, and successfully managed the hernioplasty. No adverse events occurred postoperatively.

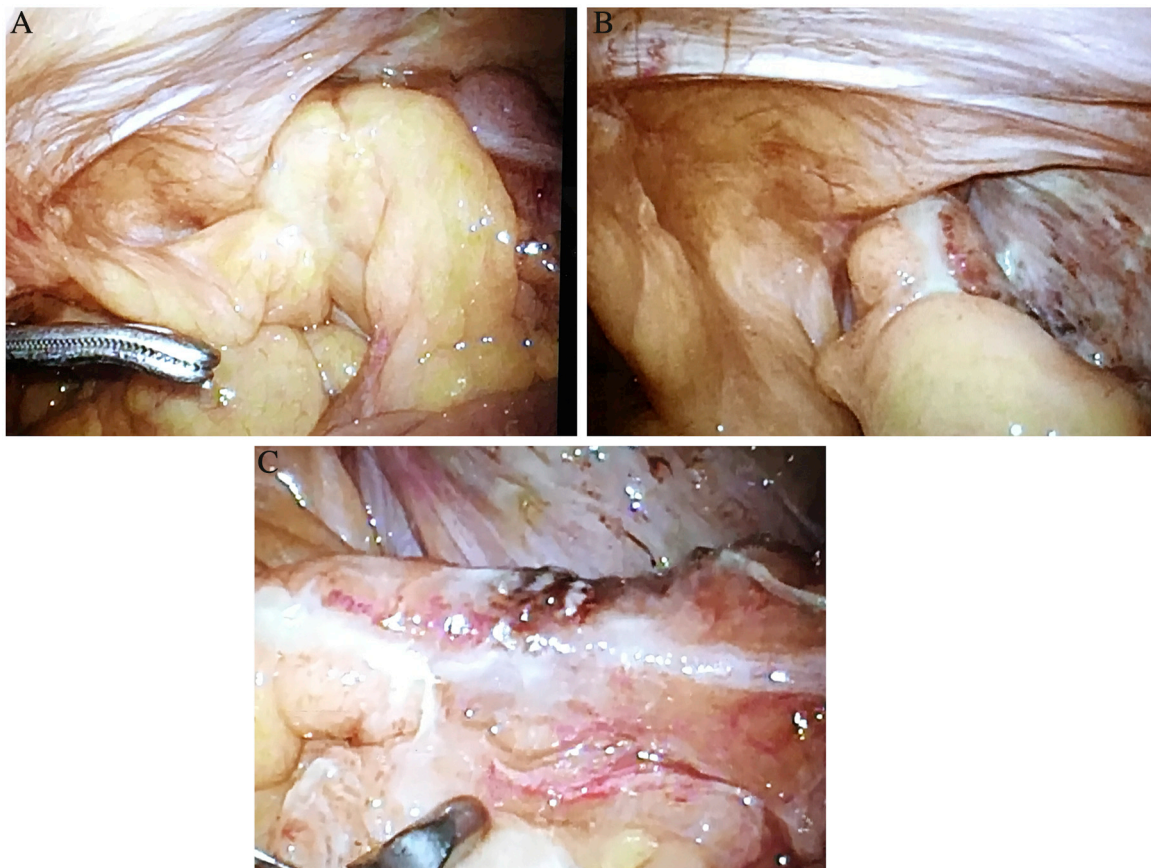


Fig. 2. Laparoscopic findings. The appendix incarcerated within the right internal inguinal ring, and perforated at the base.

3. Discussion

A laparoscopic transabdominal approach reduces the surgical manipulation needed to achieve visualization of the entire appendix and its base. This approach avoids enlarging the hernia defect and distending the neck of the hernia sac, thus reducing the possibility of hernia recurrence by weakening the anatomical structures around the defect [1,2,4]. Furthermore, the sac contents can be visually reduced [6]. Incidental appendectomy is not recommended in cases without inflammation if the appendix can be reduced easily without trauma [3,12]. However, if significant trauma occurs to the appendix while it is being reduced, appendectomy is indicated because the trauma caused to the appendix while being reduced increases the risk of appendicitis developing postoperatively [12].

However, as the laparoscopic extraperitoneal repair of an inguinal hernia does not enable visualization of the hernia sac contents, the contents cannot be visually reduced [12]. Therefore, a total laparoscopic extraperitoneal approach is not diagnostic nor appropriate for cases requiring appendectomy, such as those with appendix perforation.

Laparoscopic appendectomy followed by open hernia repair has been proposed as an alternative [6]. Wisam et al. reported a case of Amyand's hernia with appendix perforation treated by laparoscopic appendectomy [10]. However, they did not refer to the approach nor the result of the elective hernioplasty. In our case, while elective laparoscopic transabdominal repair may have been feasible, considering the adhesion of the abdominal cavity due to the inflammation of the perforated appendix, we selected the inguinal approach via the direct Kugel method using prosthetic mesh and were successful. Initiating the operation with laparoscopic transabdominal approach gives the alternative of the elective hernioplasty. Selecting the inguinal approach as the elective hernioplasty gives the advantage of performing the hernioplasty without effects of the inflammation of previous appendicitis. These two were considered as essential factors preventing postoperative SSI in our case.

4. Conclusion

A laparoscopic transabdominal approach is diagnostic and therapeutic for Amyand's hernia complicated with appendix perforation and gives the alternative of elective inguinal hernioplasty.

A two-stage surgical approach consisting of laparoscopic appendectomy followed by elective inguinal hernioplasty was used successfully to treat Amyand's hernia complicated with appendix perforation without causing postoperative SSI.

Conflicts of interest

Nothing to declare.

Funding

Nothing to declare.

Ethical approval

Ethical approval has been exempted by Iwate Prefectural Chubu Hospital.

Open Access

This article is published Open Access at [sciencedirect.com](https://www.sciencedirect.com). It is distributed under the [IJSCR Supplemental terms and conditions](#), which permits unrestricted non commercial use, distribution, and reproduction in any medium, provided the original authors and source are credited.

Consent

Informed consent was obtained from the patient for publication of this case report and any accompanying images.

Author contribution

Ryujiro Akaishi performed the surgery and perioperative patient management and drafted the manuscript. Ryuichi Nishimura supervised the writing of the manuscript. Kiminari Naoshima performed the surgery. Shukichi Miyazaki performed the surgery. All authors significantly contributed to revising the manuscript. All authors have read and approved the final manuscript.

Registration of research studies

Not applicable.

Guarantor

Dr. Shukichi Miyazaki.

Acknowledgments

We would like to thank American Journal Experts and Emily F. for the English language editing.

References

- [1] G. Ivanschuk, A. Cesmebasi, E.P. Sorenson, C. Blaak, M. Loukas, S.R. Tubbs, Amyand's hernia: a review, *Med. Sci. Monit.* 20 (January) (2014) 140–146, <http://dx.doi.org/10.12659/MSM.889873>.
- [2] H. Sharma, A. Gupta, N.S. Shekhawat, Amyand's hernia: a report of 18 consecutive patients over a 15-year period, *Hernia* 11 (2007) 31–35.
- [3] J.E. Losanoff, M.D. Basson, Amyand hernia: a classification to improve management, *Hernia* 12 (3) (2008 Jun) 325–326.
- [4] A. Michalinos, D. Moris, S. Vernadakis, Amyand's hernia: a review, *Am. J. Surg.* 207 (June (6)) (2014) 989–995, <http://dx.doi.org/10.1016/j.amjsurg.2013.07.043>.
- [5] J.E. Mullinax, A. Allins, I. Avital, Laparoscopic appendectomy for Amyand's hernia: a modern approach to a historic diagnosis, *J. Gastrointest. Surg.* 15 (2011) 533–535.
- [6] J.M. Vermillion, S.W. Abernathy, S.K. Snyder, Laparoscopic reduction of Amyand's hernia, *Hernia* 3 (1999) 159–160.
- [7] I. Inan, P.O. Myers, M.E. Hagen, Amyand's hernia: 10 years' experience, *Surgeon* 7 (2009) 198–202.
- [8] B. Elias, E. Chelala, J.L. Alle, Transabdominal laparoscopic repair of Amyand's hernia: a case report, *Case Rep. Surg.* 2011 (2011) 823936.
- [9] G. Torino, C. Campisi, A. Testa, Prosthetic repair of a perforated Amyand's hernia: hazardous or feasible, *Hernia* 11 (2007) 551–552.
- [10] W. Al-Ramlil, Y. Khodear, M. Aremu, A.B. El-Sayed, A complicated case of Amyand's hernia involving a perforated Appendix and its management using minimally invasive laparoscopic surgery: a case report, *Int. J. Surg. Case Rep.* 29 (2016) 215–218, <http://dx.doi.org/10.1016/j.ijscr.2016.11.010>.
- [11] R.A. Agha, A.J. Fowler, A. Saetta, I. Barai, S. Rajmohan, D.P. Orgill, for the SCARE Group, The SCARE Statement: consensus-based surgical case report guidelines, *Int. J. Surg.* 34 (October) (2016) 180–186 <https://doi.org/10.1016/j.ijssu.2016.08.014>.
- [12] S.K. Sarker, K. Jackson, Laparoscopic extraperitoneal repair of Amyand's inguinal hernia, *J. Soc. Laparoendosc. Surg.* 10 (4) (2006) 528–530.