



Since January 2020 Elsevier has created a COVID-19 resource centre with free information in English and Mandarin on the novel coronavirus COVID-19. The COVID-19 resource centre is hosted on Elsevier Connect, the company's public news and information website.

Elsevier hereby grants permission to make all its COVID-19-related research that is available on the COVID-19 resource centre - including this research content - immediately available in PubMed Central and other publicly funded repositories, such as the WHO COVID database with rights for unrestricted research re-use and analyses in any form or by any means with acknowledgement of the original source. These permissions are granted for free by Elsevier for as long as the COVID-19 resource centre remains active.

ENVIRONMENT, HEALTH, AND BEHAVIOR

Gastric Gross and Microscopic Lesions Caused by the UNAM-97 Variant Strain of Infectious Bronchitis Virus after the Eighth Passage in Specific Pathogen-Free Chicken Embryos

M. Escorcía,^{*,1} T. I. Fortoul,[†] V. M. Petrone,^{*} F. Galindo,^{*} C. López,^{*} and G. Téllez^{*}

**Departamento de Producción Animal: Aves, Facultad de Medicina Veterinaria y Zootecnia; and †Departamento de Biología Celular y Tisular. Facultad de Medicina, Universidad Nacional Autónoma de México, Ciudad Universitaria, Coyoacán, D. F., C. P. 04510, México*

ABSTRACT Herein we report a description of gross and microscopic lesions found in specific pathogen-free chicken embryos caused by UNAM-97 infectious bronchitis virus (IBV) variant strain after the eighth passage. Embryos were divided into three groups and were inoculated in the chorioallantoic sac with 0.2 mL of UNAM-97, Mass 41 IBV (positive control), or sterile PBS (negative control). Forty-eight hours later the allantoic fluid was taken and used to start a cycle of eight passages through 9-d-old embryos. Seven days after the last passage, embryos were harvested and macroscopic lesions in all organs were recorded. Proventriculus and gizzard samples were obtained from all embryos and routinely processed for microscopic and ultrastructural examinations. The UNAM-97 IBV variant strain caused two macroscopic

lesions uncommon for Mexican strains: thin-walled proventriculus and gizzard, as well as urate accumulation within an extra-embryonic peritoneal sac, leaving the body through the umbilical duct and accompanied by the yolk sac. At microscopic level, two relevant findings were observed to be produced by this variant. In the proventriculus, there was a decrease in the gland papillary branching, while the gizzard showed a significant reduction in mucosa thickness and tubular-to-proliferative-cell ratio, as well as an absence of hyaline secretion in the lumen. Electron-dense material scattered in proventricular and gizzard cells was observed, with a structure consistent with that of coronaviruses. These pathological chicken embryo findings have not been reported as being caused by other IBV strains in Mexico.

(*Key words:* histology, electron microscopy, infectious bronchitis virus, variant, embryo)

2002 Poultry Science 81:1647–1652

INTRODUCTION

Infectious bronchitis (IB) is caused by a RNA virus from the order *Nidovirales* (Mayo and Pringle, 1998) family *Coronaviridae* and genus *Coronavirus*. It is a highly transmissible virus. Morbidity can reach up to 100% in only 36 h. Infectious bronchitis virus (IBV) causes basically three pathologic entities. In young birds, IBV causes respiratory infection, which is often complicated with secondary bacterial infections. In adult hens, IBV causes a decrease in egg production and of internal and external egg quality. Finally, IBV causes renal damage in young and adult birds (Cavanagh and Naqi, 1997). Characteristically, frequent errors occur while the genetic information of IBV is being copied, resulting in antigenic and pathogenic variations (Steinhauer and Holland, 1986). In the face of an outbreak,

and given that various serotypes of the virus do not cross-protect, accurate serotype identification is essential to prevent further transmission (Muneer et al., 1988). For many years, poultry producers have used biosecurity and vaccination as main preventive measures. During the last decade, the presence of the disease in IB-vaccinated flocks has been reported with increasing frequency in different parts of the world (Kusters et al., 1989; Gough et al., 1992; Cook, 1996; Cargill, 1998). In Mexico, IB is one of the most common respiratory diseases. However, only the Massachusetts and Connecticut strains are officially authorized to vaccinate. Despite the use of these IBV vaccines, it is common to find IB problems in immunized chickens, causing a large economic impact. We have previously reported that IBV obtained from trachea, lung, kidney, and cecal tonsil of broiler chickens, and further characterized using the reverse transcriptase PCR and RFLP techniques, showed electrophoretic patterns different from other known IBV isolates (Escorcía et al., 2000).

©2002 Poultry Science Association, Inc.
Received for publication November 29, 2001.
Accepted for publication June 5, 2002.

¹To whom correspondence should be addressed: magdaescorcía@yahoo.com.

Abbreviation Key: IB = infectious bronchitis; IBV = infectious bronchitis virus.

This new variant was named UNAM-97, which together with strain BL-56, is now officially recognized as one of the two variant strains in Mexico (Escorcía et al., 1998; Lozano et al., 1998; Del Río et al., 1999; Escorcía, 1999; Petrone et al., 1999; Camacho et al., 2000; García et al., 2001; Gay et al., 2000). The importance of these new variant strains is that for the first time there was an outbreak that could not be controlled by immunization with the Mass and Conn strains (Escorcía et al., 2000). Herein is described macroscopic and microscopic lesions found in specific pathogen-free chicken embryos experimentally caused by UNAM-97 IBV variant strain after the eighth passage, and the presence of the virus by electronic microscopy.

MATERIALS AND METHODS

Experimental Design

Chicken Embryos. Specific pathogen-free chicken embryos ($n = 360$) (ALPES²) were used in the present study.

Viruses. An IBV variant strain known as UNAM-97 was used for the experimental group (Escorcía et al., 1998; Del Río et al., 1999; Escorcía, 1999; Petrone et al., 1999), while the Massachusetts 41 (Mass 41)³ IBV strain was used as a positive control group.

Group Design. Embryos ($n = 360$; 9-d-old) were randomly separated into three different groups of 30 embryos each (four replicates). They were inoculated by the chorioallantoic-sac route with 0.2 mL of 10^4 embryo-infective dose 50% mL UNAM-97 IBV variant (Group 1) or Mass 41 IBV strain (Group 2) (Gelb and Jackwood, 1998). Sterile PBS was inoculated to the negative control group embryos (Group 3). After 48 h of incubation at 37.5 C, the allantoic fluid was harvested and reinoculated to a new group of embryos. This procedure was repeated seven times.

Macroscopic and Microscopic Analysis

Seven days after the eighth passage, embryos were harvested and macroscopic lesions of all organs were recorded. Proventriculus/gizzard samples were obtained from all embryos. Samples were longitudinally cut at the mid-area and then immersed in 10% buffered formalin, pH 7.4. Once fixed, samples were embedded in paraffin following the conventional procedure and cut with a microtome to obtain 4- μ m sections, which were stained with hematoxylin-eosin as described by Allen (1992). The histological preparations were observed under a photon microscopy, strong dry objective lens (40 \times), and an oil immersion objective lens (100 \times). Primary, secondary, and

tertiary proventricular glands (papillae) were scored as follows: 0 = no papillae, 1 = formation of primary papillae, 2 = formation of secondary papillae, and 3 = formation of tertiary or further-branched papillae. In the gizzard, ventricular mucous membrane thickness was determined using a stage micrometer-calibrated grid installed in the photon microscope ocular, by measuring the distance between the lumen edge and the juncture site of connective tissue with mucosal proliferative epithelial cells. The ratio tubule-forming cell layer-to-proliferative cell sheet was also calculated. The presence of secretion in the gizzard lumen was also evaluated.

Ultra-Structural Study

Samples of proventriculus, gizzard, and kidney were fixed in 2.5% glutaraldehyde 0.1 M sodium cacodylate buffer, pH 7.4 (470 mosmol.L⁻¹) and cut into 3- to 5-mm pieces. Samples were then fixed with 1% osmium tetroxide for 2 h, dehydrated in an alcohol series and embedded in Araldite. Semi-thin (90 nm thick) tissue sections were stained with 1% aqueous toluidine blue solution, and observed with a light microscope. Thin (60 nm) tissue sections were contrasted with uranyl acetate and Reynold lead citrate and then observed and photographed in a transmission electronic microscope (Zeiss EM 109).⁴

Statistical Analysis

Proventricular gland papillary branching score, ventricular mucosal thickness (in μ m), and proliferative-to-tubular cell ratio were subjected to the Mann-Whitney's U test to compare between pairs of groups (Zar, 1996). The presence of secretion in gizzard lumen was evaluated by Chi square. Statistical significance was set as $P < 0.05$.

RESULTS

Macroscopic Lesions

After increasing the passage number to 8, the inoculation with the UNAM-97 variant strain provoked two gross lesions uncommon among IBV strains of Mexico. One of such lesions was the thin-walled proventriculus and the gizzard. The other was urate accumulation within an extra-embryonic peritoneal sac, close to the yolk sac, which went out from the body through the umbilical duct (Figure 1a). The inoculation with the Mass 41 strain resulted in typical lesions of IBV including runting, embryo curling, and misshaping, compression of feet over head, membrane thickening, and embryo-adhered membranes (Figure 1b). No lesions were recorded in the negative control group (Figure 1c).

Microscopic Lesions in Proventriculus and Gizzard

Neither positive nor negative control groups had lesions in the proventriculus or gizzard. In contrast, the

²Aves Libres de Patógenos Específicos, S. A. 7 Norte No. 416. Tehuacán, Pue., México, CP 75700.

³IASA. 7 Norte No. 602. Tehuacán, Pue., México, CP 75700.

⁴SPI and Sigma Chemical Co., St. Louis, MO.

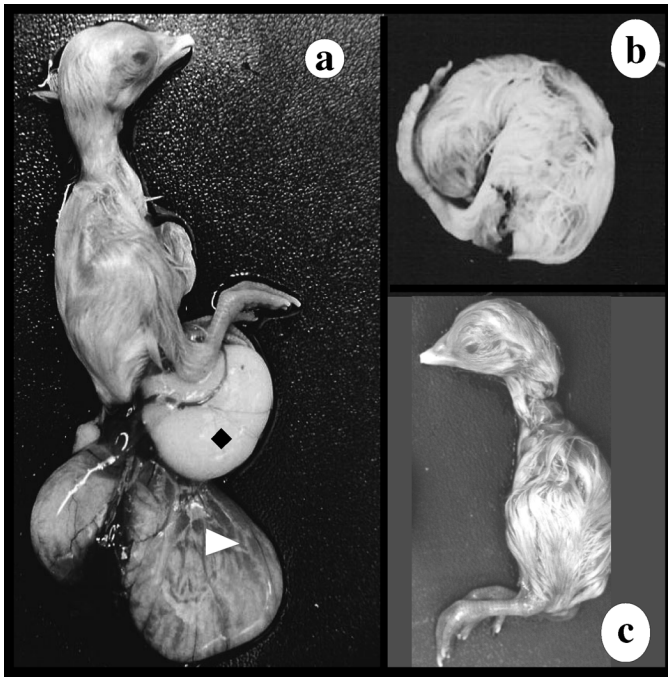


FIGURE 1. Chicken embryos (16-d-old) inoculated with: (a) UNAM-97 infectious bronchitis virus (IBV) variant strain; (b) Mass 41 strain of IBV; and (c) inoculated with sterile PBS. The chicken embryo inoculated with UNAM-97 IBV variant strain (a) had urate accumulation within an extra-embryonic peritoneal sac (◆) leaving the body through the umbilical duct, accompanied by the yolk sac (△).

group inoculated with the UNAM-97 variant strain of IBV had two relevant histological findings in the proventriculus and gizzard. In the proventriculus, a decrease in the gland papillary branching was observed as compared with both control groups, and the modal score of gland papillary branching was significantly lower (Figure 2;

Table 1). In the gizzard, a significant reduction in mean mucous thickness, an absence of secretion of gizzard lumen and a reduction in the tubular-to-proliferative cell ratio were observed as compared to both control groups (Figure 3; Table 1).

Ultrastructural Study

Virus particles, consistent with an IBV infection, were observed in the proventriculus and the gizzard of the embryos inoculated with the UNAM-97 strain (Figures 4 and 5).

DISCUSSION

In the present study we report macroscopic and microscopic lesions caused by the UNAM-97 variant strain to the digestive tract of chicken embryos after eight passages. The most evident lesions were present in the proventriculus and the gizzard. Urate accumulation within an extra-embryonic peritoneal sac leaving the body through the umbilical duct, close to the yolk sac is another interesting finding. These pathological findings have not been reported to be caused by other IBV strains from Mexico. Electron microscopy showed only viral particles with morphology consistent with coronaviruses. The molecular reverse-transcriptase-PCR-RFLP pattern of the S1 protein gene was unique for the UNAM-97 IBV variant strain, which differed greatly from those of other strains prevalent in Mexico (Escorcia et al., 2000). This new variant strain was isolated from 5- to 7-wk-old broilers previously vaccinated with Massachusetts and Connecticut IBV strains. Birds were from two commercial farms located in the State of Guanajuato, and two more in the State of Queretaro (Escorcia, 1999). Even though there is

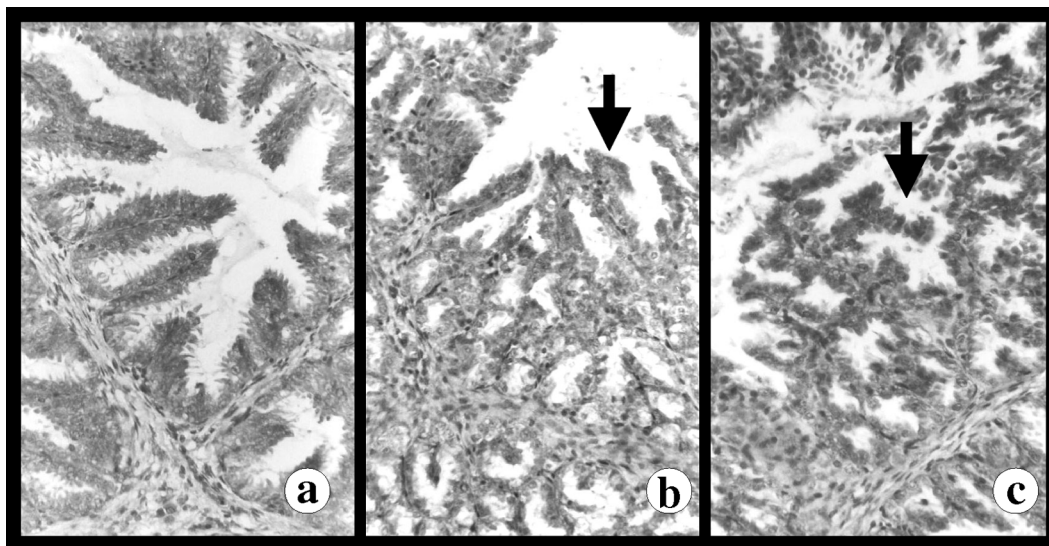


FIGURE 2. Photomicrographs of proventricular gland papillae from chicken embryo inoculated with UNAM-97 infectious bronchitis virus (IBV) variant strain (a), chicken embryo inoculated with Mass 41 strain of IBV (b), and no inoculated chicken embryo (c). Proventricular gland from chicken embryo inoculated with Mass 41 strain of IBV and no inoculated chicken embryo had primary, secondary, and tertiary papilla branches (indicated by arrows). Proventricular gland from chicken embryo inoculated with UNAM-97 IBV variant strain had primary papilla branches, only. Hematoxylin and eosin (100×).

TABLE 1. Microscopic findings in specific pathogen-free chicken embryos inoculated with UNAM-97 variant strain of infectious bronchitis virus (IBV)

Histology findings	Group 1 ¹	Group 2	Group 3
Modal score of gland papillary branching ²	2 ^a	1 ^b	2 ^a
Mean mucosal membrane thickness (μm) ³	146.8 ^a	94.9 ^b	135.7 ^a
Tubule-forming cell layer-to-proliferative cell layer ratio ⁴	2:3 ^a	1.5:3 ^b	1.9:3 ^a
Presence of secretion in gizzard lumen ⁵	360/360 (100%) ^a	0/360 (0%) ^b	360/360(100%) ^a

^{a,b}Values with different superscripts are significantly different ($P < 0.05$).

¹Embryos ($n = 360$; 9-d-old) were randomly separated into three different groups of 30 embryos each (four replicates). They were inoculated by the chorioallantoic-sac rout with 0.2 mL of 10^4 embryo-infective dose of 50% (EID_{50})mL UNAM-97 IBV variant (Group 1) or Mass 41 strain (Group 2). Sterile PBS was inoculated to the negative control group embryos (Group 3).

²Primary, secondary, and tertiary proventricular glands (papillae) were scored as follows: 0 = no papillae, 1 = formation of primary papillae, 2 = formation of secondary papillae, and 3 = formation of tertiary or further-branched papillae.

³The ventricular mucous membrane thickness of the gizzard was determined using a stage micrometer-calibrated grid in the photon microscope ocular. Mucous membrane thickness was measured from lumen edge to juncture site of connective tissue with mucosal proliferative epithelial cells.

⁴The tubule-forming cell layer-to-proliferative cell layer ratio was calculated.

⁵Number of gizzards with the presence of secretion in its lumen/total of embryos (%).

not enough information about the way these isolations emerged in Mexico, some investigators support the importance of the introduction of vaccines produced with strains from other countries (Kusters et al., 1989). Similarly, although the use of attenuated vaccines reduces economic losses caused by IBV infection, it can also be responsible for the emergence of antigenic variants due to a recombination among vaccine and field strains (Muneeer et al., 1988; Kusters et al., 1989; Keeler et al., 1998). It would be important to perform an epidemiological study in order to know the prevalence of these strains in the Mexican Republic. Having no data regarding this, it is necessary to reinforce biosecurity measures that will allow the poultry system to restrict the shedding of this virus, and to determine whether the manufacturing of a specific vaccine against this new strain is justified. New-generation vaccine technology offers the possibility of

using only some viral fractions instead of using the complete virus. This technology would offer the advantage of limiting virus recombination (Song et al., 1998).

At present, a pathological condition affects the broilers flock in Mexico, which has been called rapid transit syndrome or bad digestion syndrome, that causes large economic losses (Casaubon et al., 1997). In other countries similar situations have occurred that are related to different viral etiologies (Page et al., 1982; Goodwin et al., 1996). From the results of the present and the previous works (Escorcía et al., 2000), it becomes important to determine the role of the UNAM-97 strain in such outbreaks.

ACKNOWLEDGMENTS

The authors thank Francisco Pasos and Adrián Rondán from the Departamento de Biología Celular and Tisular, Facultad de Medicina, UNAM, for their technical support.

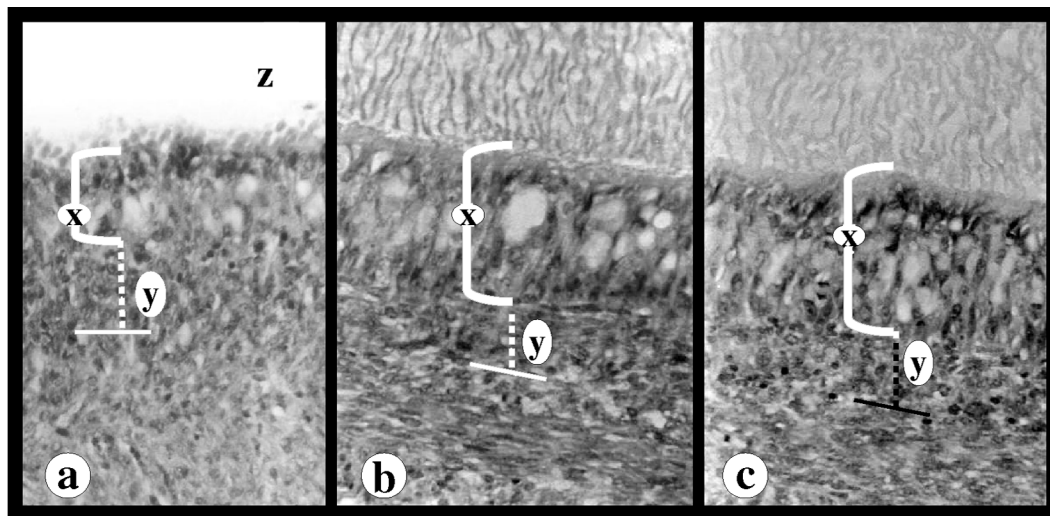


FIGURE 3. Photomicrographs of ventricular mucous membrane from chicken embryo inoculated with UNAM-97 infectious bronchitis virus (IBV) variant strain (a), chicken embryo inoculated with Mass 41 strain of IBV (b), and no inoculated chicken embryo (c). Ventricular mucous membrane from chicken embryo inoculated with UNAM-97 IBV variant strain had reduction in tubular (x)-to-proliferative (y) layers ratio, and absence of secretion in gizzard lumen (z). Hematoxylin and eosin (200 \times).

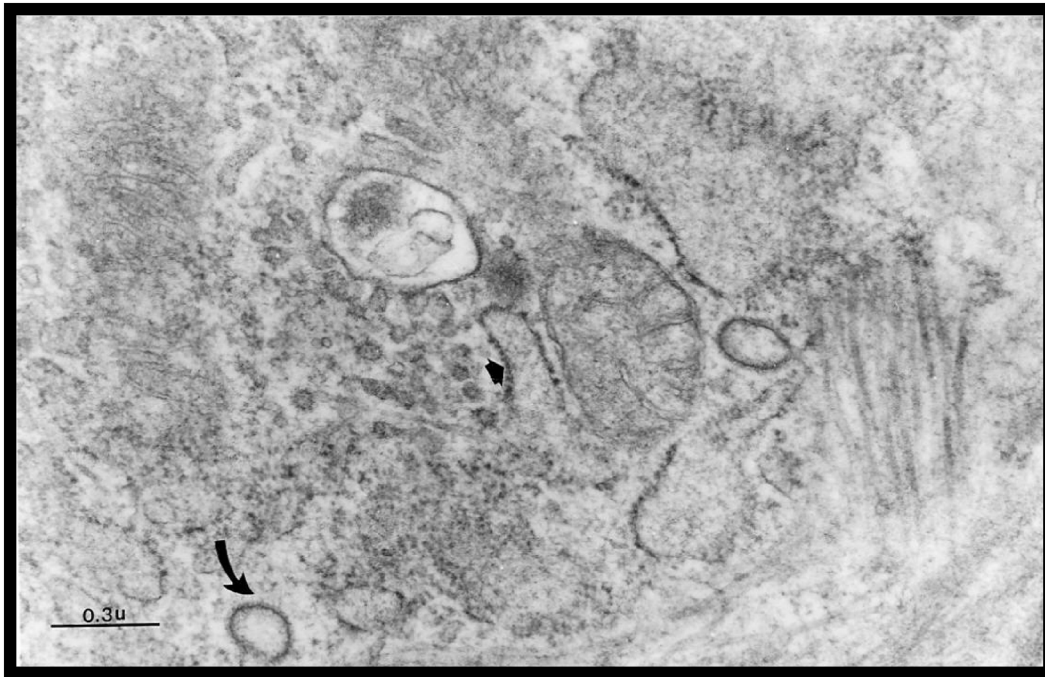


FIGURE 4. Transmission electron micrograph of proventricular cells from embryos inoculated with the UNAM-97 variant strain of infectious bronchitis virus. Note electron-dense material scattered in proventricular cells (arrow).

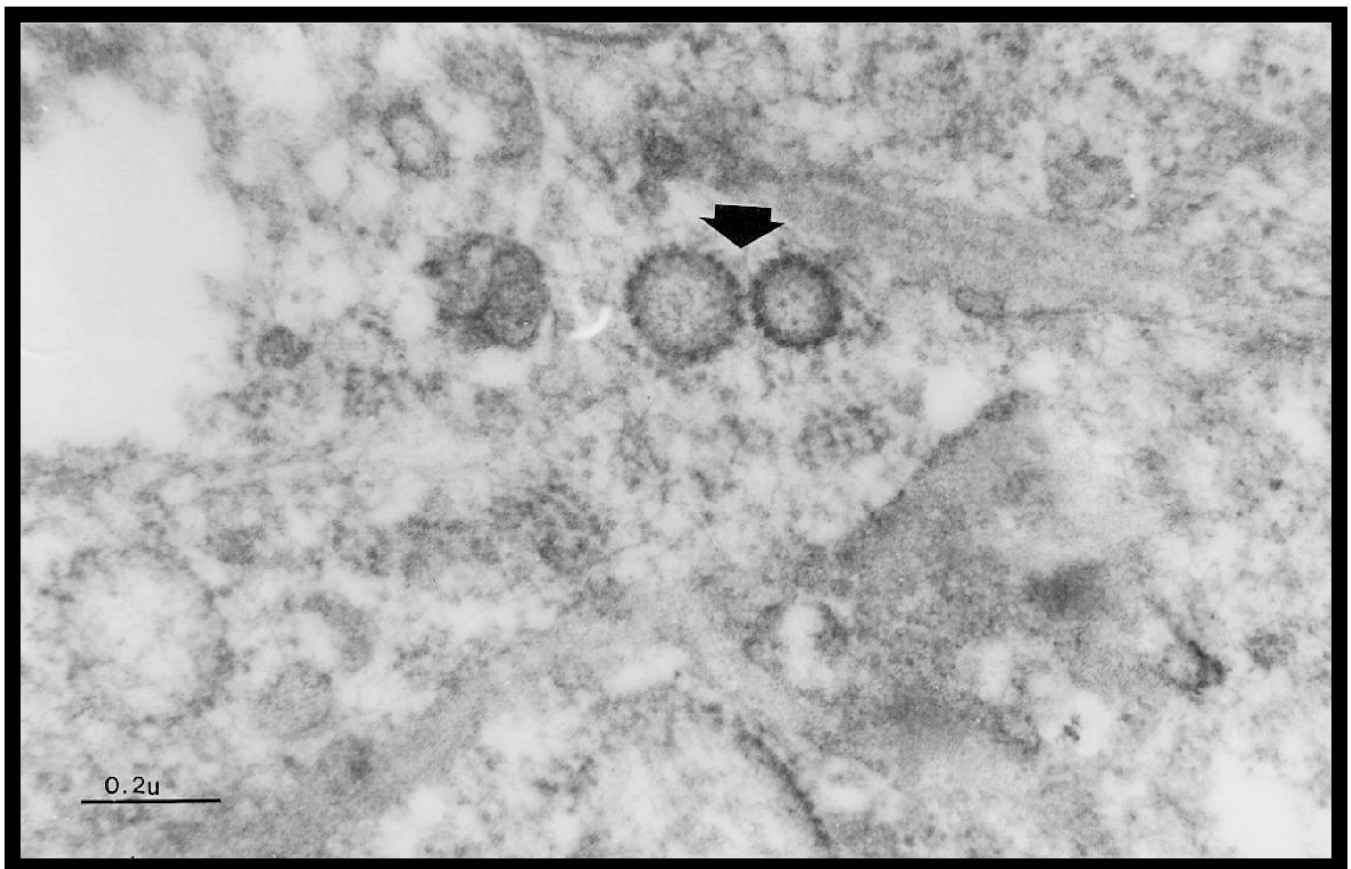


FIGURE 5. Transmission electron micrograph of ventricular cell from embryos inoculated with the UNAM-97 variant strain of infectious bronchitis virus. Note several particles with morphology consistent with that of coronaviruses (arrow).

REFERENCES

- Allen, T. C. 1992. Hematoxylin and eosin. Pages 53–58 in *Laboratory Methods in Histotechnology*, 3rd ed., E. B. Prophet, B. Mills, J. B. Arrington, and L. H. Sobin, eds., Armed Forces Institute of Pathology, Washington, DC.
- Camacho, E., E. Soto, B. Lozano, D. Sarfati, M. Gay, M. A. Murillo, J. L. Borrego, M. M. Gómez, and J. J. Murillo. 2000. Los complejos respiratorio-septicémicos de las aves en México. Proceedings of the XII Curso de Actualización Avimex. Asumiendo el Reto en la Prevención y Control de los Complejos Respiratorios de las Aves en el Nuevo Milenio. CD-ROM, Laboratorios Avimex S.A. de C.V., Mexico City.
- Cargill, P. 1998. Contemporary European infectious bronchitis variants. *World's Poult. Sci. J.* 14:52–53.
- Casaubon, M. T., N. Ledesma, V. Petrone, T. Fehervari, and J. C. Del Río. 1997. Case report of avian indigestion and diuresis syndrome in stunted mexican broiler chickens. Pages 18–22 in XI International Congress of the World Veterinary Poultry Association, Budapest.
- Cavanagh, D., and S. A. Naqi. 1997. Infectious bronchitis. Pages 511–526 in *Diseases of Poultry*, 10th ed., B. W. Calnek, H. J. Barnes, C. W. Beard, L. R. McDougald, and Y. M. Saif, eds., Iowa State University Press, Ames, IA.
- Cook, J. 1996. Novel infectious bronchitis virus causes higher mortality. *World's Poult. Sci. J.* 12:78–79.
- Del Río, J. C., V. M. Petrone, M. Escorcía, and G. Téllez. 1999. Hallazgos histológicos entéricos en pollo de engorda inoculado con la cepa UNAM-97 de bronquitis infecciosa aviar. Pages 18–19 in Proceedings of the VII Congreso de la Sociedad Mexicana de Patólogos Veterinarios. Sociedad Mexicana de Patólogos Veterinarios, Mexico City.
- Escorcía, M. 1999. Caracterización molecular de virus de bronquitis infecciosa aviar de aislamientos en México. M.Sc. Thesis. Facultad de Medicina Veterinaria y Zootecnia, Universidad Nacional Autónoma de México, Mexico City.
- Escorcía, M., M. Jackwood, B. Lucio, V. M. Petrone, C. López, T. Fehervari, and G. Téllez. 2000. Characterization of Mexican strains of avian infectious bronchitis isolated during 1997. *Avian Dis.* 44:944–947.
- Escorcía, M., V. M. Petrone, C. López, B. Lucio, and T. Fehervari. 1998. Aislamiento y caracterización de variantes del virus de bronquitis infecciosa aviar de aves vacunadas en México. Pages 60–63 in Proceedings of the III Congreso Nacional de Vacunología. El Colegio Nacional, Mexico City.
- García, G. J., M. Gay, J. Escamilla, E. Soto, D. Sarfati, and B. Lozano. 2001. ¿Qué está pasando con la bronquitis infecciosa aviar en México? Pages 45–52 in Proceedings of the XIII Curso Avimex. Respuestas a las patologías críticas en la avicultura moderna. Laboratorios Avimex S.A. de C.V., Mexico City.
- Gay, M., A. Suárez, B. Lozano, E. Soto, D. Sarfati, J. Escamilla, C. Alvarado, and A. Morales. 2000. Avances en la prevención de bronquitis infecciosa en México. Proceedings of the XII Curso de Actualización Avimex. Asumiendo el Reto en la Prevención y Control de los Complejos Respiratorios de las Aves en el Nuevo Milenio. CD-ROM. Laboratorios Avimex S.A. de C.V., Mexico City.
- Gelb, J., and M. W. Jackwood. 1998. Infectious Bronchitis. Pages 169–174 in *A Laboratory Manual for the Isolation and Identification of Avian Pathogens*, 4th ed., D. E. Swayne, J. R. Glisson, M. W. Jackwood, J. E. Pearson, and W. M. Read, eds. American Association of Avian Pathologists, Kennett Square, PA.
- Goodwin, M. A., S. Hafner, D. I. Bounous, K. S. Latimer, E. C. Player, F. D. Niagro, R. P. Campagnoli, and J. Brow. 1996. Viral proventriculitis in chickens. *Avian Dis.* 25:369–379.
- Gough, R. E., C. J. Randall, M. Dagless, D. J. Alexander, W. J. Cox, and D. Pearson. 1992. A new strain of infectious bronchitis virus infecting domestic fowl in Great Britain. *Vet. Rec.* 130:493–494.
- Keeler, D. L., K. L. Reed, W. A. Nix, and J. Gelb. 1998. Serotype identification of avian infectious bronchitis virus by RT-PCR of the peplomer (S1) gene. *Avian Dis.* 42:275–284.
- Kusters, J. G., G. M. Niesters, J. A. Lenstra, M. C. Horzinedk, and B. A. M. Van Der Zeust. 1989. Phylogeny of antigenic variants of avian coronavirus IBV. *Virology* 169:217–221.
- Lozano, B., M. Gay, D. Sarfati, E. Soto, A. Suárez, M. Aranda, J. Escamilla, M. Hernández, and J. García. 1998. Aislamiento e identificación de una posible variante o nuevo serotipo del virus de la bronquitis infecciosa en México. Pages 80–91 in Proceedings of the X Curso de Actualización Avimex. Salud y Productividad Aviar. Laboratorios Avimex S.A. de C.V., Mexico City.
- Mayo, M. A., and D. R. Pringle. 1998. Virus taxonomy-1997. *J. Gen. Virol.* 79:649–657.
- Muneer, M. A., J. A. Newman, D. A. Halvorson, V. Sivanandan, and K. V. Nagaraja. 1988. Efficacy of infectious bronchitis virus vaccines against heterologous challenge. *Res. Vet. Sci.* 45:22–27.
- Page, R. K., O. J. Fletcher, G. N. Rowland, D. Gaudry, and P. Villegas. 1982. Malabsorption syndrome in broiler chickens. *Avian Dis.* 26:618–624.
- Petrone, V. M., M. Escorcía, and G. Téllez. 1999. Hallazgos anatómopatológicos de embriones de pollo inoculados con cepa variante de bronquitis infecciosa aviar. Pages 46–47 in Proceedings of the VII Congreso de la Sociedad Mexicana de Patólogos Veterinarios. Sociedad Mexicana de Patólogos Veterinarios, Mexico City.
- Song, Ch., Y. Lee, Ch. Lee, H. Sung, J. Kim, I. Mo, Y. Izumiya, H. Jang, and T. Mikami. 1998. Induction of protective immunity in chickens vaccinated with infectious bronchitis virus S1 glycoprotein expressed by a recombinant baculovirus. *J. Gen. Virol.* 79:719–723.
- Steinhauer, D. A., and J. J. Holland. 1986. Direct method for quantitation of extreme polymerase error frequencies at selected single base sites in viral ARN. *J. Virol.* 192:710–716.
- Zar, J. 1996. Circular distributions: hypothesis testing. Pages 615–662 in *Biostatistical Analysis*, 3rd ed., J. Zar, ed. Prentice-Hall, Upper Saddle River, NJ.