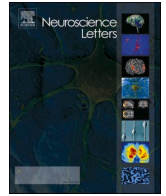




Since January 2020 Elsevier has created a COVID-19 resource centre with free information in English and Mandarin on the novel coronavirus COVID-19. The COVID-19 resource centre is hosted on Elsevier Connect, the company's public news and information website.

Elsevier hereby grants permission to make all its COVID-19-related research that is available on the COVID-19 resource centre - including this research content - immediately available in PubMed Central and other publicly funded repositories, such as the WHO COVID database with rights for unrestricted research re-use and analyses in any form or by any means with acknowledgement of the original source. These permissions are granted for free by Elsevier for as long as the COVID-19 resource centre remains active.



Neuroimaging findings in COVID-19: A narrative review

Sanaz Katal^a, Ali Gholamrezanezhad^{b,c,*}

^a Nuclear Medicine Department, Tehran University of Medical Sciences, Iran

^b Keck School of Medicine, University of Southern California (USC), Los Angeles, CA, USA

^c Department of Diagnostic Radiology, Keck School of Medicine, University of Southern California (USC), 1520 San Pablo Street, Los Angeles, CA, USA

ARTICLE INFO

Keywords:

COVID-19
SARS-CoV-2
Brain
CNS
Neurologic sequelae
MRI
Neuroimaging
Stroke
Meningitis
Encephalitis
Acute disseminated encephalomyelitis
Encephalopathy

ABSTRACT

In this mini-review, we aim to summarize some of the most common neuroimaging findings seen in patients with COVID-19.

1. Introduction

Since the appearance of the coronavirus disease 2019 (COVID-19) outbreak in late December in Wuhan (China), there has been an increasing number of publications regarding the potential neurotropism of severe acute respiratory syndrome coronavirus 2 (SARS-CoV-2). While COVID-19 primarily affects the respiratory targets [1–3], neurological alteration and damage are not uncommon. Early studies from China have reported various neurological symptoms (including anosmia, headache, myalgia) and Central Nervous system (CNS) complications (cerebrovascular events, encephalopathy, and neuro-inflammatory syndromes) in a large number of COVID-19 patients [4].

SARS-CoV-2 is similar in structure and pathogenesis to the other β -coronavirus family members, namely Severe Acute Respiratory Syndrome (SARS-CoV) and the Middle East Respiratory Syndrome (MERS). Similarity in structure and pathogenesis predicts similarity in clinical presentation and symptomatology. Prior experimental researches have established the neurotropism and neuroinvasiveness of coronavirus strains in previous SARS and MERS epidemics, even in the absence of pulmonary manifestations. SARS-CoV-2 has been suggested to have similar, but higher affinity for CNS targets [5].

Although it remains unsolved how coronavirus affects the human

neuronal system, two main pathophysiological hypotheses seem to point the most likely explanations. One suggested mechanism is based on the direct viral invasion through hematological, transcribrial, and neuronal retrograde dissemination pathways. The other possible mechanism is via hyperimmune-related reactions. Activation of inflammatory cells and cytokines precede cytokine storms, resulting in the activation of coagulation cascades, disseminated intravascular coagulation (DIC), and multiple end-organ failures, including CNS complications.

In this mini-review, we aim to summarize some of the most common imaging findings seen in patients with COVID-19. However, it is important to bear in mind that the exact relationship with SARS-CoV-2 has not yet been fully established. Indeed, while COVID-19 associated neurological features offer a possible causal or synergetic relationship between cerebral events and SARS-CoV-2 infection, coincidental events (rather than casual association) might explain some of these imaging results. In fact, due to high prevalence of the COVID-19 in communities, co-incidence of the infection with other diseases is an expected and highly likely phenomenon.

2. Radiologic findings

In our prior review on 20 studies consisting of 90 patients with

* Corresponding author.

E-mail addresses: Sanaz.Katal@gmail.com (S. Katal), ali.gholamrezanezhad@med.usc.edu (A. Gholamrezanezhad).

<https://doi.org/10.1016/j.neulet.2020.135529>

Received 6 October 2020; Received in revised form 17 November 2020; Accepted 20 November 2020

Available online 25 November 2020

0304-3940/© 2020 Elsevier B.V. All rights reserved.

neuro-COVID-19 symptoms (among 116 patients with coronavirus family infection) [6], 37 (41 %) patients had normal imaging studies (brain CT or MRI). Amongst those who displayed abnormal neuroimaging findings (59 %), vascular thrombosis, cortical signal abnormalities, hemorrhage, hemorrhagic posterior reversible encephalopathy syndrome (PRES), acute hemorrhagic necrotizing encephalopathy (ANE), meningitis/encephalitis, and acute disseminated encephalomyelitis (ADEM) were the most common reported abnormalities [6].

Similarly, in a recent observational study [7] on 73 patients who presented with neurological symptoms, 41.1 % demonstrated normal brain MRI. The remainder 58.9 % had various neuroimaging abnormalities, including acute ischemic infarcts (23.3 %), cerebral venous thrombosis (1.4 %), multiple microhemorrhages (11.3 %), perfusion abnormalities (47.7 %), multifocal white matter lesions (5.5 %), basal ganglia lesions (5.5 %), meningeal enhancement (4.8 %), central pontine myelinolysis (4.1 %), hypoxia-induced lesions (4.1 %), restricted diffusion foci within the corpus callosum consistent with cytotoxic lesions of the corpus callosum (CLOCC, 4.1 %), PRES (2.7 %), and neuritis (2.7 %). The authors have also found that two imaging patterns of multifocal white matter lesions and basal ganglia abnormalities (observed primarily in ICU patients with a more severe illness) were related more explicitly to SARS-CoV-2 infection itself rather than the disease complications.

In another multicenter observational study by Kermer et al. on 37 patients [8], the most frequent white matter abnormalities were described in three distinct patterns: signal abnormalities in the medial temporal lobe (43 %), non-confluent multifocal white matter hyperintense lesions on FLAIR and diffusion associated with hemorrhages (30 %), and white matter microhemorrhages (24 %). They stated medial temporal lobe signal abnormalities were similar to those found in viral or autoimmune encephalitis, whereby patterns 2 and 3 presented microhemorrhages. They also found that the presence of hemorrhage would worsen the prognosis in these patients.

3. Cerebrovascular events

Numerous publications have already ascertained the thrombo-inflammatory nature of SARS-Cov-2 infection [9,10]. The elevated production of coagulopathy factors such as fibrinogen, platelet, D-dimer, and inflammatory cytokines (interleukin-6), along with capillary endothelial damage, predispose patients to thromboembolic events, leading to stroke, thrombosis, and hemorrhage. Therefore, it is not surprising that stroke-related imaging findings are among the most frequent abnormalities seen in patients with neuro-COVID symptoms. Findings such as territorial acute/subacute infarction, multiple ischemic foci, evidence of thrombus in large intra and extra-cranial vessels, cerebral venous thrombus complicated by hemorrhagic infarcts, and cortical/subcortical microhemorrhages have been reported frequently in various observational studies [6,11].

The precise pathophysiology of white matter microhemorrhages in COVID-19 patients remains unclear. It has been suggested that they might be related to diffuse endothelial dysfunction, secondary to the direct viral invasion of the endothelial cells (via ACE-2 receptors) and the subsequent endothelial inflammation.

4. Guillain-Barre syndrome (GBS)

GBS has been reported as a significant parainfectious peripheral neurological sequelae of SARS-CoV-2 infection, similar to other coronavirus strains. These patients generally have normal MRI studies of the central nervous system, although post-contrast enhancement in the cervical and lumbar nerve roots has been reported frequently [7]. COVID-19 associated GBS mainly develops within a few days to weeks of established viral infection. This temporal relationship reflects a post-infective immune-mediated process as the primarily responsible mechanism. In a review by Caress et al. [12] on 37 cases of GBS

associated with COVID-19, the mean time interval between COVID-19 symptoms and GBS onset was 11 days. Brain imaging had been performed in fewer than half of patients (14/37), which displayed cranial nerve abnormalities only in 28 % of them. Furthermore, spine imaging was obtained in 15 cases, with 40 % showing abnormal features, including root enhancement, radiculitis, leptomeningeal enhancement, and myelopathy.

5. Perfusion abnormalities

MRI perfusion abnormalities are observed in a large number of individuals presenting with COVID-19 associated neurologic signs. These abnormalities might be related to hypoxic-ischemic events and seizures, or present as an isolated finding [7]. In Helms et al. study, bilateral frontotemporal hypoperfusion, leptomeningeal enhancement, and stroke-related abnormalities were the most conspicuous neuroimaging findings in COVID-19 patients presenting with a severe illness [13].

6. Acute inflammatory/infectious CNS syndromes

A range of COVID-19 associated inflammatory features is identified on radiological exams, including post-infectious ADEM, acute hemorrhagic leukoencephalitis, myelitis, and autoimmune encephalitis. As mentioned earlier, virus-induced vasculopathy and coagulopathy, direct invasion of CNS, hyperinflammatory reactions and post-infective auto-antibodies might partly explain these findings. In terms of radiologic findings, unilateral FLAIR hyperintensity and/or diffusion restriction in the medial temporal lobe have been frequently reported in these patients, similar to changes with autoimmune limbic encephalitis [11]. Similar imaging results have been featured in the concept of meningitis/encephalitis in a few case series [6,14].

PRES, multifocal white matter abnormalities, basal ganglia lesions, and leptomeningeal enhancement have also been named as relevant neuroimaging manifestations in COVID-19 [11,15]. Again the vasculitis-like phenomenon and inflammatory cascades, secondary to COVID-19-induced CNS damages, are the likely responsible mechanism for these findings [16].

7. COVID-19 in brain PET

Nuclear medicine operations are not routinely employed in COVID-19 patients [17]. However, it is assumed that molecular imaging with FDG PET-CT is potentially able to add valuable data regarding the pathophysiological basis of the disease [18,19]. In this era, a few reports have described metabolic abnormalities in patients presenting with neuro-COVID-19 manifestations. In a case series by Delorme et al. [20] brain FDG PET-CT was performed in four COVID-19 patients with possible immune encephalitis. PET displayed a consistent pattern of metabolic abnormalities in all patients: hypometabolism in the prefrontal or orbito-frontal cortices and hypermetabolism in the cerebellar vermis. None of these patients had specific MRI features nor significant cerebrospinal fluid (CSF) abnormalities. Regarding the PET-CT findings and the negative CSF SARS-CoV-2 PCR results, the authors suggested a parainfectious cytokine storm or immune-mediated process rather than a direct neuroinvasion mechanism.

Other case reports have issued similar findings. Grimaldi et al. [21], demonstrated diffuse cortical hypometabolism, associated with putaminal and cerebellum hypermetabolism in autoimmune encephalitis concomitant with SARS-CoV-2 infection. In another case study, anosmia of COVID-19 was evaluated using FDG PET-CT. They found hypometabolism of the left orbitofrontal cortex in a COVID-19 patient, representing with persistent isolated anosmia [22]. These findings, along with normal morphological data on MRI, might suggest reduced neuronal activity and functional alterations in neuro-COVID-19 patients. However, further studies (specifically using BOLD functional MRI) are still needed in this regard before we draw a definite conclusion.

8. Summary

Brain imaging should be considered in the diagnostic work up of those COVID-19 patients who present with neurological symptoms. In this regard, radiologists and clinicians should be familiar with the spectrum of neuroimaging findings in COVID-19 to detect and understand the disease process, and to evaluate its progression during the course of treatment. Yet, further studies are still warranted regarding the long-term neurological sequel and prognostic implications in COVID-19.

References

- [1] S. Katal, S.K. Johnston, J.H. Johnston, A. Gholamrezaezhad, Imaging findings of SARS-CoV-2 infection in pediatrics: a systematic review of coronavirus disease 2019 (COVID-19) in 850 patients, *Acad. Radiol.* (July (30)) (2020). S1076-6332 (20)30454-2.
- [2] S. Salehi, A. Abedi, A.R. Radmard, M. Sorouri, A. Gholamrezaezhad, Chest computed tomography manifestation of coronavirus disease 2019 (COVID-19) in patients with cardiothoracic conditions, *J. Thorac. Imaging* 35 (July (4)) (2020) W90–W96.
- [3] M. Hosseiny, S. Kooraki, A. Gholamrezaezhad, S. Reddy, L. Myers, Radiology perspective of coronavirus disease 2019 (COVID-19): lessons from severe acute respiratory syndrome and middle east respiratory syndrome, *Am. J. Roentgenol.* 214 (May (5)) (2020) 1078–1082.
- [4] L. Mao, H. Jin, M. Wang, et al., Neurologic manifestations of hospitalized patients with coronavirus disease 2019 in Wuhan, China, *JAMA Neurol.* 77 (6) (2020) 683–690.
- [5] V. Montalvan, J. Lee, T. Bueso, J. De Toledo, K. Rivas, Neurological manifestations of COVID-19 and other coronavirus infections: a systematic review, *Clin. Neurol. Neurosurg.* 194 (July (1)) (2020), 105921.
- [6] S. Katal, S. Balakrishnan, A. Gholamrezaezhad, Neuroimaging and neurologic findings in COVID-19 and other coronavirus infections: a systematic review in 116 patients, *J. Neuroradiol.* (June (27)) (2020). S0150-9861(20)30204-2.
- [7] L. Chougar, N. Shor, N. Weiss, CoCo Neurosciences study group, et al., Retrospective observational study of brain magnetic resonance imaging findings in patients with acute SARS-CoV-2 infection and neurological manifestations, *Radiology* (July (17)) (2020), 202422.
- [8] S. Kremer, F. Lersy, J. de Sèze, et al., Brain MRI findings in severe COVID-19: a retrospective observational study, *Radiology* (June (16)) (2020), 202222.
- [9] J.M. Connors, J.H. Levy, Thromboinflammation and the hypercoagulability of COVID-19, *J. Thromb. Haemost.* 18 (July (7)) (2020) 1559–1561.
- [10] S. Salehi, A. Abedi, A. Gholamrezaezhad, Reply to “vascular changes detected with thoracic CT in coronavirus disease (COVID-19) might be significant determinants for accurate diagnosis and optimal patient management”, *Am. J. Roentgenol.* (April (24)) (2020).
- [11] R.W. Paterson, R.L. Brown, L. Benjamin, UCL Queen Square National Hospital for Neurology and Neurosurgery COVID-19 Study Group, et al., The emerging spectrum of COVID-19 neurology: clinical, radiological and laboratory findings, *Brain* (July (8)) (2020) awaa240.
- [12] J.B. Caress, R.J. Castoro, Z. Simmons, S.N. Scelsa, R.A. Lewis, A. Ahlawat, P. Narayanaswami, COVID-19-associated Guillain-Barré syndrome: the early pandemic experience, *Muscle Nerve* 62 (October (4)) (2020) 485–491.
- [13] J. Helms, S. Kremer, H. Merdji, et al., Neurologic features in severe SARS-CoV-2 infection, *N. Engl. J. Med.* (April (15)) (2020).
- [14] T. Moriguchi, N. Harii, J. Goto, et al., A first case of meningitis/encephalitis associated with SARS-Coronavirus-2, *Int. J. Infect. Dis.* (April (3)) (2020).
- [15] S.G. Kandemirli, L. Dogan, Z.T. Sarikaya, et al., Brain MRI findings in patients in the intensive care unit with COVID-19 infection, *Radiology* (May (8)) (2020), 201697.
- [16] S. Behzad, L. Aghaghazvini, A.R. Radmard, A. Gholamrezaezhad, Extrapulmonary manifestations of COVID-19: radiologic and clinical overview, *Clin. Imaging* 66 (October) (2020) 35–41.
- [17] S. Katal, S. Azam, E. Bombardieri, M. Picchio, A. Gholamrezaezhad, Reopening the Country: Recommendations for Nuclear Medicine Departments, 2020.
- [18] S. Katal, H. Amini, A. Gholamrezaezhad, PET in the Diagnostic Management of infectious/inflammatory Pulmonary Pathologies: A Revisit in the Era of COVID-19, 2020.
- [19] A. Gholamrezaezhad, L. Mehta, 18F-FDG PET/CT helps in unmasking the great mimicker: a case of neurosarcoidosis with isolated involvement of the spinal cord, *Revista Española de Medicina Nuclear e Imagen Molecular (English Edition)* 37 (May (3)) (2018) 172–174.
- [20] C. Delorme, O. Paccoud, A. Kas, A. Hesters, S. Bombois, P. Shambrook, A. Bouillet, D. Doukhi, L. Le Guennec, N. Godefroy, R. Maatoug, COVID-19-related encephalopathy: a case series with brain FDG-positron-emission tomography/computed tomography findings, *Eur. J. Neurol.* (January (1)) (2020).
- [21] S. Grimaldi, S. Lagarde, J.R. Harle, J. Boucraut, E. Guedj, Autoimmune encephalitis concomitant with SARS-CoV-2 infection: insight from 18F-FDG PET imaging and neuronal autoantibodies, *J. Nucl. Med.* (July (24)) (2020) jnumed-120.
- [22] M. Karimi-Galougahi, A. Yousefi-Koma, M. Bakhshayeshkaram, N. Raad, S. Haseli, 18FDG PET/CT scan reveals hypoactive orbitofrontal cortex in anosmia of COVID-19, *Acad. Radiol.* (May (3)) (2020).