

Case Report

## Leflunomide: a treatment option for ganciclovir-resistant cytomegalovirus infection after renal transplantation

Joachim Andrassy<sup>1</sup>, Wilf Dieter Illner<sup>1</sup>, Markus Rentsch<sup>1</sup>, Gundula Jaeger<sup>3</sup>, Karl W. Jauch<sup>1</sup> and Michael Fischereider<sup>2</sup>

<sup>1</sup>Department of Surgery, Ludwig-Maximilian's University, Grosshadern, Munich, Germany, <sup>2</sup>Department of Medicine, Ludwig-Maximilian's University, IS, Munich, Germany and <sup>3</sup>Department of Virology, Ludwig-Maximilian's University, Munich, Germany

### Abstract

Cytomegalovirus (CMV) infection after renal transplantation is a problem of increasing concern resulting in significant morbidity and mortality. Widespread use of ganciclovir (GCV) and valganciclovir (VGCV) may cause an increase of CMV resistance to these first line drugs. Other treatment options are sparse and often complicated by adverse events, namely nephrotoxicity associated with foscarnet and cidofovir. Leflunomide may be another treatment option for CMV infections. So far it is not clear if leflunomide can also be used in the case of GCV-resistant CMV infections. Here we describe the use of leflunomide in two patients after renal transplantation with GCV-resistant CMV infections.

**Keywords:** CMV; ganciclovir; leflunomide; renal transplantation

### Introduction

Cytomegalovirus (CMV) disease can develop in up to 65% of the patients without prophylaxis depending on the donor–recipient constellation and is associated with an increased incidence of graft rejection and failure [1]. In the high-risk constellation [donor (D) +, recipient (R) –] pre-emptive therapy with antiviral drugs can substantially lower this percentage to around 20% [2]. However, low serum levels of or prolonged therapy with ganciclovir (GCV) may be associated with the development of GCV resistance in the presence of high levels of replicating virus. Resistance to GCV primarily involves mutation of UL97 (viral phosphotransferase) or UL54 (DNA polymerase) [3].

With cidofovir and the foscarnet, alternate drugs have been developed for the case of GCV-resistant CMV. Apart from their high nephrotoxic potential, they act by inhibition

of the viral DNA polymerase similar to the GCV. So it is not surprising that recently CMV strains have been identified with resistance to all three of these drugs [3].

Here, we show that leflunomide may represent a treatment alternative for GCV-resistant CMV infection after renal transplantation in two patients.

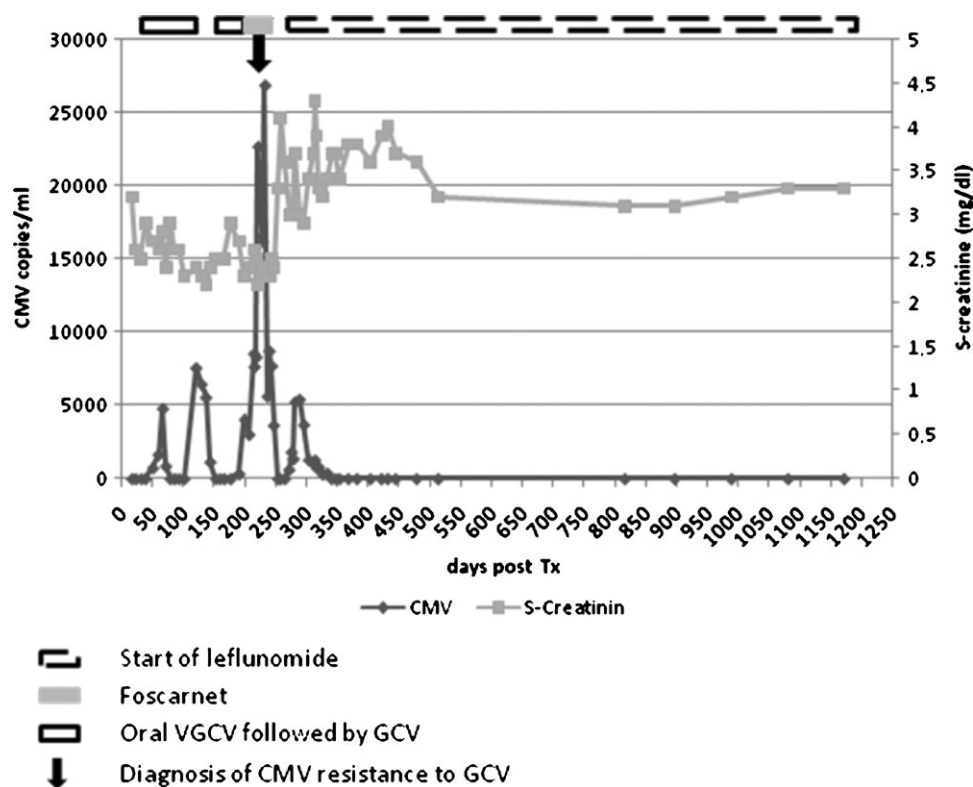
### Patient 1 (Figure 1)

A 44-year-old female patient with chronic renal failure due to sepsis and multiorgan failure during childbirth (HELLP-syndrome) received her first cadaveric kidney transplant in 2005 (high risk for CMV: D+, R–). The patient was treated with cyclosporine (CsA), mycophenolate mofetil (MMF) and steroids, and received ATG-*Fresenius* induction therapy (4 mg/kg/day) for 5 days. The kidney did not have primary function. A biopsy taken on Day 10 showed a Banff IV 2 b rejection. Anti-rejection therapy consisted of steroid bolus over 3 days (250 mg methylprednisolone/day) and a repeat course of ATG-*Fresenius* over 7 days. Two months after the transplantation, CMV copies had been detected in the patient's serum for the first time (736 copies/mL). Viraemia could be controlled under repeat GCV treatment cycles for the following 6 months when suddenly 26000 copies/mL were measured. A short course of foscarnet was started. In the meantime, the resistance to GCV was confirmed by the presence of the UL97 mutation. Due to the nephrotoxic effects of the foscarnet, the baseline creatinine had deteriorated from 2.4 to 3.3 mg/dL. Two months later, the patient presented with a second relapse (>5000 CMV copies/mL), and leflunomide was added to the patient's immunosuppressive regimen. As recommended, the dosing was 100 mg/day of leflunomide for the first 4 days and 20 mg/day thereafter. During the subsequent course, the patients CMV viraemia disappeared within 6 weeks and remained undetectable since.

### Patient 2 (Figure 2)

A 63-year-old female patient in chronic kidney failure due to glomerulonephritis received her first renal transplant in

Correspondence and offprint requests to: Joachim Andrassy, Department of Surgery, Transplant Division, Marchioninistrasse 15, 81377 Munich, Germany. Tel: +49-89-70950; Fax: +49-89-7095-5674; E-mail: joachim.andrassy@med.uni-muenchen.de



**Fig. 1.** Post-transplant course of patient no. 1: the diagnosis of GCV-resistant CMV (black arrow) was made 220 days post-transplantation. The CMV burden increased to >25 000 copies/mL and a short course of foscarnet (grey box) was administered. Baseline creatinine increased from 2.5 to >4 mg/dL. Leflunomide has not been started until GCV-resistant CMV relapsed ~2 months after the foscarnet. Trough levels were kept between 50 and 80  $\mu$ g/mL. The patient remained virus free with impaired but stable renal function since then (800 days).

1996. The graft was lost due to a thromboembolic event in 1998. The patient had then been diagnosed with a Factor V Leiden and APC resistance and put on continuous warfarin therapy. She was listed again and received her second renal transplant in September 2007 (high risk for CMV: D+, R-). The patient was immunized (PRA: 55%) and thus received an induction therapy consisting of basiliximab 20 mg on Days 0 and 4 combined with ATG-Fresenius (4 mg/kg/day) for 7 days according to our centre's standard at that time. The patient furthermore received tacrolimus, MMF and steroids as basic immunosuppressive treatment. The graft showed primary function. Thirty days post-transplant, the CMV-PCR was positive for the first time (1550 copies/mL). Under continuous oral valganciclovir (VGCV), the CMV copies showed an undulating course until a 100% increase was seen 3 months after the transplantation. Under repeated i.v. GCV, the CMV copies almost tripled so that anti-CMV immunoglobulins were administered, and a CMV-resistance test revealed the presence of the UL97 mutation. Leflunomide was introduced. The dosing was 80 mg/day for the first 4 days and 20 mg/day thereafter. Under this treatment the trough levels did not reach therapeutical levels (<30  $\mu$ g/mL). During the same time, the CMV copies increased further to 37000/mL. After adjustment of the leflunomide doses and a short course of foscarnet, the CMV copies finally decreased to undetectable levels without relapse up until now.

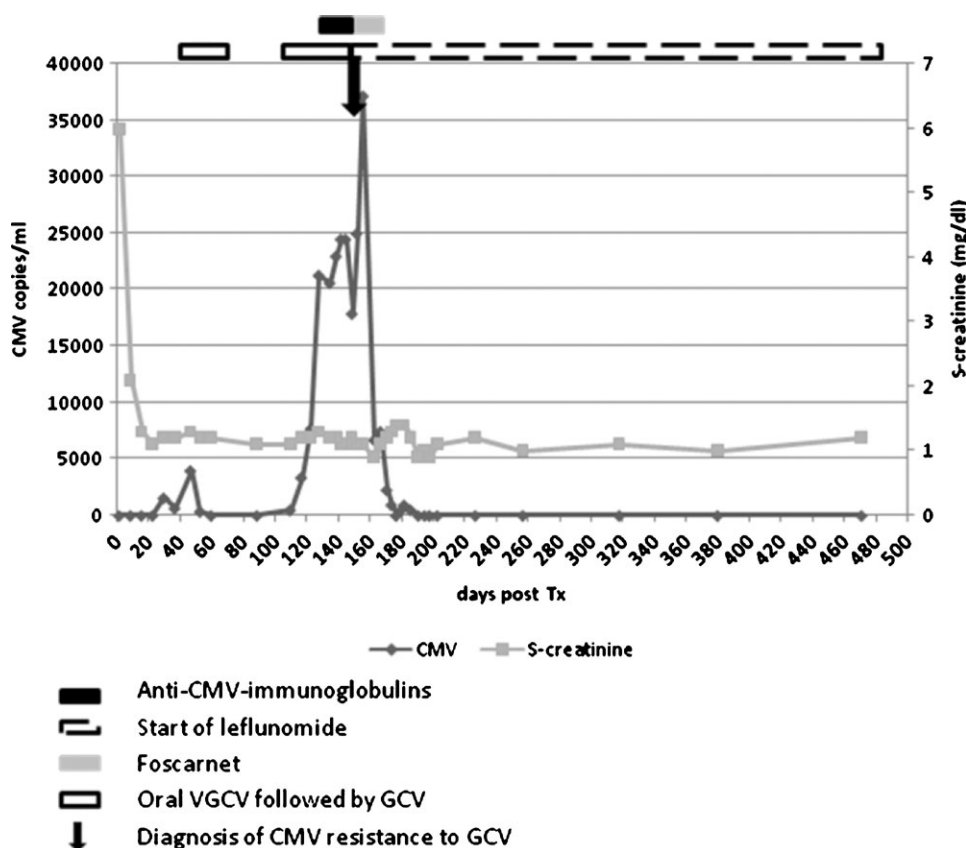
## Discussion

GCV-resistant CMV seems to develop preferably in those patients with a high-risk CMV constellation (D+, R-), a prolonged exposure of low levels of GCV and an intense immunosuppressive protocol [4]. Although antiviral agents are available to overcome this resistance, e.g. foscarnet, cidofovir and fomivirsen, their use is greatly limited by the overt nephrotoxic side effects. Other possibilities include tapering of the immunosuppression, mTOR-inhibitors [5], newer drugs [6] and 'very high-dose-GCV' [7].

The leflunomide, finally, has immunosuppressive as well as antiviral effects. It seems to inhibit the intracellular formation of viral nucleocapsid and thus exert its antiviral effects completely differently to the other anti-CMV drugs [8].

A prospective trial showed a successful course of 17 renal transplant patients with CMV disease treated with leflunomide [9]. One case of a successful treatment of a multidrug-resistant CMV infection with leflunomide has been reported so far [10]. Here, a renal transplant patient developed CMV retinitis.

In both our patients, foscarnet was administered so that a dual effect with the leflunomide cannot be ruled out. In patient no. 1, leflunomide was not introduced until the CMV had relapsed ~2 months after the administration of foscarnet. This makes a predominant role of the



**Fig. 2.** Post-transplant course of patient no. 2: after detection of the GCV, resistance of the CMV (black arrow) leflunomide was started. In the first 10 days, insufficient trough levels were measured ( $<30 \mu\text{g/mL}$ ) and the CMV burden increased to 37 000 copies/mL. A short course of foscarnet (grey box) was administered and trough levels of leflunomide were adjusted to 50–100  $\mu\text{g/mL}$ . The patient was cleared of the virus and remained virus free with good renal function since then (280 days).

foscarnet unlikely. Unfortunately, in patient no. 2, insufficient leflunomide doses were given and the CMV viral load had increased further to very high levels. Apart from adjusting the leflunomide dosage, we therefore decided to start a short course of foscarnet that helped eliminating the virus. In situations like this, a combination of the two drugs may be worthwhile: foscarnet to help reduce the virus burden quickly and leflunomide as a well-tolerated long-term prophylaxis.

*Conflict of interest statement.* None declared.

## References

1. Fishman JA, Rubin RH. Infection in organ-transplant recipients. *N Engl J Med* 1998; 338: 1741–1751
2. Hibberd PL, Tolkoff-Rubin NE, Conti D *et al.* Preemptive ganciclovir therapy to prevent cytomegalovirus disease in cytomegalovirus antibody-positive renal transplant recipients. A randomized controlled trial. *Ann Intern Med* 1995; 123: 18–26
3. Erice A. Resistance of human cytomegalovirus to antiviral drugs. *Clin Microbiol Rev* 1999; 12: 286–297
4. Limaye AP, Corey L, Koelle DM *et al.* Emergence of ganciclovir-resistant cytomegalovirus disease among recipients of solid-organ transplants. *Lancet* 2000; 356: 645–649
5. Ozaki KS, Camara NO, Nogueira E *et al.* The use of sirolimus in ganciclovir-resistant cytomegalovirus infections in renal transplant recipients. *Clin Transplant* 2007; 21: 675–680
6. Drew WL, Miner RC, Marousek GI *et al.* Maribavir sensitivity of cytomegalovirus isolates resistant to ganciclovir, cidofovir or foscarnet. *J Clin Virol* 2006; 37: 124–127
7. West P, Schmiedeskamp M, Neeley H *et al.* Use of high-dose ganciclovir for a resistant cytomegalovirus infection due to UL97 mutation. *Transpl Infect Dis* 2008; 10: 129–132
8. Waldman WJ, Knight DA, Blinder L *et al.* Inhibition of cytomegalovirus *in vitro* and *in vivo* by the experimental immunosuppressive agent leflunomide. *Intervirology* 1999; 42: 412–418
9. John GT, Manivannan J, Chandy S *et al.* A prospective evaluation of leflunomide therapy for cytomegalovirus disease in renal transplant recipients. *Transplant Proc* 2005; 37: 4303–4305
10. Levi ME, Mandava N, Chan LK *et al.* Treatment of multidrug-resistant cytomegalovirus retinitis with systemically administered leflunomide. *Transpl Infect Dis* 2006; 8: 38–43

*Received for publication:* 3.1.09

*Accepted in revised form:* 6.1.09