

Evidence-Based Approach to Timing of Nerve Surgery

A Review

Brendan J. MacKay, MD,^{a,b} Cameron T. Cox, BBA,^a Ian L. Valerio, MD,^c Jeffrey A. Greenberg, MD,^d
 Gregory M. Buncke, MD,^e Peter J. Evans, MD, PhD,^f Deana M. Mercer, MD,^g
 Desirae M. McKee, MD,^{a,b} and Ivica Ducic, MD, PhD^h

Abstract: Events causing acute stress to the health care system, such as the COVID-19 pandemic, place clinical decisions under increased scrutiny. The priority and timing of surgical procedures are critically evaluated under these conditions, yet the optimal timing of procedures is a key consideration in any clinical setting. There is currently no single article consolidating a large body of current evidence on timing of nerve surgery. MEDLINE and EMBASE databases were systematically reviewed for clinical data on nerve repair and reconstruction to define the current understanding of timing and other factors affecting outcomes. Special attention was given to sensory, mixed/motor, nerve compression syndromes, and nerve pain. The data presented in this review may assist surgeons in making sound, evidence-based clinical decisions regarding timing of nerve surgery.

Key Words: nerve surgery, timing, nerve repair, timing nerve surgery, timing nerve repair, delayed nerve repair, immediate nerve repair, nerve timing, nerve timing outcomes, delayed nerve surgery outcomes, acute versus delayed nerve repair, timing nerve decompression, acute nerve surgery, acute nerve repair, coronavirus, COVID-19

(*Ann Plast Surg* 2021;87: e1–e21)

The circumstances created by the COVID-19 pandemic have shed light on a number of unanswered questions, particularly with regard to the acuity of conditions and urgency of surgical procedures. In the context of nerve surgery, the need for expedited decisions has revealed a lack of consolidated evidence, as there is currently no published article presenting clinical data on timing considerations of nerve surgery across a wide variety of injury patterns. Surgery remains necessary for many patients, even amid resource diversion, and all procedures exist within a timing hierarchy. An evidence-based approach is needed to adequately distinguish the relative acuity of different conditions, particularly within broad (and often misunderstood)

categories such as “elective” surgery, which is frequently conflated with “optional.”¹

Published recommendations not created or endorsed by expert subspecialty groups are often vague and fail to address the nuances of clinical decision making (Tables 1, 2; Fig. 1). Overly simplified

TABLE 1. Orthopedic surgery case triage

Emergent—within 6 h	<ul style="list-style-type: none"> • Compartment syndrome • Open fracture • Joint dislocations • Fracture-dislocations • Dysvascular limb/ex fix • Traumatic amp/replant • Septic joint • Abscess • Cauda Equina syndrome
Urgent—within 24–48 h	<ul style="list-style-type: none"> • Hip and femur fractures • Pelvis and acetabulum fractures • Long bone (femur, tibia, humerus) fractures • Multiple fractures • Unstable spine fractures or progressive neurologic deficits
Acute—within 7 d	<ul style="list-style-type: none"> • Fractures in general • Hand/UE • Ankle/tibial plateau, etc • Spine fractures without gross • Instability/cord compromise or neurologic symptoms • Multiligamentous knee dislocation (s/p initial stabilization [ex fix] if necessary)
Semielective	<ul style="list-style-type: none"> • Incarcerated meniscus • Biceps tear/tendon repairs • Nerve transection
Elective	<ul style="list-style-type: none"> • Total joint replacement (hip/knee/shoulder/ankle) • Degenerative spine without cord/neurologic compromise • Nonunion without hardware compromise/unstable extremity • Degenerative hand/foot/ankle • Isolated knee ligament/meniscus etc • Hardware removal

Dr Ficke, AAOS Board of Directors, Johns Hopkins Hospital.
 ex fix, external fixation; s/p, status post; UE, upper extremity.

Received July 20, 2020, and accepted for publication, after revision December 30, 2020. From the ^aTexas Tech University Health Sciences Center; ^bUniversity Medical Center, Lubbock, TX; ^cPlastic and Reconstructive Surgery, Massachusetts General Hospital, Boston, MA; ^dIndiana Hand Center, Indianapolis, IN; ^eThe Buncke Clinic, San Francisco, CA; ^fOrthopaedic Surgery, Cleveland Clinic of Florida, Weston, FL; ^gDepartment of Orthopaedics and Rehabilitation, The University of New Mexico, Albuquerque, NM; and ^hWashington Nerve Institute, McLean, VA. Conflicts of interest and sources of funding: Although this review was not directly funded by any grant, Texas Tech University Department of Orthopaedics does receive funding and grant awards to participate in the nationwide RANGER nerve allograft trial as well as investigating uses of AVIVE (human umbilical membrane) sponsored by Axogen. The authors declare no conflict of interest.

Reprints: Cameron T. Cox, BBA, Department of Orthopaedic Surgery, Texas Tech University Health Sciences Center, 3601 4th Street, Mail Stop 9436, Lubbock, TX 79430. E-mail: cameron.cox@ttuhsc.edu.

Copyright © 2021 The Author(s). Published by Wolters Kluwer Health, Inc. This is an open-access article distributed under the terms of the Creative Commons Attribution-Non Commercial-No Derivatives License 4.0 (CCBY-NC-ND), where it is permissible to download and share the work provided it is properly cited. The work cannot be changed in any way or used commercially without permission from the journal.

ISSN: 0148-7043/21/8703-00e1

DOI: 10.1097/SAP.0000000000002767

TABLE 2. Selected Sections From the American College of Surgeons “Guidelines for Triage of Orthopedic Patients”

	Phase II		Phase III	
	Schedule	Reschedule	Schedule	Reschedule
Trauma	All new fractures Acute traumatic injury Nonunions, malunions, infections	Fractures >4 wk old	All new fractures Quad tendon rupture Patellar tendon rupture Acute change of a chronic injury	“Soft tissue injury” Patients without a diagnosis Malunions, nonunions Chronic infections
Orthopedic oncology	Infection including infected joints Sarcoma/other primary malignancy in a “chemo or radiation” window Aggressive benign tumors (GCT) Impending pathologic fracture (including periprosthetic) Pathologic fracture	Benign soft tissue masses Benign bone tumors that can wait Elective joint replacement	Infection including infected joints Sarcoma/other primary malignancy in a “chemo or radiation” window Aggressive benign tumors (GCT) Impending pathologic fracture (including periprosthetic) Pathologic fracture	
Shoulder and elbow	Acute severe pain Falls with loss of function Any fracture Any acute changes in function of shoulder or elbow Any neurological issues. Any infection	Shoulder/elbow arthritis Unchanged chronic pain with retained function Hospital discharge without impatient consult Hospital consultation, shoulder triaged Chronic cuff disease with unchanged function	Falls with inability to move shoulder or elbow Proximal humerus fracture, humeral shaft fracture, distal humerus fracture Elbow fracture dislocation, elbow or shoulder dislocation Olecranon fracture, clavicle fracture New loss of function. Acute-onset neurological complaints. Any infection	New-onset shoulder or elbow pain without trauma Shoulder/elbow arthritis Chronic shoulder pain with function intact Self-scheduling without screening Chronic shoulder or elbow dislocations with joint reduced
Hand	Laceration with tendon, nerve injury Acute infection Acute fractures hand, wrist, elbow requiring surgical treatment Acute injury hand, wrist, elbow within 2 wk	Healed lacerations with no tendon, nerve injury. Chronic and resolved infections Tendonitis hand, wrist, elbow, trigger finger, DeQuervain's, epicondylitis (tennis/golfer's elbow) Nerve compression syndromes carpal tunnel, cubital tunnel, etc Chronic fracture over 6 wk. Injury hand, wrist, elbow over 2 wk	Acute laceration with tendon, nerve injury within 2 wk Acute infection Acute fractures requiring surgical management Acute high-energy hand, wrist, elbow pain without prior evaluation	Lacerations over 2 wk. Chronic infection, chronic osteomyelitis Tendonitis hand, wrist, elbow, trigger finger, DeQuervain's, epicondylitis (tennis/golfer's elbow) Nerve compression syndromes carpal tunnel, cubital tunnel, etc Nonoperative fractures and fractures over 2 wk. Injury hand, wrist, elbow pain over 2 wk

GCT, giant cell tumor.

algorithms will do little to assist surgeons and may even give a false sense of security when further deliberation is warranted. Physicians should always operate by best practices aligned with current evidence. A misstep in clinical judgment can leave patients and surgeons vulnerable to poor outcomes. A condensed view of the relevant data could assist physicians advocating for patients' timely treatment. The following review may ultimately serve as a resource to positively impact outcomes in patients with peripheral nerve injuries.

METHODS

The authors performed a systematic review of the MEDLINE and EMBASE databases using a comprehensive combination of keywords and search algorithm according to PRISMA guidelines. The literature search focused on clinical evidence-based data on nerve repair and reconstruction and was undertaken to define the current understanding of nerve repair timing and outcomes. Particular emphasis

was made evaluating sensory, mixed/motor, nerve compression syndromes, and nerve pain. Search terms are listed in Table 3.

DELAYED TREATMENT OF INJURED NERVES

When peripheral nerves are injured, a coordinated response involving both neurons and nonneuronal cells is initiated^{2,3} (Fig. 2). Inflammatory changes increase blood-nerve barrier permeability, activating Schwann cells and macrophages.⁴ Nerve injuries present with varying degrees of involvement, which often dictate treatment and expected outcomes (Table 4). In less severe injuries, natural processes are often successful in regenerating the injured portion of a nerve, and full functional recovery may be achieved without intervention.⁶ However, with more severe injury, prolonged neuronal input deficiency distal to the site of injury can significantly reduce the regenerative success of nerves.^{4,7,8}

Elective Surgery Algorithm

ILI Symptoms:

- Fever 100.4 or greater
- Cough
- Shortness of breath
- Malaise

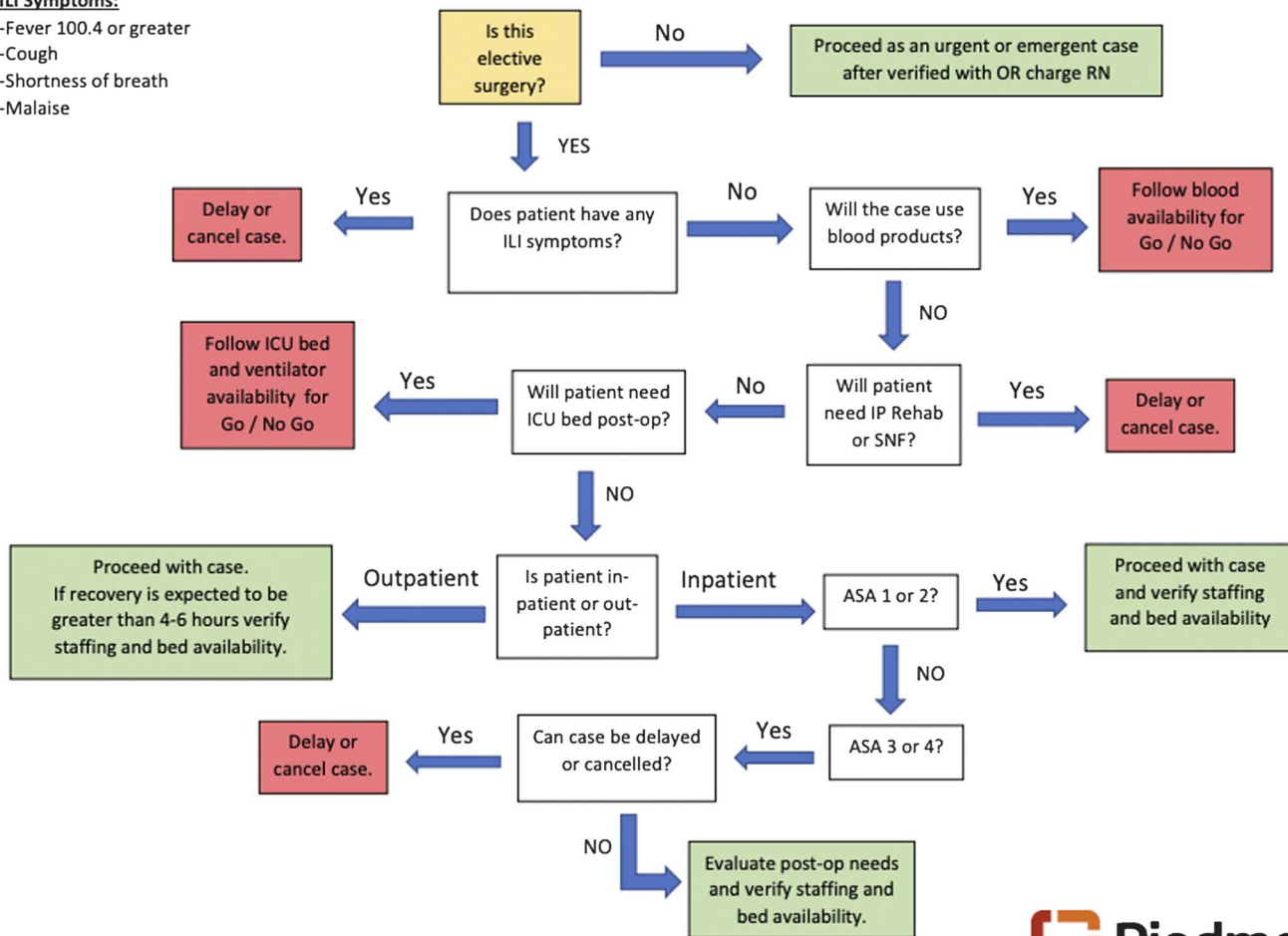


FIGURE 1. Treatment algorithm for elective cases currently in use by some centers. Piedmont Healthcare System, Georgia. full color online

In large nerve defects with greater regeneration times, denervated distal targets may not be successfully regenerated.^{9–12} In the distal stump of a severed nerve, endoneurial tubes progressively and permanently shrink in diameter, and Schwann cells lose their capacity to support axonal growth when left transected^{13,14} (Figs. 2, 3). Target sensory and motor end-organs deteriorate irreversibly over time. Another cause for suboptimal recovery in peripheral nerve injury is upstream degeneration. When nerve injuries are incurred, neuronal cell death commences in the dorsal root ganglia (distal sensory nerve injuries) and/or the spinal motor neurons (proximal nerve injuries, eg, brachial plexus).¹⁵ Cortical changes are known to develop in cases of prolonged neuronal deficiency, and neural plasticity should be considered when making decisions related to timing of intervention.^{16–19}

Peripheral nerve injuries are known to result in poor sensory and/or motor function if left untreated.^{8,20} Significant declines in postoperative function and chronic pain may lead to long-term disabilities for patients who do not receive timely operative treatment^{21–26} (Table 5). This could impact more than patient outcomes, as both proximal and distal nerve injuries may contribute to high costs, lost work or medical disabilities, increased pharmacologic dependencies and expenses, and substantial lost function.²⁸

In a study of 66 median and/or ulnar nerve lesions, Dumont and Alnot²⁶ found that the time from injury to repair was the most significant prognostic factor in functional nerve recovery. Multiple reports in the literature describe the negative implications of delayed repair on sensory and motor outcomes in a variety of injury patterns, with one study indicating the critical window lies within 3 months.^{3,10,29,30} Considering the implications of prolonged nervous deficiency, timing is critical for treatment algorithms involving the peripheral nerves.^{31,32}

SENSORY VERSUS MOTOR NERVES

Clinical data indicate that sensory nerves may be less affected by prolonged denervation than motor nerves^{19,33} (Table 6).³² However, the histologic response to prolonged denervation seems to be amplified for sensory when compared with motor nerves.³ The recovery of mixed motor nerves degrades dramatically over time, as repairs delayed more than 1 month exhibit significant functional declines. This is especially pronounced in motor outcomes, as the functional loss is even more amplified the longer the muscle is denervated because the end-target organ (eg, muscle supplied by an injured nerve) may not regenerate.^{32,34}

In a systematic review of 270 mixed nerve injuries (150 ulnar, 75 median, 45 radial), good to excellent sensory recovery (scoring scales in

TABLE 3. Search Terms Used in PubMed for Each Section

Delayed treatment of injured nerves	Delayed nerve surgery, delayed vs immediate nerve repair, nerve surgery, prognostic factors affecting nerve recovery, outcomes of peripheral nerve surgery, functional outcomes nerve, timing of nerve repair, late reconstruction nerve, immediate reconstruction nerve, acute reconstruction nerve, poor functional recovery nerve, peripheral nerve regeneration, mechanism of nerve injury, mechanism of nerve regeneration, mechanism of nerve recovery
Sensory vs motor nerves	Sensory nerve repair, motor nerve repair, sensory nerve prognostic factors, motor nerve prognostic factors, sensory nerve outcomes, motor nerve outcomes, mixed nerve outcomes, sensory vs motor nerve repair, sensory vs motor nerve outcomes, timing sensory nerves, timing motor nerves, timing mixed nerves, delay sensory nerve repair, delay motor nerve repair, delay mixed nerve repair, delay vs immediate sensory nerve, delay vs immediate motor nerve, delay vs immediate mixed nerve, repair techniques sensory nerve, repair techniques motor nerve, repair techniques mixed nerve
Digital nerves	Digital nerve repair, digital nerve prognostic factors, digital nerve outcomes, digital nerve sensory outcomes, digital nerve motor outcomes, timing digital nerves, delay digital nerve repair, immediate digital nerve repair, delay vs immediate digital nerve, repair techniques digital nerve
Compartment syndrome	Compartment syndrome peripheral nerve, compartment syndrome nerve changes, compartment syndrome neuropathy, compartment syndrome timing nerve, compartment syndrome timing, compartment syndrome delay, compartment syndrome delayed vs immediate, compartment syndrome irreversible nerve changes, compartment syndrome ischemia, compartment syndrome pediatric, compartment syndrome adult, compartment syndrome pressure
Acute nerve compression/dysfunction	Acute compressive neuropathy, acute ulnar nerve compression, acute median nerve compression, acute carpal tunnel, acute cubital tunnel, posttraumatic compressive neuropathy, pressure acute nerve compression, timing acute nerve compression, timing acute nerve decompression, timing traumatic nerve compression, normal healthy carpal tunnel pressure, normal healthy cubital tunnel pressure, acute nerve compression changes, acute nerve compression irreversible nerve changes, acute nerve compression timing, acute nerve release timing, acute carpal tunnel release timing, acute cubital tunnel release timing, acute vs delayed traumatic decompression, acute vs delayed traumatic compressive neuropathy, compressive neuropathy cyst, compressive neuropathy ischemia, posttraumatic neuropathy, postsurgical neuropathy, surgery neuropraxia, timing posttraumatic neuropathy, timing postsurgical neuropathy, timing surgery neuropraxia
Chronic nerve compression	Compressive neuropathy, carpal tunnel syndrome, cubital tunnel syndrome, radial tunnel syndrome, ulnar nerve compression, median nerve compression, Guyon's canal decompression, timing acute nerve compression, timing nerve decompression, timing carpal tunnel release, timing cubital tunnel, timing ulnar nerve transposition, delayed nerve decompression, delayed carpal tunnel release, delayed cubital tunnel, delayed ulnar nerve transposition, prolonged nerve compression, prognostic factors carpal tunnel, prognostic factors cubital tunnel, prognostic factors nerve decompression, prognostic factors median nerve decompression, prognostic factors ulnar nerve decompression, time changes peripheral neuropathy, irreversible changes compressive neuropathy, revision* nerve decompression, revision carpal tunnel, revision cubital tunnel, revision radial tunnel, timing revision nerve decompression, timing revision carpal tunnel, timing revision cubital tunnel, timing revision radial tunnel, prognostic factors revision nerve decompression, prognostic factors revision carpal tunnel, prognostic factors revision cubital tunnel
Blunt trauma and gunshot wounds	Blunt trauma peripheral nerve, blunt trauma nerve changes, blunt trauma neuropathy, blunt trauma timing nerve, blunt trauma timing, blunt trauma delay, blunt trauma delayed vs immediate, blunt trauma irreversible nerve changes, gunshot wound peripheral nerve, gunshot wound nerve changes, gunshot wound nerve changes, gunshot wound timing nerve, gunshot wound timing, gunshot wound delay, gunshot wound delayed vs immediate, gunshot wound irreversible nerve changes, gunshot wound delayed exploration, gunshot wound immediate exploration, gunshot wound treatment, penetrating wound delay, penetrating wound immediate, penetrating wound exploration, penetrating wound timing

*All terms including "revision" were also searched using "recurrent" and "recalcitrant."

Table 7) occurred in 90.9% of immediate repairs (<24 hours from time of injury), 58.3% with a delay of <1 month, 73.3% with a delay of 1 to 3 months, and 46.2% with a delay of ≥ 3 months³⁵ (Table 8).^{32,36-93} Although aggregate data show declines at monthly intervals, individual studies have reported increments as small as 14 days for progressive functional decline.^{54,58,65}

In the same group, good to excellent motor recovery was achieved in 85.7% of immediate repairs, 80.0% with a delay of <1 month, 71.9% with a delay of 1 to 3 months, 52.9% with a delay of 3 to 6 months, and 25.0% with a delay of >6 months³⁵ (Table 8).³⁶⁻⁹⁴ For each month of delay to repair, there was a significant decrease in the odds of good-excellent motor recovery (odds ratio, 0.93; 95% confidence interval [CI], 0.90-0.97; $P < 0.01$).³² In one study of 260 radial and posterior interosseous nerves, 49% of nerves repaired within 14 days achieved good-excellent results, whereas only 28% of late repairs (mean, 190 days; range, 15-440 days) produced good-excellent outcomes.⁵⁸ One study involving 82 musculocutaneous nerve injuries reported 78% (21/27) good-excellent results when repaired within 14 days and 62% (34/55) when performed >14 days after injury.⁵⁴

When making decisions for timing of nerve procedures, it is critical to use a multifactorial approach. The trends described previously are broad and do not account for variables such as gap length,

mechanism of injury, proximal versus distal location, and other considerations to be discussed in later sections, which may have a compound negative effect on delayed repairs (Tables 6, 8).

Take-Home Messages

Sensory-Only

Sensory-only nerve injuries should be considered acutely (within 14 days of injury) when possible to prevent painful neuroma formation. Once a neuroma occurs, it becomes an additional task to overcome the psychological impairment and, in some instances, narcotic dependency in order to return patients to a healthy return to functional activities. In cases where the initial presentation is delayed, it is suggested to repair within 14 days of clinical presentation if the injury occurred <6 months prior. After 6 months, reconstruction may still be undertaken but with consideration for possible adjunctive techniques to optimize outcomes based on individual prognostic factors.

Functional sensory return is not as time sensitive as muscle reinnervation. Although sooner is better, evidence points to functional sensory return being achievable for several years after complete transection, yet the quality of such delayed recovery might remain less predictable.³² Additional preoperative factors that should be considered in sensory-only

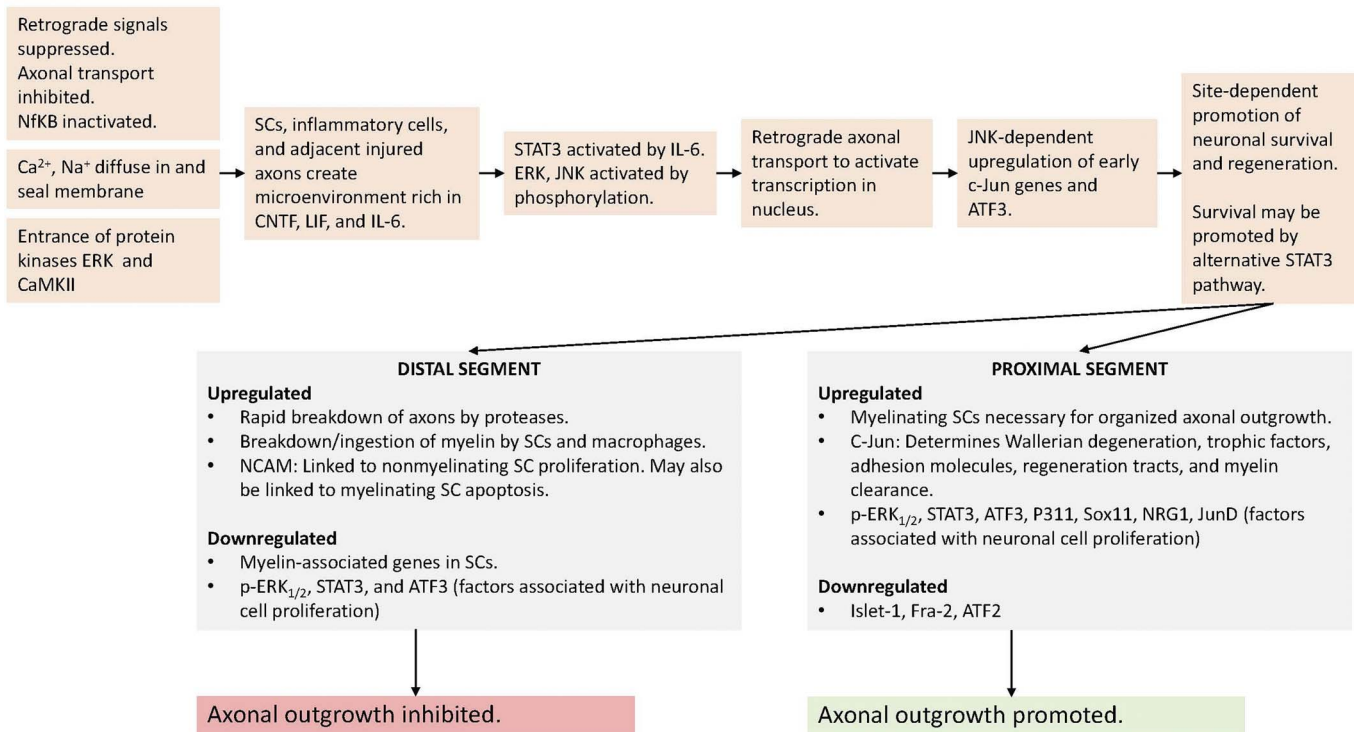


FIGURE 2. Peripheral nerve injury cascade of events leading to the unidirectional regeneration from proximal to distal stump. ATF2, activating transcription factor 2; ATF3, activating transcription factor 3; ERK, extracellular signal-regulated kinase; CaMKII, Ca²⁺/calmodulin-dependent protein kinase II; CNTF, ciliary neurotrophic factor; Fra-2, transcription factor; IL-6, interleukin 6; Islet-1, transcription factor; JNK, c-Jun N-terminal kinase; JunD, transcription factor; LIF, leukemia inhibitory factor; NCAM, neural cell adhesion molecule; NfκB, nuclear factor κB; NRG1, neuregulin 1; p-ERK_{1/2}, phosphorylated extracellular signal-regulated kinase; P311, 8-kDa protein with several PEST-like motifs found in neurons and muscle; SC, Schwann cell; Sox11, transcription factor; STAT3, signal transducer and activator of transcription 3. [full color online](#)

nerve injuries include gap length, injury level, ability to identify proximal and distal stumps, and concomitant vessel or tendon injuries (Table 6).³²

Mixed/Motor

For mixed/motor nerve injuries, immediate repair (within 24 hours of injury) is suggested when possible. In cases where the initial presentation is delayed, it is suggested to repair within 14 days of clinical presentation if the injury occurred <6 months prior. After 6 months, a

multifactorial approach including but not limited to nerve grafting, nerve transfer, and/or tendon transfer may be necessary to restore function.

Motor endplate degradation may limit the amount of time available for any functional motor return. Typically, efforts should be taken to provide axons to the muscle endplates no later than 1 year after complete transections.^{95,96} Because of the slow rate (~1 mm/d) and unidirectional nature (neuronal outgrowth only occurs distally from proximal end), irreversible motor endplate degradation has been observed as early as 12 months after injury.^{3,95,96} Additional preoperative factors that

TABLE 4. Classifications of Nerve Injuries

Degree of Nerve Injury	Definition of Nerve Injury	Prognosis	Tinel Sign	Surgical Intervention
First (neurapraxia)	Segmental demyelination Axonal continuity maintained; endoneurium, perineurium and epineurium, intact	Favorable	None	None, distal decompression
Second (axonotmesis)	Discontinuity of axon and myelin; endoneurium, perineurium, and epineurium intact	Favorable	Present, progressive	None, distal decompression, supercharge procedure
Third	Discontinuity of axon, myelin and endoneurium; perineurium and epineurium intact	Favorable	Present, progressive	None, distal decompression, supercharge procedure
Fourth	Only the epineurium remains intact	Unfavorable	Present; no progression	Nerve repair, graft, transfer
Fifth (neurotmesis)	Complete nerve transection	Unfavorable	Present; no progression	Nerve repair, graft, transfer
Sixth	Mixed injury pattern	Variable	Variable	All options may be appropriate

Table adapted from Moore et al.⁵

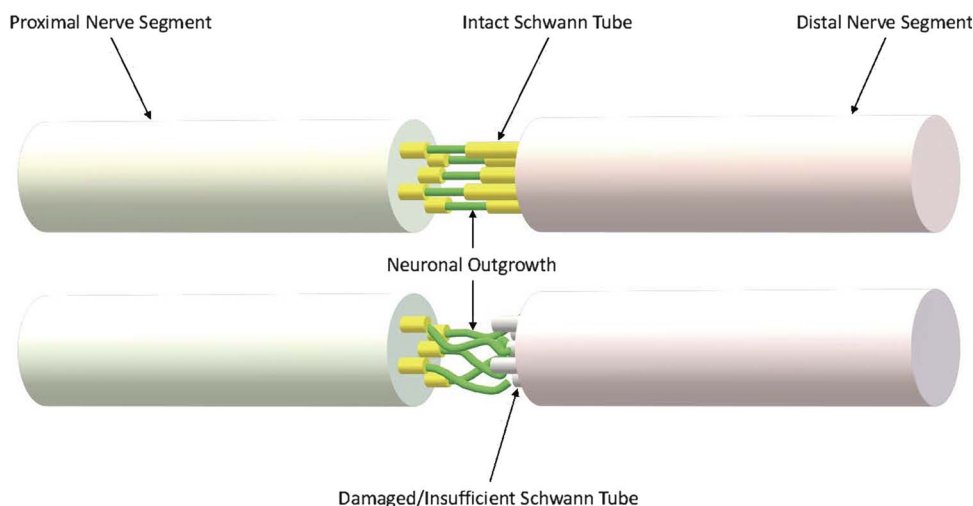


FIGURE 3. Effect of Schwann cell insufficiency on distal nerve segments after prolonged discontinuity. full color
online

should be considered in mixed nerves include the following: age, nerve injured, level of injury, concomitant vessel or tendon injuries, and gap length (Table 8).³⁶⁻⁹⁴

DIGITAL NERVES

Digital nerve injuries are a unique subset of sensory nerve injuries and should be considered independently with respect to timing of operative intervention. Although digital nerves primarily supply sensation to the hand, abnormal sensory outcomes have been shown to have an effect on motor function.⁹⁴ Patients with good active range of motion may not use the affected digit because of the lack of sensation or pain with movement, resulting in lasting stiffness and/or weakness.⁹⁷ Pain secondary to symptomatic neuroma formation has been shown to interfere with rehabilitation and functional outcomes, especially in the thumb and index finger, as both are critical for normal pinch and grip function.⁹⁸ A time to repair of <15 days has been associated with significantly improved sensory outcomes⁹⁹ (Table 9).^{32,97,100,101,103-119,121-123} Another study

including 254 digital nerve repairs reported significantly improved outcomes in repairs performed within 3 months of injury.¹²⁴

Take-Home Messages

For digital nerves, acute repair (within 14 days of injury) is suggested when possible. In cases where the initial presentation is delayed, repair is suggested within 3 months after injury to prevent painful neuroma formation. Once a neuroma occurs, it becomes an additional task to overcome the psychological impairment and, in some instances, narcotic dependency in order to return patients to a healthy return to functional activities. After 3 months, reconstruction may still be undertaken but with consideration for possible adjunctive techniques to optimize outcomes based on individual prognostic factors.

Functional sensory return is not as time sensitive as muscle reinnervation. Although sooner is better, evidence points to functional sensory return being achievable for several years after complete transection, although the extent of such recovery might be incomplete or less predictable. Additional preoperative factors that should be considered in

TABLE 5. Comparison of Patient-Reported Outcomes in Untreated Peripheral Nerve Injuries (Novak et al²⁷) Versus Those Having Undergone Operative Intervention

SF-36 Scores	Physical Function	Role Limit to Physical Health	Role Limit to Emotional Problems	Energy/Fatigue	Emotional Well-Being	Social Function
Novak et al²⁷ >6 mo after injury without operative intervention (n = 57)						
Mean ± SD	60.0 ± 23.0	23.0 ± 33.0	45.0 ± 43.0	49.0 ± 24.0	58.0 ± 23.0	57.0 ± 30.0
DASH/QuickDASH Scores						
Study	Mean Follow-Up, mo	Final Percent Disability, Mean ± SD	Mean Improvement From First Form			
Novak et al ²⁷ (n = 57): upper extremity nerve injury without operative intervention.	38.0	52.0 ± 22.0	n/a			
Lequint et al ²² (n = 30): ulnar nerve transposition	6.0	38.0 ± 21.5	10.0 (pre-op–current)			
Domeshek et al ²³ (n = 19): upper extremity nerve decompression and/or transposition	4.0	37.2 ± 27.0	11.3 (pre-op–current)			
Ido et al ²⁴ (n = 52): ulnar nerve transposition	34.8	11.1 ± 10.5	16.1 (pre-op–current)			
Guse and Moran ²⁵ (n = 54): upper extremity neuroma excision, transposition, or nerve repair (43 traumatic injuries)	240	19.75 ± 20.5	n/a			

TABLE 6. Outcomes of Sensory-Only Peripheral Nerve Repairs

Predictor	Group	Satisfactory (Good-Excellent) Sensory Recovery
Age	≤16 y	100% (7/7)
	16–25 y	75.0% (24/32)
	26–40 y	88.5% (23/26)
	>40 y	75.0% (18/24)
	Total (n)	n = 89
	Univariate odds ratio per year (95% CI)	0.98 (0.95–1.02), P = 0.31
Sex	Male	67.4% (29/43)
	Female	95.5% (21/22)
	Total (n)	n = 65
	Univariate odds ratio (95% CI): female vs male	10.14 (1.24–83.18), P = 0.03
Nerve	Digital	80.7% (71/88)
	Total (n)	n = 88
Graft length	No graft	100% (2/2)
	≤30 mm	76.2% (45/54)
	30–50 mm	33.3% (2/6)
	>50 mm	33.3% (1/3)
	Total (n)	n = 65
	Univariate odds ratio (95% CI), gap/cm	0.49 (0.30–0.80), P < 0.01
Delay	No delay (<24 h)	78.6% (33/42)
	1–30 d	75.0% (3/4)
	1–3 mo	100% (5/5)
	3–6 mo	84.6% (1/13)
	6–12 mo	75.0% (3/4)
	>12 mo	100% (2/2)
	Total (n)	n = 70
		Univariate odds ratio per month (95% CI)

Table adapted from He et al.³²

sensory-only nerves include gap length, ability to identify proximal and distal stumps, and concomitant vessel or tendon injuries (Table 6).³²

ACUTE NERVE COMPRESSION/DYSFUNCTION

In cases of acute compressive neuropathy, prompt diagnosis is particularly important because symptoms and functional outcomes deteriorate more quickly due to severe ischemic conditions and/or intraneural scarring.¹²⁵ Acute compressive neuropathy in the ulnar nerve is rare, with the majority of cases occurring in Guyon's canal secondary to ganglion cyst.^{125–128} Although early decompression has been recommended, the literature lacks algorithms for timing of intervention.^{126–129}

Treatment algorithms have been described in the literature for acute median nerve compression, which is frequently associated with distal radius fractures.^{130–134} In healthy patients, carpal tunnel pressure has been reported from 5 to 14 mm Hg. Although carpal tunnel pressure has been reported from 12 to 43 mm Hg in patients with chronic carpal tunnel syndrome, acute cases may be elevated between 40 and 60 mm Hg.^{129,135} Although the exact threshold for irreversible damage is

unknown, the literature has indicated that irreversible damage may be incurred at pressures as low as 30 mm Hg.¹²⁹

Given the amplified sequelae of acute compression, pressure measurements may be taken after 2 hours of nonsurgical intervention (eg, elevation or dressing release) using a wick catheter or STIC device.¹³¹ The current literature on compartment syndrome indicates delayed intervention may lead to additional operations and/or permanent ischemic nerve damage.¹³⁶ Although it is difficult to pinpoint the delay time because the exact time of onset is often not known, earlier intervention has been associated with significantly improved functional recovery.^{123,137–141}

In a study of 22 patients, 68% of those treated within 12 hours recovered normal function, compared with only 8% in patients treated >12 hours from time of onset.^{136,138} Nerve conduction velocity returned to normal if compartment release was performed within 4 hours.^{138,142} Of note, patient age seems to play a role in functional outcomes of compartment release. In a review of 39 pediatric cases with a mean time to diagnosis of 48 hours, 54% returned to normal function.¹⁴² Another review reported that 85% of pediatric patients achieved full functional recovery when treated within a mean of 24.5 hours after the onset of symptoms.^{131,143}

Frequently, patients present with postsurgical nerve dysfunction such as radial nerve palsy after open reduction and internal fixation of humeral fractures,^{144,145} peroneal and/or saphenous nerve palsy after knee ligament reconstruction and/or dislocation,^{146–150} or ulnar nerve complications after medial or collateral ligament reconstruction of the elbow.^{151–153} The literature addressing timing in these contexts is highly variable.^{144,145,148,150,151} Generally, symptom severity and duration are thought to be indicators of potential for spontaneous recovery or need for operative intervention. Although the literature lacks consensus recommendations, close monitoring of nerve symptoms is recommended in the early postoperative period (up to 12 weeks).^{144,145,148,150,151}

Take-Home Messages

In the case of posttraumatic compressive neuropathy, if symptoms persist and/or elevated pressure remains in the affected tunnel/canal at 2 hours after injury, exploration with possible release should

TABLE 7. Sensory and Range of Motion Recovery Scoring Scales

Mackinnon-Dellon Scale (modified from British Medical Research Council Score of Sensory Recovery)	S0 (failure): absence of sensibility in the autonomous area of the nerve
	S0 (none): no recovery of sensibility in the autonomous zone of the nerve
	S1 (poor): recovery of deep cutaneous pain and tactile sensibility
	S1+ (poor): recovery of superficial pain sensibility
	S2 (poor): recovery of some degree of superficial cutaneous pain and tactile sensibility
	S2+ (poor): as in s2, but with overresponse
	S3 (poor): return of pain and tactile sensibility with disappearance of over response, s2PD >15 mm, m2PD >7 mm
	S3+ (good): return of sensibility as in s3 with some recovery of 2-point discrimination: s2PD, 7–15 mm; m2PD, 4–7 mm
	S4 (excellent): complete recovery: s2PD, 2–6 mm; m2PD, 2–3 mm
	ASSH classification of total active motion (TAM) recovery

TABLE 8. Outcomes of Mixed Motor Peripheral Nerve Repairs

Predictor	Group	Satisfactory (Good-Excellent) Sensory Recovery	Satisfactory (Good-Excellent) Motor Recovery
Age	≤16 y	60.9% (56/92)	66.7% (54/81)
	16–25 y	64.7% (44/68)	63.6% (35/55)
	26–40 y	57.8% (38/66)	60.4% (32/53)
	>40 y	40.9% (18/44)	47.6% (20/42)
	Total (n)	n = 270	n = 231
	Univariate odds ratio per year (95% CI)	0.98 (0.96–0.99), <i>P</i> = 0.02	0.97 (0.96–0.99), <i>P</i> = 0.02
Sex	Male	51.0% (77/151)	55.8% (72/129)
	Female	61.4% (35/57)	73.5% (36/49)
	Total (n)	n = 208	n = 178
	Univariate odds ratio (95% CI), female vs male	1.53 (0.82–2.85), <i>P</i> = 0.18	2.19 (1.06–4.52), <i>P</i> = 0.03
Nerve	Ulnar	52.7% (79/150)	47.5% (56/118)
	Median	57.3% (43/75)	75.0% (39/52)
	Radial	75.6% (34/45)	75.4% (46/61)
	Total (n)	n = 270	n = 231
Univariate	Univariate odds ratio (95% CI), median vs radial	0.44 (0.19–0.99), <i>P</i> < 0.05	0.98 (0.42–2.30), <i>P</i> > 0.05
	Univariate odds ratio (95% CI), ulnar vs radial	0.36 (0.17–0.76), <i>P</i> < 0.05	0.30 (0.15–0.59), <i>P</i> < 0.05
Graft length	No graft	59.4% (63/106)	73.8% (59/80)
	≤30 mm	53.8% (14/26)	48.0% (12/25)
	30–50 mm	39.3% (11/28)	28.9% (11/38)
	>50 mm	18.2% (4/22)	64.9% (37/57)
	Total (n)	n = 182	n = 200
	Univariate odds ratio (95% CI), graft used vs none	0.48 (0.28–0.82), <i>P</i> = 0.01	0.40 (0.22–0.73), <i>P</i> < 0.01
	Univariate odds ratio (95% CI), gap/cm	0.91 (0.83–0.99), <i>P</i> = 0.04	0.93 (0.84–1.03), <i>P</i> = 0.15
Delay	No delay (<24 h)	10/11 (90.9%)	6/7 (85.7%)
	1–30 d	21/36 (58.3%)	56/70 (80.0%)
	1–3 mo	22/30 (73.3%)	23/32 (71.9%)
	3–6 mo	17/39 (43.6%)	18/34 (52.9%)
	6–12 mo	11/24 (45.8%)	5/21 (23.8%)
	>12 mo	25/52 (48.1%)	10/39 (25.6%)
	Total (n)	n = 192	n = 203
	Odds ratio per month (95% CI)	1.00 (0.99–1.01), <i>P</i> = 0.73	0.93 (0.90–0.97), <i>P</i> < 0.01

Table adapted from He et al.³²

be considered within 8 hours of symptom onset.^{129,154} Although the literature indicates that long-term changes may develop within this time window, clinical symptoms must be evaluated on a case-by-case basis. Given the lack of consensus and high-quality data, published timing recommendations should be included as one part of the clinical decision-making process rather than a sole determining factor.

In cases of compressive neuropathy secondary to cyst formation, decompression should be considered within 3 months of symptom onset if the patient's symptoms are minimal and nonprogressive. If symptoms progress rapidly and/or the patient has already incurred significant functional deficits, decompression may be performed acutely.

When treating injuries frequently associated with posttraumatic compressive neuropathy, the potential for compression should be considered when planning initial treatment. For example, in distal radius fractures, different fixation methods have been linked to varying rates of posttraumatic carpal tunnel syndrome.^{133,134}

Given the high variability of postsurgical neuropraxia, even in similar injury/repair patterns, patients with neuropathic symptoms should be closely monitored in the first several weeks postoperatively. At approximately 6 weeks, nerve conduction study (NCS) and electromyography (EMG) may further clarify etiology and serve as a baseline for future comparison if symptoms persist. At this time, surgeons may decide to schedule surgery or continue observation with a possible second NCS/EMG at 12 weeks. Although some have questioned the sensitivity of electrophysiologic testing in chronic carpal tunnel syndrome, the same studies show that symptom severity is significantly associated with positive NCS findings.^{155,156} In cases of acute, traumatic, or postsurgical compression, compartment pressure is often elevated above typical chronic compression values,^{129,135} indicating that NCS/EMG may have greater utility for monitoring suspected neuropathy in acute compression.

Ultimately, multiple modalities must be considered (eg, patient complaints, physical examination, NCS/EMG, radiological studies, and

TABLE 9. Outcomes of Digital Nerve Repair With Varying Delay Times

Author(s)	Mean Time to Repair in Days	Primary Repair	Nerve Graft	Synthetic Conduit	Vein Conduit	Muscle/Muscle-in-Vein	s2PD Mean, mm	m2PD Mean, mm	SWMT Mean
McFarlane and Mayer ¹⁰⁰	170.8		13				14.9		
Hirasawa et al ¹⁰¹	186.1	10	4				7.9	4.7	5.7
Sullivan ¹⁰²	41.02	42					11	5.6	
Walton et al ¹⁰³	61				115			4.5	4.02
Rose et al ¹⁰⁴	256.2						8.3	5.8	
Pereira et al ¹⁰⁵	42.7	24				12	9.4		
Tang et al ¹⁰⁶					16			3.2	
Segalman et al ¹⁰⁷		19					5.5	5.0	3.74
Battiston et al ⁹⁹	112.85			18		13		9.1	
Vipond et al ¹⁰⁸	1						3		
Lohmeyer et al ¹⁰⁹	115.9			12			9.6		
Marcoccio and Vigasio ¹¹⁰						18	10.7	9.2	
Taras et al ¹¹¹	6			22			5.2	5	
Rinker and Laiu ¹¹²	3			36	32		8.4	6.8	
Laveaux et al ¹¹³	1				11		11		
Chen et al ¹¹⁴	24		26				6.7		3.62
Taras et al ¹¹⁵	29		18				7.1	5.4	
Stang et al ¹¹⁶			28				9		
Pilanci et al ¹¹⁷	55.8		12				7.4		3.1
He et al ³²	23.7		100				12.81		3.57
Kim et al ⁹⁷							5.9	5.1	3.81
Rinker et al ¹¹⁸	13		37				7.1	6.7	
Wong et al ¹¹⁹							14.7		5.09
Fakin et al ¹²⁰		93					10.6		2.7
Klein et al ¹²¹	5	81					4		

Table adapted from Kim et al.⁹⁷

nerve blocks) with serial measures to determine the appropriate course of treatment and/or assess recovery.

CHRONIC NERVE COMPRESSION

Compressive neuropathies vary in severity beginning with deterioration of the blood-nerve barrier, followed by subperineurial edema and demyelination, and ending in axonal loss.¹⁵⁴ Although mild cases involving dynamic ischemia may be improved with nonoperative treatment such as therapy, activity modifications, or bracing, patients with a long history of compression may progress to axonal loss.¹⁵⁴ Severity can be confirmed by serial EMG and NCS.¹⁵⁷ Given the progressive nature of severe compression neuropathy,¹⁵⁷ operative intervention is indicated, and early intervention is preferred to avoid further changes in sensation and/or motor weakness and atrophy.

Both duration and severity of symptoms have been shown to impact pain, sensation, and functional outcomes in carpal and cubital tunnel decompression procedures^{158,159} (Tables 10–12).^{158,160,161} Masud et al¹⁵⁷ reported that normal grip strength was not achieved in carpal tunnel procedures performed on patients with symptom duration >6 months. At preoperative symptom duration >12 months, patients in this cohort were more likely to have persisting night pain and a lower rate of return to activities. These findings are consistent with the findings by Eisenhardt et al¹⁶³ in a similar patient population. In a 12-year study of 14,722 patients with carpal tunnel release, Hankins et al¹⁶⁴ suggested that these effects are likely due to the progressive nature of long-term compressive neuropathy.

Although published reports are variable, revision decompression has shown to provide comparable benefits in many outcome dimensions (Tables 13, 14).^{165–175,177,178,181–183,186,188–199} Differences in revision decompression outcomes have not been associated with

duration of symptoms in the literature.²⁰⁰ However, severity of symptoms has been identified as a correlating factor and should be taken into account if recurrent symptoms are rapidly progressing.^{201,202}

Take-Home Messages

In cases of chronic compressive neuropathy, the role of nerve surgery is to address the cause of ongoing symptoms (eg, a peripheral injury that has led to central sensitization). Multiple assessment methods are recommended to evaluate the status of a symptomatic nerve and determine the potential benefit of surgical intervention.

If operative intervention is indicated, it is suggested that nerve decompression procedures be optimally performed within 3 to 6 months of onset of symptoms. If functional deficits, pain, or atrophy are rapidly progressing, acute intervention should be considered. Revision decompression procedures may be planned with considerations for symptom severity speed of symptom progression. Additional preoperative factors that should be considered include the following: age, muscle atrophy, grip strength, electrophysiological severity, tobacco use, body mass index, anemia, depression, chronic lung disease, and inflammatory arthritis (Tables 10–12).^{158,160,161}

BLUNT TRAUMA AND GUNSHOT WOUNDS

In cases of blunt trauma or gunshot wounds, a wait time of 2 to 3 weeks for zone of injury demarcation may be recommended for peripheral nerve repair.⁵ During the time between injury and potential operative intervention, serial physical examinations may be accompanied by EMG and NCS.²⁰³ Once the extent of injury has been determined, treatment should be initiated as early as possible to avoid long-term nervous insufficiency.

TABLE 10. Carpal Tunnel Surgery: Outcomes Predictors Based on SSS and FSS

Variables Predicting Change in SSS					
Predictors	B	SE	P	Standard Coefficient β	95% CI
Age	0.002	0.001	0.134	0.077	-0.001 to 0.004
Duration of symptoms	0.056	0.20	0.007	0.137	0.015-0.096
Electrophysiological severity	0.231	0.016	<0.001	0.767	0.199 to 0.263
Thenar muscle atrophy	-0.003	0.028	0.908	-0.006	-0.58 to 0.052
Model	R	R²	Adjusted R²		
Age, duration of symptoms, electrophysiological severity, thenar muscle atrophy	0.796	0.634	0.624		
Variables Predicting Change in FSS					
Predictors	B	SE	P	Standard Coefficient β	95% CI
Age	0.004	0.002	0.020	0.185	0.001 to 0.008
Duration of symptoms	-0.063	0.030	0.037	-0.165	0.122 to 0.004
Thenar muscle atrophy	0.081	0.039	0.037	0.165	0.005 to 0.157
Model	R	R²	Adjusted R²		
Age, duration of symptoms, thenar muscle atrophy	0.309	0.095	0.077		
All Variables (Including Nonsignificant) Assessed by Alimohammadi et al¹⁵⁹					
Variables	Change Score in SSS	Change Score in FSS	Satisfaction		
Age	$r = -0.196$ $P = 0.016$	$r = 0.226$ $P = 0.005$	$r = -0.193$ $P = 0.017$		
Grip strength	$r = 0.020$ $P = 0.805$	$r = 0.063$ $P = 0.443$	$r = 0.655$ $P < 0.001$		
Thenar muscle atrophy	$z = -3.084$ $P = 0.002$	$z = -1.072$ $P = 0.284$	$z = -1.561$ $P = 0.119$		
Duration of symptom	$\chi^2 = 8.093$ $P = 0.017$	$\chi^2 = 2.638$ $P = 0.267$	$\chi^2 = 0.725$ $P = 0.696$		
Electrophysiological severity	$\chi^2 = 99.786$ $P < 0.001$	$\chi^2 = 2.927$ $P = 0.231$	$\chi^2 = 2.69$ $P = 0.260$		
Involved side	$z = -0.359$ $P = 0.719$	$z = -0.594$ $P = 0.552$	$z = -0.178$ $P = 0.859$		
Phalen test	$z = -1.066$ $P = 0.287$	$z = -1.766$ $P = 0.077$	$z = -0.371$ $P = 0.710$		
Previous carpal injection	$z = 3.881$ $P = 0.275$	$z = 7.50$ $P = 0.067$	$z = 3.861$ $P = 0.277$		
Sex	$z = -0.458$ $P = 0.647$	$z = -1.243$ $P = 0.214$	$z = -0.638$ $P = 0.524$		
BMI	$r = 0.037$ $P = 0.186$	$r = 0.044$ $P = 0.31$	$r = -0.006$ $P = 0.937$		
Smoking	$z = -0.497$ $P = 0.619$	$z = -0.067$ $P = 0.947$	$z = -0.497$ $P = 0.619$		
Hypothyroidism	$z = -1.306$ $P = 0.192$	$z = -0.145$ $P = 0.885$	$z = -0.057$ $P = 0.955$		
Tinel test	$z = -0.859$ $P = 0.390$	$z = -0.531$ $P = 0.595$	$z = -0.423$ $P = 0.672$		
Durkan test	$z = -1.385$ $P = 0.166$	$z = -0.790$ $P = 0.430$	$z = -0.130$ $P = 0.897$		
EMG abnormality	$z = -0.381$ $P = 0.704$	$z = -0.627$ $P = 0.531$	$z = -0.415$ $P = 0.678$		
Monofilament test	$\chi^2 = 0.604$ $P = 0.896$	$\chi^2 = 4.705$ $P = 0.195$	$\chi^2 = 4.780$ $P = 0.189$		

BMI, body mass index; FSS, Functional Status Scale; SSS, Symptom Severity Scale.

Table adapted from Alimohammadi et al.¹⁵⁹

TABLE 11. Outcomes Predictors for in Situ Ulnar Nerve Decompression

Variable	Unsatisfactory Group (n = 27)	Satisfactory Group (n = 208)	P
Age (y)	54.1 ± 11.3	53.2 ± 10.6	0.681
Sex			0.83
Male	17	137	
Female	10	71	
BMI, kg/m ²	24.1 ± 3.1	23.5 ± 2.7	0.287
Tobacco use			0.649
Yes	6	59	
No	21	149	
Alcohol use			0.614
Yes	4	42	
No	23	166	
Hypertension			0.438
Yes	7	39	
No	20	169	
Diabetes mellitus			0.748
Yes	2	23	
No	25	185	
Disease duration, mo	17.1 ± 6.7	13.8 ± 7.4	0.029
Preoperative severity			0.004
Severe	25	137	
Not severe	2	71	
MCV, m/s	28.2 ± 10.5	34.1 ± 12.8	0.023
SCV, m/s	23.4 ± 11.7	27.6 ± 8.4	0.021

Multivariate Regression Analysis of Risk Factors for Poor Recovery

Variable	Odds Ratio	95% CI	P
Disease duration ≥12 mo	2.14	0.75–6.16	0.156
Severe preoperative symptoms	3.06	2.16–4.32	<0.001
MCV, m/s	1.22	0.87–1.72	0.248
SCV, m/s	1.04	0.68–1.58	0.863

BMI, body mass index; MCV, motor conduction velocity; SCV sensory conduction velocity.

Table adapted from Kong et al.¹⁶⁰

Although penetrating wounds have historically been treated via delayed exploration, there is no clear consensus for optimal timing of exploration and repair.^{34,204} Advocates of early exploration point to improved outcomes and shorter graft length requirements for early exploration, which may be attributable to avoiding dense scar tissue formation and intraneural edema (by performing early epineural release), as well as preventing retraction by suturing to local structures.^{72,74,82,205,206} Histologic data also support a favorable regenerative environment in the acute setting.^{10,207} At this time, clinical data remain inconclusive, and a risk-benefit analysis is necessary to determine the optimal course of treatment for each patient.

Take-Home Messages

If the zone of injury is clearly established, immediate exploration may be warranted. In these cases, the decision to explore immediately or wait is ultimately subject to clinical judgment and individual patient/injury characteristics. When the zone of injury is unclear, a wait time of 2 to 3 weeks is recommended.

CHRONIC PAIN DUE TO NERVE INJURY-INDUCED PAINFUL NEUROMA

The term “chronic pain” can be misleading, and the need for timely surgical intervention is often mistakenly dismissed in these cases. Such delays and assumptions can lead to significant impairment and/or inability to return to work and may have even more devastating outcomes, especially if suicidal ideation is present.^{25,208–212} Although a variety of treatment options are currently used for pain secondary to neuroma formation, most are focused on treatment of symptoms. Nonsurgical or symptomatic treatments are often unsuccessful, as they fail to address the root cause of pain.^{210,213} When pain persists despite reasonable treatment via supportive symptomatic modalities, surgical intervention targeting the source of the pain is indicated.^{209,214}

Take-Home Messages

If chronic pain persists 3 to 6 months after nerve injury, it is recommended that surgical exploration/treatment be electively scheduled, with patient goals and rate of symptom progression taken into consideration. Although the literature is unclear regarding exact timing,

TABLE 12. Risk Factors for Postoperative Infection Following Open Cubital Tunnel Release

Variable	Odds Ratio	95% CI	P
Significant risk factors for infection after open cubital tunnel release			
Demographics			
Age <65 y	2.08	1.52–2.85	<0.001
Tobacco use	1.65	1.31–2.07	<0.001
Body mass index, kg/m ²			
30–40 (obesity)	1.52	1.18–1.94	<0.001
≥40 (morbid obesity)	1.53	1.16–2.01	0.002
Male sex	1.32	1.07–1.63	0.008
Comorbidity			
Hemodialysis use	2.47	1.19–5.16	0.016
Chronic anemia	2.24	1.72–2.90	<0.001
Inflammatory arthritis	1.43	1.08–1.88	0.012
Depression	1.36	1.09–1.70	0.007
Hyperlipidemia	1.33	1.00–1.76	0.049
Chronic lung disease	1.29	1.04–1.60	0.022
Factors not increasing the risk for infection after open cubital tunnel release			
Demographics			
Low body mass index (<19 kg/m ²)	0.97	0.31–3.07	0.962
Comorbidity			
Hypercoagulable state	1.16	0.78–1.72	0.459
Alcohol abuse	1.12	0.83–1.50	0.468
Diabetes mellitus	1.08	0.87–1.34	0.507
Chronic kidney disease	1.06	0.81–1.40	0.675
Peripheral vascular disease	1.06	0.82–1.39	0.648
Hypothyroidism	1.05	0.84–1.31	0.668
Hypertension	1.03	0.75–1.41	0.852
Chronic liver disease	1.01	0.75–1.36	0.942
Congestive heart failure	0.82	0.63–1.08	0.159
Coronary artery disease	0.77	0.61–0.97	0.011

Table adapted from Camp et al.¹⁶¹

TABLE 13. Primary Versus Revision Cubital Tunnel Syndrome

	Primary	Revisions	P
Final subjective symptoms according to patient group			
Relief after primary surgery	27 (96%)	14 (50%)	<0.001
Relief after revision surgery	—	22 (79%)	
Symptoms currently	22 (79%)	24 (85%)	0.48
• Paresthesias	17 (61%)	20 (71%)	0.39
Symptoms constant, intermittent, or absent			0.03
• Constant	5 (18%)	15 (53%)	
• Intermittent	17 (61%)	9 (32%)	
• Absent	6 (21%)	4 (15%)	
Physical examination findings according to patient group			
Elbow extension, °	2 (0–20)	12 (0–35)	<0.001
Elbow flexion, °	142 (120–145)	137 (125–150)	0.09
Positive Tinel sign	15 (54%)	14 (50%)	0.79
Nerve tender at elbow	4 (14%)	12 (43%)	0.02
1st DI strength (out of 5)	4.5 (2–5)	4.4 (3–5)	0.87
Grip strength, kg	33 (11–54)	28 (8–63)	0.13
Key pinch strength, kg	8 (4–15)	5 (3–16)	0.03
Ring/little finger 2-point discrimination, mm	6 (5–15)	7 (6–15)	0.02
Wartenberg sign	2 (7%)	9 (32%)	0.02
Froment sign	4 (14%)	7 (25%)	0.31
McGowan grading according to patient group			
Final McGowan grade			0.01
0	10 (36%)	6 (21%)	
I	12 (43%)	5 (18%)	
IIA	2 (7%)	12 (43%)	
IIB	3 (11%)	3 (11%)	
III	1 (3%)	2 (7%)	
Change in McGowan grade after surgery			0.003
Improved	18 (64%)	7 (25%)	
No change	8 (29%)	15 (54%)	
Worse	2 (7%)	6 (21%)	

Table adapted from Aleem et al.¹⁶⁴

increased duration of symptoms has been associated with unfavorable outcomes.²¹⁰

If a patient presents with uncontrolled pain that is severe, progressing, or incapacitating despite nonoperative management, acute exploration/intervention should be considered. Ultimately, intervention must be determined using clinical judgment for each patient regardless of whether pain has persisted for 3 months.

ADDITIONAL REPAIR CONSIDERATIONS

In addition to timing of repair, factors may play a role in both planning the operative case and the repair methodology used. Availability of personal protective equipment, sterile surgical supplies, anesthesia supplies, and staffing will influence the ability to achieve appropriate timing in nerve repair. Exposure risks for the both the clinical team and patient should also be taken into consideration. Scope and scale or exposure risks should not be limited to just the surgery, but should include efforts to minimize recovery room time, days of hospitalization, rehabilitation, and any steps that can be appropriately taken to reduce staging of procedures and the overall episodes of care.

There is evidence to support a variety of reconstructive options. Optimal treatment is determined using available clinical data on safety, efficacy, and utility. Common repair methods for peripheral nerve

injuries include direct suture, autograft, allograft, conduit, or nerve transfer (Fig. 4). In addition to clinical outcomes data, additional factors should be considered for each approach, including:

1. Ability to achieve a tension-free repair
2. Operative time required for each repair approach
3. Ability to reduce anesthesia acuity and duration
 - a. For example, although local regional anesthesia and monitored anesthesia care carry less risk of airway irritation, they may increase aerosol production (and viral spread in the present scenario) compared with tracheal intubation or laryngeal mask airway. Patient risk and the risk of viral spread should be discussed with an anesthesiologist.
4. Management of nerve gap (Fig. 4)^{95,124,215–217}
5. Ability to reduce resource utilization by performing a single surgery versus staged reconstruction
 - a. Insurance, socioeconomic status, and likelihood of returning for secondary procedures should be considered.
6. Management plan for concomitant injuries/procedures
7. Extent and timing of rehabilitative plan
8. Proximity to a tertiary referral center and/or available transportation

Each of these factors plays a role in resource utilization, ability to schedule the procedure, and exposure risk to the patient and clinical teams. Patient desires may not always align with scientific evidence

TABLE 14. Outcomes After Revision Carpal Tunnel Surgery

Recurrent or persistent CTS	Study	Level of Evidence	No. of Hands	Method/Follow-Up	Resolved or Improved, n (%)	Complications and Patient-Reported Outcomes
Endoscopic revision CTR	Teoh and Tan ¹⁶⁵	IV Retrospective	9	Endoscopic revision 24-mo avg follow-up	9 (100)	0 complications PRO: NR
	Luria et al ¹⁶⁶	IV Prospective	41	Endoscopic revision 12-mo follow-up (all)	37 (90)	0 complications CTSS improved from 3.3 to 2.0* CTSFSS improved from 3.1 to 2.1* UWSS improved from 68 to 86* Mean RTW 25 d
Open revision CTR and neurolysis	Total	IV	50	External neurolysis	46 (92)	0 (0%) complications Complications: NR
	Langlois and Linscheid ¹⁶⁷	IV Retrospective	33	External neurolysis 24-mo avg follow-up	28 (85)	Complications: NR PRO: NR
Open revision CTR and neurolysis	Wadstroem and Nigst ¹⁶⁸	IV Retrospective	27	External and internal neurolysis	22 (81)	NA
	O'Malley et al ¹⁶⁹	IV Retrospective	20	External neurolysis 31-mo avg follow-up	12 (60)	1 superficial wound infection 1 RSD PRO: NR
Open revision CTR and neurolysis	Chang and Dellon ¹⁷⁰	IV Retrospective	35	External and internal neurolysis	29 (83)	Complications: NR PRO: NR
	Cobb et al ¹⁷¹	IV Retrospective	131	External and internal neurolysis 23.5-mo avg follow-up	87 (66)	9 delayed wound healing 4 postoperative infections 3 RSD Mean RTW 7.8 wk Mean RTA 8 wk NA
Open revision CTR and neurolysis	Duclos and Sokolow ¹⁷²	IV Retrospective	13	External neurolysis 27.5-mo avg follow-up	12 (92)	NA
	Hulsizer et al ¹⁷³	IV Retrospective	30	External neurolysis 30-mo avg follow-up	18 (60)	Complications: NR PRO: NR
Open revision CTR and neurolysis	Forman et al ¹⁷⁴	IV Retrospective	22	External neurolysis 19-mo avg follow-up	21 (95)	2 scar tenderness and stiffness PRO: NR
	Beck et al ¹⁷⁵	III Retrospective	28	External neurolysis 12-mo avg follow-up	23 (82)	Complications: NR Mean DASH 29 at follow-up
Vein wrap	Total	IV	339	Saphenous vein wrap 18-mo avg follow-up	252 (74)	20 (6%) complications 1 transient venous insufficiency PRO: NR
	Sotereanos et al ⁶ Sotereanos and Xu ¹⁷⁷	IV Retrospective	6	Saphenous vein wrap 18-mo avg follow-up	6 (100)	1 transient local swelling at leg PRO: NR
Synthetic wrap	Varitimidis et al ¹⁷⁸	IV Retrospective	15	Saphenous vein wrap 43-mo avg follow-up	15 (100)	2 (10%) complications, transient Complications: NR PRO: NR
	Total	IV	21	Collagen synthetic wrap 13.7-mo avg follow-up	21 (100)	8 (39%) complications, transient Complications: NR PRO: NR
Synthetic wrap	Soltani et al ¹⁷⁹	IV Retrospective	9	Collagen synthetic wrap 19-mo avg follow-up	8 (89)	0 complications PRO: NR
	Kokkalis et al ¹⁸⁰	IV Retrospective	2	Collagen synthetic wrap 24-mo avg follow-up	2 (100)	0 complications
Synthetic wrap	Kokkalis et al ¹⁸¹	IV Retrospective	10	Collagen synthetic wrap 24-mo avg follow-up	10 (100)	0 complications
	Total	IV Retrospective	21	Collagen synthetic wrap 24-mo avg follow-up	21 (95)	0 (0%) complications

Continued next page

TABLE 14. Outcomes After Revision Carpal Tunnel Surgery

	Study	Level of Evidence	No. of Hands	Method/Follow-Up	Resolved or Improved, n (%)	Complications and Patient-Reported Outcomes
Recurrent or persistent CTS	Hypothenar fat flap	IV Retrospective	62	Hypothenar fat flap (62) + internal neurolysis (7) 33-mo avg follow-up	55 (89)	1 ulnar digital nerve paresthesias 1 hypothenar numbness 1 superficial cellulitis Mean RTW 37 wk (work comp) Mean RTW 12 wk (nonwork comp) NA
		IV Retrospective	9	Hypothenar fat flap	8 (89)	
		IV Retrospective	45	Hypothenar fat flap 45 mo median follow-up	43 (96)	2 scar pain and edema, transient PRO: NR 100% RTW
		IV Retrospective	28	Hypothenar fat flap 10.5-mo avg follow-up	26 (93)	Complications: NR
		III Retrospective comparative	11	Hypothenar fat flap 11-mo avg follow-up	8 (73)	PRO: NR 2 hypertrophic scar DASH 31 at follow-up
		IV Retrospective	20	Hypothenar fat flap 6 mo minimum follow-up	18 (90)	16 two-point discrimination resolved to normal DASH improved significantly in all patients
		IV Retrospective	27	Hypothenar fat flap 22-mo avg follow-up	24 (89)	Complications: NR
		IV Retrospective	18	Hypothenar fat flap 22-mo avg follow-up	16 (89)	PRO: NR
		IV Prospective	34	Hypothenar fat flap 24 mo minimum follow-up 60 mo follow-up in 13 patients	34 (100)	2 hypertrophic scar DASH 42.2 to 17.6 ($P < 0.01$) VAS decreased from 6.4 to 1.4 ($P < 0.05$) Grip strength improved from 72% to 86% of the contralateral side ($P < 0.05$) QuickDASH 60.7 to 19.8 ($P < 0.05$)
		Total	254		232 (91)	9 (4%) complications
Synovial flap		IV Retrospective	27	Synovial flap Follow-up range 1 mo to 14 y	25 (93)	NA
		III Retrospective comparative	16	Synovial flap 11-mo avg follow-up	9 (56)	1 delayed wound healing DASH 37 at follow-up
		IV Retrospective	45	Synovial flap 11-mo avg follow-up	43 (96)	1 scar pain PRO: NR
		Total	88		77 (88)	2 (2%) complications

Multiple surgical methods (outcomes not reported separately)	Strasberg et al ¹⁹³	IV Retrospective	45	External and internal neurolysis Median nerve release forearm Ulnar nerve submuscular transposition Median nerve repair Common dig nerve graft Abductor muscle flap 31-mo avg follow-up	24 (53)	Complications: NR PRO: NR
	Varitimidis et al ¹⁹⁴	IV Retrospective	24	External neurolysis alone (7) Hypothenar flap (15) Saphenous vein wrap (1) Neurothraphy and hypothenar flap (1) 19-mo avg follow-up	24 (100)	Complications: NR RTW 92%
	Jones et al ¹⁹⁵	IV Retrospective	55	External neurolysis (41) Epineurectomy (15) Synovial or hypothenar flap (8) Reverse radial forearm flap (3) Minimum 1 year follow-up Avg follow-up NR	45 (82)	Complications: NR PRO: NR
Recurrent or persistent CTS	Zieske et al ¹⁹⁶	III Retrospective	97 Persistent (42) Recurrent (19) New (36)	External neurolysis (97) Internal neurolysis (NA) Ulnar tunnel release (63) Proximal median n release (7) Median n reconstruction (6) Ulnar n reconstruction (3) Opponensplasty (2) Hypothenar flap (22) 3.4-4.1 mo follow-up dependent on subgroup	NR	All groups had decreases in VAS pain scores postop Persistent and new subgroups had improvement in pinch and grip strength postop Recurrent subgroup had a higher prevalence of diabetes and did not have significant change in postoperative grip or pinch
	Djerbi et al ¹⁹⁷	IV Retrospective	38	Neurolysis (22) Hypothenar fat flap (11) Pronator quadratus flap (1) Synovial flap (2) Vein wrap (1) Silicone sheet (1) 51-mo avg follow-up	26 (68)	Complications: NR DASH 35 if no fibrosis present at revision surgery DASH 28.7 if perineural fibrosis present at revision surgery DASH 58.6 if perineural and intraneural fibrosis present at revision surgery
	Total		162		119 (73)	

*P < 0.01.

Avg, average; CTR, carpal tunnel release; CTS, carpal tunnel syndrome; CTSFSS, Carpal Tunnel Syndrome Functional Status Score; CTSSS, Carpal Tunnel Syndrome Severity Score; DASH, Disabilities of the Arm, Shoulder, and Hand Score; NA, not available; NR, not reported; PRO, patient self-reported outcomes, validated outcomes include DASH, PRWE, RSD, reflex sympathetic dystrophy (ie, chronic regional pain syndrome); RTA, return to recreational activities; RTW, return to work; UWSS, University of Washington patient satisfaction score; VAS, visual analog scale.

Table adapted from Lauder et al.¹⁹⁸

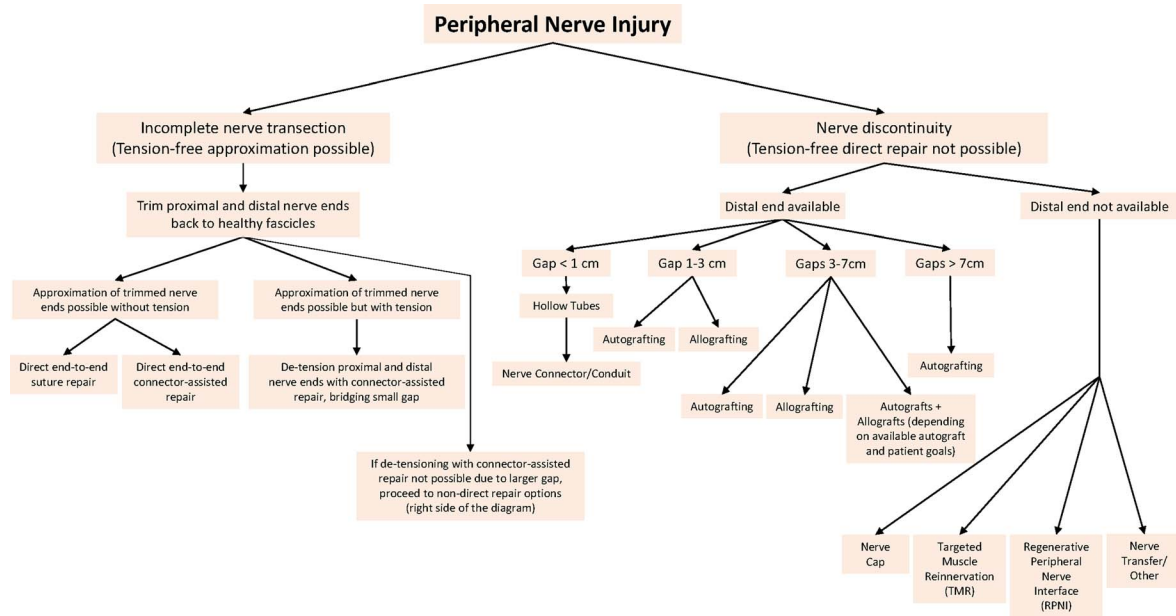


FIGURE 4. Management of peripheral nerve transection. [full color online](#)

TABLE 15. Medically Necessary, Time-Sensitive Procedures

Procedure Factors	1	2	3	4	5	Score (1-5)
OR time, min	<30	30-60	60-120	120-180	≥180	
Estimated length of stay	Outpatient	23 h	24-48 h	≤3 d	>4 d	
Postoperative ICU need, %	Very unlikely	<5	5-10	10-25	≥25	
Anticipated blood loss, cc	<100	100-250	250-500	500-750	≥75	
Surgical team size	1	2	3	4	>4	
Intubation probability	≤1%	1%-5%	5%-10%	10%-25%	≥25%	
Surgical site	None of the following	Abdominopelvic MIS surgery	Abdominopelvic open surgery, infraumbilical	Abdominopelvic open surgery, supraumbilical	OHNS/upper GI/thoracic	
Disease factors	1	2	3	4	5	Score (1-5)
Nonoperative treatment option effectiveness	None available	Available, <40% as effective as surgery	Available, 40%-60% as effective as surgery	Available, 60%-95% as effective as surgery	Available, equally effective	
Nonoperative treatment option resource/exposure risk	Significantly worse/not applicable	Somewhat worse	Equivalent	Somewhat better	Significantly better	
Impact of 2-wk delay in disease outcome	Significantly worse	Worse	Moderately worse	Slightly worse	No worse	
Impact of 2-wk Delay in surgical difficulty/risk	Significantly worse	Worse	Moderately worse	Slightly worse	No worse	
Impact of 6-wk delay in disease outcome	Significantly worse	Worse	Moderately worse	Slightly worse	No worse	
Impact of 6-wk delay in surgical difficulty/risk	Significantly worse	Worse	Moderately worse	Slightly worse	No worse	
Patient factors	1	2	3	4	5	Score (1-5)
Age, y	<20	20-40	40-50	50-65	>65	
Lung disease (asthma, COPD, CF1)	None			Minimal (rare inhaler)	>Minimal	
Obstructive sleep apnea	Not present			Mild/Moderate (no CPAP)	On CPAP	
CV disease (HTN, CHF, CAD)	None	Minimal (no meds)	Mild (≤1 med)	Moderate (2 meds)	Severe (≥3 meds)	
Diabetes	None		Mild (no meds)	Moderate (PO meds only)	>Moderate (insulin)	
Immunocompromised ²	No			Moderate	Severe	
ILI3 Sx's (fever, cough, sore throat, body aches, diarrhea)	None, asymptomatic				Yes	
Exposure to known COVID-19-positive person in the past 14 d	No	Probably not	Possibly	Probably	Yes	
Total Score:						

Each row is scored, and all scores are added to produce a cumulative score (range, 21-105). A higher total score is associated with poorer perioperative outcomes, increased COVID-19 transmission, and/or increased hospital resource requirements.

CAD, coronary artery disease; CHF, congestive heart failure; CV, cardiovascular; COPD, chronic obstructive pulmonary disease; HTN, hypertension; ICU, intensive care unit.

Table adapted from Prachand et al.¹

TABLE 16. MeNTS Possible Score Ranges for Common Nerve Procedures

Procedure Factors	Sharp Laceration of Digital Nerve	Ulnar Elbow (MM)		Carpal Tunnel	Neuroma (Palmar Nerve)
OR time	1–2	2–3		1	2
Estimated length of stay	1	1		1	1
Postoperative ICU need	1	1		1	1
Anticipated blood loss	1	1		1	1
Surgical team size	4	4		4	4
Intubation probability	1	1		1	1
Surgical site	1	1		1	1
Disease factors					
Nonoperative treatment, pain medication	2	1		2	2
Nonoperative treatment, pain medication	5	1		5	5
Impact of 2-wk delay End-organ viability, painful neuroma formation, amount of scarring in the nerve results in more trimming and longer gap	3	3		5	3
Impact of 2-wk delay Adhesions, ability to find distal stump	2	2		5	5
Impact of 6-wk delay End-organ viability, painful neuroma formation	2	1		4	3
Impact of 6-wk delay Adhesions, ability to find distal stump	2	2		5	5
Score (+ possible scores from factors below)	27 (+8 → 40)	22 (+8 → 40)		36 (+8 → 40)	34 (+8 → 40)
Patient factors	1	2	3	4	5
Age, y	<20	20–40	40–50	50–65	>65
Lung disease (asthma, COPD, CF1)	None			Minimal (rare inhaler)	> Minimal
Obstructive sleep apnea	Not present			Mild/moderate (no CPAP)	On CPAP
CV disease (HTN, CHF, CAD)	None	Minimal (no meds)	Mild (≤1 med)	Moderate (2 meds)	Severe (≥3 meds)
Diabetes	None		Mild (no meds)	Moderate (PO meds only)	>Moderate (insulin)
Immunocompromised ²	No			Moderate	Severe
ILI3 Sx's (fever, cough, sore throat, body aches, diarrhea)	None, asymptomatic				Yes
Exposure to known COVID-19–positive person in the past 14 d	No	Probably not	Possibly	Probably	Yes
Nerve Procedures	Sharp Laceration of Digital Nerve	Ulnar Elbow (MM)		Carpal Tunnel	Neuroma (Palmar Nerve)
Total MeNTS score range	35–67	30–62		44–76	42–74

A higher total score is associated with poorer perioperative outcomes, increased COVID-19 Transmission, and/or increased hospital resource requirements.

CAD, coronary artery disease; CHF, congestive heart failure; CPAP, continuous positive airway pressure; CV, cardiovascular; COPD, chronic obstructive pulmonary disease; HTN, hypertension; ICU, intensive care unit; MeNTS, Medically Necessary, Time-Sensitive Procedures; PO, per os (oral administration).

for optimal timing. In practice, decisions are made by engaging patients in an informed discussion of near- and long-term goals of recovery, as well as how these may be affected by different treatment options. Developing a shared understanding of the factors listed previously is crucial when creating a management plan and determining appropriate repair methods.

DISCUSSION

Appropriate timing of repair is a key consideration for the management of patients with nerve injuries. Injuries to peripheral nerves initiate a series of regenerative and degenerative processes. When these processes fail to proceed in a synchronous, organized manner, neuroma formation and/or nervous deficiency may occur, both of which are progressive in nature.²¹⁸ Untreated nerve injuries can result in serial remodeling in the sensorimotor, frontoparietal, and executive control networks.²¹⁹

Postinjury neuropathic pain has been linked to adverse cortical changes and psychosocial factors such as pain catastrophizing.²²⁰ Successful nerve procedures can improve or eliminate neuropathic pain symptoms as well as restore connectivity in the brain's sensorimotor and salience networks.^{219,221} Timely intervention may reduce the risk of patients progressing to dependence on narcotics or neuromodulators.²²²

As a critical component of the nerve treatment algorithm, the issue of timing must be addressed to optimize outcomes. A concise view of relevant clinical data may assist physicians making decisions and advocating for the appropriate timing of intervention for patients. Although most of the existing recommendations are too broad to be useful in a clinical setting with high variability between cases, Prachand et al¹ recently proposed a scoring system that integrates procedure, disease, and patient factors to justify the scheduling of

procedures (Table 15). This system provides a template that may be adapted to subspecialties. As a thought experiment, we scored four common nerve procedures using an adapted version of Prachand's scale to briefly assess whether their Medically Necessary, Time-Sensitive procedure scale may be applicable in nerve practice (Table 16). Preliminary analysis shows some promise in nerve procedures, and further research is needed to determine the utility of this scoring system.

In the case of the COVID-19 pandemic, the initial response of many institutions was to cancel or reschedule all "elective" surgeries. Unfortunately, many nerve surgeries must be performed within a critical time window to avoid permanent sensory and/or functional deficits. Postponing these serious but nonemergency cases can result in rescheduled surgeries performed in a more unfavorable environment if ideal conditions do not materialize within the time frame for effective operative intervention. In routine practice conditions, procedures are often delayed because of inopportune surrounding circumstances such as patients' work or social commitments. When planning surgery with patients, the appropriate data must be used to weigh potential risks of delaying treatment.

Crisis scenarios can be a catalyst but are not the focus of discussions surrounding optimal treatment algorithms. Timing decisions are always critical to patient outcomes and are made by surgeons daily, regardless external circumstances. Although the current literature remains limited in many situations, the authors believe this review serves as a suitably condensed resource to allow surgeons to make educated assessments for individual patients with any type of nerve pathology. Although further investigation will be necessary to parse out nuances in clinical decision making, the authors believe that these data will allow physicians to better advocate for patients regarding the timing of nerve procedures and may ultimately lead to more optimal outcomes.

REFERENCES

- Prachand VN, Milner R, Angelos P, et al. Medically necessary, time-sensitive procedures: scoring system to ethically and efficiently manage resource scarcity and provider risk during the COVID-19 pandemic. *J Am Coll Surg*. 2020;231:281–288.
- Giorgadze T, Rukhadze R, Giorgadze S, et al. Quantitative changes of schwann and mast cells in the process of peripheral nerve regeneration. *Georgian Med News*. 2010;188:84–88.
- Dahlin LB. The role of timing in nerve reconstruction. *Int Rev Neurobiol*. 2013;109:151–164.
- Müller-Vahl H. Traumatic nerve damage: causes, approaches and prognosis. *Nervenarzt*. 2015;86:142–150.
- Moore AM, Wagner II, Fox IK. Principles of nerve repair in complex wounds of the upper extremity. *Semin Plast Surg*. 2015;29:40–47.
- Höke A. Mechanisms of disease: what factors limit the success of peripheral nerve regeneration in humans? *Nat Clin Pract Neurol*. 2006;2:448–454.
- Gordon T. The physiology of neural injury and regeneration: the role of neurotrophic factors. *J Commun Disord*. 2010;43:265–273.
- Gordon T, Tyreman N, Raji MA. The basis for diminished functional recovery after delayed peripheral nerve repair. *J Neurosci*. 2011;31:5325–5334.
- Fu SY, Gordon T. Contributing factors to poor functional recovery after delayed nerve repair: prolonged denervation. *J Neurosci*. 1995;15(5 pt 2):3886–3895.
- Jonsson S, Wiberg R, McGrath AM, et al. Effect of delayed peripheral nerve repair on nerve regeneration, Schwann cell function and target muscle recovery. *PLoS One*. 2013;8:e56484.
- Palispis WA, Gupta R. Surgical repair in humans after traumatic nerve injury provides limited functional neural regeneration in adults. *Exp Neurol*. 2017;290:106–114.
- Sulaiman OA, Gordon T. Effects of short- and long-term Schwann cell denervation on peripheral nerve regeneration, myelination, and size. *Glia*. 2000;32:234–246.
- Ronchi G, Cillino M, Gambarotta G, et al. Irreversible changes occurring in long-term denervated Schwann cells affect delayed nerve repair. *J Neurosurg*. 2017;127:843–856.
- Terenghi G, Hart A, Wiberg M. The nerve injury and the dying neurons: diagnosis and prevention. *J Hand Surg Eur Vol*. 2011;36:730–734.
- Navarro X. Chapter 27: neural plasticity after nerve injury and regeneration. *Int Rev Neurobiol*. 2009;87:483–505.
- Navarro X, Vivó M, Valero-Cabré A. Neural plasticity after peripheral nerve injury and regeneration. *Prog Neurobiol*. 2007;82:163–201.
- Zink PJ, Philip BA. Cortical plasticity in rehabilitation for upper extremity peripheral nerve injury: a scoping review. *Am J Occup Ther*. 2020;74:7401205030p1–7401205030p15.
- Rosén B, Chemnitz A, Weibull A, et al. Cerebral changes after injury to the median nerve: a long-term follow up. *J Plast Surg Hand Surg*. 2012;46:106–112.
- Gordon T. Nerve regeneration: understanding biology and its influence on return of function after nerve transfers. *Hand Clin*. 2016;32:103–117.
- Fu SY, Gordon T. Contributing factors to poor functional recovery after delayed nerve repair: prolonged axotomy. *J Neurosci*. 1995;15(5 pt 2):3876–3885.
- Novak CB, Mackinnon SE. Evaluation of nerve injury and nerve compression in the upper quadrant. *J Hand Ther*. 2005;18:230–240.
- Lequint T, Naito K, Awada T, et al. Ulnar nerve transposition using a mini-invasive approach: case series of 30 patients. *J Hand Surg Eur Vol*. 2013;38:468–473.
- Domeshek LF, Krauss EM, Snyder-Warwick AK, et al. Surgical treatment of neurotomas improves patient-reported pain, depression, and quality of life. *Plast Reconstr Surg*. 2017;139:407–418.
- Ido Y, Uchiyama S, Nakamura K, et al. Postoperative improvement in DASH score, clinical findings, and nerve conduction velocity in patients with cubital tunnel syndrome. *Sci Rep*. 2016;6:–27497.
- Guse DM, Moran SL. Outcomes of the surgical treatment of peripheral neurotomas of the hand and forearm: a 25-year comparative outcome study. *Ann Plast Surg*. 2013;71:654–658.
- Dumont CE, Alnot JY. Proximal median and ulnar resections. Results of primary and secondary repairs. *Rev Chir Orthop Reparatrice Appar Mot*. 1998;84:590–599.
- Novak CB, Anastakis DJ, Beaton DE, et al. Patient-reported outcome after peripheral nerve injury. *J Hand Surg Am*. 2009;34:281–287.
- Bergmeister KD, Große-Hartlage L, Daeschler SC, et al. Acute and long-term costs of 268 peripheral nerve injuries in the upper extremity. *PLoS One*. 2020;15:e0229530.
- Basar H, Basar B, Erol B, et al. Comparison of ulnar nerve repair according to injury level and type. *Int Orthop*. 2014;38:2123–2128.
- Zeineldin A, Mohammed M, Elhoseny A. Comparative study between primary versus delayed peripheral nerve repair after various types of injury. *Menoufia Med J*. 2015;28:80–86.
- Schneider M, Antoniadis G. Traumatic peripheral nerve lesions: diagnosis and treatment. *Chirurg*. 2019;90:941–954.
- He B, Zhu Z, Zhu Q, et al. Factors predicting sensory and motor recovery after the repair of upper limb peripheral nerve injuries. *Neural Regen Res*. 2014;9:661–672.
- Kabak S, Halici M, Baktir A, et al. Results of treatment of the extensive volar wrist lacerations: 'the spaghetti wrist'. *Eur J Emerg Med*. 2002;9:71–76.
- Secer HI, Daneyemez M, Tehli O, et al. The clinical, electrophysiologic, and surgical characteristics of peripheral nerve injuries caused by gunshot wounds in adults: a 40-year experience. *Surg Neurol*. 2008;69:143–152; discussion 152.
- Barrios C, Amillo S, de Pablos J, et al. Secondary repair of ulnar nerve injury. 44 cases followed for 2 years. *Acta Orthop Scand*. 1990;61:46–49.
- Barrios C, de Pablos J. Surgical management of nerve injuries of the upper extremity in children: a 15-year survey. *J Pediatr Orthop*. 1991;11:641–645.
- Birch R, Raji AR. Repair of median and ulnar nerves. Primary suture is best. *J Bone Joint Surg Br*. 1991;73:154–157.
- Novak CB, Mackinnon SE, Kelly L. Correlation of two-point discrimination and hand function following median nerve injury. *Ann Plast Surg*. 1993;31:495–498.
- Vastamäki M, Kallio PK, Solonen KA. The results of secondary microsurgical repair of ulnar nerve injury. *J Hand Surg Br*. 1993;18:323–326.
- Kallio PK, Vastamäki M, Solonen KA. The results of secondary microsurgical repair of radial nerve in 33 patients. *J Hand Surg Br*. 1993;18:320–322.
- Deutinger M, Girsch W, Burggasser G, et al. Peripheral nerve repair in the hand with and without motor sensory differentiation. *J Hand Surg Am*. 1993;18:426–432.
- Kallio PK, Vastamäki M. An analysis of the results of late reconstruction of 132 median nerves. *J Hand Surg Br*. 1993;18:97–105.
- Calder JS, Norris RW. Repair of mixed peripheral nerves using muscle autografts: a preliminary communication. *Br J Plast Surg*. 1993;46:557–564.
- Lundborg G, Rosén B, Dahlin L, et al. Tubular versus conventional repair of median and ulnar nerves in the human forearm: early results from a prospective, randomized, clinical study. *J Hand Surg Am*. 1997;22:99–106.
- Joshi N, Mir X, Busquets R, et al. Contralateral median nerve autograft. *Acta Orthop Belg*. 1995;61:323–326.
- Trumble TE, Kahn U, Vanderhooff E, et al. A technique to quantitate motor recovery following nerve grafting. *J Hand Surg Am*. 1995;20:367–372.
- Nunley JA, Saies AD, Sandow MJ, et al. Results of interfascicular nerve grafting for radial nerve lesions. *Microsurgery*. 1996;17:431–437.
- Hudson DA, Bolitho DG, Hodgetts K. Primary epineurial repair of the median nerve in children. *J Hand Surg Br*. 1997;22:54–56.

49. Lundborg G, Rosen B, Abrahamson SO, et al. Tubular repair of the median nerve in the human forearm. Preliminary findings. *J Hand Surg Br.* 1994;19:273–276.
50. Taha A, Taha J. Results of suture of the radial, median, and ulnar nerves after missile injury below the axilla. *J Trauma.* 1998;45:335–339.
51. Kato H, Minami A, Kobayashi M, et al. Functional results of low median and ulnar nerve repair with intraneural fascicular dissection and electrical fascicular orientation. *J Hand Surg Am.* 1998;23:471–482.
52. Braga-Silva J. The use of silicone tubing in the late repair of the median and ulnar nerves in the forearm. *J Hand Surg Br.* 1999;24:703–706.
53. Bolitho DG, Boustred M, Hudson DA, et al. Primary epineurial repair of the ulnar nerve in children. *J Hand Surg Am.* 1999;24:16–20.
54. Osborne AW, Birch RM, Munshi P, et al. The musculocutaneous nerve. *J Bone Joint Surg Br.* 2000;82:1140–1142.
55. Wiedeman JE, Zierold D, Klink BK. Machete injuries in Haiti. *Mil Med.* 2001;166:1023–1025.
56. Merrell GA, Barrie KA, Katz DL, et al. Results of nerve transfer techniques for restoration of shoulder and elbow function in the context of a meta-analysis of the English literature. *J Hand Surg Am.* 2001;26:303–314.
57. Kim DH, Kam AC, Chandika P, et al. Surgical management and outcome in patients with radial nerve lesions. *J Neurosurg.* 2001;95:573–583.
58. Shergill G, Bonney G, Munshi P, et al. The radial and posterior interosseous nerves. Results of 260 repairs. *J Bone Joint Surg Br.* 2001;83:646–649.
59. Rosén B, Lundborg G. The long term recovery curve in adults after median or ulnar nerve repair: a reference interval. *J Hand Surg Br.* 2001;26:196–200.
60. Ozkan T, Ozer K, Gulgonen A. Restoration of sensibility in irreparable ulnar and median nerve lesions with use of sensory nerve transfer: long-term follow-up of 20 cases. *J Hand Surg Am.* 2001;26:44–51.
61. Duteille F, Petry D, Dautel G, et al. A comparison between clinical results and electromyographic analysis after median or ulnar nerve injuries in children's wrists. *Ann Plast Surg.* 2001;46:382–386.
62. Matejcek V. Surgical treatment of peripheral nerve injuries in upper extremities. *Acta Chir Plast.* 2002;44:80–85.
63. Buntic RF, Buncke HJ, Kind GM, et al. The harvest and clinical application of the superficial peroneal sensory nerve for grafting motor and sensory nerve defects. *Plast Reconstr Surg.* 2002;109:145–151.
64. Meek MF, Coert JH, Robinson PH. Poor results after nerve grafting in the upper extremity: quo vadis? *Microsurgery.* 2005;25:396–402.
65. Kim DH, Han K, Tiel RL, et al. Surgical outcomes of 654 ulnar nerve lesions. *J Neurosurg.* 2003;98:993–1004.
66. Wehbe J, Maalouf G, Habanbo J, et al. Surgical treatment of traumatic lesions of the axillary nerve. A retrospective study of 33 cases. *Acta Orthop Belg.* 2004;70:11–18.
67. Hasegawa T, Nakamura S, Manabe T, et al. Vascularized nerve grafts for the treatment of large nerve gap after severe trauma to an upper extremity. *Arch Orthop Trauma Surg.* 2004;124:209–213.
68. Gurbuz H, Aktas S, Calpur OU. Clinical evaluation of ulnar nerve repair at wrist level. *Arch Orthop Trauma Surg.* 2004;124:49–51.
69. Schreuders TA, Roebroek ME, Jaquet JB, et al. Long-term outcome of muscle strength in ulnar and median nerve injury: comparing manual muscle strength testing, grip and pinch strength dynamometers and a new intrinsic muscle strength dynamometer. *J Rehabil Med.* 2004;36:273–278.
70. Roganovic Z. Missile-caused ulnar nerve injuries: outcomes of 128 repairs. *Neurosurgery.* 2004;55:1120–1129.
71. Baysefer A, Izci Y, Akay KM, et al. Surgical outcomes of ulnar nerve lesions in children. A retrospective clinical study. *Pediatr Neurosurg.* 2004;40:107–111.
72. Roganovic Z. Missile-caused median nerve injuries: results of 81 repairs. *Surg Neurol.* 2005;63:410–418; discussion 418–419.
73. Lundborg G, Rosen B, Dahlin L, et al. Tubular repair of the median or ulnar nerve in the human forearm: a 5-year follow-up. *J Hand Surg Br.* 2004;29:100–107.
74. Roganovic Z, Petkovic S. Missile severances of the radial nerve. Results of 131 repairs. *Acta Neurochir.* 2004;146:1185–1192.
75. Rosberg HE, Carlsson KS, Höjgård S, et al. Injury to the human median and ulnar nerves in the forearm—analysis of costs for treatment and rehabilitation of 69 patients in southern Sweden. *J Hand Surg Br.* 2005;30:35–39.
76. Ruijs AC, Jaquet JB, Kalmijn S, et al. Median and ulnar nerve injuries: a meta-analysis of predictors of motor and sensory recovery after modern microsurgical nerve repair. *Plast Reconstr Surg.* 2005;116:484–494; discussion 495–486.
77. Roganovic Z, Pavlicevic G. Difference in recovery potential of peripheral nerves after graft repairs. *Neurosurgery.* 2006;59:621–633; discussion 621–633.
78. Portincasa A, Gozzo G, Parisi D, et al. Microsurgical treatment of injury to peripheral nerves in upper and lower limbs: a critical review of the last 8 years. *Microsurgery.* 2007;27:455–462.
79. Reyes O, Sosa JJ, Santiago J, et al. A novel technique leading to complete sensory and motor recovery across a long peripheral nerve gap. *P R Health Sci J.* 2007;26:225–228.
80. Donoghoe N, Rosson GD, Dellon AL. Reconstruction of the human median nerve in the forearm with the Neurotube. *Microsurgery.* 2007;27:595–600.
81. Cempla J, Pieniazek M, Pelczar-Pieniazek M. Regimen and results of physiotherapy in patients following surgical treatment of ulnar nerve injury. *Ortop Traumatol Rehabil.* 2007;9:499–510.
82. Secer HI, Daneyemez M, Gonul E, et al. Surgical repair of ulnar nerve lesions caused by gunshot and shrapnel: results in 407 lesions. *J Neurosurg.* 2007;107:776–783.
83. Roganovic Z, Ilic S, Savic M. Radial nerve repair using an autologous denatured muscle graft: comparison with outcomes of nerve graft repair. *Acta Neurochir.* 2007;149:1033–1038; discussion 1038–1039.
84. Shieh SJ, Lee JW, Chiu HY. Long-term functional results of primary reconstruction of severe forearm injuries. *J Plast Reconstr Aesthet Surg.* 2007;60:339–348.
85. Vordemvenne T, Langer M, Ochman S, et al. Long-term results after primary microsurgical repair of ulnar and median nerve injuries: a comparison of common score systems. *Clin Neurol Neurosurg.* 2007;109:263–271.
86. Noaman H, Khalifa AR, El-Deen MA, et al. Early surgical exploration of radial nerve injury associated with fracture shaft humerus. *Microsurgery.* 2008;28:635–642.
87. Terzis JK, Kokkalis ZT. Outcomes of secondary reconstruction of ulnar nerve lesions: our experience. *Plast Reconstr Surg.* 2008;122:1100–1110.
88. Lee YH, Chung MS, Gong HS, et al. Sural nerve autografts for high radial nerve injury with nine centimeter or greater defects. *J Hand Surg Am.* 2008;33:83–86.
89. Mavrogenis AF, Spyridonos SG, Antonopoulos D, et al. Effect of sensory re-education after low median nerve complete transection and repair. *J Hand Surg Am.* 2009;34:1210–1215.
90. Gu B, Xie F, Jiang H, et al. Repair of electrically injured median nerve with the aid of somatosensory evoked potential. *Microsurgery.* 2009;29:449–455.
91. Mohseni MA, Pour JS, Pour JG. Primary and delayed repair and nerve grafting for treatment of cut median and ulnar nerves. *Pak J Biol Sci.* 2010;13:287–292.
92. Pan CH, Chuang DC, Rodriguez-Lorenzo A. Outcomes of nerve reconstruction for radial nerve injuries based on the level of injury in 244 operative cases. *J Hand Surg Eur Vol.* 2010;35:385–391.
93. Boender ZJ, Ultee J, Hovius SE. Cognitive capacity: no association with recovery of sensibility by Semmes Weinstein test score after peripheral nerve injury of the forearm. *J Plast Reconstr Aesthet Surg.* 2010;63:354–359.
94. Bulut T, Akgun U, Citlak A, et al. Prognostic factors in sensory recovery after digital nerve repair. *Acta Orthop Traumatol Turc.* 2016;50:157–161.
95. Grinsell D, Keating CP. Peripheral nerve reconstruction after injury: a review of clinical and experimental therapies. *Biomed Res Int.* 2014;2014:698256.
96. Menorca RMG, Fussell TS, Elfar JC. Nerve physiology: mechanisms of injury and recovery. *Hand Clin.* 2013;29:317–330.
97. Kim JS, Bonsu NY, Leland HA, et al. A systematic review of prognostic factors for sensory recovery after digital nerve reconstruction. *Ann Plast Surg.* 2018;80(S5):S311–s316.
98. Mermans JF, Franssen BBGM, Serroyen J, et al. Digital nerve injuries: a review of predictors of sensory recovery after microsurgical digital nerve repair. *Hand (New York, NY).* 2012;7:233–241.
99. Battiston B, Geuna S, Ferrero M, et al. Nerve repair by means of tubulization: literature review and personal clinical experience comparing biological and synthetic conduits for sensory nerve repair. *Microsurgery.* 2005;25:258–267.
100. McFarlane RM, Mayer JR. Digital nerve grafts with the lateral antebrachial cutaneous nerve. *J Hand Surg Am.* 1976;1:169–173.
101. Hirasawa Y, Katsumi Y, Tokioka T. Evaluation of sensibility after sensory reconstruction of the thumb. *J Bone Joint Surg Br.* 1985;67:814–819.
102. Sullivan DJ. Results of digital neurolysis in adults. *J Hand Surg Br.* 1985;10:41–44.
103. Walton RL, Brown RE, Matory WE Jr, et al. Autogenous vein graft repair of digital nerve defects in the finger: a retrospective clinical study. *Plast Reconstr Surg.* 1989;84:944–949; discussion 950–942.
104. Rose EH, Kowalski TA, Norris MS. The reversed venous arterialized nerve graft in digital nerve reconstruction across scarred beds. *Plast Reconstr Surg.* 1989;83:593–604.
105. Pereira JH, Bowden RE, Gattuso JM, et al. Comparison of results of repair of digital nerves by denatured muscle grafts and end-to-end sutures. *J Hand Surg Br.* 1991;16:519–523.
106. Tang JB, Gu YQ, Song YS. Repair of digital nerve defect with autogenous vein graft during flexor tendon surgery in zone 2. *J Hand Surg Br.* 1993;18:449–453.
107. Segalman KA, Cook PA, Wang BH, et al. Digital neurolysis after the age of 60 years. *J Reconstr Microsurg.* 2001;17:85–88.
108. Vipond N, Taylor W, Rider M. Postoperative splinting for isolated digital nerve injuries in the hand. *J Hand Ther.* 2007;20:222–230; quiz 231.

109. Lohmeyer JA, Sommer B, Siemers F, et al. Nerve injuries of the upper extremity-expected outcome and clinical examination. *Plast Surg Nurs*. 2009;29:88–93; quiz 94–85.
110. Maccoccio I, Vignasio A. Muscle-in-vein nerve guide for secondary reconstruction in digital nerve lesions. *J Hand Surg Am*. 2010;35:1418–1426.
111. Taras JS, Amin N, Patel N, et al. Allograft reconstruction for digital nerve loss. *J Hand Surg Am*. 2013;38:1965–1971.
112. Rinker B, Liau JY. A prospective randomized study comparing woven polyglycolic acid and autogenous vein conduits for reconstruction of digital nerve gaps. *J Hand Surg Am*. 2011;36:775–781.
113. Laveaux C, Pauchot J, Obert L, et al. Emergency management of traumatic colateral palmar digital nerve defect inferior to 30 mm by venous grafting. Report of 12 clinical cases. *Chir Main*. 2011;30:16–19.
114. Chen C, Tang P, Zhang X. Reconstruction of proper digital nerve defects in the thumb using a pedicle nerve graft. *Plast Reconstr Surg*. 2012;130:1089–1097.
115. Taras JS, Jacoby SM, Lincoski CJ. Reconstruction of digital nerves with collagen conduits. *J Hand Surg Am*. 2011;36:1441–1446.
116. Stang F, Stollwerck P, Prommersberger KJ, et al. Posterior interosseus nerve vs. medial cutaneous nerve of the forearm: differences in digital nerve reconstruction. *Arch Orthop Trauma Surg*. 2013;133:875–880.
117. Pilanci O, Ozel A, Basaran K, et al. Is there a profit to use the lateral antebrachial cutaneous nerve as a graft source in digital nerve reconstruction? *Microsurgery*. 2014;34:367–371.
118. Rinker BD, Ingari JV, Greenberg JA, et al. Outcomes of short-gap sensory nerve injuries reconstructed with processed nerve allografts from a multicenter registry study. *J Reconstr Microsurg*. 2015;31:384–390.
119. Wong JN, Olson JL, Morhart MJ, et al. Electrical stimulation enhances sensory recovery: a randomized controlled trial. *Ann Neurol*. 2015;77:996–1006.
120. Fakin RM, Calcagni M, Klein HJ, et al. Long-term clinical outcome after epineural coaptation of digital nerves. *J Hand Surg Eur Vol*. 2016;41:148–154.
121. Klein HJ, Fakin RM, Ducommun P, et al. Evaluation of cutaneous spatial resolution and pressure threshold secondary to digital nerve repair. *Plast Reconstr Surg*. 2016;137:1203–1212.
122. Kim J, Lee YH, Kim MB, et al. Innervated reverse digital artery island flap through bilateral neurotaphy using direct small branches of the proper digital nerve. *Plast Reconstr Surg*. 2015;135:1643–1650.
123. Garner MR, Taylor SA, Gausden E, et al. Compartment syndrome: diagnosis, management, and unique concerns in the twenty-first century. *HSS J*. 2014;10:143–152.
124. Kallio PK. The results of secondary repair of 254 digital nerves. *J Hand Surg Br*. 1993;18:327–330.
125. Tottas S, Kougioumtzis I, Titsi Z, et al. Ulnar nerve entrapment in Guyon's canal caused by a ganglion cyst: two case reports and review of the literature. *Eur J Orthop Surg Traumatol*. 2019;29:1565–1574.
126. Erkin G, Uysal H, Keles I, et al. Acute ulnar neuropathy at the wrist: a case report and review of the literature. *Rheumatol Int*. 2006;27:191–196.
127. Wang B, Zhao Y, Lu A, et al. Ulnar nerve deep branch compression by a ganglion: a review of nine cases. *Injury*. 2014;45:1126–1130.
128. Inaparthi PK, Anwar F, Botchu R, et al. Compression of the deep branch of the ulnar nerve in Guyon's canal by a ganglion: two cases. *Arch Orthop Trauma Surg*. 2008;128:641–643.
129. Mack GR, McPherson SA, Lutz RB. Acute median neuropathy after wrist trauma. The role of emergent carpal tunnel release. *Clin Orthop Relat Res*. 1994;300:141–146.
130. Debkowska MP, Cotterell IH, Riley AJ. Case report: acute cubital tunnel syndrome in a hemophilic patient. *SAGE Open Med Case Rep*. 2019;7:2050313X18824814.
131. Schnetzler KA. Acute carpal tunnel syndrome. *J Am Acad Orthop Surg*. 2008;16:276–282.
132. Pope D, Tang P. Carpal tunnel syndrome and distal radius fractures. *Hand Clin*. 2018;34:27–32.
133. Xu GY, Qiu Y, Mao HJ. A network meta-analysis of outcomes of 7 surgical treatments for distal radius fractures. *Am J Ther*. 2016;23:e1320–e1328.
134. Zhao HL, Wang GB, Jia YQ, et al. Comparison of risk of carpal tunnel syndrome in patients with distal radius fractures after 7 treatments. *Med Sci Monit*. 2015;21:2837–2844.
135. Ahn SY, Hong YH, Koh YH, et al. Pressure measurement in carpal tunnel syndrome: correlation with electrodiagnostic and ultrasonographic findings. *J Korean Neurosurg Soc*. 2009;46:199–204.
136. Sheridan GW, Matsen FA 3rd. Fasciotomy in the treatment of the acute compartment syndrome. *J Bone Joint Surg Am*. 1976;58:112–115.
137. Finkelstein JA, Hunter GA, Hu RW. Lower limb compartment syndrome: course after delayed fasciotomy. *J Trauma*. 1996;40:342–344.
138. Guo J, Yin Y, Jin L, et al. Acute compartment syndrome: cause, diagnosis, and new viewpoint. *Medicine*. 2019;98:e16260–e16260.
139. Heckman MM, Whitesides TE Jr, Grewe SR, et al. Histologic determination of the ischemic threshold of muscle in the canine compartment syndrome model. *J Orthop Trauma*. 1993;7:199–210.
140. Whitesides TE, Heckman MM. Acute compartment syndrome: update on diagnosis and treatment. *J Am Acad Orthop Surg*. 1996;4:209–218.
141. Labbe R, Lindsay T, Walker PM. The extent and distribution of skeletal muscle necrosis after graded periods of complete ischemia. *J Vasc Surg*. 1987;6:152–157.
142. Lin JS, Samora JB. Pediatric acute compartment syndrome: a systematic review and meta-analysis. *J Pediatr Orthop B*. 2020;29:90–96.
143. Kanj WW, Gunderson MA, Carrigan RB, et al. Acute compartment syndrome of the upper extremity in children: diagnosis, management, and outcomes. *J Child Orthop*. 2013;7:225–233.
144. Reichert P, Wnukiewicz W, Witkowski J, et al. Causes of secondary radial nerve palsy and results of treatment. *Med Sci Monit*. 2016;22:554–562.
145. Schwab TR, Stillhard PF, Schibli S, et al. Radial nerve palsy in humeral shaft fractures with internal fixation: analysis of management and outcome. *Eur J Trauma Emerg Surg*. 2018;44:235–243.
146. Haviv B, Bronak S, Rath E, et al. Nerve injury during anterior cruciate ligament reconstruction: a comparison between patellar and hamstring tendon grafts harvest. *Knee*. 2017;24:564–569.
147. Oshima T, Nakase J, Numata H, et al. Common peroneal nerve palsy with multiple-ligament knee injury and distal avulsion of the biceps femoris tendon. *Case Rep Orthop*. 2015;2015:306260.
148. Haviv B, Yassin M, Rath E, et al. Prevalence and clinical implications of nerve injury during bone patellar tendon bone harvesting for anterior cruciate ligament reconstruction. *J Orthop Surg (Hong Kong)*. 2017;25:2309499016684988.
149. Hardy A, Casabianca L, Andrieu K, et al. Complications following harvesting of patellar tendon or hamstring tendon grafts for anterior cruciate ligament reconstruction: systematic review of literature. *Orthop Traumatol Surg Res*. 2017;103:S245–s248.
150. Alejandro SF, Maloney PJ, Grandizio LC, et al. The sequelae of drop foot after knee dislocation: evaluation and treatment. *Oper Tech Sports Med*. 2015;23:348–356.
151. Clain JB, Vitale MA, Ahmad CS, et al. Ulnar nerve complications after ulnar collateral ligament reconstruction of the elbow: a systematic review. *Am J Sports Med*. 2019;47:1263–1269.
152. Ciccotti MG, Atanda A Jr, Nazarian LN, et al. Stress sonography of the ulnar collateral ligament of the elbow in professional baseball pitchers: a 10-year study. *Am J Sports Med*. 2014;42:544–551.
153. Erickson BJ, Harris JD, Chalmers PN, et al. Ulnar collateral ligament reconstruction: anatomy, indications, techniques, and outcomes. *Sports Health*. 2015;7:511–517.
154. Dy CJ, Mackinnon SE. Ulnar neuropathy: evaluation and management. *Curr Rev Musculoskelet Med*. 2016;9:178–184.
155. Taylor-Gjevrev RM, Gjevrev JA, Nair B. Suspected carpal tunnel syndrome: do nerve conduction study results and symptoms match? *Can Fam Physician*. 2010;56:e250–e254.
156. Graham B. The value added by electrodiagnostic testing in the diagnosis of carpal tunnel syndrome. *J Bone Joint Surg Am*. 2008;90:2587–2593.
157. Masud M, Rashid M, Malik SA, et al. Does the duration and severity of symptoms have an impact on relief of symptoms after carpal tunnel release? *J Brachial Plex Peripher Nerve Inj*. 2019;14:e1–e8.
158. Burke FD, Wilgis EF, Dubin NH, et al. Relationship between the duration and severity of symptoms and the outcome of carpal tunnel surgery. *J Hand Surg Am*. 2006;31:1478–1482.
159. Alimohammadi E, Bagheri SR, Hadidi H, et al. Carpal tunnel surgery: predictors of clinical outcomes and patients' satisfaction. *BMC Musculoskelet Disord*. 2020;21:51–51.
160. Kong L, Bai J, Yu K, et al. Predictors of surgical outcomes after in situ ulnar nerve decompression for cubital tunnel syndrome. *Ther Clin Risk Manag*. 2018;14:69–74.
161. Camp CL, Tebo CC, Degen RM, et al. Patient-related risk factors for infection following ulnar nerve release at the cubital tunnel: an analysis of 15,188 cases. *Orthop J Sports Med*. 2018;6:2325967118772799.
162. Eisenhardt SU, Mathonia C, Stark GB, et al. Retrospective analysis of 242 patients whose carpal tunnels were released using a one-port endoscopic procedure: superior results of early intervention. *J Plast Surg Hand Surg*. 2010;44:311–317.
163. Hanks CL, Brown MG, Lopez RA, et al. A 12-year experience using the Brown two-port endoscopic procedure of transverse carpal ligament release in 14,722 patients: defining a new paradigm in the treatment of carpal tunnel syndrome. *Plast Reconstr Surg*. 2007;120:1911–1921.

164. Aleem AW, Krogue JD, Calfee RP. Outcomes of revision surgery for cubital tunnel syndrome. *J Hand Surg Am.* 2014;39:2141–2149.
165. Teoh LC, Tan PL. Endoscopic carpal tunnel release for recurrent carpal tunnel syndrome after previous open release. *Hand Surg.* 2004;9:235–239.
166. Luria S, Waitayawinyu T, Trumble TE. Endoscopic revision of carpal tunnel release. *Plast Reconstr Surg.* 2008;121:2029–2034; discussion 2035–2026.
167. Langloh ND, Linscheid RL. Recurrent and unrelieved carpal-tunnel syndrome. *Clin Orthop Relat Res.* 1972;83:41–47.
168. Wadstroem J, Nigst H. Reoperation for carpal tunnel syndrome. A retrospective analysis of forty cases. *Ann Chir Main.* 1986;5:54–58.
169. O'Malley MJ, Evanoff M, Terrono AL, et al. Factors that determine reexploration treatment of carpal tunnel syndrome. *J Hand Surg Am.* 1992;17:638–641.
170. Chang B, Dellon AL. Surgical management of recurrent carpal tunnel syndrome. *J Hand Surg Br.* 1993;18:467–470.
171. Cobb TK, Amadio PC, Leatherwood DF, et al. Outcome of reoperation for carpal tunnel syndrome. *J Hand Surg Am.* 1996;21:347–356.
172. Duclos L, Sokolow C. Management of true recurrent carpal tunnel syndrome: is it worthwhile to bring vascularized tissue? *Chir Main.* 1998;17:113–117; discussion 118.
173. Hulsizer DL, Staebler MP, Weiss AP, et al. The results of revision carpal tunnel release following previous open versus endoscopic surgery. *J Hand Surg Am.* 1998;23:865–869.
174. Forman DL, Watson HK, Caulfield KA, et al. Persistent or recurrent carpal tunnel syndrome following prior endoscopic carpal tunnel release. *J Hand Surg Am.* 1998;23:1010–1014.
175. Beck JD, Brothers JG, Maloney PJ, et al. Predicting the outcome of revision carpal tunnel release. *J Hand Surg Am.* 2012;37:282–287.
176. Sotereanos DG, Giannakopoulos PN, Mitsionis GI, et al. Vein-graft wrapping for the treatment of recurrent compression of the median nerve. *Microsurgery.* 1995;16:752–756.
177. Sotereanos DG, Xu J. Vein wrapping for the treatment of recurrent carpal tunnel syndrome. *Tech Hand Up Extrem Surg.* 1997;1:35–40.
178. Varitimidis SE, Riano F, Sotereanos DG. Recalcitrant post-surgical neuropathy of the ulnar nerve at the elbow: treatment with autogenous saphenous vein wrapping. *J Reconstr Microsurg.* 2000;16:273–277.
179. Soltani AM, Allan BJ, Best MJ, et al. Revision decompression and collagen nerve wrap for recurrent and persistent compression neuropathies of the upper extremity. *Ann Plast Surg.* 2014;72:572–578.
180. Kokkalis ZT, Mavrogenis AF, Ballas EG, et al. Collagen nerve wrap for median nerve scarring. *Orthopedics.* 2015;38:117–121.
181. Kokkalis ST, Mavrogenis AF, Vottis C, et al. Median nerve biodegradable wrapping: clinical outcome of 10 patients. *Acta Orthop Belg.* 2016;82:351–357.
182. Strickland JW, Idler RS, Lourie GM, et al. The hypothenar fat pad flap for management of recalcitrant carpal tunnel syndrome. *J Hand Surg Am.* 1996;21:840–848.
183. Giunta R, Frank U, Lanz U. The hypothenar fat-pad flap for reconstructive repair after scarring of the median nerve at the wrist joint. *Chir Main.* 1998;17:107–112.
184. Mathoulin C, Bahm J, Roukoz S. Pedicled hypothenar fat flap for median nerve coverage in recalcitrant carpal tunnel syndrome. *Hand Surg.* 2000;5:33–40.
185. Craft RO, Duncan SF, Smith AA. Management of recurrent carpal tunnel syndrome with micro-neurolysis and the hypothenar fat pad flap. *Hand (N Y).* 2007;2:85–89.
186. Stutz NM, Gohritz A, Novotny A, et al. Clinical and electrophysiological comparison of different methods of soft tissue coverage of the median nerve in recurrent carpal tunnel syndrome. *Neurosurgery.* 2008;62(3 suppl 1):194–199; discussion 199–200.
187. Fusetti C, Garavaglia G, Mathoulin C, et al. A reliable and simple solution for recalcitrant carpal tunnel syndrome: the hypothenar fat pad flap. *Am J Orthop (Belle Mead NJ).* 2009;38:181–186.
188. Karthik K, Nanda R, Stothard J. Recurrent carpal tunnel syndrome—analysis of the impact of patient personality in altering functional outcome following a vascularized hypothenar fat pad flap surgery. *J Hand Microsurg.* 2012;4:1–6.
189. Wichelhaus A, Mittlmeier T, Gierer P, et al. Vascularized hypothenar fat pad flap in revision surgery for carpal tunnel syndrome. *J Neurol Surg A Cent Eur Neurosurg.* 2015;76:438–442.
190. Athlani L, Haloua JP. Strickland's hypothenar fat pad flap for revision surgery in carpal tunnel syndrome: prospective study of 34 cases. *Hand Surg Rehabil.* 2017;36:202–207.
191. Wulle C. The synovial flap as treatment of the recurrent carpal tunnel syndrome. *Hand Clin.* 1996;12:379–388.
192. Murthy PG, Abzug JM, Jacoby SM, et al. The tenosynovial flap for recalcitrant carpal tunnel syndrome. *Tech Hand Up Extrem Surg.* 2013;17:84–86.
193. Strasberg SR, Novak CB, Mackinnon SE, et al. Subjective and employment outcome following secondary carpal tunnel surgery. *Ann Plast Surg.* 1994;32:485–489.
194. Varitimidis SE, Herndon JH, Sotereanos DG. Failed endoscopic carpal tunnel release. Operative findings and results of open revision surgery. *J Hand Surg Br.* 1999;24:465–467.
195. Jones NF, Ahn HC, Eo S. Revision surgery for persistent and recurrent carpal tunnel syndrome and for failed carpal tunnel release. *Plast Reconstr Surg.* 2012;129:683–692.
196. Zieske L, Ebersole GC, Davidge K, et al. Revision carpal tunnel surgery: a 10-year review of intraoperative findings and outcomes. *J Hand Surg Am.* 2013;38:1530–1539.
197. Djerbi I, Cesar M, Lenoir H, et al. Revision surgery for recurrent and persistent carpal tunnel syndrome: clinical results and factors affecting outcomes. *Chir Main.* 2015;34:312–317.
198. Lauder A, Mithani S, Leversedge FJ. Management of recalcitrant carpal tunnel syndrome. *J Am Acad Orthop Surg.* 2019;27:551–562.
199. Bassilios Habre S, Bond G, Jing XL, et al. The surgical management of nerve gaps: present and future. *Ann Plast Surg.* 2018;80:252–261.
200. Bartels RH, Grotenhuis JA. Anterior submuscular transposition of the ulnar nerve. For post-operative focal neuropathy at the elbow. *J Bone Joint Surg Br.* 2004;86:998–1001.
201. Rogers MR, Bergfield TG, Alicino PL. The failed ulnar nerve transposition. Etiology and treatment. *Clin Orthop Relat Res.* 1991;269:193–200.
202. Kholinne E, Alsharidah MM, Almutairi O, et al. Revision surgery for refractory cubital tunnel syndrome: a systematic review. *Orthop Traumatol Surg Res.* 2019;105:867–876.
203. Guan WJ, Ni ZY, Hu Y, et al. Clinical characteristics of coronavirus disease 2019 in China. *N Engl J Med.* 2020;382:1708–1720.
204. Pannell WC, Heckmann N, Alluri RK, et al. Predictors of nerve injury after gunshot wounds to the upper extremity. *Hand (N Y).* 2017;12:501–506.
205. Houdek MT, Shin AY. Management and complications of traumatic peripheral nerve injuries. *Hand Clin.* 2015;31:151–163.
206. Dicipinigitis PA, Koval KI, Tejwani NC, et al. Gunshot wounds to the extremities. *Bull NYU Hosp Jt Dis.* 2006;64:139–155.
207. Saito H, Dahlin LB. Expression of ATF3 and axonal outgrowth are impaired after delayed nerve repair. *BMC Neurosci.* 2008;9:88.
208. Eberlin KR, Ducic I. Surgical algorithm for neuroma management: a changing treatment paradigm. *Plast Reconstr Surg Glob Open.* 2018;6:e1952–e1952.
209. Ducic I, Yoon J, Eberlin KR. Treatment of neuroma-induced chronic pain and management of nerve defects with processed nerve allografts. *Plast Reconstr Surg Glob Open.* 2019;7:e2467.
210. Poppler LH, Parikh RP, Bichanich MJ, et al. Surgical interventions for the treatment of painful neuroma: a comparative meta-analysis. *Pain.* 2018;159:214–223.
211. Grant M, Rees S, Underwood M, et al. Obstacles to returning to work with chronic pain: in-depth interviews with people who are off work due to chronic pain and employers. *BMC Musculoskelet Disord.* 2019;20:486–486.
212. Petrosky E, Harpaz R, Fowler KA, et al. Chronic pain among suicide decedents, 2003 to 2014: findings from the National Violent Death Reporting System. *Ann Intern Med.* 2018;169:448–455.
213. Souza JM, Purnell CA, Cheesborough JE, et al. Treatment of foot and ankle neuroma pain with processed nerve allografts. *Foot Ankle Int.* 2016;37:1098–1105.
214. Mackinnon SE. *Nerve Surgery.* New York: Thieme; 2015.
215. Socolovsky M, Di Masi G, Battaglia D. Use of long autologous nerve grafts in brachial plexus reconstruction: factors that affect the outcome. *Acta Neurochir.* 2011;153:2231–2240.
216. Brooks DN, Weber RV, Chao JD, et al. Processed nerve allografts for peripheral nerve reconstruction: a multicenter study of utilization and outcomes in sensory, mixed, and motor nerve reconstructions. *Microsurgery.* 2012;32:1–14.
217. Safa B, Shores JT, Ingari JV, et al. Recovery of motor function after mixed and motor nerve repair with processed nerve allograft. *Plast Reconstr Surg Glob Open.* 2019;7:e2163.
218. Oliveira KMC, Pindur L, Han Z, et al. Time course of traumatic neuroma development. *PLoS One.* 2018;13:e0200548–e0200548.
219. Dhananjaya IB, Devi BI, Komal B, et al. Cortical plasticity after brachial plexus injury and repair: a resting-state functional MRI study. *Neurosurg Focus FOC.* 2017;42:E14.
220. Goswami R, Anastakis DJ, Katz J, et al. A longitudinal study of pain, personality, and brain plasticity following peripheral nerve injury. *Pain.* 2016;157:729–739.
221. O'Brien AL, Jordan SW, West JM, et al. Targeted muscle reinnervation at the time of upper-extremity amputation for the treatment of pain severity and symptoms. *J Hand Surg Am.* 2021;46:72.e1–72.e10.
222. Borsook D, Kussman BD, George E, et al. Surgically induced neuropathic pain: understanding the perioperative process. *Ann Surg.* 2013;257:403–412.