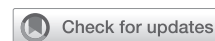

Muscle-sparing minithoractomy for cardiac surgery: Surgical technique



Wan Kee Kim, MD,^a Younju Rhee, MD,^a and SungA Bae, MD, PhD,^b Seoul and Yongin-si, Republic of Korea

From the ^aDepartment of Thoracic and Cardiovascular Surgery, Hanyang University Seoul Hospital, Hanyang University College of Medicine, Seoul; and ^bDepartment of Cardiology, Yongin Severance Hospital, Yonsei University College of Medicine, Yongin-si, Gyeonggi-do, Republic of Korea.

Read at *The American Association for Thoracic Surgery Mitral Conclave Workshop, New York, New York, May 3-5, 2023.*

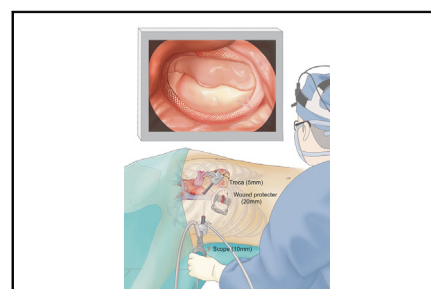
Received for publication June 23, 2023; revisions received Aug 2, 2023; accepted for publication Aug 7, 2023; available ahead of print Aug 19, 2023.

Address for reprints: SungA Bae, MD, PhD, Department of Cardiology, Yongin Severance Hospital, Yonsei University College of Medicine, 363, Dongbaek Jukjeon Daero, Giheung-gu, Yongin-si, Gyeonggi-do, Republic of Korea (E-mail: cardiobsa@yuhs.ac).

JTCVS Techniques 2023;21:86-91
2666-2507

Copyright © 2023 The Author(s). Published by Elsevier Inc. on behalf of The American Association for Thoracic Surgery. This is an open access article under the CC BY-NC-ND license (<http://creativecommons.org/licenses/by-nc-nd/4.0/>).

<https://doi.org/10.1016/j.jtc.2023.08.002>



Muscle-sparing 3-port minithoractomy for cardiac surgery.

CENTRAL MESSAGE

Muscle-sparing small incisional approach for cardiac surgery can be performed safe for some selected patients.

▶ Video clip is available online.

The minimal thoracotomy incisional approach has been introduced as a feasible option for the cardiac surgery. Concerns on the thoracic muscle cutting, however, have been argued as which may slow down the postoperative recovery.¹ In this regard, we report our separated 3-port thoracotomy approach technique with minimized muscle cutting for the cardiac surgery (institutional review board: 9-2023-0076, June 22, 2023, with a waiver of individual consent).

PROCEDURES

In the left lateral semidecubitus position, skin incisions were drawn at the second (5 mm, anterior axillary line [AXL]), third (10 mm, mid-axillary line [MXL]), and fourth (20 mm, AXL) intercostal spaces. This approach is our default setting, but there have been minor modifications of the locations, such as second (5 mm, AXL), fourth (10 mm, MXL), and fifth (20 mm, AXL) for patients with small chest walls (computed tomography, [Figure E1](#)). For better visualization and less instrument interference, a vertical direction toward the mitral valve (MV) for the camera port (10 mm) and distance more than 3 cm between each port were primarily regarded to draw incisions ([Figure E2](#)). Except for the main utility port (20 mm), thoracic wall muscles were all divided only. A virtual illustration is depicted in [Figure 1](#).

After the setting of this approach, cardiopulmonary bypass was established. All the following procedures were performed under scope-assist. The left ventricular venting catheter and cardioplegia line were inserted through main working port (20 mm). Thereafter, a detachable aortic clamp was inserted through the 10-mm port (MXL) to be parallel to the transverse sinus. Del Nido cardioplegia (mixture of 80% crystalloid solution and 20% oxygenated blood) was administered with an antegrade manner through ascending aorta. After the left or right atriotomy, MV repair, atrial septal defect closure, or mass-removal procedures were performed ([Figure E3](#)). Techniques used for the MV repair were new artificial chorda placement, the anterolateral or posteromedial commissure closures, indentation closures, and annuloplasty ring insertions, depending on the individual mitral regurgitation pathologies. [Video 1](#) shows an infective endocarditis case using this technique to treat a 27-year-old female patient.

From June 2022 to Marvh 2023, we have used this approach in 9 patients ([Table 1](#)). There was no mortality or neurologic deficits reported. In 2 cases (#2 and #8), we experienced sternotomy conversion. In 1 case (#2), the whole procedure was performed successfully through a similar approach as mentioned previously, but the right

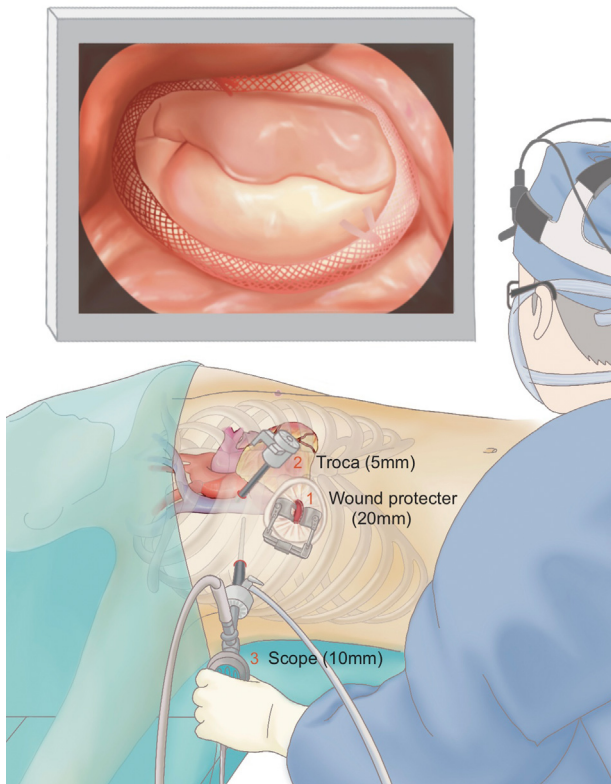


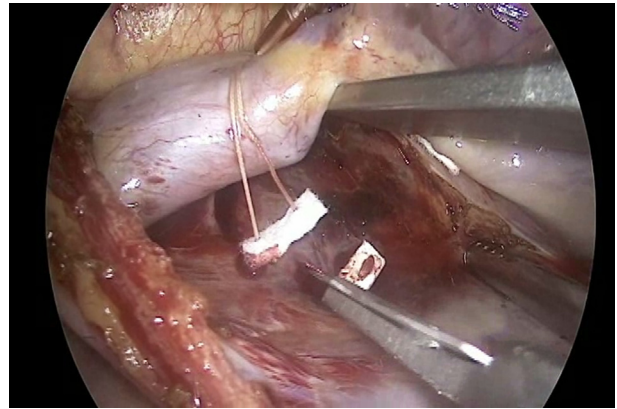
FIGURE 1. Muscle-sparing 3-port minithoracotomy for cardiac surgery.

atrial appendage was largely torn during the cardioplegic line removal. In another case (#8), a mass-like lesion was observed on the intraoperative transesophageal echocardiography, and we clamped the aorta again to reopen the left atrium through sternotomy. The mass, however, was revealed as a folded left atrium superior wall due to the left atrial appendage clipping. There were no further complications in either patient. For some cases (#3, #5, and #9), we used this approach for the cosmetic purpose (Figure E4).

The study was approved by the institutional ethics committee/review board (study number 9-2023-0076), and the requirement for informed patient consent was waived in view of the retrospective nature of the study.

DISCUSSION

For better perioperative recovery, the indication of minimal incisional approach for the cardiac surgery has been recently expanded.² Instead of splitting the sternum, thoracotomy or hemisternotomy are common methods for minimal incisional cardiac surgery.³ A 5~6 cm of incision on the right fourth intercostal space is frequently used to enter the atria of the heart. This thoracotomy offers many benefits, such as avoiding hemorrhage from the sternum and providing vision parallel to the MV as well



VIDEO 1. Mitral valve repair through 3-port minithoracotomy for a patient with infective endocarditis. Video available at: [https://www.jtcvs.org/article/S2666-2507\(23\)00278-X/fulltext](https://www.jtcvs.org/article/S2666-2507(23)00278-X/fulltext).

as cosmetic benefits. The thoracic wall muscles, however, must be cut and separated for this approach, and the pleura is to be opened to the same size (5~6 cm) as well. From this reason, there is an argument that a thoracotomy wound may bring more pain compared with a sternotomy.¹ In some cases, direct vision through this incision is troublesome, or the body of scope often interferes movements of surgical instruments in the single large port system.

To overcome these limitations, we modified the thoracotomy incision by shortening incision length, minimizing muscle cutting, and separating the video scope port. We think our technique has advantages as follows: (1) Except for the main 20-mm incision, thoracic wall muscles can be saved without cutting. (2) As 3 thoracotomy ports can be placed in a triangular shape, movement of surgical instruments became more effective without interference from the scope. (3) The procedure may be helpful for patients who have cosmetic considerations, such as young women.

The disadvantage of minimal incisional cardiac surgery is longer cardiopulmonary bypass and cardiac ischemic times than the cardiac surgery with conventional sternotomy.⁴ However, the hurdle may be overcome, as a single del Nido enables 90 minutes of continuous procedure.⁵ In our case series, cardiac ischemic time was longer than 100 minutes in first 3 cases. Although it took longer than usual thoracotomy cases, no patient developed postoperative heart failure. In addition, the surgical time has been gradually de-escalated as the surgical team has gained experience. This muscle-sparing small incisional approach for cardiac surgery may be feasible for some selected young patients. Our technique, however, may not be appropriate for patients who are older or who have heart failure or other comorbid conditions because

TABLE 1. Details of patients with muscle-sparing thoracotomy cardiac surgery

Number	Age, y	Sex	Disease	Procedures	ACC time, min	CPB time, min	Complication
#1	43	M	Myxoma	Myxoma removal	90	228	
#2	43	M	Degenerative MR	Mitral annuloplasty, neochorda formation at P2	207	368	Sternotomy
#3	27	F	Endocarditis	Mitral annuloplasty, neochorda formation at P1, lateral commissuroplasty, A2-A3 indentation repair	190	296	
#4	63	F	Degenerative MR	Mitral annuloplasty, neochorda formation at P1	132	217	
#5	18	M	Atrial septal defect	Patch repair	87	171	
#6	43	M	Myxoma	Myxoma removal	48	100	
#7	61	F	TR, Afib	Tricuspid annuloplasty, Afib ablation	101	212	
#8	82	F	Myxoma, Afib	Myxoma removal, Afib ablation	68	300	Sternotomy
#9	26	M	Endocarditis	A3 primary repair, Medial commissuroplasty	97	203	

ACC, Aortic crossclamp; CPB, cardiopulmonary bypass; M, male; MR, mitral regurgitation; F, female; TR, tricuspid regurgitation; Afib, atrial fibrillation.

it may require more cardiac ischemic time than the usual thoracotomy approach.

Conflict of Interest Statement

The authors reported no conflicts of interest.

The *Journal* policy requires editors and reviewers to disclose conflicts of interest and to decline handling or reviewing manuscripts for which they may have a conflict of interest. The editors and reviewers of this article have no conflicts of interest.

All individuals involved in the study are included in the authorship.

References

1. Minami K, Kabata D, Kakuta T, Fukushima S, Fujita T, Yoshitani K, et al. Association between sternotomy versus thoracotomy and the prevalence and severity of chronic postsurgical pain after mitral valve repair: an observational cohort study. *J Cardiothorac Vasc Anesth*. 2021;35:2937-44.
2. Modi P, Hassan A, Chitwood WR Jr. Minimally invasive mitral valve surgery: a systematic review and meta-analysis. *Eur J Cardiothorac Surg*. 2008;34:943-52.
3. Phan K, Xie A, Di Eusano M, Yan TD. A meta-analysis of minimally invasive versus conventional sternotomy for aortic valve replacement. *Ann Thorac Surg*. 2014;98:1499-511.
4. Lim JY, Deo SV, Altarabsheh SE, Jung SH, Erwin PJ, Markowitz AH, et al. Conventional versus minimally invasive aortic valve replacement: pooled analysis of propensity-matched data. *J Card Surg*. 2015;30:125-34.
5. Jung JC, Kim SI, Hwang HY, Sohn SH, Choi JW, Chung JH, et al. Serial ultrastructural evaluation of myocardial ischemic injury after infusion of del nido cardioplegia in the human heart. *J Thorac Cardiovasc Surg*. 2022;164:528-36.e2.

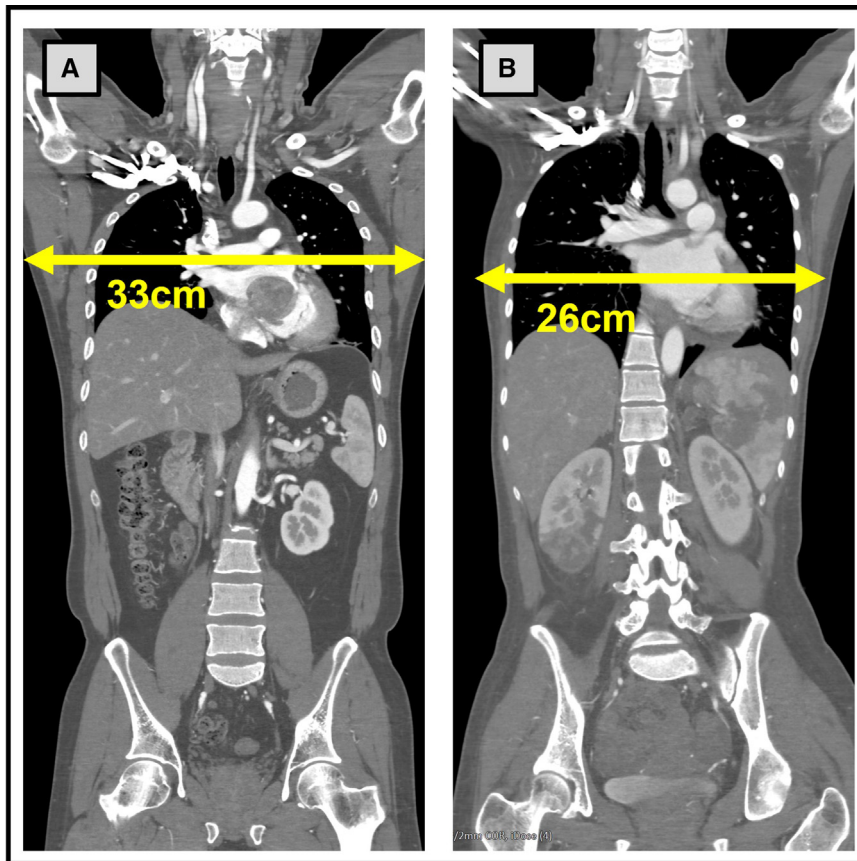


FIGURE E1. Preoperative computed tomography (CT) images to determine working port location. When the intercostal spaces were small, the main incision was made at the fifth intercostal space to avoid instrumental interference. A, Preoperative CT scan for a male patient with the main incision at the fourth intercostal space. B, Preoperative CT scan for a female patient with the main incision at the fifth intercostal space.

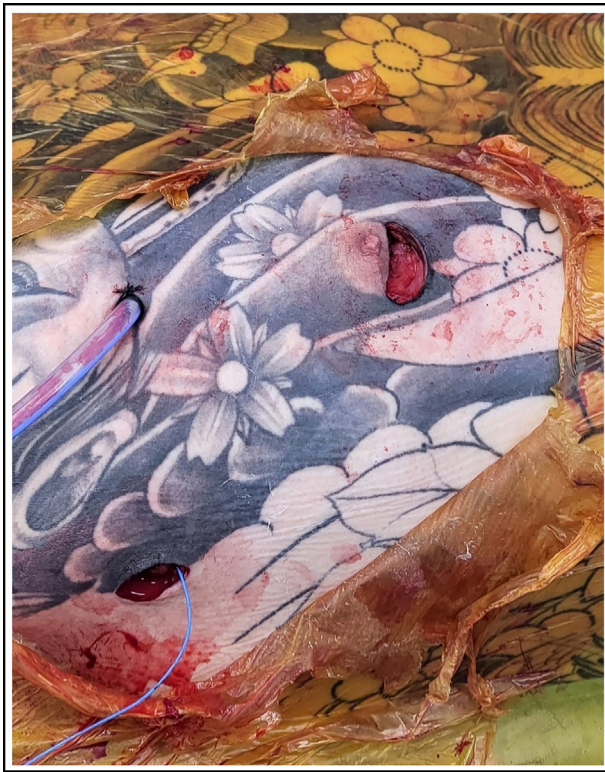


FIGURE E2. Incision of the muscle-sparing 3-port minithoracotomy for cardiac surgery.

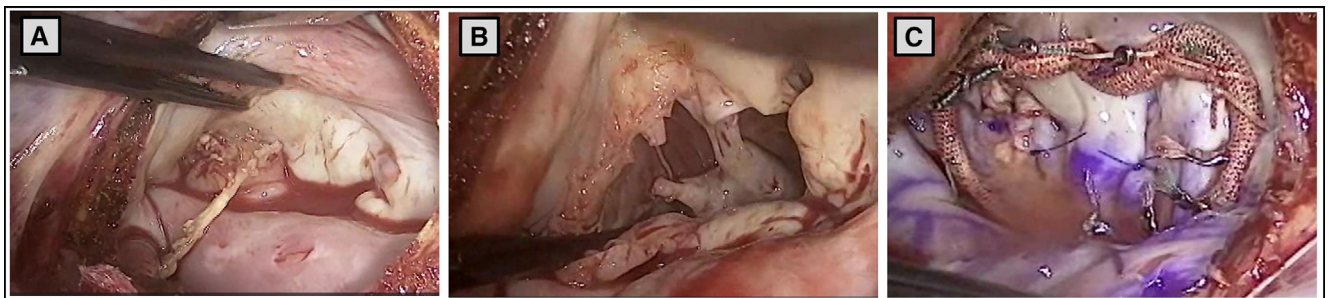


FIGURE E3. Mitral repair for infective endocarditis. A, Infective mitral valve. B, After removal of vegetation and infected leaflet. C, Mitral valve repair was completed.

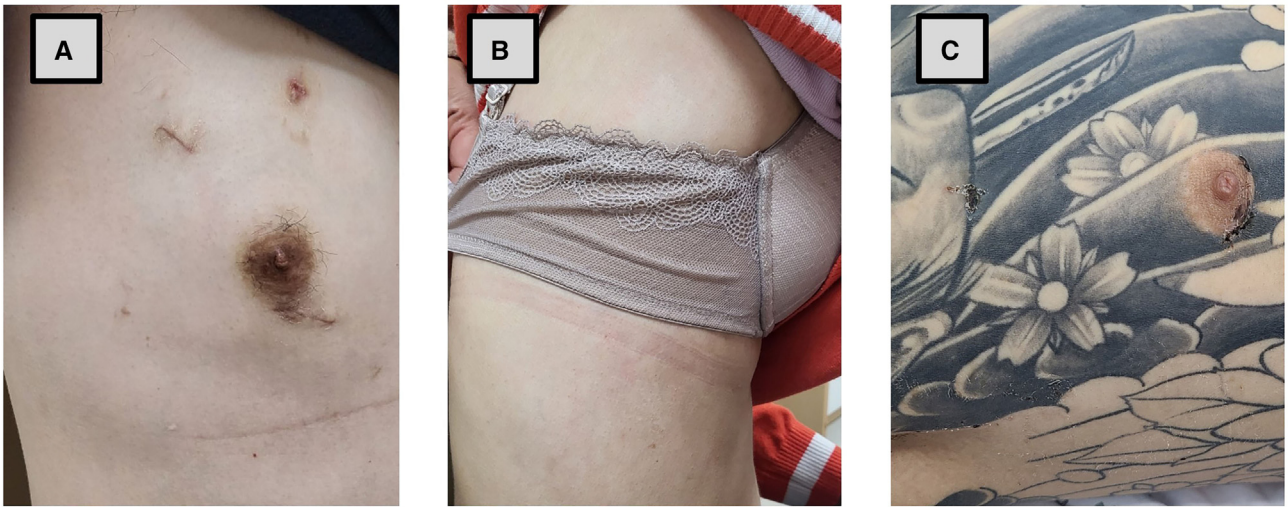

FIGURE E4. Wound pictures at the first outpatient clinics. A, Surgical wound for a high school student. B, Surgical wound for a 27-year-old female patient. C, Surgical wound for a young male patient with a tattoo.