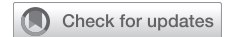

Floating fibrin mass in the left ventricle after fibrin glue use in left ventricular reconstruction: A case report



Hideki Isa, MD, Tomonori Shirasaka, MD, PhD, Shingo Kunioka, MD, and Hiroyuki Kamiya, MD, PhD, Asahikawa, Japan

From the Department of Cardiac Surgery, Asahikawa Medical University, Asahikawa, Japan.

Disclosures: The authors reported no conflicts of interest.

The *Journal* policy requires editors and reviewers to disclose conflicts of interest and to decline handling or reviewing manuscripts for which they may have a conflict of interest. The editors and reviewers of this article have no conflicts of interest.

Received for publication June 9, 2022; revisions received Aug 27, 2022; accepted for publication Sept 11, 2022; available ahead of print Sept 26, 2022.

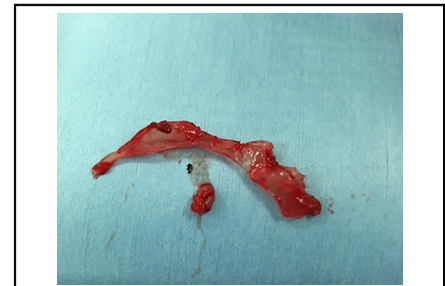Address for reprints: Tomonori Shirasaka, MD, PhD, Department of Cardiac Surgery, Asahikawa Medical University, 1-2-1-1, Midorigaoka-higashi, Asahikawa, 078-8510, Hokkaido, Japan (E-mail: shira.skyrocket@gmail.com).

JTCVS Techniques 2022;16:99-101

2666-2507

Copyright © 2022 The Author(s). Published by Elsevier Inc. on behalf of The American Association for Thoracic Surgery. This is an open access article under the CC BY-NC-ND license (<http://creativecommons.org/licenses/by-nc-nd/4.0/>).

<https://doi.org/10.1016/j.xjtc.2022.09.011>



The removed fibrin mass from the left ventricular cavity.

CENTRAL MESSAGE

Use of fibrin glue in left ventriculoplasty can be dangerous. The recommendations for fibrin glue and intraoperative TEE are vital. The prophylactic use of fibrin glue should be reconsidered.

▶ Video clip is available online.

FG is widely used in cardiac surgery and considered to be safe. Herein, we report a case in which FG used to attain hemostasis of the suture line in left ventriculoplasty leaked into the left ventricular cavity as a floating mass.

CASE PRESENTATION

A 66-year-old man was brought to our department because of a pseudoaneurysm in the posterior wall of the left ventricle (Figure 1). He had undergone an extended sandwich patch procedure 3 years previously for a postmyocardial infarction ventricular septal perforation due to an occlusion of the right coronary artery. Although there were no symptoms, he underwent urgent surgery due to the risk of rupture.

The patient underwent a median sternotomy. Cardiopulmonary bypass was established via the ascending aorta and right atrium. The aorta was clamped, and antegrade cold blood cardioplegia was administered intermittently. When the pseudoaneurysm was incised, a large thrombus was found. The patch on the left ventricular side, which was the orifice of the pseudoaneurysm, was semicircumferentially detached. The orifice was located near the posterior papillary muscle and was subsequently closed using a Dacron patch with double sutures. Beriplast P (CSL Behring K.K.) was applied to suture line with fibrinogen solution and thrombin solution in that order, then BioGlue (CryoLife

Inc) was applied. The outer wall of the pseudoaneurysm was closed, the aorta was declamped, and the heartbeat resumed spontaneously.

Transesophageal echocardiography (TEE) revealed a floating structure around the aortic valve. It was thought that the mitral chorda tendineae were partially ruptured. However, after the second cardioplegic arrest, an incision was made on the right side of the left atrium and a 3- × 20-mm fibrin mass (FM) was found in the left ventricle. The mass was removed, then the aorta was declamped. However, the TEE revealed a structure attached to the back of the anterior leaflet of the mitral valve. After the third cardioplegic arrest, the left ventricular cavity was observed through the aortic valve and a 5- × 10- mm FM was found attached to the papillary muscle of the anterior leaflet of the mitral valve. The mass was removed. During the surgery, heparin was administered to keep the activated clotting time over 400 seconds, and protamine was administered after the second FM removal. Images of the removed masses are shown in Figure 2. The TEE revealed no abnormal structures; therefore, surgery was completed (Video 1). The postoperative course was uneventful, and the patient was discharged unaided on postoperative day 16.

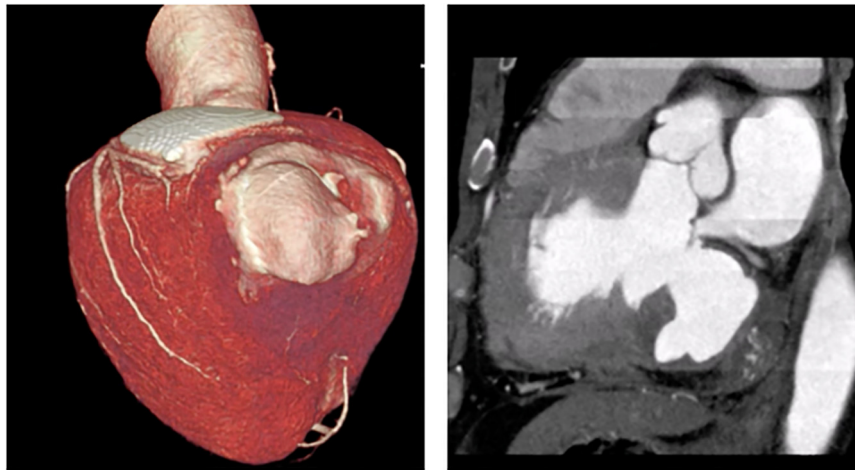

FIGURE 1. A preoperative contrast enhanced computed tomography image. A pseudoaneurysm was found in the in the posterior wall of the left ventricle.

DISCUSSION

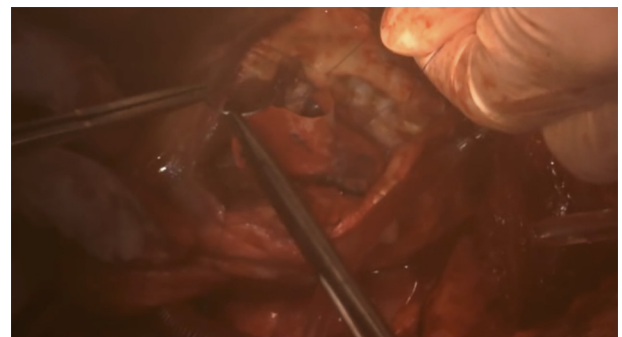
Fibrin glue (FG) is widely used for hemostasis, and its usefulness has been reported. However, the routine use of FG and the necessary precautions to ensure safety need further examination. A systematic review and meta-analysis by Daud and Kaur¹ showed that the use of FG significantly reduced the blood loss and operative time. However, no significant differences in the postoperative blood transfusion volume, reoperation rate, or 30-day mortality were observed. Thus, the study suggested that FG should be used selectively rather than routinely in cardiovascular surgery. The use of FG in coronary artery bypass grafting can reportedly increase the 30-day mortality.² On the basis of these reports, the routine use of FG is not recommended.

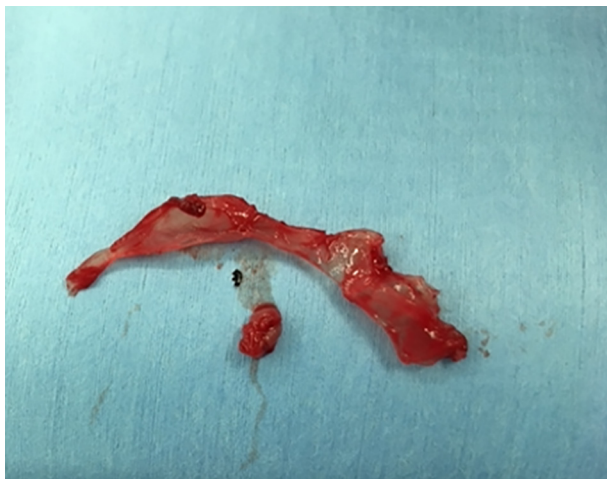

FIGURE 2. The fibrin mass removed from the left ventricular cavity. Fibrin glue used for hemostasis of the suture line after the left ventriculoplasty. The fibrin glue leaked into the left ventricular cavity as a floating mass.

We experienced the FG applied to the outside of the heart, infiltrating the inside of the heart. A similar report described that the FG applied at the anastomosis of a synthetic vessel graft leaked into the aorta and adhered to the aortic valve, emphasizing the importance of a comprehensive TEE study before weaning from cardiopulmonary bypass.³ To avoid serious complications when FG is used, we should evaluate for foreign bodies and other abnormalities.

In this case, the FG was applied without reducing the suction pressure of the left ventricular vent. This negative suction pressure might have caused FG leakage into the cardiac cavity. In addition, the amount of glue applied may have been too much; therefore, it may be better to apply a small amount and add more if insufficient. Having the anastomosed structure filled with blood may be effective too. Minato and Shimokawa⁴ also studied the use of FG for needle holes and found that the rub-and-spray method, ie, rubbing solution A (containing fibrinogen) on the needle holes, followed by spraying both A and B solutions (containing



VIDEO 1. This video shows the pseudoaneurysm incision, left ventriculoplasty, TEE, and removal of the fibrin mass. Video available at: [https://www.jtcvs.org/article/S2666-2507\(22\)00480-1/fulltext](https://www.jtcvs.org/article/S2666-2507(22)00480-1/fulltext).

thrombin and calcium chloride) using an application nozzle, had the best hemostatic effect. The thrombus formation could be prevented by a specific polymerization reaction of the fibrin by spraying solutions A and B.⁴ Despite these improvements, one should be aware of the potential risk of embolic complications caused by FG, and the prophylactic application of FG in left ventriculoplasty should be evaluated further. Informed consent was obtained orally to submit and publish this report.

References

1. Daud A, Kaur B. Fibrin and thrombin sealants in vascular and cardiac surgery: a systematic review and meta-analysis. *Eur J Vasc Endovasc Surg.* 2020;60:469-78.
2. Goerler H, Oppelt P. Safety of the use of Tissucol Duo S in cardiovascular surgery: retrospective analysis of 2149 patients after coronary artery bypass grafting. *Eur J Cardiothorac Surg.* 2007;32:560-6.
3. Nakahira J, Ishii H. Fibrin glue on an aortic cusp detected by transesophageal echocardiography after valve-sparing aortic valve replacement: a case report. *J Med Case Rep.* 2015;9:53.
4. Minato A, Shimokawa T. New application method of fibrin glue for more effective hemostasis in cardiovascular surgery: rub and spray method. *Jpn J Thorac Cardiovasc Surg.* 2004;52:361-6.