

Received: 2014.06.12  
Accepted: 2014.07.18  
Published: 2014.11.21

# Holmium Laser Lithotripsy with Semi-Rigid Ureteroscopy: A First-Choice Treatment for Impacted Ureteral Stones in Children?

Authors' Contribution:  
Study Design A  
Data Collection B  
Statistical Analysis C  
Data Interpretation D  
Manuscript Preparation E  
Literature Search F  
Funds Collection G

AE 1 **Senol Adanur**  
F 2 **Hasan Riza Aydin**  
B 1 **Fatih Ozkaya**  
C 1 **Tevfik Ziypak**  
D 1 **Ozkan Polat**

1 Department of Urology, School of Medicine, Ataturk University, Erzurum, Turkey  
2 Department of Urology, Akçaabat Haçkâli Baba Hospital, Trabzon, Turkey

**Corresponding Author:** Senol Adanur, e-mail: [s.adanur61@hotmail.com](mailto:s.adanur61@hotmail.com)  
**Source of support:** Departmental sources

**Background:** We aimed to assess the effectiveness of semi-rigid ureteroscopy and holmium laser lithotripsy in the treatment of impacted ureteral stones in children.

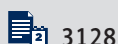
**Material/Methods:** We evaluated a total of 32 children under the age of 18 years treated with ureteroscopic holmium laser lithotripsy for impacted ureteral stones between January 2005 and July 2013. Their stone-free state was defined as the absence of any residual stone on radiologic evaluation performed 4 weeks postoperatively. Complications were evaluated according to the modified Clavien classification.

**Result:** The mean patient age was  $9.5 \pm 5.1$  years (range 1–18 years). Seven (21.8%) of the stones were located in the proximal ureter, 9 (28.2%) were in the mid-ureter, and 16 (50%) were in the distal ureter. The mean stone size was calculated as being  $10.46 \pm 3.8$  mm<sup>2</sup> (range 5–20). The stone-free rate was 93.75% (30/32 patients) following primary URS. Additional treatment was required for only 2 (6.25%) of the patients. After the procedure, a D-J stent was placed in all the patients. The total complication rate was 15.6% (5 patients). The 10 total complications in these 5 patients were 5 (15.6%) Grade I, 1 (3.1%) Grade II, 2 (6.25%) Grade IIIa, and 2 (6.25%) Grade IIIb. The mean follow-up period was 16.5 months (range 3–55).

**Conclusions:** For the treatment of impacted ureteral stones in children, holmium laser lithotripsy with semi-rigid ureteroscopy, with its low retreatment requirement and acceptable complication rates, is an effective and reliable method in experienced and skilled hands as a first-choice treatment approach.

**MeSH Keywords:** **Child • Holmium • Lasers • Ureteral Calculi**

**Full-text PDF:** <http://www.medscimonit.com/abstract/index/idArt/891173>



## Background

Endoscopic treatment of stone disease in children has developed dramatically during the last 2 decades. Since the first pediatric ureteroscopic procedure in 1988 [1], ureterorenoscopy (URS) has become a more attractive option for treating children due to significant improvements in the miniaturization and durability of endoscopic equipment. In addition to stone burden and localization, anatomic limitations, patient factors, and stone characteristics also play important roles in the choice of URS treatment [2].

In adults, impacted stones are defined as stones that remain in the same position for at least 2 months, with no visualization of contrast beyond the stone and no ability to pass a guidewire beside the stone [3,4]. Extracorporeal shockwave lithotripsy (SWL) is a noninvasive method of treating stones. However, stone-free rates are dramatically lower in impacted stone cases than in cases involving other stones, as there is no area of enlargement around impacted stones [5,6]. Ureteroscopic intracorporeal lithotripsy has recently become the treatment of choice for treating impacted ureteral stones [7]. While studies on the effectiveness of ureteroscopic holmium laser use in adults for the treatment of impacted ureteral stones at various localizations have been reported in the literature, no studies specific to children have been conducted.

Thus, the aim of this study was to evaluate the effectiveness of this procedure in the treatment of impacted ureteral stones with different localizations in children. To our knowledge, this is the first published series evaluating the effectiveness of ureteroscopic holmium laser lithotripsy in treating impacted ureteral stones in children.

## Material and methods

### Patients

We evaluated 32 patients under the age of 18 years with impacted ureteral stones of different localizations who were treated with ureteroscopic holmium laser lithotripsy between January 2005 and July 2013. A total of 2420 URS procedures were performed in our clinic during this time period, of which 177 were performed on children under the age of 18. In the literature, the definition of impacted ureteral calculi includes a <20 mm impacted stone remaining in the same position in 2 sequential kidney-ureteral-bladder (KUB) radiographs taken at least 1 month apart; inability to visualize beyond the stone with contrast agent via intravenous urography (IVU) or preoperative retrograde ureterography; and inability to pass a guidewire beside the stone [3,4]. In our study, an impacted ureteral stone was defined as calculi that remain in the same

position for more than 1 month and cause ureteral obstruction, with non-visualization of contrast medium beyond the stone on IVU or failure to pass a guidewire beside the stone.

We excluded from the study any patients with a history of ipsilateral stricture, postural abnormality, renal failure, previous urethra reimplantation surgery, active urinary tract infection, previously unsuccessful URS procedures, or coagulation disorder.

The preoperative evaluation included a careful medical history, clinical examination, routine blood tests, urinalysis, urine culture, KUB radiography, renal ultrasonography (US), and IVU or non-contrast computerized tomography (NCCT). The diagnosis of impacted stones in patients who had not undergone IVU preoperatively was confirmed via preoperative retrograde ureterography and/or ureteroscopic visualization under direct vision. Renal scintigraphy and computerized tomography were not performed routinely; however, they were used when required. A primary metabolic examination was performed on all patients. The size of the stone was calculated according to the guidelines of the European Association of Urology (EAU) [8].

Prophylactic preoperative wide-spectrum antibiotics were given to patients with sterile urine. Patients with positive urine cultures underwent URS after being treated with the appropriate antibiotics. Sepsis due to obstructed kidneys was not detected in any of the patients with urinary tract infections.

Patient demographics, localization and sizes of stones, stone-free state, additional treatment requirements, duration of surgery, complication rates, and follow-up results were evaluated.

### Surgical technique

All of the procedures were performed by surgeons with high levels of ureteroscopy experience. The URS procedure was performed with the patient under general anesthesia and on a urologic table with a C-armed fluoroscopy unit at the lithotomy position. After entering the bladder with the ureteroscope, retrograde ureterography was performed using 3F or 4F open-end ureteral catheters. The safety wire was gently advanced in an attempt to provide passage to the distal side of the stone. In all cases, the impaction of the stones to the ureteral mucosa was confirmed endoscopically. In patients in whom the guidewire could not be passed beyond the stones before the procedure, lithotripsy under direct vision was performed meticulously, using circular movements exerted on the center of the stone without nearing the junction between the ureteral mucosa and the stone. Fragmented stones were crushed into powder, after which a safety wire was passed proximally beyond the stone. During the procedure, 0.025- or 0.035-inch hydrophilic guidewires were used as safety wires.

The procedures were performed with a 6.4F Olympus® or 4.5F Wolf® semi-rigid ureteroscope under ureter calibration. For stone fragmentation, an Auriga® or StoneLight® holmium laser lithotripter was used. The laser was set at a 0.6–1.5 J energy pulse and a 4–12 Hz frequency over 273 or 365 μ laser fibers. During the procedure, when the ureter distal to the stone was appropriate, large fragmented stones were removed with forceps. Small pieces measuring <2 mm were left for spontaneous passage. At the end of the procedure, to prevent the transient obstruction that can develop due to ureteral edema and to provide postoperative drainage, 3F or 4F double-J (D-J) stents were placed in all patients. The ureteral stents were removed at 3–4 weeks postoperatively under short-duration anesthesia. Complications were grouped according to the modified Clavien grading system [9].

### Followup

On the first postoperative day, all of the patients were evaluated using KUB radiography and renal US. The patients were followed up every 3 months for the first year, and every 6 months thereafter. At each control visit, the patients were evaluated via urinalysis, urine cultures, KUB radiography, and renal US for the presence of residual stones, hydronephrosis, and urinary tract infection. Patients with suspected hydronephrosis and stones were evaluated by NCCT. When planning the study, the patients were recruited via telephone and controlled via IVU regarding the presence of ureteral stricture. A stone-free state was defined as the absence of residual stones at Week 4, determined using renal ultrasonography and KUB radiography, as well as low-dose NCCT for radiolucent stones.

### Results

Thirty-two children were included in the study; 14 (43.7%) patients had a previous history of stones and 12 (37.5%) patients had a history of unsuccessful SWL. The most prevalent presenting symptom was flank or abdominal pain, which occurred in 18 (56.3%) patients. The other common symptoms were hematuria, which occurred in 9 (28.1%) patients, and urinary tract infection, which was confirmed by urine culture in 5 (15.6%) patients.

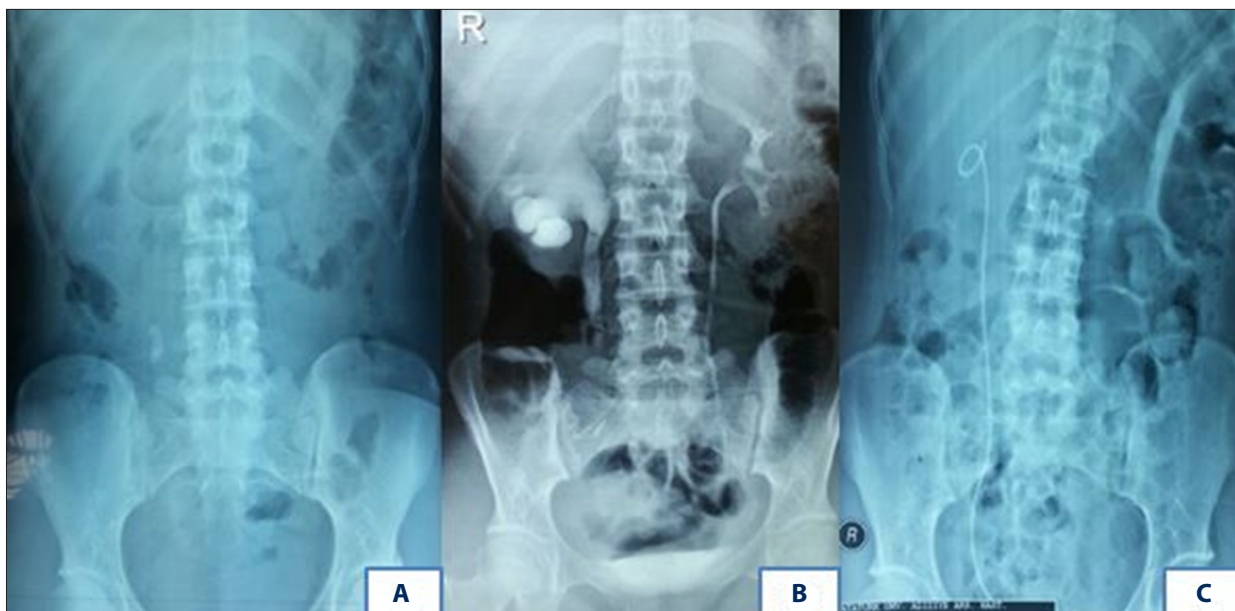
The demographic and stone characteristics of the patients are listed in Table 1. The mean duration of the operation was 37.3±6.5 min (range 25–50 min). None of the patients had stenosis requiring balloon dilatation in the distal side of the stone. The stone-free rate was 93.75% (30/32 patients) after primary URS. During the same time period, in our clinic, the stone-free rate after primary URS in 145 pediatric patients who underwent ureteroscopic lithotripsy due to non-impacted ureteral stones was 95.2% (138/145). Figure 1A–1C shows

**Table 1.** Stone parameters and demography of the patients.

Characteristics	
Number of patients	32
Gender (male: female)	17/15
Mean age (years)	9.5±5.1 (1–18)
History of stone disease	14 (43.7%)
History of unsuccessful SWL	12 (37.5%)
Clinical presentation (%)	
Abdominal or flank pain	18 (56.3)
Hematuria	9 (28.1)
Urinary tract infection	5 (15.6)
Stone side	
Right (%)	20 (62.5)
Left (%)	12 (37.5)
Stone size (mm <sup>2</sup> )	10.46±3.8 (5–20)
Stone location (%)	
Proximal	7 (21.8)
Middle	9 (28.2)
Distal	16 (50)
Degree of hydronephrosis (%)	
Grade I	11 (34.3)
Grade II	13 (40.6)
Grade III	8 (25)
Mean follow-up (months)	16.5±14.2 (3–55)

a single-session holmium laser lithotripsy procedure with the successful fragmentation of an impacted right ureter stone in a 16-year-old child. Additional treatment was required in only 2 (6.25%) patients, in which stones were displaced during the procedure and migrated into the kidney. D-J stents were placed in the 2 patients during the procedure, and they were treated with SWL afterwards; they were stone-free after 1 SWL session. All patients were given D-J stents following the procedure. The mean hospital stay was 1.87±1.4 days (range 1–7).

Five patients (15.6%) experienced 4 intraoperative and 6 postoperative complications. The complication distribution according to the Clavien classification is listed in Table 2. Following the modified Clavien classification, Grade I complications were recorded in 5 (15.6%) patients, Grade II complications were recorded in 1 (3.1%) patient, Grade IIIa complications were recorded in 2 (6.25%) patients, and Grade IIIb complications



**Figure 1.** (A) KUB radiograph view of the right upper ureter stone. (B) IVU shows right ureterohydronephrosis caused by impacted ureteral calculi. (C) KUB radiograph view of the right DJ stent after treatment with ureteroscopic lithotripsy.

**Table 2.** Complications according to Clavien classification systems.

	No. of patients	Clavien grade
No. of patients without complications	27	0
Intraoperative complications		
Intrarenal stone migration	2	IIIb
Small mucosal laceration (without leakage)	2	IIIa
Early postoperative complications		
Pain necessitating analgesic	4	I
Fever	1	I
Febrile urinary tract infection	1	II

were recorded in 2 (6.25%) patients. In 2 patients (age 1 and 6 years) with Grade II hydronephrosis, upper ureter stones migrated into the kidney due to the forceful impact of the irrigation fluid delivered during the laser lithotripsy. Because of diffuse edema in the region of the stone impaction and the large size of the stones, small mucosal lacerations were incurred during lithotripsy in a female patient and a male patient, both age 9 years, with mid-ureteral stones measuring 19 mm and 15 mm in diameter, respectively. Postoperative pain occurred in 4 patients, who were treated with oral analgesics. Postoperative fever developed in an 8-year-old male patient who had an 11-mm stone in the upper ureter. This patient, who

had a sterile urine culture, was managed successfully with intravenous analgesics and antipyretic. In addition, the 1-year-old male patient who experienced intrarenal stone migration also developed a postoperative febrile urinary tract infection. His postoperative urine and blood cultures were sterile, and he was treated successfully with oral antibiotics. Three weeks later, he was treated with SWL.

The D-J stents of the 2 patients with intrarenal stone migration who were treated with SWL were removed under short-term anesthesia 1 week after SWL, following confirmation of a completely stone-free state. The D-J stents inserted following lithotripsy in the 2 patients with small intraoperative mucosal lacerations were removed 4 weeks after the URS procedure. Before the extraction of the D-J stents in these patients, a 4.5F semirigid ureterorenoscope was passed proximally through the edge of the D-J stent. Complete healing of the region of stone impaction and mucosal lesions was observed.

Long-term follow-up was conducted in 71.8% (23/32) of the patients. During the planning phase of this study, the mean follow-up period of these 23 patients invited for follow-up visits was 16.5 months (range 3–55). The follow-up duration was longer than 1 year in 11 patients (34.3%). Ureteral stricture was not observed in any of the patients during the long-term follow-up.

## Discussion

In recent years, many investigations have focused on the acceleration of the spontaneous passage of ureteral stones using

certain drugs and medicines. Among these, analgesic agents, anti-inflammatory drugs, calcium antagonists, and alpha-1 blockers are the most commonly used drugs. Although alpha blockers are widely used in adults, there have been few studies demonstrating their efficacy and safety in children. According to EAU guidelines, medical expulsive therapy is not recommended for this specific patient population [10].

Although SWL is still the first step in the treatment of many ureteral stones, it might not be successful for calcium oxalate monohydrate or cystine stones, impacted stones, stones >10 mm in size, and stones in children with unsuitable anatomies [11,12]. It might be difficult to fragment some stones with SWL, and stone pieces can remain in the urinary tract even after successful stone fragmentation [13]. In particular, the success rate of SWL is low when treating impacted ureter stones, most likely due to the absence of an expandable area around the stone [14]. These stones can also lead to infections and pain because of the obstruction they cause in the pelvicaliceal system [15]. If not treated immediately, partial or total loss of the renal unit may ensue. Decompression of the obstructed urinary tract via surgery or transient urinary diversion is very important [14]. Twelve of the children in our series had a history of previously unsuccessful SWL.

Historically, ureteroscopy has been used after failure of SWL for upper-tract stones and stones below the iliac crests. However, it has not been considered a primary treatment for upper-tract stones in children, due to concerns regarding the development of vesicoureteral reflux, which can develop as a result of dilatation of small ureteral orifices, ureteral ischemia, perforation, and stricture formation [16]. The use of ureteroscopy to treat stone disease in children is less common than in adults because the incidence of lower ureteral stone formation in children, higher clearance rates from stone fragments after SWL, and concerns about entering small ureters with large ureteroscopes [17,18].

The endoscopic treatment of upper ureteral stones with a semirigid ureteroscope is a well-known and commonly used technique. However, after the introduction of small-caliber flexible ureteroscopes and laser lithotripsy, the use of semirigid ureteroscopes for upper ureteral stones has become controversial. Some authors defend the use of semirigid ureteroscopes in the absence of flexible instruments [19]. In addition, the absence of sufficient experience with the use of flexible instruments in children and the high cost of the instruments are other factors limiting their use.

The success rates of ureteroscopic treatment are similar to or higher than those of SWL, with better rates in the immediate resolution of obstructions and faster cleaning of the stone [20]. The holmium laser, which is a mode of intracorporeal lithotripsy,

is widely used in endourology practice because of the minimal thermal injury related to laser ablation and its success in fragmenting all stone components [21]. In addition, holmium lasers can vaporize soft tissues and cause coagulation, and they have excellent cutting ability. Thus, they can be used to treat ureteral strictures and polyps, which commonly accompany impacted stones, by reducing costs and time required. Moreover, they have a limited tissue penetration of 0.5 mm, which makes them one of the safest types of lithotripters. These properties make the holmium laser a very good instrument for the treatment of impacted stones [22]. Dretler et al. [5] reported the proven role of intracorporeal laser lithotripsy in the treatment of non-impacted ureteral stones, stones in which SWL was unsuccessful, and impacted ureteral stones at all levels of the ureter. However, Seitz et al. found no significant difference between the duration of surgery for non-impacted and impacted stones treated with holmium lasers. In the same study, it was reported that the stone-free rate associated with holmium lithotripsy was related to the degree of impaction and the localization of the stone, but was not related to grade of hydronephrosis, stone size, or stone composition [23].

To our knowledge, there are no studies available in the literature that show the effectiveness of holmium lasers on impacted ureteral stone treatment in children. With increasing acquisition of ureteroscopic skills, improved technology, and enhanced adjunctive devices, URS will play a major role in the management of these difficult cases [24]. Jiang et al. [25] reported a fragmentation success rate of 93.9% in their study in which they presented the effectiveness of the holmium laser with the use of semirigid ureteroscopy in the emergency treatment of acute renal failure caused by impacted ureteral stones in adults. Pardalidis et al. [26] used flexible URS together with a ureteral access sheath in the management of small impacted lower ureteral stones, comparing the technique with the standard technique. They reported a 95.8% stone-free rate when they used the ureteral access sheath in this faster and safer procedure for managing small, impacted lower ureteral stones. Degirmenci et al. [14], used holmium laser lithotripsy in 105 adult patients with impacted ureteral stones at different localizations and reported success rates of 95.7%, 88.8%, and 81.8% in lower, middle, and upper ureteral stones, respectively. We observed a 93.75% treatment success rate after a single-session procedure with holmium laser lithotripsy and semirigid URS in our series of children under the age of 18 with impacted ureteral stones. Similar success rates were achieved in our clinic during the same period in pediatric patients who underwent non-impacted ureteral stone treatment.

The use of postoperative ureteral stents is another issue that must be discussed. The most important advantage of placing a stent is to prevent renal colic development; in other words,

ureteral obstruction due to the passage of fragments or ureteral edema. In addition, ureteral dilatation caused by ureteral stents may facilitate the passage of small stone particles. The prevention of strictures and faster healing of the ureter are accepted as the other advantages of stent application [27]. In our series, a D-J stent after the procedure was required for all children with impacted ureteral stones to avoid edema, inflammation, and sudden ureteral obstructions that can be caused by stone particles.

While most ureteroscopic procedures can be classified as uncomplicated, procedures involving impacted ureteral stones cannot be viewed as uncomplicated, and they can result in severe ureteral inflammation. There is an increased risk of ureteral injury caused by the instruments used in these endoscopic procedures [4]. Ureteroscopic interventions can cause complications such as ureteral perforation, problems with entry, stone migration, urosepsis, and ureteral stricture [28]. Stone burden, stents, orifice dilatation, institutional experience, patient age, and duration of the operation are important risk factors for complications that can develop during URS procedures [29]. In their study of impacted ureteral stones in adults, Degirmenci et al. [14] reported a total complication rate of 25.7%. In our series of pediatric impacted ureter stone cases, the total complication rate was determined to be 15.6%. We believe that the placement of postoperative D-J stents in all of our patients was shown to be effective by our low complication rate.

Ureteral stricture formation related to impacted stones is a well-known complication and may develop as a result of the instrumentation used for ureteral stone treatment. Factors include direct mechanical trauma, relative ischemia due to large instruments, and thermal injury [30]. In addition, periureteral fibrosis can develop when urine is extracted from the ureter,

particularly in the presence of infection [31]. Binbay et al. compared the effectiveness of pneumatic and laser lithotripters in the treatment of impacted ureteral stones. They found that while 2.5% of the pneumatic group developed ureteral strictures during long-term follow-up, none of the patients in the laser group did [32]. In our series, no ureteral stricture was detected with IVU in any of the 23 patients (71.8%), who were followed for an average of 16.5 months. The lack of postoperative ureteral stricture development and our reasonable complication rates can be explained by our high level of institutional experience with ureteroscopic procedures, gentler ureteroscopic manipulations, use of appropriate ureteroscopes in terms of patient age, and ureteral calibration during the procedures, as well as the placing of postoperative D-J stents in all patients.

The retrospective nature of our study, the limited number of patients, follow-up periods that were not long enough to determine the safety of the procedure, and the inability to perform follow-ups on patients referred to our clinic from other provinces can be counted among the limitations of our study.

## Conclusions

Holmium laser lithotripsy with semirigid URS, when performed by skilled hands with experience gained from adult patients, has low retreatment requirements, similar success rates as non-impacted ureteral stone treatment, and acceptable complication rates, thus making it an effective method as the first-choice treatment for impacted ureteral stones in children.

## Conflict of interest

The authors declare that they have no conflict of interest.

## References:

- Ritchey M, Patterson DE, Kelalis PP et al: A case of pediatric ureteroscopic lasertripsy. *J Urol*, 1988; 139: 1272-74
- Granberg CF, Baker LA: Urolithiasis in children: surgical approach. *Pediatr Clin North Am*, 2012; 59(4): 897-908
- Deliveliotis C, Chrisofos M, Albanis S et al: Management and follow up impacted utereral stones. *Urol Int*, 2003; 70: 269-72
- Morgentaler A, Bridge SS, Dretler SP: Management of the impacted ureteral calculus. *J Urol*, 1990; 143: 263-66
- Dretler SP, Keating MA, Riley J: An algorithm for the management of ureteral calculi. *J Urol*, 1986; 136: 1190-93
- Lingeman JE, Shirrell WL, Newman DM et al: Management of upper ureteral calculi with extracorporeal shock wave lithotripsy. *J Urol*, 1987; 138: 720-23
- Mugiya S, Nagata M, Un-No T et al: Endoscopic management of impacted ureteral stones using a small caliber ureteroscope and a laser lithotripter. *J Urol*, 2000; 164: 329-31
- Turk C, Knoll T, Petrik A et al: Guidelines on urolithiasis. *Eur Assoc Urol*, 2010; 1-106
- Dindo D, Demartines N, Clavien PA: Classification of surgical complications: a new proposal with evaluation in a cohort of 6336 patients and results of a survey. *Ann Surg*, 2004; 240: 205-13
- Turk C, Knoll T, Petrik A et al: Guidelines on urolithiasis. *Eur Assoc Urol*, 2013; 1-100
- Landau EH, Gofrit ON, Shapiro A et al: Extracorporeal shock wave lithotripsy is highly effective for ureteral calculi in children. *J Urol*, 2001; 165(6): 2316-19
- Hochreiter WW, Danuser H, Perrig M et al: Extracorporeal shock wave lithotripsy for distal ureteral calculi: what a powerful machine can achieve. *J Urol*, 2003; 169(3): 878-80
- Brito AH, Mitre AI, Srougi M: Ureteroscopic pneumatic lithotripsy of impacted ureteral calculi. *Int Braz J Urol*, 2006; 32: 295-99
- Degirmenci T, Gunlusoy B, Kozacioglu Z et al: Outcomes of ureteroscopy for the management of impacted ureteral calculi with different localizations. *Urology*, 2012; 80(4): 811-15
- Cheung MC, Lee F, Yip SK et al: Outpatient holmium laser lithotripsy using semirigid ureteroscope. Is the treatment outcome affected by stone load? *Eur Urol*, 2001; 39: 702-8
- Smaldone MC, Cannon GM Jr, Wu HY et al: Is ureteroscopy first line treatment for pediatric stone disease? *J Urol*, 2007; 178(5): 2128-31
- Gofrit ON, Pode D, Meretyk S et al: Is the pediatric ureter as efficient as the adult ureter in transporting fragments following extracorporeal shock wave lithotripsy for renal calculi larger than 10 mm? *J Urol*, 2001; 166: 1862-64

18. Gillespie RS, Stapleton FB: Nephrolithiasis in children. *Pediatr Rev*, 2004; 25: 131–39
19. Elganainy E, Hameed DA, Elgammal M et al: Experience with impacted upper ureteral stones; should we abandon using semirigid ureteroscopes and pneumatic lithoclast? *Int Arch Med*, 2009; 2(1): 13–17
20. Netto Júnior NR, Claro JF, Lemos GC et al: Treatment options for ureteral calculi: endourology or extracorporeal shock wave lithotripsy. *J Urol*, 1991; 146: 5–7
21. Wollin TA, Denstedt JD: The holmium laser in urology. *J Clin Laser Med Surg*, 1998; 16: 13–20
22. Dushinski JW, Lingeman JE: Urologic applications of the Holmium laser. *Tech Urol*, 1997; 3: 60–64
23. Seitz C, Tanovic E, Kikic Z et al: Impact of stone size, location, composition, impaction, and hydronephrosis on the efficacy of holmium: YAG laser ureterolithotripsy. *Eur Urol*, 2007; 52: 1751–59
24. Skolarikos AA, Papatsoris AG, Mitsogiannis IC et al: Current status of ureteroscopic treatment for urolithiasis. *Int J Urol*, 2009; 16(9): 713–17
25. Jiang H, Wu Z, Ding Q: Ureteroscopy and holmium: YAG laser lithotripsy as emergency treatment for acute renal failure caused by impacted ureteral calculi. *Urology*, 2008; 72(3): 504–7
26. Pardalidis NP, Papatsoris AG, Kapotis CG et al: Treatment of impacted lower third ureteral stones with the use of the ureteral access sheath. *Urol Res*, 2006; 34(3): 211–14
27. Cevik I, Dillioglugil O, Akdas A et al: Is stent placement necessary after uncomplicated ureteroscopy for removal of impacted ureteral stones? *J Endourol*, 2010; 24(8): 1263–67
28. Parker BD, Frederick RW, Reilly TP et al: Efficiency and cost of treating proximal ureteral stones: shock wave lithotripsy versus ureteroscopy plus holmium: yttrium-aluminum-garnet laser. *Urology*, 2004; 64: 1102–6
29. Dogan HS, Onal B, Satar N et al: Factors affecting complication rates of ureteroscopic lithotripsy in children: results of multi-institutional retrospective analysis by Pediatric Stone Disease Study Group of Turkish Pediatric Urology Society. *J Urol*, 2011; 186(3): 1035–40
30. Motola JA, Smith AD: Complications of ureteroscopy: prevention and treatment. *AUA update series 1992; Volume 11, lesson 21*
31. Mitchinson MJ, Bird DR: Urinary leakage and retroperitoneal fibrosis. *J Urol*, 1971; 105: 56–58
32. Binbay M, Tepeler A, Singh A et al: Evaluation of pneumatic versus holmium: YAG laser lithotripsy for impacted ureteral stones. *Int Urol Nephrol*, 2011; 43(4): 989–95