Case Report

SAGE Open Medical Case Reports

SAGE Open Medical Case Reports
Volume 12: 1–9

DOI: 10.1177/2050313X241236313
journals.sagepub.com/home/sco
Sage

Surfactant therapy using vibrating-mesh nebulizers in adults with COVID-19-induced ARDS: A case series

Killen H Briones-Claudett[1,2*], Mónica H Briones-Claudett[2*], Cynthia K Bajaña Huilcapi[2], Olga Elizabeth Tripul Villamar[2], Rosario Ochoa Vásquez[2], Carolina del Rosario Rivera Salas[2,3], Killen H Briones-Zamora[4], Jaime Benites Solis[3], Diana C Briones-Márquez[5], Amado X Freire[6] and Michelle Grunauer[7]

Abstract

Coronavirus adult respiratory distress syndrome, characterized by decreased surfactant due to lysis of type II pneumocytes and hyaline membrane formation, contributes to severe hypoxemia. The administration of surfactant via high-flow nasal cannula (HFNC) may positively affect lung structure and function in this context. In this study, we report on five clinical cases, encompassing patients aged 40–60 years of both sexes, who tested positive for coronavirus disease 2019 via real-time polymerase chain reaction and exhibited significant pulmonary compromise with elevated inflammatory biomarkers. These patients were treated with aerosol therapy using surfactant delivered through vibrating-mesh nebulizers alongside HFNC. Of these patients, four demonstrated positive responses to the treatment, suggesting that aerosol therapy with surfactant through vibrating-mesh nebulizers could be a viable rescue therapy in adults receiving HFNC oxygen therapy for hypoxemic respiratory failure caused by severe acute respiratory syndrome coronavirus 2 (SARS-CoV-2). Unfortunately, one patient had a negative outcome and succumbed. The findings from these cases indicate that the use of aerosol therapy with vibrating-mesh nebulizers as rescue therapy might offer an alternative approach for managing adults with hypoxemic respiratory failure due to SARS-CoV-2, as evidenced by the positive outcomes in four out of the five cases presented.

Keywords

SARS-CoV-2, ARDS, surfactant, high flow oxygen therapy, vibrating-mesh nebulizers

Date received: 22 August 2023; accepted: 14 February 2024

Introduction

The severe acute respiratory syndrome coronavirus 2 (SARS-CoV-2) binds to epithelial cells through angiotensin-converting enzyme 2 (ACE2) and damages the alveolar lining, especially of type II pneumocytes.[1] The virus damages alveolar cells, promoting cell lysis and apoptosis and causing diffuse alveolar damage with fibrin-rich hyaline membrane formation and some multinucleated giant cell infiltration, leading to coronavirus respiratory distress syndrome. It is characterized by severe hypoxemia due to alterations in pulmonary compliance and elastance, damage to pulmonary flow, and hypoxemic pulmonary vasoconstriction.[2]

Type II pneumocytes synthesize and secrete pulmonary surfactant, which covers the alveolar air–liquid interface, minimizing surface tension and avoiding alveolar collapse.[3] Traditional approaches to surfactant replacement therapy in acute respiratory distress syndrome include invasive methods for instillation.

[1]Facultad de Medicina, Universidad de Las Americas, Quito, Ecuador
[2]Intensive Care Unit, Ecuadorian Institute of Social Security, Babahoyo, Ecuador
[3]Omni Hospital, Guayaquil, Ecuador
[4]Universidad Espíritu Santo, Samborondón, Ecuador
[5]Faculty of Medical Sciences, University of Guayaquil, Guayaquil, Ecuador
[6]Division of Pulmonary, Critical Care, and Sleep Medicine, The University of Tennessee Health Science Center, Memphis, TN, USA
[7]School of Medicine, Universidad San Francisco de Quito, Quito, Ecuador

*These authors contributed equally to this work.

Corresponding Author:
Killen H. Briones-Claudett, Facultad de Medicina, Universidad de las Americas, Redondel del Ciclista, Antigua Vía a Nayron, Quito 170124, Ecuador.
Emails: killenbrio@hotmail.com; killen.briones@udla.edu.ec

Surfactant therapy, traditionally used in neonatal care, has been explored in adults with acute respiratory illnesses. While not considered standard treatment globally, its potential benefits, cost implications, and side effects warrant further investigation. However, the administration of surfactant by nebulization can reduce side effects associated with invasive instillation, such as transient airway obstructions, hypercapnia, and hypoxia.[4]

High-flow nasal cannula (HFNC) oxygen therapy provides heated and humidified oxygen gas, by supplying a controlled fraction of inspired oxygen (FiO_2) and a positive pressure at the end of expiration, improving hypoxemia by decreasing respiratory effort and reducing rebreathing of oxygen and carbon dioxide.[5] HFNC has been proven effective during the coronavirus disease-2019 (COVID-19) pandemic.[6] Nevertheless, concerns about the aerosolization and spread of the virus through these ventilatory support techniques remain under investigation.[7]

The vibrating-mesh nebulizer is used in ventilatory support with a higher performance and drug absorption than traditional nebulizers.[8] The active vibratory technology applies vibratory energy, generating a low-speed aerosol and allowing the nebulization of viscous solutions. In addition, it allows a greater deposition of the drug compared to traditional nebulizers because of the minimum residual volume remaining in the device after nebulization.[9]

During the early stages of the pandemic, there existed undeniable uncertainty in the optimal management of this novel disease. These rescue measures were desperate attempts to prevent intubation and mechanical ventilation in patients at high risk of mortality. The scarcity of ventilator resources exacerbated this challenge, pushing clinicians to find alternative treatment modalities.[10]

In the context of the escalating crisis caused by SARS-CoV-2 and its resultant hypoxemic respiratory failure, the innovative adaptation of aerosol therapy with surfactant, traditionally used in neonatal populations, is introduced. The dosage, initially modeled after pediatric protocols, was meticulously adjusted based on the clinical response of each adult patient, thus endorsing the extrapolation of treatment strategies from neonates to the adult demographic. This pragmatic approach was pursued amidst a strained healthcare system, which necessitated leveraging any available therapeutic option that offered safety and a potential benefit.

We explore the application of vibrating-mesh nebulizers for administering surfactant to adults on HFNC oxygen therapy, aiming to bridge the treatment gap in severe respiratory conditions. To further elucidate the efficacy and safety of this innovative approach, we present five clinical cases where vibrating-mesh nebulizer-administered surfactant was used as a rescue therapy in adults experiencing hypoxemic respiratory failure due to SARS-CoV-2. These cases were documented during the initial wave of the COVID-19 pandemic in Ecuador in 2020.

Case report

Patient 1

A 49-year-old man presented on day 1 with a 5-day history of progressive dyspnea and fever. His oxygen saturation on ambient air was 85%. Laboratory findings revealed an elevated white cell count of 18,230 per mm^3, a neutrophil count of 12,000 per mm^3, and lymphocytes at 1600 per mm^3. His clinical state was moderately severe with a ratio of oxygen saturation as measured by pulse oximetry/FIO_2 to respiratory rate (ROX index).

ROX index of 5.4. He was immediately commenced on HFNC. The surfactant used was a synthetic formulation prepared as per standard guidelines. On day 3, due to persistent dyspnea and worsening clinical state, aerosol therapy with surfactant was initiated using a vibrating-mesh nebulizer. This was given for 5 days at doses of 100 mg every 12 h without any observed side effects. On day 7 of evolution, HFNC weaning began, and by day 9, he only required a simple nasal cannula with 3 L oxygen. A chest tomography showed significant ground-glass pulmonary opacities, condensation areas, and a crazy-paving pattern. He was discharged from the intensive care unit (ICU) on day 12 and from the hospital on day 14.

Patient 2

A 52-year-old woman presented on day 1 with 4 days of cough, shortness of breath, headache, arthralgias, myalgia, and dyspnea. Her oxygen saturation was 80%. Laboratory examinations showed a white cell count of 8260 per mm^3, 7800 neutrophils per mm^3, and lymphocytes at 530 per mm^3. Her initial ROX index was 5.3, and aerosol therapy with surfactant was initiated on day 2 using a vibrating-mesh nebulizer for 5 days at doses of 100 mg every 12 h. No side effects were noted from the treatment. Tomography displayed significant ground-glass opacities with some condensation areas. She was discharged from the ICU on day 6 and from the hospital on day 8.

Patient 3

A 73-year-old man was admitted with 7 days of flu-like symptoms including fever, dry cough, chest and abdominal pain, diarrhea, dyspnea, and malaise. His oxygen saturation was 85%. Laboratory results showed a white cell count of 11,920 per mm^3, 10,800 neutrophils per mm^3, and lymphocytes at 410 per mm^3. He started aerosol therapy with a vibrating-mesh nebulizer on day 3 which was continued for 5 days at doses of 100 mg every 12 h. On day 7, he showed marked clinical improvement. Tomography revealed ground-glass opacities and condensation areas but no crazy-paving. He was discharged from the ICU on day 10 and from the hospital after 22 days.

Patient 4

A 53-year-old woman with 6 days of persistent cough, high fever, headache, chest pain, and dyspnea was admitted. Her oxygen saturation stood at 80%. Laboratory analysis revealed a white cell count of 10,700 per mm^3, 10,000 neutrophils per mm^3, and lymphocytes at 600 per mm^3. She was started on aerosol therapy with surfactant on day 2, which continued for 5 days. On day 7, her clinical state improved, but she developed a hypertensive crisis likely unrelated to the surfactant therapy. Chest tomography showed ground-glass opacities, condensation areas, and a crazy-paving pattern. She was discharged from the hospital on day 21.

Patient 5

A 60-year-old man presented with 8 days of worsening dyspnea, sore throat, dry cough, general discomfort, and fatigue. His oxygen saturation was recorded at 85%. Laboratory tests showed a white cell count of 10,800 per mm^3, 10,800 neutrophils per mm^3, and lymphocytes at 500 per mm^3. Despite starting aerosol therapy with surfactant on day 10, he showed no significant improvement. Tomography depicted significant ground-glass opacities, condensation areas, and a crazy-paving pattern. On day 14, due to further deterioration, he was intubated and put on invasive mechanical ventilation. Unfortunately, his condition worsened, leading to multiorgan failure, and he died on day 22. A chest radiograph taken on admission and post-treatment is shown in Figure 1.

Alongside surfactant therapy, patients were administered antiviral therapies, anticoagulation, steroids, and other COVID-specific therapies.

Specific surfactant details, the patient's clinical presentations, and observed side effects (if any) are tabulated in Table 1. Arterial blood gas levels before and after treatment are detailed in Table 2.

Surfactant dosing in adults. In neonatal care, surfactant therapy has been a cornerstone for the management of neonatal respiratory distress syndrome (NRDS). The efficacy of surfactants in reducing morbidity and mortality in NRDS led to an interest in its potential benefits for adults with lung conditions, such as ARDS (Acute Respiratory Distress Syndrome). Translating pediatric dosages to adult care, a dose of 100 mg every 12 h via a vibrating-mesh nebulizer is currently being explored. This dose attempts to maintain a therapeutic surfactant level in the alveoli, leveraging the positive outcomes observed in pediatric populations. It is essential to monitor the patient's response and lung mechanics to ensure optimal outcomes.

A chest radiograph on initial evaluation and after aerosol therapy with surfactant through a vibrating-mesh nebulizer is shown in Figure 1. The characteristics of patients are shown in Table 1.

All five patients were subjected to intermittent conscious pronation for 12 hours as a part of their treatment protocol. ABG measurements were taken before surfactant treatment and immediately following the administration of surfactant to evaluate the therapy's acute impact on respiratory function. Arterial blood gas levels before and after aerosol therapy with surfactant through a vibrating-mesh nebulizer are shown in Table 2.

This case series obtained ethical approval from the ad hoc ethics committee of the Ecuadorian Ministry of Public Health (Approval Code: MSP-CGDES-2021-0065-O). It involved the use of the REDCap (Research Electronic Data Capture) is a secure platform application designed to support data capture for research studies). The study was conducted at the Intensive Care Unit, Ecuadorian Institute of Social Security Hospital in Babahoyo, and followed all ethical standards for clinical research. Data collection spanned from July 2020 to March 2021. We confirm that we have obtained written informed consent from the legally authorized representative of the deceased subject for the publication of this case report. This is in addition to the written informed consent obtained from the other subjects. We have ensured that the consent was obtained retrospectively for the deceased subject. We understand and respect the guidelines set by the Committee on Publication Ethics (COPE) and have adhered to them.

Discussion

We report five clinical cases of patients undergoing aerosol therapy with surfactant using HFNC through vibrating-mesh nebulizers and four of them exhibited positive outcomes. Although instillation is the only approved method for the administration of surfactants, current approaches to surfactant replacement therapy for acute respiratory distress syndrome are less invasive than traditional invasive methods. The administration of surfactant by nebulization may reduce side effects associated with instillation such as transient airway obstructions and reflux, hypercapnia, and hypoxia.

Several in vitro and animal studies have explored the usefulness of nebulized surfactants with variable results[10] but few clinical studies have evaluated the efficacy of nebulized surfactants in human infants without ventilation.[11–13] Some of these studies have used jet-type nebulization, which is very ineffective owing to the use of air drags.[14] Nevertheless, other studies have demonstrated that the early use of postnatal nebulized surfactant may reduce the need for intubation in the first 3 days of life compared to nasal continuous positive airway pressure alone.[15]

The beneficial effects of HFNC vary across patients due to its effects on oxygenation and decrease in ventilatory work.[16] The primary concern while using HFNC is the dispersion of aerosol particles. However, dispersion with vibrating-mesh nebulizers is lower than with other oxygenation and ventilation devices. Despite this, the principal advantages of the use of mesh nebulizers are greater efficiency and low risk in the dispersion of particles. In addition,

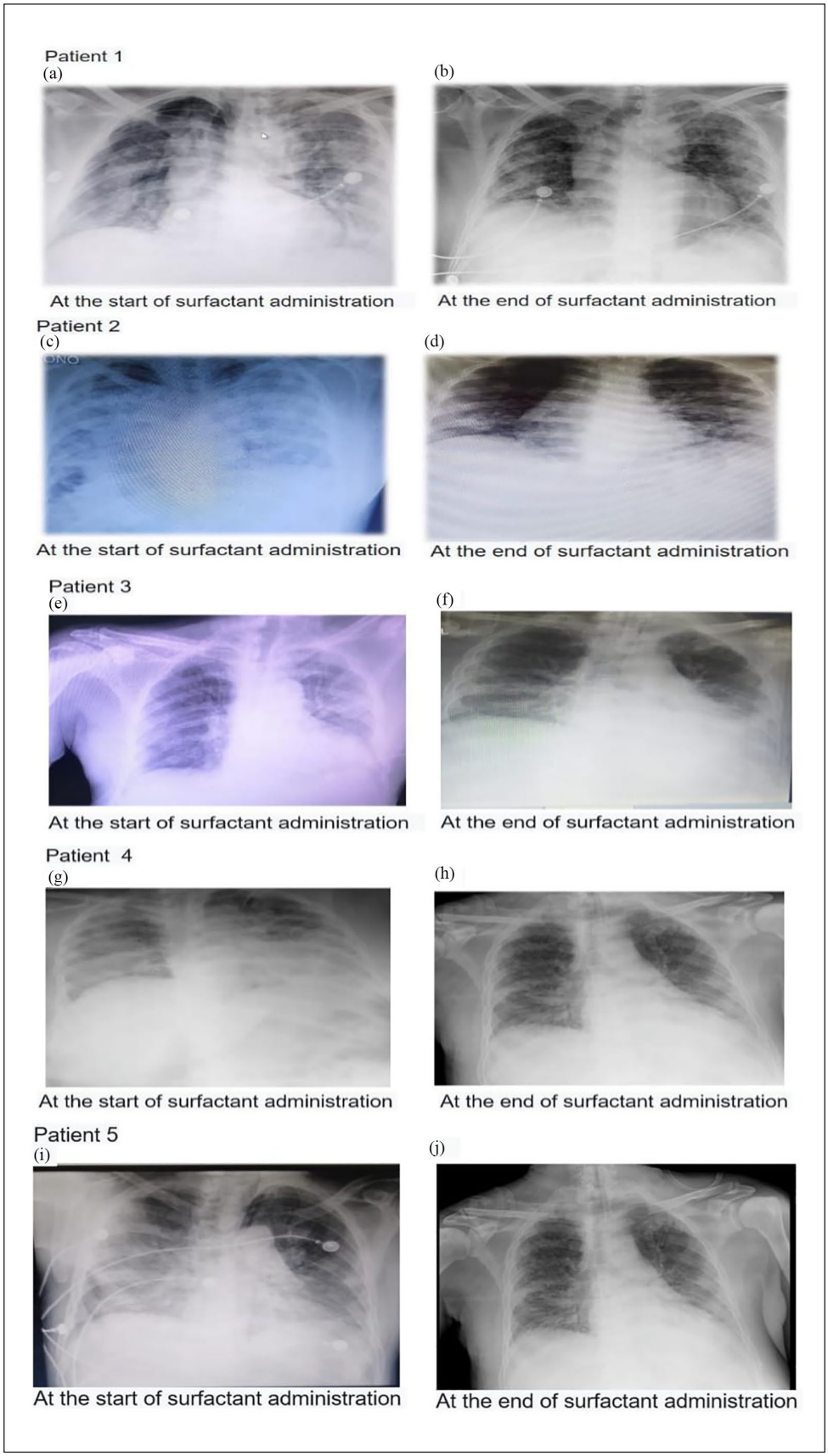

Figure 1. Chest radiograph on initial evaluation and after aerosol therapy with surfactant through a vibrating-mesh nebulizer.

Table 1. Clinical characteristics, laboratory findings, radiologic features, and treatment outcomes of COVID-19 patients.

Characteristics	Patient 1	Patient 2	Patient 3	Patient 4	Patient 5
Age (years)	49	52	73	53	60
Sex	Male	Female	Male	Female	Male
Previous comorbidities	Arterial hypertension	Rheumatoid arthritis	Arterial hypertension	Arterial hypertension plus obesity type II	None
Clinical picture	Fever, dry cough, chest pain, discomfort, dyspnea	Fever, dry cough, headache, arthralgias, myalgia, dyspnea	Fever, dry cough, chest and abdominal pain, diarrhea, dyspnea, malaise	Fever, dry cough, headache, chest pain, dyspnea	Fever, sore throat, dry cough, general discomfort, difficulty breathing
RT-PCR test for SARS-CoV-2	+	+	+	+	+
Oxygen saturation on ambient air (%)	85	80	85	80	85
Laboratory exams					
White cell count (per mm^3) (normal range 4400–10,300)	18,230	8260	11.92	10,700	10,800
Differential count (per mm^3)					
Total neutrophils (normal range 1780–5380)	12,000	7800	10,800	10	10,800
Total lymphocytes (normal range 1180–3740)	1600	530	410	600	500
Total monocytes (normal range 250–710)					
CRP (mg/dL) (normal range 0–5)	30	0.74	398	100	217
Ferritin (ng/mL) (normal range 30–400)	1260	335	1703	1185	2000
Creatinine level (mg/dL) (normal range 0.6–1.2)	1.2	0.9	1.1	1.1	1.3
IL-6 (pg/mL) (normal range 0–6.5)	400	1027	336	250	500
D-dimer (mg/L) (normal range 0–1.9)	0.4	0.3	1.1	0.14	10.28
Procalcitonin (ng/mL) (normal range <0.046)	0.03	0.02	0.55	0.21	1.72
Tomographic findings					
Ground-glass pulmonary opacities	+++	+++	+++	+++	+++
Condensation areas	++	+	+	++	+
Crazy-paving	+	–	–	++	+
Solitary nodule	–	–	–	–	–
Therapeutic management	HFNC oxygen therapy, meropenem, moxifloxacin, dexamethasone, enoxaparin, tocilizumab, simvastatin, antihypertensives	HFNC oxygen therapy, meropenem, moxifloxacin, dexamethasone, enoxaparin tocilizumab, simvastatin	HFNC oxygen therapy, meropenem, moxifloxacin, dexamethasone, convalescent plasma, enoxaparin, simvastatin, antihypertensives	HFNC oxygen therapy, meropenem, moxifloxacin, dexamethasone, enoxaparin, simvastatin, antihypertensives	HFNC oxygen therapy and mechanical ventilation), imipenem + cilastatin, levofloxacin, dexamethasone, enoxaparin, simvastatin
Intubated	No	No	No	No	Yes
Survival	Yes	Yes	Yes	Yes	No

CRP, C-reactive protein; HFNC, high-flow nasal cannula; IL-6, interleukin; RT-PCR, real-time polymerase chain reaction; SARS-CoV-2, severe acute respiratory syndrome coronavirus 2.

Table 2. Arterial blood gas levels before and after aerosol therapy with surfactant through vibrating-mesh nebulizers.

Parameters	Patient 1				Patient 2				Patient 3				Patient 4				Patient 5			
	First doses		Second doses		First doses		Second doses		First doses		Second doses		First doses		Second doses		First doses		Second doses	
ABG	Pre	Post	Pre	Post	Pre	Post	Pre	Post	Pre	Post	Pre	Post	Pre	Post	Pre	Post	Pre	Post	Pre	Post
Ph	7.45	7.53	7.46	7.40	7.45	7.42	7.45	7.43	7.45	7.52	7.44	7.47	7.47	7.43	7.42	7.47	7.45	7.40	7.48	7.51
pCO_2 (mmHg)	32.1	29.5	32.5	40.6	34.9	31.8	34.2	36	32.6	31.5	34	32.4	37.5	45.5	43.8	36.8	27.5	39.3	32.8	29
PO_2 (mmHg)	65.1	95	64.2	72.4	53	147	139	113	65.4	84.5	62.6	61.7	58.5	74.4	45.7	51.3	58.6	134	49	59.4
EB	−1	2.3	−0.4	0.9	−1.5	−3	0	−0.3	−1	3.1	−0.1	0.3	−0.1	−0.2	0.4	3.3	−4.1	0.2	1.1	1.3
HCO_3 (mmol/L)	24.2	27.6	24.7	25.1	23.8	22.1	24.9	25	24	27.9	24.1	25.5	28	29.4	28.5	27.4	21.8	24.7	25.8	26.5
PaO_2/FiO_2 (mmHg)	89	130	107	121	76	210	214	174	93	121	89	88	84	106	57	64	65	149	54	66
SO_2/FIO_2	123	132	148	160	137	141	148	152	136	139	129	134	129	131	111	110	101	107	94	107
FiO_2 (%)	73	73	60	60	70	70	65	65	70	70	70	70	70	70	80	80	90	90	90	90
Flow O_2 (L/min)	50	50	50	50	60	60	60	60	60	60	60	60	60	60	60	60	60	60	60	60
SaO_2 (%)	92.1	99.7	92.6	94.2	91.0	99.0	99.0	98.5	94.3	97.3	87.3	94.3	87.8	94.5	79.7	87.2	89.1	98.8	86.6	95.0
SaO_2 (%) oximeter	90	96	89	96	96	99	96	99	95	97	90	94	90	92	89	88	91	96	85	96
A/P (mmHg)	138/70	133/92	128/88	133/92	125/68	195/66	125/68	120/64	106/60	108/65	118/68	118/65	150/81	169/81	187/92	184/80	130/76	132/65	140/82	136/76
RR	23	17	24	22	26	20	24	18	17	19	22	19	12	12	37	32	26	20	24	18
HR	110	97	106	97	73	72	73	72	58	57	72	69	80	80	97	73	92	80	94	78
ROX index	5.4	7.7	6.2	7.3	5.3	7.1	6.2	8.5	8.0	7.3	5.8	7.1	10.7	11.0	3.0	3.4	3.9	5.3	3.9	5.9

ABG, arterial blood gases; HR, heart rate; PaO_2, partial pressure of arterial oxygen; RR, respiratory rate; ROX index, ratio of oxygen saturation as measured by pulse oximetry/FiO_2 to respiratory rate; SaO_2 (%), arterial oxygen saturation calculated by pulse oximetry; EB, base excess; HCO_3, bicarbonate; SO_2, oxygen saturation.

mesh nebulization provides greater comfort and satisfaction than conventional nebulization (Jet).[17]

Another highlight of the report is the time of intubation in our patients.[18] Although the Surviving Sepsis Campaign Guidelines[19] initially recommended early intubation and invasive mechanical ventilation in patients with acute respiratory failure by COVID-19, recent clinical studies report mixed results for analysis of early versus late intubation mortality.[20] The SARS-CoV-2 in the airways interacts with the layers of respiratory surfactant that line the alveoli. Virus binding to cells occurs by binding to the S1 domain of the Spike protein that binds to the ACE2 receptor on type II pneumocytes in the alveoli.[21]

Surfactant molecules, through their micellar aggregates, bind to these specific regions of the S1 domain, impeding the virus's ability to dock with cells. This interference with viral binding, brought about by exogenous surfactant application, has significant therapeutic potential, potentially altering disease progression as the surfactant blocks the interaction between Spike proteins and ACE2. Moreover, surfactant molecules may integrate into the viral envelope, disrupting its integrity, and leading to viral inactivation through lysis. Consequently, surfactant therapy may offer dual benefits: enhancing alveolar function in a traditional sense and providing antiviral action by both inhibiting cellular entry of the virus and causing its direct inactivation. This dual functionality underlines the necessity for further research into surfactant therapy's comprehensive role in managing respiratory ailments like COVID-19.

The concentration of surfactant at the pulmonary level was not determined in any of these clinical cases; however, the functional inactivation of viral proteins by adsorption of low concentrations of surfactant could be adequate for therapeutics.[22]

Despite biological plausibility,[22,23] few studies have evaluated the use of surfactants in patients with acute respiratory failure due to COVID-19. Piva et al.[24] evaluated the efficacy of intrabronchial instillation in patients with a ratio of partial pressure of arterial oxygen to fraction of inspired oxygen—the potential of hydrogen (quantitative measure of the acidity or basicity of aqueous or other liquid solutions) (PaO_2/FiO_2 ratio) >150 through bronchial copies and demonstrated that it is safe and does not cause decompensation or hemodynamic compromise. Furthermore, Busani et al.[25] reported positive results in four of five patients with a PaO_2/FiO_2 ratio >100 after instilling surfactant under invasive mechanical ventilation.

During the severe COVID-19 wave that overwhelmed the medical community, hospitals faced critical shortages, limited therapeutic options, and mounting pressure for efficient solutions. In this setting, we share our experience treating five adult patients with COVID-19-induced ARDS using surfactant therapy, drawn from neonatal protocols.

Adapting a neonatal protocol, proven safe and effective for newborns, for adult use seemed a logical yet unconventional choice given the urgency. In our series, four of the five patients exhibited significant clinical improvement post-treatment. No significant adverse events were observed directly related to surfactant administration. These findings underscore surfactant's potential as a viable intervention for adults with COVID-19-related ARDS.

Despite the occurrence of a hypertensive crisis in Patient 4, the current evidence does not support a direct link between surfactant administration and elevated blood pressure. The patient's existing comorbidities, specifically arterial hypertension and type II obesity, along with the administration of dexamethasone—a corticosteroid known for its potential to increase blood pressure—suggest a more likely etiology for the hypertensive event. While dexamethasone's anti-inflammatory benefits are well-documented, its propensity to cause hypertension cannot be overlooked, especially in a patient with a history of hypertensive episodes, attributing the hypertensive crisis solely to surfactant therapy would be unsubstantiated, given the absence of robust data connecting the two. Further research is necessary to elucidate any potential causal relationships between surfactant therapy and hypertensive crises.

On the other hand, the delayed administration of surfactant therapy on day 10 for Patient 5 was dictated by the patient's clinical trajectory and the critical escalation of interventions in response to the progressive respiratory decline. Surfactant is often used in severe pulmonary impairment to improve oxygenation and lung mechanics; however, its efficacy can be diminished in the presence of advanced lung damage, as evidenced by the significant ground-glass opacities and crazy-paving pattern seen on tomography. The lack of a significant clinical response and the subsequent need for invasive mechanical ventilation indicate a missed therapeutic window where earlier surfactant administration might have been more beneficial.

However, our primary limitation is that this is merely a case series, limiting generalization and result comparison. In addition, we must consider the possibility that the delivered drug dosage to the lungs might be sub-therapeutic due to various factors:

a. Surfactant micelle size: Evidence suggests that larger molecules, such as those of surfactant micelles, are prone to deposition in the upper airways when administered via HFNC, potentially leading to insufficient concentrations reaching the alveoli.

b. Flow rate and inspiratory flow dynamics: Although HFNC flow was maintained at 50–60 L/min, research indicates that aerosol delivery is more effective when the gas flow is set below the patient's inspiratory flow rate. Especially in patients with distressed breathing patterns, there is an increased likelihood of aerosol deposition in the pharynx due to turbulence. This is significant as the distressed respiratory pattern may result in an inspiratory flow that surpasses the set HFNC flow, thus reducing the efficiency of drug delivery to the lower airways. In addition, we

recognize that the use of HFNC therapy itself varies in effect based on the severity of COVID-19 pneumonia in patients. It has been documented that HFNC reduces intubation rates in cases of severe hypoxemia due to COVID-19[26] and may also exert some benefits in patients with milder forms of hypoxemia.[27] However, our study design does not allow us to definitively differentiate the impact of surfactant administration from the effects attributable to high humidified flows delivered by HFNC. Hence, the potential benefits observed might be confounded by the variable efficacy of HFNC in different severities of disease. Future studies with a control group not receiving surfactant therapy would be valuable to ascertain the independent effect of surfactant in the context of HFNC treatment.[28]

Conclusion

In summary, our case series report during the pandemic highlights that surfactant therapy, adapted from neonatal protocols, may offer a promising avenue for adults with COVID-19-induced ARDS. With four out of five cases responding positively to aerosol therapy using vibratory mesh nebulizers for SARS-CoV-2-induced hypoxemia, these findings underscore the need for further validation through controlled, randomized studies.

Acknowledgements

None.

Author's note

This research was conducted at the Intensive Care Unit, Ecuadorian Institute of Social Security (IESS), Babahoyo, Ecuador.

Author contributions

K.H.B.-C. and M.H.B.-C.: conceptualization and writing—review and editing; C.K.B.H. and O.E.T.V.: methodology and writing—review and editing; R.O.V. and C.d.R.R.S.: investigation; K.H.B.-Z. and D.C.B.-M.: data curation; A.X.F. and M.G.: writing—original draft preparation and supervision. All authors have read and agreed to the published version of the manuscript.

Declaration of conflicting interests

The author(s) declared no potential conflicts of interest for the research, authorship, and/or publication of this article.

Funding

The author(s) received no financial support for the research, authorship, and/or publication of this article.

Ethics approval

This case series obtained ethical approval from the ad hoc ethics committee of the Ecuadorian Ministry of Public Health (Approval Code: MSP-CGDES-2021-0065-O). It involved the use of the REDCap platform for secure patient data management. The study was conducted at IESS Hospital in Babahoyo and followed all ethical standards for clinical research. Data collection spanned from July 2020 to March 2021.

Informed consent

We confirm that we have obtained written informed consent from the legally authorized representative of the deceased subject for the publication of this case report. This is in addition to the written informed consent obtained from the other subjects. We have ensured that the consent was obtained retrospectively for the deceased subject. We understand and respect the guidelines set by the Committee on Publication Ethics (COPE) and have adhered to them.

ORCID iD

Killen H Briones-Claudett https://orcid.org/0000-0002-7778-0362

References

1. Sims AC, Baric RS, Yount B, et al. Severe acute respiratory syndrome coronavirus infection of human ciliated airway epithelia: role of ciliated cells in viral spread in the conducting airways of the lungs. *J Virol* 2005; 79: 15511–15524.
2. Yee M, Domm W, Gelein R, et al. Alternative progenitor lineages regenerate the adult lung depleted of alveolar epithelial type 2 cells. *Am J Respir Cell Mol Biol* 2017; 56: 453–464.
3. Mason RJ. Pathogenesis of COVID-19 from a cell biology perspective. *Eur Respir J* 2020; 55(4): 2000607.
4. Mazela J, Merritt TA and Finer NN. Aerosolized surfactants. *Curr Opin Pediatr* 2007; 19: 155–162.
5. Li J, Fink JB and Ehrmann S. High-flow nasal cannula for COVID-19 patients: low risk of bio-aerosol dispersion. *Eur Respir J* 2020; 55(5): 2000892.
6. Panadero C, Abad-Fernández A, Rio-Ramirez MT, et al. High-flow nasal cannula for acute respiratory distress syndrome (ARDS) due to COVID-19. *Multidiscip Respir Med* 2020; 15(1): 693.
7. Ari A and Moody GB. How to deliver aerosolized medications through high flow nasal cannula safely and effectively in the era of COVID-19 and beyond: a narrative review. *Can J Respir Ther* 2021; 57: 22–25.
8. Dallas RH, Rains JK, Wilder K, et al. The Aerogen® solo is an alternative to the small particle aerosol generator (SPAG-2) for administration of inhaled ribavirin. *Pharmaceutics* 2020; 12(12): 1163.
9. Gowda AA, Cuccia AD and Smaldone GC. Reliability of vibrating mesh technology. *Respir Care* 2017; 62: 65–69.
10. Bianco F, Ricci F, Catozzi C, et al. From bench to bedside: in vitro and in vivo evaluation of a neonate-focused nebulized surfactant delivery strategy. *Respir Res* 2019; 20: 134.
11. Jorch G, Hartl H, Roth B, et al. Surfactant aerosol treatment of respiratory distress syndrome in spontaneously breathing premature infants. *Pediatr Pulmonol* 1997; 24: 222–224.
12. Berggren E, Liljedahl M, Winbladh B, et al. Pilot study of nebulized surfactant therapy for neonatal respiratory distress syndrome. *Acta Paediatr* 2000; 89: 460–464.
13. Finer NN, Merritt TA, Bernstein G, et al. An open label, pilot study of Aerosurf® combined with nCPAP to prevent RDS in

preterm neonates. *J Aerosol Med Pulm Drug Deliv* 2010; 23: 303–309.
14. Santo KP and Neimark AV. Adsorption of pulmonary and exogeneous surfactants on SARS-CoV-2 spike protein. Preprint. bioRxiv, 2022. DOI: 2022.05.04.490631.
15. Minocchieri S, Berry CA and Pillow JJ; CureNeb Study Team. Nebulised surfactant to reduce severity of respiratory distress: a blinded, parallel, randomised controlled trial. *Arch Dis Child Fetal Neonatal Ed* 2019; 104: F313–F319.
16. Tran K, Cimon K, Severn M, et al. Aerosol generating procedures and risk of transmission of acute respiratory infections to healthcare workers: a systematic review. *PLoS One* 2012; 7: e35797.
17. Hui DS, Chow BK, Lo T, et al. Exhaled air dispersion during high-flow nasal cannula therapy versus CPAP via different masks. *Eur Respir J* 2019; 53(4): 1802339.
18. Cinesi Gómez C, Peñuelas Rodríguez Ó, Torné ML, et al. Clinical consensus recommendations regarding non-invasive respiratory support in the adult patient with acute respiratory failure secondary to SARS-CoV-2 infection. *Med Intensiva* 2020; 44: 429–438.
19. Lee YH, Choi KJ, Choi SH, et al. Clinical significance of timing of intubation in critically ill patients with COVID-19: a multi-center retrospective study. *J Clin Med* 2020; 9: 2847.
20. Alhazzani W, Møller MH, Arabi YM, et al. Surviving Sepsis Campaign: guidelines on the management of critically ill adults with Coronavirus Disease 2019 (COVID-19). *Intensive Care Med* 2020; 46: 854–887.
21. Pandya A, Kaur NA, Sacher D, et al. Ventilatory mechanics in early vs late intubation in a cohort of coronavirus disease 2019 patients with ARDS: a single center's experience. *Chest* 2021; 159: 653–656.
22. Kannan SR, Spratt AN, Cohen AR, et al. Evolutionary analysis of the Delta and Delta Plus variants of the SARS-CoV-2 viruses. *J Autoimmun* 2021; 124: 102715.
23. Pramod K, Kotta S, Jijith US, et al. Surfactant-based prophylaxis and therapy against COVID-19: a possibility. *Med Hypotheses* 2020; 143: 110081.
24. Piva S, DiBlasi RM, Slee AE, et al. Surfactant therapy for COVID-19 related ARDS: a retrospective case–control pilot study. *Respir Res* 2021; 22(1): 20.
25. Busani S, Dall'Ara L, Tonelli R, et al. Surfactant replacement might help recovery of low-compliance lung in severe COVID-19 pneumonia. *Ther Adv Respir Dis* 2020; 14: 1753466620951043.
26. Ospina-Tascón GA, Calderón-Tapia LE, García AF, et al. Effect of high-flow oxygen therapy vs conventional oxygen therapy on invasive mechanical ventilation and clinical recovery in patients with severe COVID-19: a randomized clinical trial [published correction appears in *JAMA* 2022; 327(11): 1093]. *JAMA* 2021; 326(21): 2161–2171.
27. Frat JP, Thille AW, Mercat A, et al. High-flow oxygen through nasal cannula in acute hypoxemic respiratory failure. *N Engl J Med* 2015; 372(23): 2185–2196.
28. Dushianthan A, Clark H, Madsen J, et al. Nebulised surfactant for the treatment of severe COVID-19 in adults (COV-Surf): a structured summary of a study protocol for a randomized controlled trial. *Trials* 2020; 21(1): 1014.