

# Right coronary artery originating from the left ventricular outflow tract diagnosed after a Ross procedure: a case report

Prashanth Venkatesh \*, Weiyi Tan , Katia Bravo-Jaimes ,  
and Jamil Aboulhosn 

Division of Cardiology, Department of Medicine, Ahmanson-UCLA Adult Congenital Heart Disease Center, David Geffen School of Medicine, University of California, Los Angeles, 200 Medical Plaza, Suite 202, Los Angeles, CA 90095, USA

Received 4 September 2021; first decision 31 December 2021; accepted 11 June 2022; online publish-ahead-of-print 15 June 2022

## Background

Anomalous coronary origin from the left ventricular outflow tract (LVOT) is an exceedingly rare condition thought to be associated with the bicuspid aortic valve (BAV). While the malignant presentation of this entity has been described, its pathophysiology and diagnostic evaluation are poorly understood.

## Case summary

A 33-year-old woman status post Ross procedure in childhood for congenital aortic stenosis due to BAV with presumed common origin of right and left coronary arteries based on single coronary ostium seen on aortic valve inspection, presented with symptomatic pulmonary regurgitation and stenosis. Invasive left coronary angiography revealed retrograde filling of the right coronary artery (RCA) with systolic washout of contrast indicating a patent RCA ostium. No RCA ostium was found on aortic root injection, but an injection into the LVOT revealed an RCA ostium below the aortic valve. Selective RCA angiography revealed pulsatile antegrade flow down the RCA occurring during systole. There was no anatomic RCA stenosis. We proceeded with valve-in-valve TcPVR. The patient had significant improvement of symptoms and RCA reimplantation was hence deferred.

## Discussion

This case is the first of an anomalous coronary artery arising from the LVOT diagnosed in a patient after the Ross procedure. Our angiograms shed light on the unusual physiology of coronary filling during systole and ischaemia arising from inadequate perfusion gradient between the left ventricle and the coronary during systole, leading to collateralization despite the lack of anatomic stenosis. We urge consideration of this potentially malignant entity in any symptomatic patient, especially with concomitant BAV.

## Keywords

Anomalous coronary artery • Ross operation • Bicuspid aortic valve • Coronary angiography • Case Report

## ESC Curriculum

2.4 Cardiac computed tomography • 3.4 Coronary angiography • 4.7 Pulmonary regurgitation • 7.5 Cardiac surgery • 9.7 Adult congenital heart disease

\* Corresponding author. Tel: +1 310 825 2019, Fax: 424 465 6189, Email: [pvenkatesh@mednet.ucla.edu](mailto:pvenkatesh@mednet.ucla.edu)

Handling Editor: Sylvia Krupickova

Peer-reviewers: Maria Antonieta Albanez A de Medeiros Lopes and Pruthvi C Revaiah

Compliance Editor: Zhiyu Liu

Supplementary Material Editor: Fabienne Vervaat

© The Author(s) 2022. Published by Oxford University Press on behalf of the European Society of Cardiology.

This is an Open Access article distributed under the terms of the Creative Commons Attribution-NonCommercial License (<https://creativecommons.org/licenses/by-nc/4.0/>), which permits non-commercial re-use, distribution, and reproduction in any medium, provided the original work is properly cited. For commercial re-use, please contact [journals.permissions@oup.com](mailto:journals.permissions@oup.com)

## Learning points

- Understand the pathophysiologic considerations of anomalous coronary artery arising from the left ventricular outflow tract (LVOT), including the implications of a systolic-predominant coronary circulation.
- Use multimodality imaging to diagnose anomalous coronary artery arising from the LVOT, with an appreciation for the various diagnostic challenges.
- Understand the implications of anomalous coronary artery arising from the LVOT in patients undergoing cardiac surgery under cardio-pulmonary bypass.

## Introduction

Coronary artery anomalies encompass a wide range of clinical presentations and disease severity, ranging from a complete lack of symptoms to sudden cardiac death. Anomalous coronary origin from the left ventricular outflow tract (LVOT) is an exceedingly rare condition, whose mention in the literature is restricted to isolated case reports. Notably, multiple reports have described an association with bicuspid aortic valve (BAV) and subaortic membrane.<sup>1–3</sup> Patients are usually symptomatic from myocardial ischaemia, with presentations as severe as acute global ischaemia<sup>4</sup> and sudden cardiac death.<sup>5</sup> The pathophysiology is poorly understood due to very limited data, but its potentially malignant presentation indicates an urgency to better understand and diagnose this condition.

We present a 33-year-old patient with a prior Ross procedure and a subvalvular right coronary artery (RCA), which we diagnosed on invasive coronary angiography. Our findings provide crucial insights into the pathophysiology and diagnostic pitfalls of this condition.

## Timeline

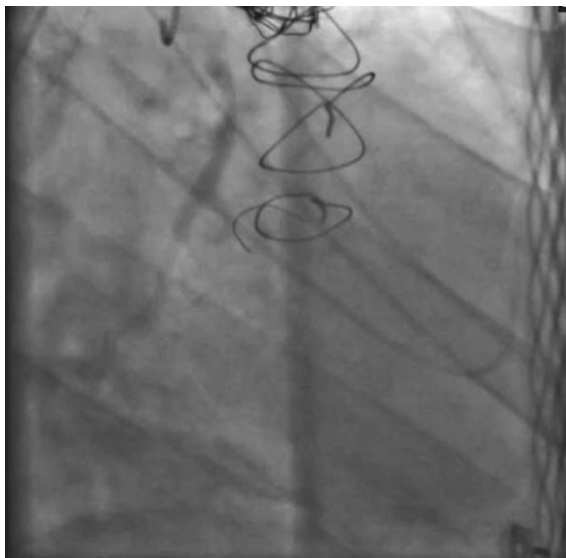
Current presentation	A 33 y/o woman presented with 5 months of progressive dyspnoea on exertion
23 years ago	Underwent Ross procedure at age 10 years for congenital bicuspid aortic stenosis. Found to have a single coronary ostium from left coronary cusp on aortic valve inspection
11 years ago	Transcatheter pulmonary valve replacement performed at age 22 years with a Melody prosthesis due to symptomatic pulmonary conduit stenosis, and stenting of coarctation of the aorta
Transthoracic echocardiogram	Revealed moderate pulmonary regurgitation and moderate pulmonary valve stenosis
Cardiopulmonary exercise test	Showed severely reduced peak oxygen consumption (14 mL/kg/min), ventricular bigeminy during exercise and recovery, and diffuse 1 mm flat ST depressions during exercise
Decision	Invasive angiography, valve-in-valve implantation

Coronary angiography	Revealed anomalous right coronary artery origin from the left ventricular outflow tract with atypical pulsatile antegrade filling during systole and no stenosis
Intervention	Transcatheter pulmonary valve-in-valve replacement with a 23 mm Sapien S3 prosthesis
6-month follow-up	Exertional dyspnoea markedly improved. Improved exercise performance on exercise stress test with no ventricular ectopy or ST segment changes
Decision	Conservative management of anomalous right coronary artery

## Case presentation

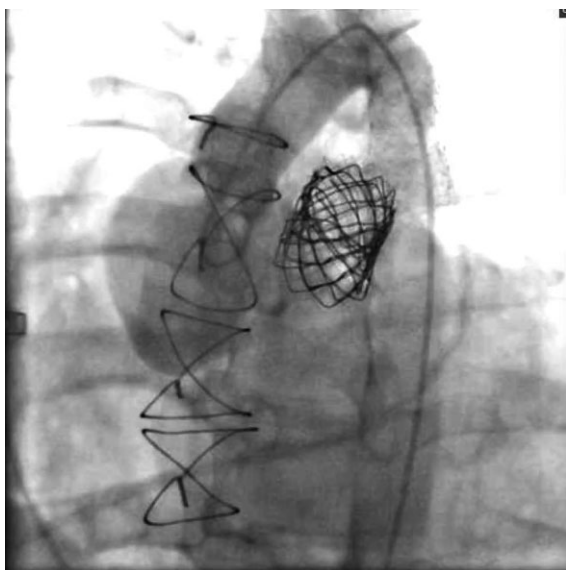
A 33-year-old woman with congenital heart disease and obesity presented with exertional dyspnoea for 5 months. She had a history of congenital aortic stenosis due to BAV and coarctation of the aorta. She underwent a Ross procedure at 10 years old and per the operative report, she was found to have a single coronary ostium from the left coronary cusp upon inspection of the aortic valve. She was diagnosed with common origin of the right and left coronary arteries, and a single coronary button was created from the left cusp and reimplanted following suturing of the pulmonary autograft in the aortic position. A 20 mm synthetic graft (Vascutek Ltd.) was placed in the pulmonic position. She eventually developed symptomatic stenosis of the synthetic graft and underwent uncomplicated transcatheter pulmonary valve replacement (TcPVR) with a Melody valve prosthesis with concomitant stenting of the aortic coarctation at 22 years old.

As part of her current evaluation, physical examination was notable for a palpable right ventricular lift, a grade III/VI mid-systolic crescendo murmur and a Grade II/IV short diastolic decrescendo murmur, both heard best at the left upper sternal border. The pulmonary examination was normal. Transthoracic echocardiography showed moderate stenosis and moderate regurgitation of the pulmonary prosthesis. The peak velocity across the pulmonary prosthesis was 3.3 m/s with peak instantaneous gradient of 44 mmHg and mean gradient of 25 mmHg. There was normal neo-aortic valve and biventricular systolic function, trace tricuspid regurgitation, and no evidence of re-coarctation of the aorta. Cardiopulmonary exercise test revealed severely reduced peak oxygen consumption of 14 mL/kg/min with a total exercise time of 5 min 40 s, ventricular

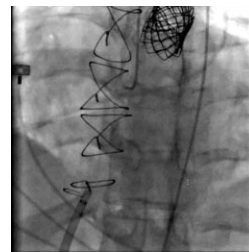


**Video 1** Anteroposterior cranial view of selective left coronary artery angiography showing no evidence of epicardial coronary artery disease as well as late retrograde filling of the right coronary artery via collateralization. There is antegrade washout of contrast from the right coronary artery during systole, suggestive of patency of the right coronary artery ostium.

bigeminy during exercise and recovery, and diffuse 1 mm flat ST depressions during exercise. These results were markedly worse compared with a test done 2 years prior, during which the patient was



**Video 2** Aortic root angiography in the left anterior oblique view with a pigtail catheter with transient prolapse into the left ventricular outflow tract at the time of injection, revealing the right coronary artery origin at the subvalvular level.



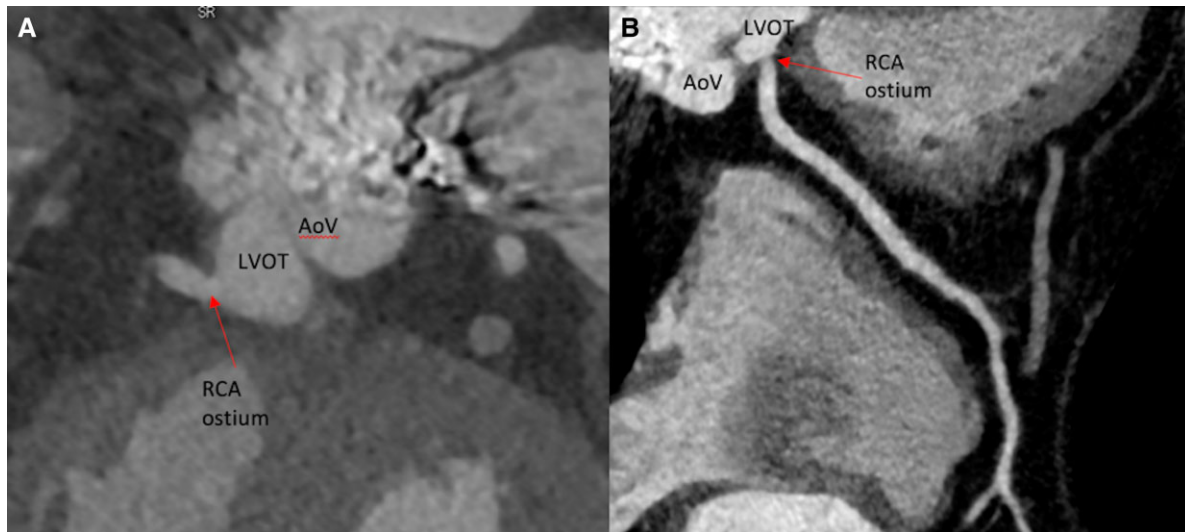
**Video 3** Selective right coronary artery angiography in the left anterior oblique view showing pulsatile flow filling the proximal segment of the vessel. During diastole, there is retrograde reflux of contrast into the left ventricular outflow tract, and during systole there is both antegrade flow down the coronary and ejection of the refluxed contrast in the left ventricular outflow tract through the aortic valve.

able to exercise up to 9 and 10 s with peak oxygen consumption of 20 mL/kg/min and only rare ventricular ectopy seen during recovery.

Given concern for symptomatic prosthetic valve disease, she was referred for valve-in-valve TcPVR with coronary angiography to evaluate for coronary ostial stenosis given the history of a prior Ross procedure. Laboratory tests were notable for elevated B-type natriuretic peptide at 214 pg/mL, undetectable serum troponin-I level, mild thrombocytopenia of 139 000/ $\mu$ L, normal leukocyte count, renal and hepatic function, and normal C-reactive protein of 0.7 mg/dL.

A cardiac catheterization was performed, demonstrating right ventricle (RV) systolic pressure of 76 mmHg with a peak-to-peak systolic gradient of 23 mmHg across the pulmonary valve, and angiography of the main pulmonary artery demonstrated severe pulmonary regurgitation. Aortic pressure was 98/55 mmHg. Selective angiography of the left coronary artery (LCA) demonstrated a large left anterior descending artery (LAD) that wrapped around the left ventricular apex, and no epicardial LCA disease. However, retrograde filling of a medium-sized dominant right coronary artery (RCA) via collaterals from the LAD was noted, with systolic washout of contrast from the RCA ([Video 1](#)). Aortic root angiography showed no evidence of an RCA ostium, but the pigtail catheter momentarily prolapsed into the LVOT during injection. This revealed an RCA ostium originating from the high LVOT, immediately below the aortic valve ([Video 2](#)). Selective RCA angiography was then performed using a Judkins Right 4.0 catheter prolapsed across the aortic valve, and showed an angiographically patent RCA ostium with pulsatile antegrade flow augmented during systole, with washout and reflux of contrast into the LVOT during diastole ([Video 3](#), [Supplementary material online, Video S1](#)). The aortic valve was clearly seen to be above the level of the RCA ostium (see [Supplementary material online, Video S1](#)).

Given the absence of angiographic stenosis, we concluded that the collateralization of the RCA occurred because of ischaemia in the RCA territory resulting from inadequate coronary perfusion pressure due to the subvalvular coronary origin and the consequent systolic dominant RCA flow. We successfully performed valve-in-valve



**Figure 1** Coronary computed tomography angiography showing the ostium of the right coronary artery originating in the left ventricular outflow tract below the level of the aortic valve. This is seen in the coronal view (A) and curved multiplanar reconstruction of the right coronary artery (B).

TcPVR with a 23 mm Sapien S3 prosthesis, with the improvement of transvalvular gradient to 8 mmHg and resolution of pulmonary regurgitation. A coronary computed tomography angiogram (CCTA) was obtained, which re-demonstrated the subvalvular RCA takeoff (Figures 1 and 2). Transthoracic echocardiography done the day after valve replacement showed complete resolution of pulmonary regurgitation and improvement in pulmonary valve haemodynamics when compared with before the valve-in-valve TcPVR. The peak velocity was 2.8 m/s with peak instantaneous gradient of 32 mmHg and a mean gradient of 17 mmHg. Trace tricuspid regurgitation was seen. Over the next 6 months, the patient reported significant improvement of her exertional dyspnoea with improved exercise performance and absence of angina, ventricular ectopy, and wall motion abnormalities on repeat stress echocardiography. Given these results, along with consideration of the risk of redo sternotomy for coronary bypass grafting or RCA reimplantation, conservative management including medical therapy with aspirin and labetalol as well as targeted lifestyle counselling directed towards weight reduction was pursued, after a discussion with the patient.

## Discussion

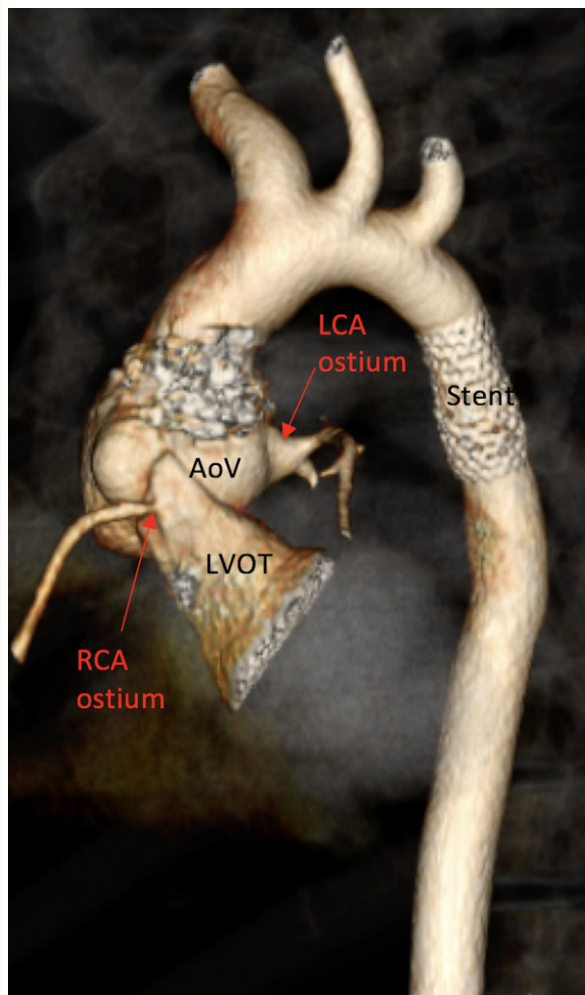
Our case provides insights into the key pathophysiologic concepts of this coronary anomaly to a degree not described in the literature to date. The antegrade RCA angiograms demonstrate systolic dominant coronary flow, rather than conventional diastolic dominant coronary flow. This occurs because the RCA ostium is now anatomically contiguous with the LV. Coronary perfusion pressure in this anomaly is hence governed by the difference between systolic pressure in the LVOT and systolic pressure in the ventricular cavity—a setup for myocardial ischaemia, particularly in the LV where there is minimal pressure gradient between the LVOT and the LV cavity. This

pathophysiology can also impact the RV and lead to ischaemia, particularly in cases of RV systolic hypertension due to pulmonary vascular disease or RV outflow obstruction. Our patient was relatively well compensated before developing severe pulmonary valve disease, likely because of collateralization by the LAD and the fact that the majority of the inferior LV myocardium was supplied by the large wrap-around LAD rather than the anomalous RCA. The TcPVR reduced RV systolic pressure and improved coronary perfusion pressure to her RV, which also may have contributed to improved exercise capacity and resolution of previously seen ventricular ectopy.

Diagnosis of this anomaly can be challenging, since the absence of a coronary ostium on invasive angiography combined with the presence of retrograde filling via collateralization from the contralateral coronary can lead to the erroneous diagnosis of a chronic total coronary occlusion.<sup>2</sup> In such a situation, identification of systolic wash-out of contrast during retrograde injection of the anomalous coronary as well as left ventricular (LV) or LVOT angiography can lead to the correct diagnosis, which may be needed rapidly in the case of an acute presentation. Careful evaluation of the coronary ostia on CCTA can also lead to the diagnosis in less acute cases.<sup>2</sup>

While this is the first case, to our knowledge, of a subvalvular coronary artery being reported after a Ross procedure, our report carries wide-ranging implications from a surgical standpoint given the association with BAV and subaortic membrane that may necessitate surgical intervention.<sup>1-3</sup> Antegrade cardioplegia will not perfuse the LV myocardium supplied by the subvalvular coronary, and without a retrograde approach, haemodynamic collapse and fatal LV failure may result when coming off pump, particularly in young patients who may lack sufficient collateralization. Delineation of coronary anatomy invasively or non-invasively before aortic valve replacement can hence be vital for surgical planning, and should be considered in patients with BAV to avoid missing this rare entity. In addition, careful





**Figure 2** Three-dimensional volume rendered coronary computed tomography angiography, sagittal projection, showing the ostium of the right coronary artery originating in the left ventricular outflow tract below the level of the aortic valve. The left coronary ostium is seen originating above the aortic valve. Also noted is the previously placed stent in the descending aorta at the site of prior coarctation.


intraoperative inspection of the origins and courses of the individual coronary arteries should be done to evaluate for this diagnosis, should a single supra-avalvular coronary ostium be seen upon inspection of the aortic sinuses.

## Conclusions

We report a rare anomaly of a coronary artery originating from the LVOT that was diagnosed angiographically in a patient following a

Ross procedure. Our case adds to the understanding of the pathophysiology of this rare condition, and a multimodality approach is needed for this challenging diagnosis. We underscore the need to consider this diagnosis in symptomatic patients with an absent supra-avalvular coronary ostium on aortic root angiography as well as in young patients with BAV undergoing cardiac surgery, as this carries important implications for management strategies for this population.

## Lead author biography



Dr Prashanth Venkatesh is a second-year fellow physician in adult congenital heart disease at the Ahmanson/UCLA Adult Congenital Heart Disease Center at the David Geffen School of Medicine at the University of California, Los Angeles, USA. He has a keen interest in cardiac imaging of patients with complex congenital heart disease and the care of pregnant patients with congenital heart disease.

## Supplementary material

Supplementary material is available at *European Heart Journal – Case Reports* online.

**Slide sets:** A fully edited slide set detailing these cases and suitable for local presentation is available online as Supplementary data.

**Consent:** The authors confirm that written consent for submission and publication of this case report including images and associated text has been obtained from the patient in line with COPE guidelines.

**Conflict of interest:** None declared.

**Funding:** None declared.

## References

1. Culbertson C, De Campli W, Williams R, Helton G, Young N, Hardy C. Congenital valvar aortic stenosis and abnormal origin of the right coronary artery: rare combination with important clinical implications. *Pediatr Cardiol* 1995;**16**:73–75.
2. Kang N, Tan SY, Ding ZP, Chua YL. Abnormal origin of right coronary artery from left ventricle with bicuspid aortic stenosis. *Ann Thorac Surg* 2013;**96**:e43–e45.
3. Pirelli L, Yu PJ, Srichai MB, Khvilivitzky K, Angelini P, Grau JB. Ectopic origin of left coronary ostium from left ventricle, with occlusive membrane: a previously unreported anomaly, with an embryologic interpretation. *Tex Heart Inst J* 2008;**35**:162–165.
4. Khan A, Audlin J, Miro S, Chaudhuri D, Dunton R. Anomalous origin of the left main coronary artery arising from the left ventricular outflow tract with a retro-aortic collateral vessel. *J Card Surg* 2017;**32**:483–484.
5. Land RN, Hamilton AY, Fuchs PC. Sudden death in a young athlete due to an anomalous commissural origin of the left coronary artery, and focal intimal proliferation of aortic valve leaflet at the adjacent commissure. *Arch Pathol Lab Med* 1994;**118**:931–933.