


CASE REPORT

Open Access



C3 glomerulopathy in cystic fibrosis: a case report

Domenico Santoro^{1*} , Rossella Siligato¹, Carmela Vadalà¹, Mariacristina Lucanto², Simona Cristadoro², Giovanni Conti³, Michele Buemi¹, Stefano Costa², Ettore Sabadini⁴ and Giuseppe Magazzù²

Abstract

Background: C3 glomerulonephritis is a rare glomerulopathy characterized at renal biopsy by C3 deposition, alone or with scanty immunoglobulins, as well as by an electron-dense material in mesangium, subendothelial and subepithelial space. An abnormal systemic activation of the alternative pathway of the complement cascade is responsible for the development of the disease if triggered by several possible environmental conditions. We report the first case in literature of a patient affected by cystic fibrosis and C3GN.

Case presentation: Our case involves a young woman with cystic fibrosis, who had persistent microscopic hematuria, proteinuria and hypocomplementemia C3 for over three months. Renal biopsy confirmed the diagnosis of C3 glomerulopathy. Complement system dysregulation was tested and resulted in a strong terminal pathway activation proved by high levels of sC5b-9 complex, amounting to 1588 ng/ml (normal value < 400 ng/ml). Next generation sequencing (NGS) showed polymorphism in *CFH* (p.V62I in SCR1) and *THBD* (p.A473V), already known as pathogenic for C3GN, as well as a mutation in *C3* (p.R102G) associated only with age-related macular degeneration (AMD) so far. Treatment was based on ACE inhibitors and kidney function is currently stable (GFR 50 ml/min, serum creatinine 1.7).

Conclusions: The co-existence of C3 glomerulopathy in a patient with CF, which is characterized by chronic infection/inflammation, makes this case an interesting model of chronic altered systemic activation of the alternative pathway of the complement cascade.

Keywords: C3 glomerulopathy, Renal biopsy, Cystic fibrosis, Inflammation

Background

C3 glomerulonephritis (C3GN) has been recently included with Dense Deposit Disease (DDD) in the new entity of C3 glomerulopathy. This has been codified to highlight the difference between clearly recognizable secondary forms of membranoproliferative glomerulonephritis (MPGN) and those idiopathic cases lacking the classical staining for immunoglobulin at immunofluorescence (IF). The latter forms show, instead, an almost exclusive C3 staining- in some cases also C5b-9- without other complement factors belonging to either classical or lectin pathway, and they are associated to hypocomplementemia. At present time C3 glomerulopathy can be considered as a multifactorial disease, resulting from an altered control of the alternative pathway, triggered by

outer conditions, such as infections that stimulate the already abnormal activation of complement [1].

C3 glomerulonephritis represents a very rare disorder with an incidence of 2–3 cases per million inhabitants per year. It affects equally both male and female population and the mean age of onset is 21 years old. Its onset is typically characterized by nephritic symptoms but it can also be associated with higher levels of proteinuria, even in nephrotic range. The natural course of this disease implies a 25% risk of ESRD progression in the following 10 years. Recurrence of C3GN after kidney transplant is observed in 60% of patients, usually in a mean range of 12–8 months after receiving the allograft [2].

Cystic fibrosis (CF) is the most common autosomal recessive disease affecting the Caucasian population, with a birth incidence ranging between 1:2500 and 1:4500 [3]. It is caused by mutations in *CFTR* (*cystic fibrosis transmembrane regulator*) gene which is localized on chromosome 7

* Correspondence: dsantoro@unime.it

¹Department of Clinical and Experimental Medicine, University of Messina, Via Faranda, 2-98123 Messina, Italy

Full list of author information is available at the end of the article



(<https://ghr.nlm.nih.gov/condition/cystic-fibrosis#statistics>). Renal disease is reported as a relatively rare complication in adult patients with CF [4]. This is the first occurrence of C3 glomerulopathy in a patient with CF.

Case presentation

Our case involved a 32 year-old woman affected by CF diagnosed at 6 months old, with renal diseases and hypertension in her family medical history. She also suffered from reactive arthritis since 19 years old in steroid and hydroxychloroquine therapy and had been diagnosed with CF-related diabetes at the age of 21.

After a fever episode (treated with ciprofloxacin) in October 2015 the patient's laboratory tests showed Haemoglobin 8.2 mg/dl, serum creatinine 2 mg/dl, creatinine clearance 62 ml/min, hypocomplementemia C3. Her urinalysis pointed out hematuria (10–20 RBC/field of view) with 60% of dysmorphic erythrocytes, without proteinuria. The first clinical suspicion was a post-infectious glomerulonephritis. After that, a close follow up was conducted until December 2015. The persistent laboratory results over 8 weeks required kidney biopsy to be performed to exclude other causes of nephritic syndrome.

Light microscopy pointed out 5 sclerotic glomeruli out of 23. Main pattern was diffuse endocapillary proliferation, segmental in only a few glomeruli, with neutrophil (and less frequently lympho-monocyte) infiltration. Mesangium was characterized by deposits as well as hypercellularity and increased mesangial matrix. Interstitium showed mild edema and inflammatory cells, as well as between Tubular Basement Membrane and the above cells. A few arteries presented a fibrous intimal thickening. Arteriolar hyalinosis manifested too (Fig. 1a and b).

Immunofluorescence assay proved strong C3 staining (3+) in granular deposits in mesangium and glomerular basement membrane (GBM). Staining was less evident in tubuli (2+). IgA staining was focal in mesangium and in only a few arteriolar walls (2+). The presence of IgG only into tubular cells was explained as the result of re-absorption (Fig. 2).

The deposits were well characterized by electron microscopy. They were localized to a greater extent in mesangium, but the assay demonstrated their presence also in subendothelial and subepithelial spaces. Their confluent electrondense appearance, instead of the intensely osmiophilic ribbon-shaped deposits pathognomonic for DDD, allowed to conclude for a C3 glomerulonephritis (Fig. 3a and b).

Complement system dysregulation was tested and resulted in a strong terminal pathway activation proved by high levels of sC5b-9 complex, amounting to 1588 ng/ml (normal value < 400 ng/ml).

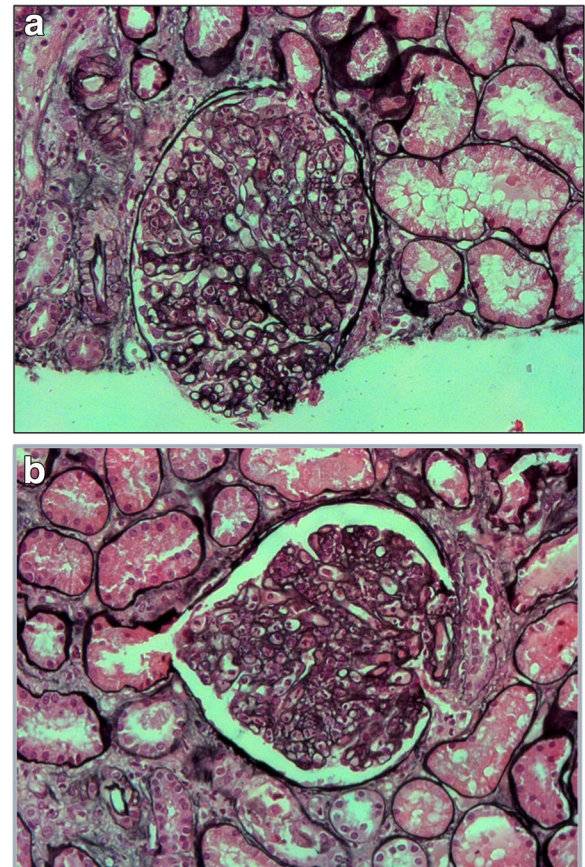


Fig. 1 a and b. Light microscopy (Silver staining 40x): Endocapillary proliferation with neutrophil (and less frequently lympho-monocyte) infiltration

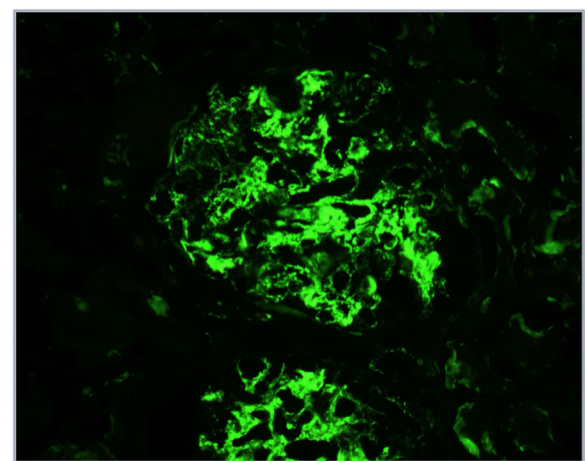


Fig. 2 Immunofluorescence for C3: strong staining (3+) in granular deposits in mesangium and glomerular basement membrane (GBM). staining was less evident in tubuli (2+)

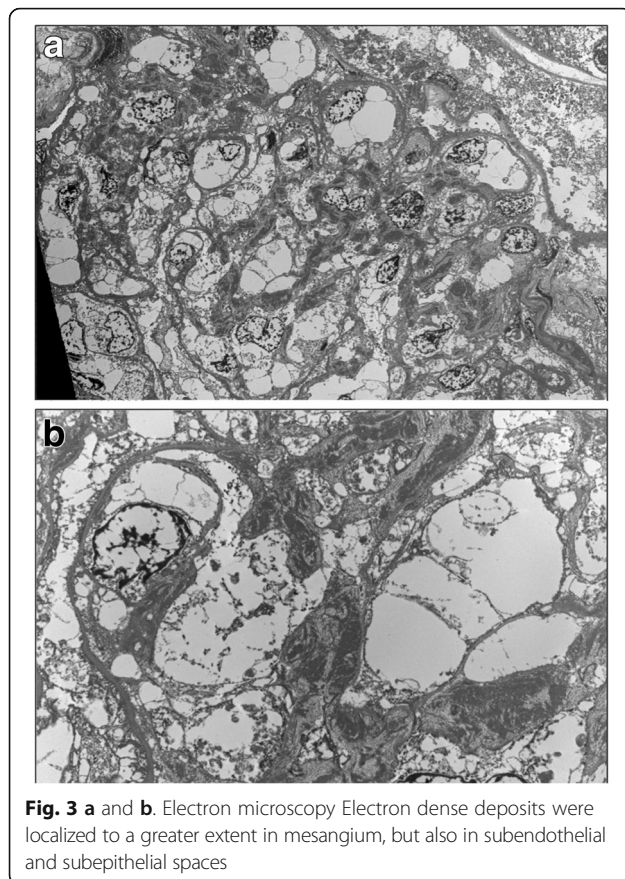


Fig. 3 a and b. Electron microscopy Electron dense deposits were localized to a greater extent in mesangium, but also in subendothelial and subepithelial spaces

Both genetics and C3NeF were investigated to determine the etiology of this altered control of alternative pathway. Next generation sequencing (NGS) showed polymorphism in *CFH* (p.V62I in SCR1) and *THBD* (p.A473V) already known as pathogenic for C3GN, as well as a mutation in *C3* (p.R102G) associated only with age-related macular degeneration (AMD) so far.⁴

Our patient is now treated with Angiotensin-converting-enzyme inhibitors (ACEI) added to her current Cystic Fibrosis and Reactive Arthritis therapies to preserve her kidney function.

After two years of disease her renal function is stable with serum creatinine 1.7 mg/dl, creatinine clearance 50 ml/min, 24 h proteinuria 270 mg, hypocomplementemia for C3 (14 mg/dl) and haemoglobin 9.4 mg/dl.

Discussion

The patient is affected by two rare diseases, Cystic Fibrosis and C3 glomerulonephritis, whose association is not known in literature because of their different gene mutations and the lacking of a common pathogenesis.

First thing first we have to consider that the improved therapy of CF made possible a prolongation of life expectancy - from 20 years in 1960 beyond 40 years for patients born in 2000 [5] - that exposes the patients to the

risk of developing age-related kidney disease. Moreover, this goal has been reached also with the prevention and treatment of infections with antibiotics, whose renal toxicity has to be carefully considered, given that it is cumulative especially in children and may cause chronic interstitial lesions in kidneys.

Secondly, we have to consider possible CF indirect kidney complications which are more evident with the longer estimated life of the patients. The progressive pancreatic failure and the development of diabetes may cause diabetic nephropathy. Equally, also chronic infections, which patients are more vulnerable to, may be responsible of AA amyloidosis that usually involves kidney with proteinuria, nephrotic syndrome and progressive renal insufficiency leading to ESRD.

In this case, besides the genetic predisposition to dysregulation of alternative complement pathway expressed by patient's *CFH*, *THBD* and *C3* polymorphism, one hypothesis regarding pathophysiology could be related to chronic infections due to CF. Indeed it may act as a trigger for the onset of C3 glomerulopathy stimulating a continuous activation of complement cascade, but we do not exclude other possible causes.

Complement dysregulation is the known cause of C3 glomerulopathy and can be congenital or acquired. Genetic mutations involve mainly fluid phase regulator factors of the alternative pathway such as *CFH* in its short consensus repeats (SCR) 1, 2, 6, 10 and 20. However, also *CFI* and *MCP* mutations were found [6, 7]. In particular, Martínez-Barricarte and coll [8] and Gale and coll [9] studied familiar forms of C3GN and found an association with a *CFHR3-1* hybrid protein, [10] an internal duplication of *CFHR1* [11] and another duplication interesting *CFHR5*, all genes codifying for proteins that share a high degree of homology with *CFH* [12]. All these mutations cause a loss of function that implies an abnormal activation of the alternative pathway.

An acquired mechanism of dysregulation involves C3 Nephritic Factor (C3NeF), an autoantibody that binds a neoepitope on the C3 convertase of the alternative pathway, stabilizing it against *CFH*-mediated decay and prolonging its C3 cleaving action. A second kind of C3NeF stabilizes the C3 convertase of the classical pathway, incrementing C3 and C5 activation but is properdin-dependent. C3NeF can be found in up to 50% of patients with C3 glomerulopathy, with lower titer in C3GN compared to DDD patients.

Also factor H autoantibodies (FHAA) binding SCR 3 and altering FH interaction with C3b have been identified, although they are rare in C3GN and their effective pathogenic role has to be investigated yet [6].

In our patient we found two polymorphisms already known as pathogenic for C3GN in *CFH* (p.V62I in SCR1) and *THBD* (p.A473V) genes, as well as a polymorphism

so far associated to age-related macular degeneration (AMD) in C3 (p.R102G) [13]. These alterations may express a certain degree of predisposition to the dysregulation of alternative complement pathway.

Our patient is now treated with ACEI since no other therapies have been demonstrated to be effective in the treatment of this disorder. ACEI and Angiotensin II receptor blocker (ARB) are given to most of the patients because of their antiproteinuric and antihypertensive effect, thus playing a nephroprotective role in both nephritic and nephrotic presentation. This strategy has been borrowed in other glomerulonephritis and it is not specific for this disease. Our patient is in lung transplant waiting list at the moment.

Several other approaches are currently used for C3 glomerulopathy lacking a gold standard treatment. Long term steroid therapy alone or in combined approach with mycophenolate efficacy is yet to be proven because the only study which demonstrated beneficial effects on kidney function regarded MPGN cases before of their distinction in immunocomplex mediated and C3 glomerulopathy [14, 15].

Plasma therapy, in its variants of plasma exchange (PE) and plasma infusion (PI), has been adopted in selected cases of DDD with mutated *CFH*, but in only a few reports demonstrated its effectiveness [16].

Evidence of C3NeF and occasionally of FHAA addressed attention to immunosuppressor targeted therapies such as rituximab and eculizumab, respectively humanized anti-CD20 and anti-C5 monoclonal antibodies. Eculizumab in particular has been designed first to treat paroxysmal nocturnal hemoglobinuria (PNH) and atypical hemolytic uremic syndrome (aHUS). Because of the common genetic background to aHUS and C3 glomerulopathy, this drug is now an off-label treatment administered to few patients and with variable effectiveness. Inactivation of C5 eculizumab mediated in a *CFH* deficient mouse model proved that the C3GN phenotype can develop with regular C3 deposition and endothelial alterations as well as proteinuria, but with less glomerular inflammation [17]. In our case, the hypothesis of a therapy with eculizumab was initially considered. Indeed, data seem to prove that the best degree of efficacy can be reached treating with eculizumab those patients who have high levels of sC5b-9 complex that lead to cell apoptosis. For the moment this drug has been used in anecdotal cases and in a single non-randomized trial for the treatment of C3 glomerulopathies [18]. However, in this study patients were selected on the basis of a high risk of progression, defined by a proteinuria of more than 1 g / day or acute renal failure [18]. In our case, stable renal function and low degree of proteinuria, as well as the increased risk of infections, to which the inhibition of the complement system would

inevitably expose, did not represent indications to eculizumab therapy.

Finally, it is worth considering the relationship between kidney function and lung transplant. This is an advanced stage therapy for CF and requires a careful monitoring of renal function for an appropriate management of both pre- and post-operative periods, because of the surgery impact as well as the subsequent huge use of antibiotics and immunosuppressor drugs, with high risk of nephrotoxicity. An analysis led by Lefaucheur and coll. Registered a faster reduction of glomerular filtration rate (GFR) in 32.5% of transplanted lung patients and a strong association with the risk of developing ESRD [19].

Conclusions

We reported for the first time the occurrence of C3 glomerulopathy in CF. We speculate that CF may act as a trigger for continuous activation of complement system due to a predisposing condition of alternative pathway dysregulation.

Abbreviations

ACEI: Angiotensin-converting-enzyme inhibitors; aHUS: atypical hemolytic uremic syndrome; AMD: Age-related macular degeneration; ARB: Angiotensin II receptor blocker; C3GN: C3 glomerulonephritis; C3NeF: C3 Nephritic factor; CF: Cystic fibrosis; *CFTR*: Cystic fibrosis transmembrane regulator; DDD: Dense Deposit Disease; ESRD: End stage renal disease; FHAA: Factor H autoantibodies; GFR: Glomerular filtration rate; MPGN: Membranoproliferative glomerulonephritis; PE: Plasma exchange; PI: Plasma infusion; PNH: Paroxysmal nocturnal hemoglobinuria; SCR: Short consensus repeats

Acknowledgements

Our sincere appreciation to Prof. Arthur Cohen for his critical contribution to this report and for providing the electron microscopy images.

Funding

No funds to declare.

Availability of data and materials

Data, material and images of this case report are available from the corresponding author on reasonable request.

Authors' contributions

DS, ML, SC, SC, GC analyzed and interpreted the patient data regarding renal disease and transplant. DS performed the histologic examination of the kidney and was a major contributor in writing the manuscript. DS, RS, CV, MB, GM participated during elaboration of the manuscript; ES gave important contribution regarding the therapeutical strategies. All authors read and approved the final manuscript.

Ethics approval and consent to participate

Not applicable.

Consent for publication

The patient signed her informed consent for publication.

Competing interests

Prof. Domenico Santoro is an Associate Editor of BMC Nephrology. Other authors declare that they have no competing interests.

Publisher's Note

Springer Nature remains neutral with regard to jurisdictional claims in published maps and institutional affiliations.

Author details

¹Department of Clinical and Experimental Medicine, University of Messina, Via Faranda, 2-98123 Messina, Italy. ²Unit of Pediatric Gastroenterology and Cystic Fibrosis, University of Messina, Messina, Italy. ³Unit of Pediatric Nephrology and Rheumatology, University of Messina, Messina, Italy. ⁴Unit of Nephrology, Hospital Riuniti, Bergamo, Italy.

Received: 13 March 2017 Accepted: 20 March 2018

Published online: 28 March 2018

References

- Pickering MC, D'Agati VD, Nester CM, Smith RJ, Haas M, Appel GB, et al. C3 glomerulopathy: consensus report. *Kidney Int.* 2013;84:1079–89.
- Xiao X, Pickering MC, Smith RJH. C3 Glomerulopathy: the genetic and clinical findings in dense deposit disease and C3 glomerulonephritis. *Semin Thromb Hemost.* 2014;40(04):465–71.
- Yahiaoui Y, Jablonski M, Hubert D, Mosnier-Pudar H, Noël LH, et al. Renal involvement in cystic fibrosis: diseases Spectrum and clinical relevance. *Clin J Am Soc Nephrol.* 2009;4(5):921–8.
- Iatropoulos P, Noris M, Mele C, Piras R, Valoti E, Bresin E, Curreri M, Mondo E, Zito A, Gamba S, Bettoni S, Murer L, Fremeaux-Bacchi V, Vivarelli M, Emma F, Daina E, Remuzzi G. Complement gene variants determine the risk of immunoglobulin-associated MPGN and C3 glomerulopathy and predict long-term renal outcome. *Mol Immunol.* 2016;71:131–42.
- MacKenzie T, Gifford AH, Sabadosa KA, Quinton HB, Knapp EA, Goss CH, Marshall BC. Longevity of patients with cystic fibrosis in 2000 to 2010 and beyond: survival analysis of the Cystic Fibrosis Foundation patient registry. *Ann Intern Med.* 2014;161(4):233–41. <https://doi.org/10.7326/M13-0636>.
- Servais A, Noel LH, Roumenina LT, Le Quintrec M, Ngo S, Dragon-Durey MA, Macher MA, Zuber J, Karras A, Provot F, Moulin B, Grunfeld JP, Niaudet P, Lesavre P, Fremeaux-Bacchi V. Acquired and genetic complement abnormalities play a critical role in dense deposit disease and other C3 glomerulopathies. *Kidney Int.* 2012;82:454–64.
- Sethi S, Fervenza FC, Zhang Y, et al. C3 glomerulonephritis: clinicopathologic findings, complement abnormalities, glomerular proteomic profile, treatment and follow-up. *Kidney Int.* 2012;82:465–73.
- Martinez-Barricarte R, Heurich M, Valdes-Canedo F, et al. Human C3 mutation reveals a mechanism of dense deposit disease pathogenesis and provides insights into complement activation and regulation. *J Clin Invest.* 2010;120:3702–12.
- Gale DP, de Jorge EG, Cook HT, et al. Identification of a mutation in complement factor H-related protein 5 in patients of Cypriot origin with glomerulonephritis. *Lancet.* 2010;376:794–801.
- Malik TH, Lavin PJ, Goicoechea de Jorge E, et al. A hybrid CFHR3-1 gene causes familial C3 glomerulopathy. *J Am Soc Nephrol.* 2012;23:1155–60.
- Tortajada A, Yébenes H, Abarrategui-Garrido C, et al. C3 glomerulopathy-associated CFHR1 mutation alters FHR oligomerization and complement regulation. *J Clin Invest.* 2013;123(6):2434–46.
- Medjeral-Thomas N, Malik TH, Patel MP, et al. A novel CFHR5 fusion protein causes C3 glomerulopathy in a family without Cypriot ancestry. *Kidney Int.* 2014;85(4):933–7.
- Tarshish P, Bernstein J, Tobin JN, Edelmann CM Jr. Treatment of mesangiocapillary glomerulonephritis with alternate day prednisone—a report of the international study of kidney disease in children. *Pediatr Nephrol.* 1992;6:123–30.
- Appel GB, Cook HT, Hageman G, Jennette JC, Kashgarian M, Kirschfink M, Lambris JD, Lanning L, Lutz HU, Meri S, Rose NR, Salant DJ, Sethi S, Smith RJ, Smoyer W, Tully HF, Tully SP, Walker P, Welsh M, Wurznner R, Zipfel PF. Membranoproliferative glomerulonephritis type II (dense deposit disease): an update. *J Am Soc Nephrol.* 2005;16:1392–403.
- Krmar RT, Holtbäck U, Linné T, Berg UB, Celsi G, Söderberg MP, Wernerson A, Szakos A, Larsson S, Skattum L, Bárányi P. Acute renal failure in dense deposit disease: complete recovery after combination therapy with immunosuppressant and plasma exchange. *Clin Nephrol.* 2011;75(Suppl 1):4–10.
- Roussel-Rouviere C, Cailliez M, Garaix F, Bruno D, Laurent D, Tsimaratos M. Rituximab fails where eculizumab restores renal function in C3NeF-related DDD. *Pediatr Nephrol.* 2014;29:1107–11.
- Pickering MC, Warren J, Rose KL, Carlucci F, Wang Y, Walport MJ, Cook HT, Botto M. Prevention of C5 activation ameliorates spontaneous and experimental glomerulonephritis in factor H deficient mice. *Proc Natl Acad Sci U S A.* 2006;103:9649–54.
- Bomback AS, Smith RJ, Barile GR, Zhang Y, Heher EC, Herlitz L, Stokes MB, Markowitz GS, D'Agati VD, Canetta PA, Radhakrishnan J, Appel GB. Eculizumab for dense deposit disease and C3 glomerulonephritis. *Clin J Am Soc Nephrol.* 2012;7:748–56.
- Lefaucheur C, Nochy D, Amrein C, Chevalier P, Guillemain R, Cherif M, Jacquot C, Glotz D, Hill GS. Renal histopathological lesions after lung transplantation in patients with cystic fibrosis. *Am J Transplant.* 2008;8:1901–10.

Submit your next manuscript to BioMed Central and we will help you at every step:

- We accept pre-submission inquiries
- Our selector tool helps you to find the most relevant journal
- We provide round the clock customer support
- Convenient online submission
- Thorough peer review
- Inclusion in PubMed and all major indexing services
- Maximum visibility for your research

Submit your manuscript at
www.biomedcentral.com/submit

