

## Birdshot Retinochoroidopathy

Albert T. Vitale, MD

Department of Ophthalmology and Visual Sciences, John A. Moran Eye Center, Salt Lake City, UT, USA

### Abstract

Birdshot retinochoroidopathy (BSRC) is an uncommon, but well-characterized chronic, bilateral posterior uveitis, which is uniquely associated with the human leukocyte antigen-A29 phenotype. The disease presents predominantly in middle-aged Caucasian females who complain of blurred vision, floaters, photopsias, paracentral scotomas and nyctalopia. While autoimmune mechanisms are thought to play an important role in the pathogenesis of BSRC, its etiology remains unknown. Important questions remain in our understanding of BSRC with respect to its pathogenesis, epidemiology, optimal treatment, and prognosis, including the determinants of remission and relapse, as well as the best strategy for monitoring disease activity, progression and response to therapy with electroretinographic and psychophysical testing, established and emerging imaging modalities, and peripheral cytokines profiles.

**Keywords:** Immunomodulatory Therapy; Monitoring; Multi-modal Imaging; Pathogenesis

*J Ophthalmic Vis Res* 2014; 9 (3): 350-361.

### PATHOGENESIS

Birdshot retinochoroidopathy (BSRC) is unique in having the strongest association between a human leukocyte antigen (HLA) and human disease reported to date, with up to 96% of patients being HLA-A29 positive suggesting the central importance of this molecule for disease susceptibility.<sup>[1]</sup> However, the inciting antigen is unknown and the exact role of HLA-A29 in the pathogenesis of the disease is not well-understood. It has been suggested that an autoinflammatory response results from presumed molecular mimicry initiated either by prior microbial infection or other damaging factors and that HLA-A29 cross-reactive proliferative responses directed against retinal antigens could lead to loss of immunological tolerance and autoimmunity in BSRC.<sup>[2]</sup>

An infectious etiology has been proposed in the pathogenesis of BSRC, either by initiating an immune response directly to the microbe itself or through molecular mimicry in a genetically predisposed individual, facilitating the presentation of autoantigen to T-cells by the HLA-A29 molecule. While antibodies

to *Borrelia burgdorferi* were found in 4 of 11 HLA-A29 positive patients with BSRC in one study, there is no conclusive evidence for a direct role for Lyme disease pathogenesis of this disease.<sup>[3]</sup>

The spontaneous development of a retinopathy resembling BSRC in HLA-A29 transgenic mice after 6 months of age suggests that the molecule itself plays a role in disease pathogenesis. In this model, the level of cell surface expression of HLA-A29, as well as the presence or absence of human beta 2-microglobulin, did not influence the frequency of retinopathy, suggesting that HLA-A29 itself does not mediate risk by presenting antigen to the immune system. As BSRC is a disease of older individuals in humans, it is of interest that younger transgenic mice did not develop disease, raising important questions as to role of aging in the pathogenesis of inflammation in this disease

*In vitro* immune responsiveness to retinal soluble antigen (S-Ag) and to interphotoreceptor retinoid binding protein (IRBP), while not specific to BSRC, have been demonstrated in a high percentage of patients.<sup>[4,5]</sup> In addition, the histopathologic findings of one eye

### Correspondence to:

Albert T. Vitale, MD. Department of Ophthalmology and Visual Sciences, John A. Moran Eye Center, 65 N. Mario Capecchi Drive, Salt Lake City, UT 84132, USA. E-mail: albert.vitale@hsc.utah.edu

Received: 17-11-2013

Accepted: 25-12-2013

### Access this article online

Quick Response Code:



Website:

[www.jovr.org](http://www.jovr.org)

DOI:

10.4103/2008-322X.143376

from a BSRC patient with immune responsiveness to retinal S-Ag were similar to those found in monkeys with S-Ag induced uveitis,<sup>[6]</sup> while those from another HLA-A-29 patient were strikingly similar to those found in HLA-A29 transgenic mice.<sup>[7]</sup>

Birdshot retinochoroidopathy is a disease involving both the retina and choroid. While it may be difficult to determine, which level is affected primarily on clinical exam, histopathologic, electroretinographic, and imaging studies of patients with BSRC suggest that the inner retina and choroid may be affected differentially and in the earlier stages of the disease. The role of S-Ag and IRBP in disease pathogenesis must be reconciled with their location in the outer retina, suggesting that they may not be the primary inciting antigens; rather, the immune response to these antigens may be an epiphenomenon in which these proteins are released by inflammation or infection later in the disease and become autoantigens, which propagate the autoimmune response.

The presence of HLA-A29 does not fully explain the full expression of disease, experimentally or in clinical experience. Not all transgenic mice develop the disease, and in humans, the disease remains rare despite the fact that 7% of the Caucasian population are HLA-A29 positive. While disease susceptibility appears linked to the HLA-A29 molecule, irrespective of subtype, other genetic or acquired factors not linked to the major histocompatibility complex are also likely to be involved in disease development given the low prevalence of BSRC in the HLA-A29 positive population.

Recently, specific allelic combinations of the killer cell immunoglobulin-like receptor (KIR) gene, which encode for inhibitory and activating receptors expressed on human natural killer (NK) cells and some T-cells, including CD8+ T lymphocytes, which are important in both innate and adaptive immunity, have been shown to confer significant risk for the development disease in HLA-A29 positive patients with BSRC while other compound genotypes were relatively protective.<sup>[8]</sup> These genes may contribute to the pathogenesis of BSRC by activating NK cells and T-cell subsets against intraocular self-antigens.

The preponderance of experimental and clinical evidence supports the notion of BSRC as a T-cell-mediated autoimmune disease associated with HLA-A29. Cyclosporine A, a specific inhibitor of CD4+ T-cell function, has been shown to be effective both the inhibition of S-Ag induced experimental autoimmune uveitis<sup>[6]</sup> and in the treatment of BSRC patients.<sup>[9]</sup> Most recently, T helper 17 (Th17) cells, a subset of CD4+ lymphocytes which secrete mainly interleukin-17 (IL-17), have been implicated in the pathogenesis of BSRC. A recent study employing a multiplex immunoassay for the detection of 23 immune mediators in paired aqueous humor (AqH) and serum samples of 16 patients with BSRC and 11 age related cataract controls, showed that

the levels of IL-17, IL-2, IL-1 $\beta$ , IL-6 and tumor necrosis factor- $\alpha$  (TNF- $\alpha$ ) were elevated in the intraocular fluid but not in the serum, with significant positive correlation between IL-17 and both IL-2 and IL-23 and between IL-2 and IL-23.<sup>[10]</sup> The presence of elevated intraocular proinflammatory and T-cell associated cytokines suggest the novel pathogenic concept that an organ specific, Th17, cell-mediated process may be important in the pathogenesis of BSRC.

Similarly, a recent study provides complimentary information on peripheral levels of 20 immune mediators in the serum of 17 BSRC patients measured during different phases of disease activity and therapy employing quantitative, multiplex immunoassay with 12 healthy volunteers serving as controls.<sup>[11]</sup> Newly diagnosed BSRC patients with active disease, naïve to systemic immunomodulatory therapy (IMT) ( $n = 4$ ) exhibited significantly elevated and positively correlated serum levels of IL-21, IL-23 and transforming growth factor- $\beta$ 1 (TGF- $\beta$ 1), three of the four key cytokines, which are known to be necessary for Th17 differentiation. While the fourth cytokine, IL-6, was not elevated, alternative pathways exist where either IL-21 or IL-23 together with TGF- $\beta$ 1 may promote Th17 differentiation independent of IL-6.<sup>[12-14]</sup> In contrast, among BSRC patients who were on systemic IMT or who were in remission ( $n = 13$ ), there was no significant difference in the serum levels of immune mediators when compared with controls. While IL-23 was not found to be elevated in the AqH of BSRC patients in the previously cited study, neither IL-21 nor TGF- $\beta$ 1 were included in the multiplex assay.<sup>[10]</sup>

Finally, the role of regulatory T-cells (Tregs), which are important in the development of certain systemic autoimmune disorders such as rheumatoid arthritis<sup>[15]</sup> and systemic lupus erythematosus<sup>[16]</sup> and in selected ocular diseases including Behcet's disease<sup>[17]</sup> and Vogt-Koyanagi-Harada (VKH) syndrome,<sup>[18]</sup> may be relevant in the maintenance of or escape from ocular self-tolerance in patients with BSRC. A pilot, case control study of 5 patients with active, treatment naïve BSRC showed that the percentage of CD4+ CD25+ Foxp3+ Tregs was significantly lower than in controls, whereas there was no difference between CD4+ CD25+ Tregs in both groups.<sup>[19]</sup>

Taken together, these studies support the notion that peripheral cytokines (IL-21, IL-23 and TGF- $\beta$ 1) necessary for Th17 cell differentiation may promote, amplify and maintain a chronic, intraocular Th17 cell-mediated autoimmune response in patients with active BSRC. The mechanism by which chorioretinal-specific targeting of Th17 cell-mediated inflammation occurs in BSRC remains to be elucidated. In terms of clinical management, these findings underscore the importance of systemic therapy in BSRC, suggesting not only new strategies for targeted treatment, but also new insight into the determinants of and markers for the induction of sustained remission.

## EPIDEMIOLOGY

Birdshot retinochoroidopathy is a disease seen almost exclusively in the Caucasian population with a mean onset age of 53 years and a slight female preponderance ranging from 51.7% to 72.7% in various studies.<sup>[1]</sup> Given its rarity, little data exists on the true national or global prevalence of the disease although it accounts for between 0.6% and 1.5% of cases referred to specialty uveitis centers, or 6-7% of those with posterior uveitis.<sup>[1]</sup>

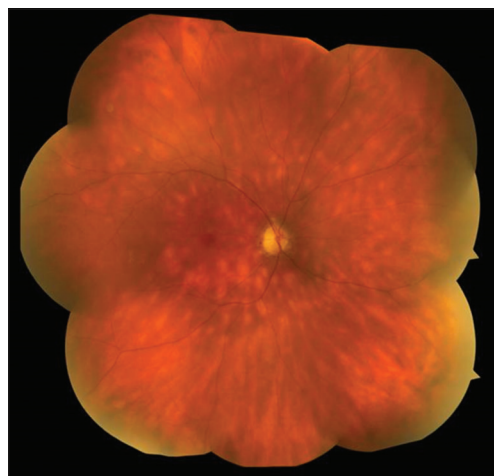
A peculiar aspect of the epidemiology of BSRC is its essential restriction to the Caucasian population. Sequencing of the Class I region has revealed more than 20 HLA-A29 subtypes, the most common being HLA-A29.2, and HLA-A29.1, the frequency and distribution of each varying with ethnicity.<sup>[20]</sup> Among HLA-A29 positive healthy white patients of Northern European extraction, the HLA-A29.2 subtype is present in approximately 80-100%, whereas the HLA-A29.1 subtype is found more commonly among populations from Southeast Asia where BSRC is absent or extremely rare.<sup>[21]</sup> While case reports exist among Hispanic<sup>[22]</sup> and African American patients in the USA,<sup>[23]</sup> and from Japan,<sup>[24]</sup> the disease is virtually nonexistent in Asia and the Indian subcontinent. The differential distribution of HLA-A29.2 and HLA-A29.1 among whites and Asians respectively has been cited as an explanation for the selective development of BSRC in patients of Northern European descent, with HLA-A29.2 thought to confer significant risk for the development of disease, while a "resistance motif" has been invoked in association with HLA-A29.1.<sup>[25,26]</sup> In the United States, the gene frequency of HLA-A29.2 is 4.34% in whites, 3.57% in African Americans, and 4.91% in Hispanics and 0.42% in Asian Americans.<sup>[27]</sup> Corresponding gene frequencies for HLA-A29.1 include 0.19% in whites, 0.21% in Hispanics and 0.125% in Asian Americans. The low frequency of HLA-A29.2 in Asian Americans may partially explain the paucity of reported cases in this group; however, it does not among African Americans and Hispanics who appear strikingly protected from the disease. Recently, high resolution DNA typing of HLA-A29 among 20 patients with BSRC failed to support a protective role for HLA-A29.1 as both HLA-A29.1 and HLA-A29.2 were associated with disease.<sup>[28]</sup> Likewise, HLA-A29.1 has been reported in 2 white patients with a clinical diagnosis of BSRC; the HLA-A29.1 haplotype for white patients and Asian healthy subjects being identical, together with HLA-A29.1 and HLA-A29.2 complotypes.<sup>[20,29]</sup> These data suggest that heretofore unidentified factors, not linked to the HLA allele, are either protective in Asians, Hispanics, and Africans or conversely, trigger autoimmune reactivity in whites.

## CLINICAL FINDINGS

Patients often present in the subacute phase of the disease with floaters, photopsias, scotomata, nyctalopia, poor color, and contrast sensitivity.<sup>[30]</sup> Not infrequently, they may complain of blurry vision despite fairly good Snellen visual acuity. This may be attributable to metamorphopsia and poor contrast sensitivity.<sup>[1]</sup> Photophobia and pain are infrequent findings as are clinical signs and structural complications of anterior segment inflammation such as posterior synechiae; however, a mild vitritis is almost universally present.<sup>[1]</sup> Macular edema as seen clinically, angiographically or by optical coherence tomography (OCT) is the most common cause of central vision loss in patients with BSRC.<sup>[1]</sup> Retinal vasculitis is an important component of active disease and manifests predominantly as a periphlebitis being best visualized by fluorescein angiography (FA).<sup>[31,32]</sup> Funduscopic findings include ovoid cream-colored lesions at the level of the choroid and retinal pigment epithelium (RPE), which are typically postequatorial in location, have a nasal and radial distribution, and are best visualized by indirect ophthalmoscopy<sup>[22,33]</sup> [Figure 1]. Funduscopic findings later in the disease include vascular attenuation,<sup>[6]</sup> nerve pallor and diffuse retinal atrophy with pigmentary changes<sup>[31,34,35]</sup> and the infrequent development of choroidal neovascularization (CNV).

## DIAGNOSIS

The diagnosis of BSRC is essentially a clinical one, based on a thorough ophthalmic and medical history, review of systems, and ocular examination revealing the characteristic funduscopic picture. The absence of



**Figure 1.** Fundus photograph of a patient with birdshot retinochoroidopathy. The lesions are typically at the level of the choroid or retinal pigment epithelium; ovoid, cream-colored with indistinct borders. They are between 50 and 1,500  $\mu\text{m}$  in size with a characteristic nasal, radial distribution in the postequatorial fundus.

significant anterior inflammatory sequelae (synechiae), the presence of vitritis and/or cystoid macular edema (CME) without pars plana exudation, and HLA-A29 positivity all serve to solidify the diagnosis. Except for atypical cases, laboratory and ancillary testing are usually not necessary to establish the diagnosis of BSRC, but they are most useful in confirming the initial clinical impression and in excluding other differential diagnostic considerations.

The presence of HLA-A29 is not an absolute criterion for the diagnosis of BSRC.<sup>[36]</sup> While up to 96% of patients in the reported literature are HLA-A29 positive, based largely on antibody-based HLA typing, the positive predictive value of this test is <50% given the low prevalence of BSRC among patients with posterior uveitis (7%); hence, routine screening is discouraged as the diagnosis of BSRC would be more often incorrect based on this test alone.<sup>[37]</sup> On the other hand, for patients with bilateral multifocal choroiditis and clinical features consistent with a diagnosis of BSRC, the negative predictive value of HLA-29 typing (99%) may be useful as it may suggest alternative diagnoses such as sarcoidosis or choroidal lymphoma in the correct clinical context. While false negative antibody-based HLA-A29 typing has been reported in two patients with BSRC,<sup>[38]</sup> the more widespread availability of polymerase chain reaction based techniques should eliminate these outliers. Conversely, the absence of the typical clinical features of BSRC in the presence of the HLA-A29 positivity should prompt consideration of an alternative diagnosis, as 7% of the general population carries this haplotype.

## DIFFERENTIAL DIAGNOSES

The various inflammatory, infectious, and neoplastic entities that may mimic BSRC appear in Table 1. Infectious entities that may produce white dots in the retina and choroid, such as syphilis and tuberculosis, must be considered in the differential diagnosis, as these require specific antimicrobial therapy.

**Table 1. Differential Diagnoses of Birdshot**

**Noninfectious Uveitis:**

- Sarcoidosis
- Acute posterior multifocal placoid pigment epitheliopathy
- Multifocal choroiditis and panuveitis
- Vogt-Koyanagi-Harada syndrome
- Sympathetic ophthalmia
- Punctate inner choroidopathy
- Multiple evanescent white dot syndrome

**Infectious Uveitis:**

- Syphilis
- Tuberculosis
- Diffuse unilateral subacute neuroretinitis

**Masquerade Syndromes of Uveitis:**

- Primary intraocular lymphoma

In the absence of anterior segment stigmata of granulomatous inflammation, posterior involvement by sarcoidosis may closely resemble that of BSRC both morphologically and angiographically.<sup>[39-42]</sup>

In contrast to BSRC, the cream-colored lesions of acute posterior multifocal posterior placoid epitheliopathy (APMPPE) have a plaque-like morphology, are located predominantly in the posterior pole, and exhibit characteristic angiographic features of early blockage and late staining. Moreover, the acute lesions of APMPPE typically resolve with retinal pigment epithelial hyperpigmentation, whereas, those with BSRC do not.<sup>[43,44]</sup>

Other white dot syndromes to be distinguished from BSRC include multifocal choroiditis and panuveitis, which typically exhibits smaller, discrete, punched out hyper- and hypo-pigmented lesions that block early, stain late, and are typically clustered around the optic nerve.<sup>[45]</sup>

Bilateral choroidal lesions appearing in the acute uveitic phase of VKH disease may be distinguished from those of BSRC by the presence of exudative retinal detachment with pinpoint areas of hyper-fluorescence at the level of the RPE with subneurosensory pooling on FA versus retinal vascular inflammation. In addition, VKH is a systemic disease with characteristic extraocular differentiating features.<sup>[46]</sup>

Finally, patients with primary intraocular lymphoma may present with multiple bilateral yellowish lesions and vitritis; however, their subretinal, sub-RPE location in the clinical context usually distinguishes them from those seen in BSRC.<sup>[47-50]</sup>

## TREATMENT

When to initiate therapy, the optimal therapeutic regimen, and the duration of such treatment are important issues in the management of BSRC. While it has been suggested that as many as 20% of patients with birdshot may have self-limited disease,<sup>[22]</sup> long-term follow-up suggests a course marked by multiple inflammatory exacerbations and progressive visual loss replete with structural complications and global retinal dysfunction over the long-term independent previous oral corticosteroid therapy.<sup>[33,34,51,52]</sup> Given this guarded visual prognosis and uncertain natural history, the early introduction of steroid-sparing IMT has been advocated in the treatment of BSRC as extended treatment is anticipated in most patients.<sup>[53]</sup> Indeed, numerous studies have demonstrated that both preservation of visual function with a reduction of inflammation, macular edema, and preservation of global retinal integrity as well as the induction of long-term remission is possible in patients with BSRC managed in this fashion.<sup>[9,22,51,52,54-56]</sup>

Certainly highly symptomatic patients with BSRC, especially those who present with or develop vitritis, retinal vasculitis, macular edema, or evidence of

peripheral retinal dysfunction should be treated as described above. The situation is not as clear in the minimally symptomatic individual who presents with a classical fundusoscopic appearance of BSRC, no clinically apparent inflammation, absent structural complications, full visual field (VF), normal electroretinogram (ERG) and excellent visual acuity. It may be difficult to convince and/or inappropriate to commit such a patient to an extended course of IMT at this point in their disease as such therapy is not entirely benign. Imaging modalities, FA and indocyanine green angiography (ICGA) are very sensitive in detecting subclinical retinochoroidal inflammation and may influence one's decision to treat with IMT in these situations as this approach has been shown to stabilize and even reverse both VF and ERG abnormalities associated with BSRC, which may occur even in the absence of clinically overt signs of inflammation.

There is no consensus on the optimal treatment regimen or duration of therapy for patients with BSRC. Corticosteroids are typically employed in the management of the more acute inflammatory manifestations of the disease and may be administered systemically, as bridging therapy until systemic IMT becomes effective, or as periocular and/or intravitreal injections for the treatment of acute or recurrent macular edema. Systemic corticosteroids are of inconsistent efficacy over the long run when used as chronic monotherapy requiring unacceptably high maintenance doses with the not infrequent development of serious steroid-associated adverse effects.

Systemic IMT options include antimetabolites, T-cell transduction/calcineurin inhibitors, intravenous immunoglobulin (IVIg) and the emerging use of other biologic therapies alone or in combination.

In an initial retrospective study of 19 patients with BSRC and in the subsequent study of 28 in patients from the same institution treated with very low initial doses of cyclosporine (2.5 mg/kg/day) alone or in combination with antimetabolites (methotrexate [MTX], azathioprine, mycophenolate mofetil [MM]) or daclizumab, a favorable visual outcome, inflammatory control, stabilization of ERG parameters, and the absence of demonstrable nephrotoxic side effects were achieved.<sup>[9,55]</sup>

Similarly, a recent retrospective analysis of 76 HLA-A 29 patients with BSRC, 46 of whom were followed for 5 years and 18 for >10 years, demonstrated that visual outcomes were better for those treated with MTX as compared to untreated individuals and corticosteroid-based regimens.<sup>[35]</sup>

While the use of MTX or cyclosporine alone may be superior to the long-term use of systemic corticosteroids in the treatment of BSRC, monotherapy with cyclosporine, in our experience, has been associated with need for exceedingly prolonged therapy with the recurrences of inflammation when tapering this medication.

In an effort to achieve durable remission of inflammation, the combination of cyclosporine or MM has been exploited in 49 patients (98 eyes), over a mean follow-up time of 65 months. At the 1-year time point, vitreous inflammatory scores, the presence of angiographic leakage, but not the presence of CME, were significantly reduced from baseline with 67% (31/46) of patients achieving inflammatory control with no deterioration of ERG indices. All of these patients were able to maintain inflammatory remission off any kind of corticosteroids after the 1-year follow-up.<sup>[57]</sup>

For patients with inflammation refractory to conventional IMT, biological agents such as IVIg<sup>[58]</sup> and daclizumab<sup>[59,60]</sup> had been successfully employed in a small series of patients, although the latter agent is no longer available. The use of monoclonal antibodies to TNF- $\alpha$  is an emerging treatment alternative to conventional IMT, either alone or in combination. In a recent retrospective study of 22 patients with BSRC refractory to conventional IMT treated with infliximab, inflammatory control was achieved in 81.8% and 88.9% of patients at 6 months and the 1-year follow-up, respectively. Similarly, the rate of CME decreased from 22.7% at baseline to 13.9% at 6 months and to 6.7% at 12 months, while the percentage of patients with a visual acuity (VA)  $\geq 20/40$  increased from 84.1% at baseline to 91.7% and 94.4% at 6 months and 1-year, respectively.<sup>[61]</sup> Over the course of the study, 3 patients had active inflammation during therapy and 6 discontinued infliximab due to adverse effects.

The sustained release fluocinolone acetonide implant (Retisert<sup>®</sup>) may be a viable alternative for patients with BSRC who are unable to tolerate systemic corticosteroids or IMT.<sup>[62-64]</sup> While highly effective in controlling inflammation, reducing CME, stabilizing and/or improving vision and reducing the need for systemic IMT, the decision to employ this modality as the initial therapy should be tempered by the universal development of cataract and a more robust intraocular pressure response to the FA implant in eyes with BSRC than in those with other types of posterior and panuveitis. Specifically, there was a statistically significant increase in intraocular pressure during the first 4 months following FA implantation as well as a higher percentage of eyes requiring glaucoma surgery after a shorter time period following FA implantation (0.42/eye-year [EY] vs. 0.11/EY; median time to glaucoma surgery: 15.5 months vs. 31.5 months respectively, hazard ratio, 3.4; 95% confidence interval, 1.0-10.8,  $P = 0.04$ ).<sup>[64]</sup>

While there is consensus that the early introduction of steroid-sparing IMT offers the best long-term control of inflammation and preservation of visual function, in the absence of prospective, comparative data, the choice of drug and the regimen must be individualized to each patient with consideration given to both their medical status as well as to the availability and cost of these medications. An antimetabolite is generally commenced together

with systemic corticosteroids to treat the more acute manifestations of the disease; however, it is not known which antimetabolite is superior as the initial therapy. In the event of inflammatory recurrence while on an antimetabolite, cyclosporine or tacrolimus may be added. Whether sequential or initial combined therapy of an antimetabolite and a calcineurin inhibitor is most efficacious in an effort to achieve durable remission, requires further prospective study. Should the inflammation recur despite combined IMT, therapy may be advanced to the available biologic agents such as IVIg or TNF inhibitors with discontinuation of cyclosporine or tacrolimus.

The demonstration of IL-17, IL-2, IL-1 $\beta$  and TNF- $\alpha$  in the aqueous humor of patients with BSRC supports the use of infliximab and daclizumab in this disease and raises the possibility for therapeutic potential of anti-IL-17 therapy. Similarly, the presence of IL-21, I-L23, and TGF- $\beta$ 1 in the peripheral blood of patients with active, treatment naïve BSRC suggests a therapeutic rationale for the upstream or downstream targeting one or more of the cytokines involved in the Th17 cell-mediated with available or emerging biologic antagonists such as ustekinumab.<sup>[11]</sup> Whether such targeted biologic therapy is superior to standard IMT in the management of established intraocular inflammation and whether the active phenotype of Th17 cells and the production of proinflammatory cytokines (IL-17) can be modulated in such a way to reestablish immunologic tolerance and achieve sustained remission independent of chronic therapy, are important avenues for investigation moving forward.

## PROGNOSIS

Birdshot retinochoroidopathy is a chronic progressive disease with the potential for significant visual impairment due to both structural complications (CME) and diffuse retinal dysfunction with the duration of disease being a statistically significant risk factor for both. In some eyes, central VA may be preserved until late in the disease course with significant irreversible peripheral retinal damage. Reported incidence rates for the development of vision loss to 20/50 or worse and to 20/200 or worse are 13% and 4%/EY, respectively.<sup>[54]</sup> Similarly, CME, with central visual loss, occurs at 10%/EY. The use of long-term IMT results in an 83% reduction in CME,<sup>[54]</sup> may improve and/or stabilize VF<sup>[65,66]</sup> and ERG parameters,<sup>[55,57,67-69]</sup> and in some cases, produce long-term remission in patients with BSRC.<sup>[57]</sup>

There is no prospective data with respect to rates of relapse and remission in patients with BSRC, as well as to the optimal duration of therapy with IMT to achieve this goal. The Standardization of Uveitis Nomenclature Working Group has defined the term remission as inactive disease for  $\geq 3$  months after discontinuation of all treatments for ocular inflammation; however, this definition is clearly limited with respect to BSRC given its protracted course

and the insidious nature of the development of visual dysfunction.<sup>[53]</sup> More clinically meaningful categories for clinical remission derived from those suggested for juvenile idiopathic arthritis, may be more congruent with the overall treatment goals for patients with inflammatory ocular disease in general and those with BSRC in particular and include: clinical remission, defined as inactive disease for 6 months on medication; and durable remission, defined as inactive disease off all IMT for 1-year.

## MONITORING

The treatment endpoints, and so, the determinants of relapse and remission as well as the effective evaluation of existing and novel treatment strategies in BSRC hinge on the accurate assessment and monitoring of disease activity and severity in patients with BSRC; however, there is no consensus on how to best achieve this. Given that the typical clinical indices for inflammatory activity are clearly inadequate alone, a multifaceted approach employing electroretinographic and psychophysical testing, together with multimodal imaging modalities, is currently employed.

## FULL FIELD ELECTRORETINOGRAPHY AND PSYCHOPHYSICAL TESTING

Full field electroretinography and perimetry have proven invaluable in the longitudinal follow-up of patients with BSRC for detection of global retinal dysfunction and peripheral retinal abnormalities respectively. As previously noted, the institution of IMT has been shown to stabilize and even partially reverse both VF and ERG abnormalities associated with BSRC, which may occur even in the absence of clinically overt signs of inflammation.<sup>[55,57,65-69]</sup>

Prolongation of the 30 Hz flicker implicit time on the full field ERG testing has emerged as the single most important proxy marker for monitoring disease in patients with BSRC as it has been consistently correlated with disease activity, visual acuity, and may improve or stabilize with treatment, while predicting relapse with tapering of IMT.<sup>[67-69]</sup> Likewise, perturbations in other ERG parameters such as the dim rod scotopic b wave and bright scotopic b wave amplitudes correlate with disease severity (night blindness) and treatment failure with IMT taper respectively.<sup>[67]</sup> While retrospective data suggests that longer treatment intervals and perhaps more intensive therapy with alternative IMT may achieve better inflammatory control, prospective evaluation of the incremental changes in these ERG parameters will be of value not only in validating this impression, but also, in the management of patients between clinic visits.<sup>[70]</sup> Practically, ERG testing may present logistical problems

for both clinicians and patients where such expertise is not readily available.

In contrast, VF testing as a direct measure of both central and peripheral visual function is more widely available. Abnormalities on Humphrey visual field (HVF) testing were present in 62% of 80 patients with BSRC at baseline with the most common patterns being multiple foci and arcuate defects.<sup>[71]</sup> While mean deviation scores were correlated with patient symptoms (blurred vision, nyctalopia and poor contrast sensitivity), and less so with visual acuity, VF abnormalities were observed in patients with normal visual acuity, underscoring the importance of monitoring peripheral retinal function in patients with BSRC. Moreover, total deviation was correlated with disappearance of the inner segment (IS)/outer segment (OS) band on time domain OCT. Goldmann visual field (GVF) defects (I-4 isopter) were present in 75% of 24 BSRC patients within 6 months of presentation with continued VF loss among those off treatment while some degree of reversibility for those receiving IMT.<sup>[65]</sup>

The progression of VF defects over time in association with disease activity<sup>[22,33,52,72]</sup> and their improvement under systemic IMT<sup>[65,66]</sup> suggests that standardized evaluations may provide data that are useful in the longitudinal management of these patients. It has been suggested that GVF testing is more sensitive than HVF protocols in the evaluation of BSRC patients although this has not been studied in large groups of patients.<sup>[65]</sup> Certainly VF testing is fraught with inconsistency due to the inherent introduction of subjectivity on the part of the patient; however, GVF testing is additionally dependent on the expertise of the technician performing the test and is less widely available than HVF testing. Similarly, while it has been suggested that ERG testing may be more sensitive in the detection of early retinal dysfunction than VF testing, practical matters of time, cost, and access to available expertise of such testing must be considered. Monitoring with each modality on an alternate basis (every 6 months) may be a reasonable compromise.

## MULTIMODAL IMAGING

Multimodal imaging with FA, ICGA, OCT and fundus autofluorescence (FAF) has demonstrated that the inner and outer retina, RPE and choroid are all involved, albeit differentially, in BSRC and is widely employed for both monitor and guide therapy. Questions remain as to which combinations of established and emerging imaging modalities are best suited for monitoring disease activity and as to whether there exists a BSRC phenotype based on early imaging.

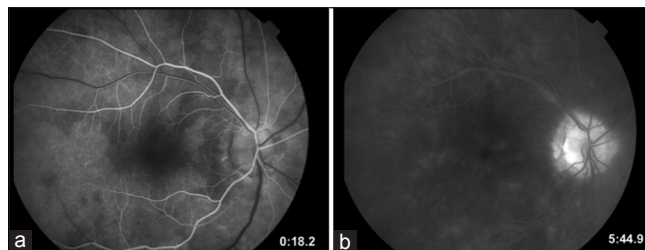
## FLUORESCIN ANGIOGRAPHY

Fluorescein angiography typically fails to highlight the birdshot lesions themselves; rather the angiographic

heterogeneity of these lesions seems to depend on their age and associated degree of activity, as well as on the presence of many lesions at different stages of evolution within the same eye. More important, FA may reveal critical components of active disease including retinal vasculitis, subtle macular edema, optic nerve head leakage, and diffuse posterior pole hyper-fluorescence<sup>[73]</sup> [Figure 2]. Late structural complications of BSRC include retinal vascular attenuation, optic atrophy, epiretinal membrane formation<sup>[31,32]</sup> and the uncommon occurrence of CNV, the latter best visualized by FA.<sup>[74,75]</sup> The arteriovenous transit time is frequently prolonged in BSRC and it has been suggested that this finding may have diagnostic value in comparison to other posterior uveitic entities. Employing concurrent FA and ICGA, this finding has been reinterpreted in the light of the nearly normal transit time seen on ICGA versus the prolonged transit time measured on FA, attributable to extreme leakage of fluorescein dye from retinal arterioles and diffusion into the surrounding tissue prior to entering the venous circulation and to the more protein-bound, and hence, intravascular ICG.<sup>[73,76]</sup> For this reason, a timed transit should be performed in patients with BSRC. The overarching utility of both standard and wide-field FA may be in the detection of clinically unapparent retinal vascular leakage, providing a highly sensitive index for active inflammation and may even reveal a BSRC phenotype in the early stages of the disease. Indeed, retinal vascular leakage as demonstrated by FA may be associated with decreased VA in eyes with a normal OCT.<sup>[77]</sup>

## INDOCYANINE GREEN ANGIOGRAPHY

Indocyanine green angiography discloses multiple hypo-fluorescent spots in the mid phase of the study, distributed around choroidal vessels, which may correspond to funduscopy lesions but are typically

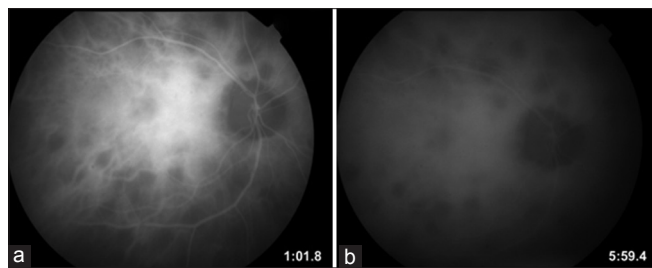


**Figure 2.** Fluorescein angiographic findings in birdshot are inconsistent and depend on the age of the lesions and the phase of the study. Early birdshot lesions (a) demonstrate early hypofluorescence with subtle late staining. In the later stages of the angiogram (b), leakage at the optic nerve is typically seen as a segmental periphlebitis. Cystoid macular edema and choroidal neovascularization may also be evident.

more numerous than those appreciated on clinical examination or on FA [Figure 3]. Some areas of patchy hyper-fluorescence observed on FA did correspond to the hypo-fluorescent dots on ICGA, again suggesting that the retina and choroid are differentially affected in this disease.<sup>[78]</sup> ICGA may be valuable diagnostically in patients with lightly pigmented fundi and very early in the course of the disease where hypo-fluorescent dots are readily visualized by ICGA but the lesions themselves are not apparent clinically, on color photography or on FA.<sup>[73]</sup> Patients with recent active disease may also have fuzzy, indistinct choroidal vessels and late-diffuse choroidal hyper-fluorescence.<sup>[73]</sup> Both of these findings as well as the hypo-fluorescent dots not corresponding to window defects on FA, have been reported to respond to therapy to some degree.<sup>[73,78]</sup> While providing insight into the choroidal inflammatory component of this disease, the more precise use of ICGA in monitoring patients with BSRC awaits prospective study.

## FUNDUS AUTOFLUORESCENCE

Fundus autofluorescence imaging is a relatively new, noninvasive, *in vivo* modality that exploits the autofluorescence properties associated with lipofuscin accumulation within RPE cells and that of other fluorophores within the outer retina and subretinal space. It provides complimentary information with respect to RPE structure and function that may not be apparent with other imaging modalities and so, offer new insights into disease pathogenesis for monitoring progression.<sup>[79]</sup> FAF findings in BSRC include discrete areas of hypoautofluorescence (hypoAF) due to RPE atrophy; however there appears to be a nonuniform correspondence between these spots and the birdshot lesions seen biomicroscopically.<sup>[80,81]</sup> RPE atrophy as visualized by FAF is seen both in areas of hypo-pigmented lesions and in areas where there are no such lesions suggesting that choroid and RPE (outer retina) may be differentially and independently affected. Likewise, the presence of linear hypoAF streaks, corresponding to visible changes at the level of the RPE along retinal



**Figure 3.** Indocyanine angiography in birdshot retinochoroidopathy reveals hypo-fluorescent spots in both the early phases of the study (a), as well as the late phases of the study (b) that are more numerous than those seen on fluorescein angiography.

blood vessels in some patients, reinforces the notion that retinal vascular inflammation plays an independent role in mediating inflammatory damage to the RPE. Finally, areas of placoid macular hypoAF indicative of RPE atrophy have been significantly correlated with VA of 20/50 or worse and with decreased mean foveal thickness.<sup>[80]</sup> With respect to disease monitoring, it will be of interest to learn whether these FAF findings are dynamic; changing with the progression of disease or modifiable with treatment.

## OPTICAL COHERENCE TOMOGRAPHY

Optical coherence tomography is an invaluable noninvasive tool in the detection, quantification and longitudinal management of cystic, intraretinal and subretinal fluid associated inflammatory macular edema and CNV and in the delineation of other structural abnormalities including, epiretinal membranes and vitreomacular traction, in patients with BSRC.<sup>[82]</sup> At baseline, 31% of 122 eyes with BSRC were found to have macular edema using time-domain OCT.<sup>[77]</sup>

High resolution, spectral domain OCT (SD-OCT) provides more precise anatomic detail of both inner and outer retinal anatomy including the clear identification of the external limiting membrane, the photoreceptor IS/OS junction, and the RPE/Bruch's membrane complex, the integrity of each being potentially predictive of reversible and irreversible macular changes; however, there are few studies detailing these findings in patients with BSRC. Macular thinning and disruption of the photoreceptor IS/OS junction has been noted using both time domain and SD-OCT and had been associated with decreased VA, contrast sensitivity and portends a poor visual prognosis.<sup>[77,83,84]</sup> Indeed, among 14 eyes of 7 patients with longstanding BSRC, macular atrophy as measured by SD-OCT was correlated with poor VA and depressed multifocal ERG (mfERG) foveal responses.<sup>[84]</sup> Macular thinning was associated with a loss of thickness of the segment subtending the proximal border of the outer plexiform layer and the Bruch-membrane-choroid interface suggesting that macular atrophy in BSRC occurs largely in the outer retina.<sup>[84,85]</sup> The mfERG was abnormal even among those patients without evidence of macular atrophy on SD-OCT suggesting that mfERG changes precede thinning on OCT damage and may serve as a sensitive surrogate marker for disease activity before the development of irreversible structural damage. Restoration of macular outer retinal architecture as visualized by SD-OCT has been described in a patient with BSRC with the institution of systemic IMT.<sup>[86]</sup>

The recent introduction of "enhanced depth imaging" (EDI) protocols<sup>[87]</sup> and extramacular image acquisition<sup>[88]</sup> with currently available SD-OCT provides high resolution visualization of the choroidal



anatomy and the delineation of potentially significant structural changes outside the macula/vascular arcades respectively, heretofore unobtainable by conventional OCT. These protocols may be ideally suited for the study or uncommon chorioretinal diseases such as BSRC in which there is diffuse and differential inflammation of retina, RPE, and choroid which may not be confined entirely to the macula.

Retinal and choroidal morphology among 12 patients (24 eyes) with HLA-A29 positive BSRC was recently evaluated prospectively using a standard protocol for EDI and extramacular SD-OCT imaging and compared to that of 9 (18 eyes) normal controls.<sup>[89]</sup> Extramacular image sets revealed a spectrum of outer retinal substructure derangement ranging from focal disruption to generalized loss of the photoreceptor IS/OS junction as well as visualization of a “transition zone” in which structural abnormalities were initially seen. With generalized thinning and loss of retinal architecture, small hyper-reflective foci, thought to represent either clumping of the photoreceptors or pigment migration in response to injury, were observed in the absence of the photoreceptor IS/OS junction. Choroidal abnormalities included thinning/absence of Sattler layer, generalized atrophy, significantly reduced foveal choroidal thickness measurements relative to normal, focal choroidal hypo-pigmentation (increased sclera reflectivity corresponding to birdshot lesions), discrete hyper-reflective foci (proximate to birdshot lesions and thought to represent either pigment or clusters of inflammatory cells) and the presence of suprachoroidal hyporeflective space (fluid, possibly indicative of ongoing choroidal inflammation).

Preliminary data from a retrospective study of 14 HLA-A29 positive BSRC patients evaluated clinically and with EDI SD-OCT indicates that both the presence and thickness of this suprachoroidal fluid band is positively correlated not only with the subjective complaint of photopsias, but also with overt signs of active inflammation, specifically, retinal vasculitis and vitritis.<sup>[90]</sup>

The use of EDI and extramacular OCT may allow improved phenotyping of posterior uveitic entities in general and of BSRC in particular. Both qualitative and quantitative assessment of the IS/OS junction thickness and intensity in peripheral locations may prove valuable both in clinical practice, as a marker for disease activity and response to therapy even in situations when it appears grossly intact, and as a surrogate endpoint in clinical trials. Likewise, abnormalities in choroidal morphology, such as the presence and thickness of suprachoroidal fluid, may serve as sensitive markers for disease activity which correlates with not only overt signs of inflammation (vasculitis and vitritis), but also subjective complaints (photopsias) which may influence treatment decisions. While assessment of the choroid for

evidence of focal depigmentation with accompanying hyper-reflective foci may be of value diagnostically, the utility of EDI in monitoring disease activity will require prospective study to determine whether and to what degree these abnormalities in choroidal morphology are modifiable with therapy. Finally, detailed prospective evaluation of the relationship between extramacular and choroidal structural abnormalities, as well as those seen on other imaging modalities, such as FAF, the presence of inflammatory activity as manifested by FA and ICGA, and their functional correlates on electroretinographic and psychophysical testing will be fruitful avenues for future investigation.

Finally, as previously mentioned, peripheral cytokine levels may prove to be valuable markers in monitoring disease progression, predicting inflammatory recurrence and/or recalcitrant disease as well as the response to therapy.

## CYTOKINES

As previously mentioned, intraocular (IL-17, IL-2, IL-1 $\beta$  and TNF- $\alpha$ ) and peripheral cytokines (IL-21, IL-23 and TGF- $\beta$ 1) necessary for Th17 cell differentiation and abnormalities of Tregs in patients with active BSRC have been recently demonstrated.<sup>[10,11,19]</sup> These may provide valuable markers for monitoring disease progression, predicting inflammatory recurrence and/or recalcitrant disease as well as the response to therapy.

## SUMMARY

BSRC is a chronic, progressive sight-threatening disease, which requires the early introduction of IMT in an effort to limit ocular structural damage, preserve global visual function, and induce long-term remission. Important questions remain in our understanding of this disease with respect to its pathogenesis, epidemiology, optimal treatment, prognosis, including predictors of remission and relapse, and in monitoring of disease progression and response to therapy. Markers of active and progressive disease, which may influence treatment decisions, include not only clinical indices of intraocular inflammation, but also those seen on established and emerging imaging modalities, including FA, ICGA, OCT (with EDI) and FAF, perimetry and electroretinography. Refinements in and standardization of the existing protocols for both ERG and VF testing, including the optimal type of perimetry, will be of value from both a clinical and research perspective. Likewise, questions remain as to which combinations of established and emerging imaging modalities are best suited for monitoring disease activity and as to whether a BSRC phenotype may be discerned on early imaging. Finally, cytokine levels may prove to be valuable markers in monitoring disease progression, predicting

inflammatory recurrence and/or recalcitrant disease as well as the response to therapy.

## REFERENCES

- Shah KH, Levinson RD, Yu F, Goldhardt R, Gordon LK, Gonzales CR, et al. Birdshot chorioretinopathy. *Surv Ophthalmol* 2005;50:519-541.
- Holak HM, Szymaniec S, Holak SA. The pathogenesis of birdshot chorioretinopathy. *Surv Ophthalmol* 2006;51:446-447.
- Suttorp-Schulten MS, Luyendijk L, van Dam AP, de Keizer RJ, Baarsma GS, Bos PJ, et al. Birdshot chorioretinopathy and Lyme borreliosis. *Am J Ophthalmol* 1993;115:149-153.
- Nussenblatt RB, Mittal KK, Ryan S, Green WR, Maumenee AE. Birdshot retinochoroidopathy associated with HLA-A29 antigen and immune responsiveness to retinal S-antigen. *Am J Ophthalmol* 1982;94:147-158.
- de Smet MD, Yamamoto JH, Mochizuki M, Gery I, Singh VK, Shinohara T, et al. Cellular immune responses of patients with uveitis to retinal antigens and their fragments. *Am J Ophthalmol* 1990;110:135-142.
- Nussenblatt RB, Kuwabara T, de Monasterio FM, Wacker WB. S-antigen uveitis in primates. A new model for human disease. *Arch Ophthalmol* 1981;99:1090-1092.
- Gaudio PA, Kaye DB, Crawford JB. Histopathology of birdshot retinochoroidopathy. *Br J Ophthalmol* 2002;86:1439-1441.
- Levinson RD. Killer immunoglobulin-like receptor genes in uveitis. *Ocul Immunol Inflamm* 2011;19:192-201.
- Vitale AT, Rodriguez A, Foster CS. Low-dose cyclosporine therapy in the treatment of birdshot retinochoroidopathy. *Ophthalmology* 1994;101:822-831.
- Kuiper JJ, Mutis T, de Jager W, de Groot-Mijnes JD, Rothova A. Intraocular interleukin-17 and proinflammatory cytokines in HLA-A29-associated birdshot chorioretinopathy. *Am J Ophthalmol* 2011;152:177-182.e1.
- Yang P, Foster CS. Interleukin 21, interleukin 23, and transforming growth factor  $\beta$ 1 in HLA-A29-associated birdshot retinochoroidopathy. *Am J Ophthalmol* 2013;156:400-406.
- Zhou L, Ivanov II, Spolski R, Min R, Shenderov K, Egawa T, et al. IL-6 programs T(H)-17 cell differentiation by promoting sequential engagement of the IL-21 and IL-23 pathways. *Nat Immunol* 2007;8:967-974.
- Korn T, Bettelli E, Gao W, Awasthi A, Jäger A, Strom TB, et al. IL-21 initiates an alternative pathway to induce proinflammatory T (H) 17 cells. *Nature* 2007;448:484-487.
- Manel N, Unutmaz D, Littman DR. The differentiation of human T (H)-17 cells requires transforming growth factor-beta and induction of the nuclear receptor ROR $\gamma$ mat. *Nat Immunol* 2008;9:641-649.
- Raghavan S, Cao D, Widhe M, Roth K, Herrath J, Engström M, et al. FOXP3 expression in blood, synovial fluid and synovial tissue during inflammatory arthritis and intra-articular corticosteroid treatment. *Ann Rheum Dis* 2009;68:1908-1915.
- Crispín JC, Kytтарыс VC, Terhorst C, Tsokos GC. T cells as therapeutic targets in SLE. *Nat Rev Rheumatol* 2010;6:317-325.
- Nanke Y, Kotake S, Goto M, Ujihara H, Matsubara M, Kamatani N. Decreased percentages of regulatory T cells in peripheral blood of patients with Behcet's disease before ocular attack: a possible predictive marker of ocular attack. *Mod Rheumatol* 2008;18:354-358.
- Chen L, Yang P, Zhou H, He H, Ren X, Chi W, et al. Diminished frequency and function of CD4+CD25high regulatory T cells associated with active uveitis in Vogt-Koyanagi-Harada syndrome. *Invest Ophthalmol Vis Sci* 2008;49:3475-3482.
- Foster CS, Siddique SS, Amorese L, Mulki L, Suelves A. Regulatory T cells in blood of patients with birdshot retinochoroidopathy. *Ophthalmology* 2013;120:430.e1.
- Donvito B, Monnet D, Tabary T, Delair E, Vittier M, Réveil B, et al. Different HLA class IA region complotypes for HLA-A29.2 and -A29.1 antigens, identical in birdshot retinochoroidopathy patients or healthy individuals. *Invest Ophthalmol Vis Sci* 2005;46:3227-3232.
- de Waal LP, Lardy NM, van der Horst AR, Baarsma GS, Kijlstra A, Noens L, et al. HLA-A29 subtypes and birdshot chorioretinopathy. *Immunogenetics* 1992;35:51-53.
- Gasch AT, Smith JA, Whitcup SM. Birdshot retinochoroidopathy. *Br J Ophthalmol* 1999;83:241-249.
- Barondes MJ, Fastenberg DM, Schwartz PL, Rosen DA. Peripheral retinal neovascularization in birdshot retinochoroidopathy. *Ann Ophthalmol* 1989;21:306-308.
- Saito W, Yamamoto S, Mitamura Y, Takeuchi S. Birdshot chorioretinopathy : a case report and a case study in Japanese patients. *Nihon Ganka Gakkai Zasshi* 2002;106:229-235.
- Tabary T, Lehoang P, Betuel H, Benhamou A, Semiglia R, Edelson C, et al. Susceptibility to birdshot chorioretinopathy is restricted to the HLA-A29.2 subtype. *Tissue Antigens* 1990;36:177-179.
- Tabary T, Prochnicka-Chalufour A, Cornillet P, Lehoang P, Betuel H, Cohen JH. HLA-A29 sub-types and "Birdshot" choroido-retinopathy susceptibility: a possible "resistance motif" in the HLA-A29.1 molecule. *C R Acad Sci III* 1991;313:599-605.
- Cao K, Hollenbach J, Shi X, Shi W, Chopek M, Fernández-Viña MA. Analysis of the frequencies of HLA-A, B, and C alleles and haplotypes in the five major ethnic groups of the United States reveals high levels of diversity in these loci and contrasting distribution patterns in these populations. *Hum Immunol* 2001;62:1009-1030.
- Levinson RD, Rajalingam R, Park MS, Reed EF, Gjertson DW, Kappel PJ, et al. Human leukocyte antigen A29 subtypes associated with birdshot retinochoroidopathy. *Am J Ophthalmol* 2004;138:631-634.
- Donvito B, Monnet D, Tabary T, Delair E, Vittier M, Réveil B, et al. A new HLA extended haplotype containing the A \* 2910 allele in birdshot retinochoroidopathy: Susceptibility narrowed to the HLA molecule itself. *Invest Ophthalmol Vis Sci* 2010;51:2525-2528.
- Ladas JG, Arnold AC, Holland GN. Control of visual symptoms in two men with birdshot retinochoroidopathy using low-dose oral corticosteroid therapy. *Am J Ophthalmol* 1999;128:116-118.
- Gass JD. Vitiliginous chorioretinitis. *Arch Ophthalmol* 1981;99:1778-1787.
- Ryan SJ, Maumenee AE. Birdshot retinochoroidopathy. *Am J Ophthalmol* 1980;89:31-45.
- Priem HA, Oosterhuis JA. Birdshot chorioretinopathy: clinical characteristics and evolution. *Br J Ophthalmol* 1988;72:646-659.
- Rothova A, Berendschot TT, Probst K, van Kooij B, Baarsma GS. Birdshot chorioretinopathy: long-term manifestations and visual prognosis. *Ophthalmology* 2004;111:954-959.
- Rothova A, Ossewaarde-van Norel A, Los LI, Berendschot TT. Efficacy of low-dose methotrexate treatment in birdshot chorioretinopathy. *Retina* 2011;31:1150-1155.
- Levinson RD, Brezin A, Rothova A, Accorinti M, Holland GN. Research criteria for the diagnosis of birdshot chorioretinopathy: results of an international consensus conference. *Am J Ophthalmol* 2006;141:185-187.
- Zamecki KJ, Jabs DA. HLA typing in uveitis: use and misuse. *Am J Ophthalmol* 2010;149:189-193.
- Wender JD, Fu AD, Jumper JM, McDonald HR, Johnson RN, Cunningham ET Jr. False negative antibody-based HLA-A29 typing in two patients with birdshot chorioretinopathy. *Br J Ophthalmol* 2008;92:1153-1154.
- Brinkman CJ, Rothova A. Fundus pathology in neurosarcoidosis. *Int Ophthalmol* 1993;17:23-26.
- Brod RD. Presumed sarcoid choroidopathy mimicking birdshot retinochoroidopathy. *Am J Ophthalmol* 1990;109:357-358.

41. Yoshioka T, Yoshioka H, Tanaka F. Birdshot retinochoroidopathy as a new ocular sign of the sarcoidosis. *Nihon Ganka Gakkai Zasshi* 1983;87:283-288.
42. Read RW, Rao NA, Sharma OP. Sarcoid choroiditis initially diagnosed as birdshot choroidopathy. *Sarcoidosis Vasc Diffuse Lung Dis* 2000;17:85-86.
43. Ryan SJ, Maumenee AE. Acute posterior multifocal placoid pigment epitheliopathy. *Am J Ophthalmol* 1972;74:1066-1074.
44. Gass JD. Acute posterior multifocal placoid pigment epitheliopathy. *Arch Ophthalmol* 1968;80:177-185.
45. Dreyer RF, Gass DJ. Multifocal choroiditis and panuveitis. A syndrome that mimics ocular histoplasmosis. *Arch Ophthalmol* 1984;102:1776-1784.
46. Moorthy RS, Inomata H, Rao NA. Vogt-Koyanagi-Harada syndrome. *Surv Ophthalmol* 1995;39:265-292.
47. Chatzistefanou K, Markomichelakis NN, Christen W, Soheilian M, Foster CS. Characteristics of uveitis presenting for the first time in the elderly. *Ophthalmology* 1998;105:347-352.
48. Gupta R, Murray PI. Chronic non-infectious uveitis in the elderly: epidemiology, pathophysiology and management. *Drugs Aging* 2006;23:535-558.
49. Kirsch O, Lautier-Frau M, Labetoulle M, Offret H, Frau E. Characteristics of uveitis presenting de novo in the elderly. *J Fr Ophthalmol* 2003;26:720-724.
50. Sen HN, Bodaghi B, Hoang PL, Nussenblatt R. Primary intraocular lymphoma: diagnosis and differential diagnosis. *Ocul Immunol Inflamm* 2009;17:133-141.
51. Becker MD, Wertheim MS, Smith JR, Rosenbaum JT. Long-term follow-up of patients with birdshot retinochoroidopathy treated with systemic immunosuppression. *Ocul Immunol Inflamm* 2005;13:289-293.
52. Oh KT, Christmas NJ, Folk JC. Birdshot retinochoroiditis: long term follow-up of a chronically progressive disease. *Am J Ophthalmol* 2002;133:622-629.
53. Jabs DA, Nussenblatt RB, Rosenbaum JT, Standardization of Uveitis Nomenclature (SUN) Working Group. Standardization of uveitis nomenclature for reporting clinical data. Results of the First International Workshop. *Am J Ophthalmol* 2005;140:509-516.
54. Thorne JE, Jabs DA, Peters GB, Hair D, Dunn JP, Kempen JH. Birdshot retinochoroidopathy: ocular complications and visual impairment. *Am J Ophthalmol* 2005;140:45-51.
55. Kiss S, Ahmed M, Letko E, Foster CS. Long-term follow-up of patients with birdshot retinochoroidopathy treated with corticosteroid-sparing systemic immunomodulatory therapy. *Ophthalmology* 2005;112:1066-1071.
56. Multicenter Uveitis Steroid Treatment (MUST) Trial Research Group, Kempen JH, Altaweel MM, Holbrook JT, Jabs DA, Louis TA, et al. Randomized comparison of systemic anti-inflammatory therapy versus fluocinolone acetonide implant for intermediate, posterior, and panuveitis: The multicenter uveitis steroid treatment trial. *Ophthalmology* 2011;118:1916-1926.
57. Cervantes-Castañeda RA, Gonzalez-Gonzalez LA, Cordero-Coma M, Yilmaz T, Foster CS. Combined therapy of cyclosporine A and mycophenolate mofetil for the treatment of birdshot retinochoroidopathy: a 12-month follow-up. *Br J Ophthalmol* 2013;97:637-643.
58. LeHoang P, Cassoux N, George F, Kullmann N, Kazatchkine MD. Intravenous immunoglobulin (IVIg) for the treatment of birdshot retinochoroidopathy. *Ocul Immunol Inflamm* 2000;8:49-57.
59. Sobrin L, Huang JJ, Christen W, Kafkala C, Choopong P, Foster CS. Daclizumab for treatment of birdshot chorioretinopathy. *Arch Ophthalmol* 2008;126:186-191.
60. Yeh S, Wroblewski K, Buggage R, Li Z, Kurup SK, Sen HN, et al. High-dose humanized anti-IL-2 receptor alpha antibody (daclizumab) for the treatment of active, non-infectious uveitis. *J Autoimmun* 2008;31:91-97.
61. Artornsombudh P, Gevorgyan O, Payal A, Siddique SS, Foster CS. Infliximab treatment of patients with birdshot retinochoroidopathy. *Ophthalmology* 2013;120:588-592.
62. Srivastava SK, Nguyen QD, Callanan D, Goldstein DA, Albini TA. The use of the fluocinolone acetonide (Retisert) implant in patients with birdshot choroidopathy. *Invest Ophthalmol Vis Sci* 2011;52:2751.
63. Rush RB, Goldstein DA, Callanan DG, Meghpara B, Feuer WJ, Davis JL. Outcomes of birdshot chorioretinopathy treated with an intravitreal sustained-release fluocinolone acetonide-containing device. *Am J Ophthalmol* [2011;151:630-636.
64. Burkholder BM, Wang J, Dunn JP, Nguyen QD, Thorne JE. Postoperative outcomes after fluocinolone acetonide implant surgery in patients with birdshot chorioretinitis and other types of posterior and panuveitis. *Retina* 2013;33:1684-1693.
65. Thorne JE, Jabs DA, Kedhar SR, Peters GB, Dunn JP. Loss of visual field among patients with birdshot chorioretinopathy. *Am J Ophthalmol* 2008;145:23-28.
66. de Courten C, Herbort CP. Potential role of computerized visual field testing for the appraisal and follow-up of birdshot chorioretinopathy. *Arch Ophthalmol* 1998;116:1389-1391.
67. Sobrin L, Lam BL, Liu M, Feuer WJ, Davis JL. Electroretinographic monitoring in birdshot chorioretinopathy. *Am J Ophthalmol* 2005;140:52-64.
68. Holder GE, Robson AG, Pavesio C, Graham EM. Electrophysiological characterisation and monitoring in the management of birdshot chorioretinopathy. *Br J Ophthalmol* 2005;89:709-718.
69. Zacks DN, Samson CM, Loewenstein J, Foster CS. Electroretinograms as an indicator of disease activity in birdshot retinochoroidopathy. *Graefes Arch Clin Exp Ophthalmol* 2002;240:601-607.
70. Comander J, Loewenstein J, Sobrin L. Diagnostic testing and disease monitoring in birdshot chorioretinopathy. *Semin Ophthalmol* 2011;26:329-336.
71. Gordon LK, Monnet D, Holland GN, Brézin AP, Yu F, Levinson RD. Longitudinal cohort study of patients with birdshot chorioretinopathy. IV. Visual field results at baseline. *Am J Ophthalmol* 2007;144:829-837.
72. Fuerst DJ, Tessler HH, Fishman GA, Yokoyama MM, Wyhinny GJ, Vygantas CM. Birdshot retinochoroidopathy. *Arch Ophthalmol* 1984;102:214-219.
73. Fardeau C, Herbort CP, Kullmann N, Quentel G, LeHoang P. Indocyanine green angiography in birdshot chorioretinopathy. *Ophthalmology* 1999;106:1928-1934.
74. Brucker AJ, Deglin EA, Bene C, Hoffman ME. Subretinal choroidal neovascularization in birdshot retinochoroidopathy. *Am J Ophthalmol* 1985;99:40-44.
75. Godel V, Baruch E, Lazar M. Late development of chorioretinal lesions in birdshot retinochoroidopathy. *Ann Ophthalmol* 1989;21:49-52.
76. Guex-Crosier Y, Herbort CP. Prolonged retinal arterio-venous circulation time by fluorescein but not by indocyanine green angiography in birdshot chorioretinopathy. *Ocul Immunol Inflamm* 1997;5:203-206.
77. Monnet D, Levinson RD, Holland GN, Haddad L, Yu F, Brézin AP. Longitudinal cohort study of patients with birdshot chorioretinopathy. III. Macular imaging at baseline. *Am J Ophthalmol* 2007;144:818-828.
78. Herbort CP, Probst K, Cimino L, Tran VT. Differential inflammatory involvement in retina and choroid in birdshot chorioretinopathy. *Klin Monbl Augenheilkd* 2004;221:351-356.
79. Schmitz-Valckenberg S, Holz FG, Bird AC, Spaide RF. Fundus autofluorescence imaging: review and perspectives. *Retina* 2008;28:385-409.

80. Koizumi H, Pozzoni MC, Spaide RF. Fundus autofluorescence in birdshot chorioretinopathy. *Ophthalmology* 2008;115:e15-e20.
81. Giuliari G, Hinkle DM, Foster CS. The spectrum of fundus autofluorescence findings in birdshot chorioretinopathy. *J Ophthalmol* 2009;2009:567693.
82. Gallagher MJ, Yilmaz T, Cervantes-Castañeda RA, Foster CS. The characteristic features of optical coherence tomography in posterior uveitis. *Br J Ophthalmol* 2007;91:1680-1685.
83. Kappel PJ, Monnet D, Yu F, Brezin AP, Levinson RD, Holland GN. Contrast sensitivity among patients with birdshot chorioretinopathy. *Am J Ophthalmol* 2009;147:351-356.
84. Birch DG, Williams PD, Callanan D, Wang R, Locke KG, Hood DC. Macular atrophy in birdshot retinochoroidopathy: an optical coherence tomography and multifocal electroretinography analysis. *Retina* 2010;30:930-937.
85. Forooghian F, Yeh S, Faia LJ, Nussenblatt RB. Uveitic foveal atrophy: clinical features and associations. *Arch Ophthalmol* 2009;127:179-186.
86. Forooghian F, Gulati N, Jabs DA. Restoration of retinal architecture following systemic immunosuppression in birdshot chorioretinopathy. *Ocul Immunol Inflamm* 2010;18:470-471.
87. Spaide RF. Enhanced depth imaging optical coherence tomography of retinal pigment epithelial detachment in age-related macular degeneration. *Am J Ophthalmol* 2009;147:644-652.
88. Kriechbaum K, Bolz M, Deak GG, Prager S, Scholda C, Schmidt-Erfurth U. High-resolution imaging of the human retina *in vivo* after scatter photocoagulation treatment using a semiautomated laser system. *Ophthalmology* 2010;117:545-551.
89. Keane PA, Allie M, Turner SJ, Southworth HS, Sadda SR, Murray PI, et al. Characterization of birdshot chorioretinopathy using extramacular enhanced depth optical coherence tomography. *JAMA Ophthalmol* 2013;131:341-350.
90. Birnbaum AD, Fawzi AA, Rademaker A, Goldstein DA. Correlation between clinical signs and optical coherence tomography with enhanced depth imaging findings in patients with birdshot chorioretinopathy. *JAMA Ophthalmol* 2014.

**How to cite this article:** Vitale AT. Birdshot Retinochoroidopathy. *J Ophthalmic Vis Res* 2014;9:350-61.

**Source of Support:** Nil. **Conflict of Interest:** None declared.