

Aim of the study: Determining the role of PET/CT imaging in the evaluation of treatment efficacy in primary mediastinal B-cell lymphoma (PMBCL).

Material and methods: Retrospective analysis of seven PMBCL patients, treated at the University Hospital in Krakow, with interim PET/CT after the third course of chemo-immunotherapy. The analysis was based on the calculation of exact tumour volume and metabolic activity, compared with initial values (directly after diagnosis).

Results: Patients (five females, two males, average age 26.2 years, range 18–40 years), in clinical stage IIBX at diagnosis, were treated with eight cycles of R-CHOP-14 regimen, with radiotherapy consolidation (7/7) and central nervous system prophylaxis (6/7). The observed decrease in tumour volume between the initial staging and the interim PET ranged 72–89%. The mean $\Delta\text{SUV}_{\text{max}}$ reduction between initial (when available) and interim PET was 87% (range 84–89%). In 3/7 cases in the interim PET/CT, the uptake of the tumour was higher than the liver (Deauville Criteria score 4–5), and in 4/7 it was lower than the liver but higher than mediastinal blood pool structures (score 3 according to Deauville Criteria). After a median follow-up of 58 months – OS and EFS is 100%.

Conclusions: The excellent clinical outcome in the study group corresponds with very good metabolic and volumetric response in the interim PET. The $\Delta\text{SUV}_{\text{max}}$ seems to be easier in implementation and has a more significant impact than other measurements.

Key words: lymphoma, large B-cell, diffuse/radionuclide imaging, tomography, X-ray computed mediastinal neoplasms/radiography.

Contemp Oncol (Pozn) 2016; 20 (4): 297–301
DOI: 10.5114/wo.2016.61849

Primary mediastinal B-cell lymphoma – metabolic and anatomical features in 18FDG-PET/CT and response to therapy

Anna Kocurek¹, Bogdan Małkowski², Agnieszka Giza¹, Wojciech Jurczak¹

¹Jagiellonian University Collegium Medicum, Krakow, Poland

²The Franciszek Łukaszczyk Oncology Centre, Bydgoszcz, Poland

*The authors had equal participation in the study design.

Introduction

Primary mediastinal B-cell lymphoma (PMBCL) is a rare neoplasm, which represents 2–3% of all cases of non-Hodgkin lymphoma. It usually affects young females, 20–40 years old, and has a relatively good prognosis with modern immune-chemotherapy regimens (over 90% five-year progression-free survival, based on results of patients treated at the Department of Haematology of the University Hospital in Krakow).

The higher PMBCL mortality rate, described in early publications, could have resulted from an inaccurate diagnosis (differential diagnosis with diffuse large B cell lymphoma (DLBCL) – with secondary mediastinal involvement [1, 2]) or inappropriate therapy. Although adding rituximab clearly increased response rates and overall survival [3], the role of dose intensity regimens, and consolidation radiotherapy has not yet been established (efficiency vs. adverse effects).

To allow an adequate comparison of different treatment protocols, it is crucial to determine the optimal response assessment, addressing the problem of residual mass – a common phenomenon at the end of therapy. 18 F-fluorodeoxyglucose (FDG) PET/CT allows assessment of both the morphology and biology of the tumour. It became a standard of care in staging and evaluation of treatment outcome in DLBCL patients [4, 5]. In PMBCL [6–11] PET/CT has been implemented using the standard response criteria for lymphoma [12]. Early response assessment in PET/CT performed after 2–4 cycles remains controversial. Initial results in DLBCL were highly optimistic [13, 14], but further studies were not coherent in their conclusions [15, 16]. Even fewer data are available on PMBCL [3, 17, 18].

Material and methods

A retrospective analysis of imaging studies was performed in seven sequential PMBCL patients treated at the Department of Haematology of the University Hospital in Krakow, whose interim PET/CT after the third course of chemoimmunotherapy was available.

Patients included in the analysis were treated with seven or eight cycles of R-CHOP regimen, repeated every 14 days, consolidated by IFRT (Involved-Field Radiation Therapy). Additionally, central nervous system involvement prevention was implemented: in five cases as intrathecal DepoCyt (4–8 doses), and in one as prophylactic cerebral irradiation.

The protocol included imaging studies at diagnosis (in four cases PET/CT, in three CT), an early response PET/CT assessment and response assessment four weeks after the completion of chemotherapy and three months after radiotherapy.

All PET/CT examinations were acquired with the same protocol in one centre. For the purpose of this study, images collected in the DICOM system were retrospectively analysed by an independent radiologist. The analysis of CT data included: volumetric measurements of the tumour (tumour volume = sum of surface areas of the lesion on the transverse sections multiplied by thickness of scans) and calculation of the SPD (the sum of the products of the largest transverse diameters of up to six changes) [19]. In the assessment of PET-CT we used the five-point scale, defined at the First Consensus Conference in Deauville 2009 [20], as recommended during the International Conference on Malignant Lymphomas Imaging Working Group (ICML recommendations) [12], based on comparison of standardised uptake value (SUV) of the lesion with reference SUV (mediastinal blood pool structures (MBPS) and liver uptake). In four patients we additionally calculated the $\Delta\text{SUV}_{\text{max}}$ – reduction in the maximum standardised uptake value at the most intense tumour in two subsequent examinations [21], according to the following formula:

$$\Delta\text{SUV}_{\text{max}}(\%) = 100 \times (\text{SUV}_{\text{max}}[\text{initial}] - \text{SUV}_{\text{max}}[\text{subsequent}]) / \text{SUV}_{\text{max}}[\text{initial}].$$

Results

Demographics: five women and two men. The median age at diagnosis was 28 (range 18 to 40) years. The median follow-up was 58 months (range 48 to 68 months), the progression-free survival (PFS) and the overall survival (OS) were both 100%.

The predominant manifestation at diagnosis was a tumour of the upper anterior mediastinum. In some cases, it extended to the adjacent regions (Fig. 1). Its largest transverse diameter varied from 8 to 14.7 cm (median 10.3 cm). Involvement of cervical or pericardial lymph nodes was confirmed in three and two patients, respectively. Involvement of extra-nodal sites was relatively frequent: pleural and pericardial effusions (in two and three patients, accordingly) and pulmonary nodules and lung infiltrations (two cases). In the study group nobody had infra-phrenic changes. The total volume of the involved masses ranged from 151 to 987 cm³ (median 427 cm³).

A significant decrease of tumour masses and volumes, as well as a reduction of the SUV_{max} , was observed in the course of the treatment. The change was most notable during the first cycles of immunochemotherapy (reduction of volume at the interim PET/CT ranged from 72 to 89%, compared to the initial volume of the tumour). This tendency continued in the following assessments, reaching from 23 to 65% one month after the completion of the first round of immunochemotherapy. A similar trend and comparable values were observed according to the SPD. The tumour volumes, SPD at different stages of the treatment, and their changes are summarised in Table 1 and Fig. 2. In the interim PET/CT the SUV_{max} of the lesion of every patient was above the uptake of the MBPS (mediastinal blood pool structures), with a similar population achieving four and three points according to the Deauville Criteria (three and four patients, respectively). Despite such differences in the FDG uptake, the $\Delta\text{SUV}_{\text{max}}$ between initial and interim PET were very high and surprisingly coherent (84–89%, median 88%).

In the studied group, there was only one person who had SUV_{max} of the tumour remnants lower than the MBPS after completion of the therapy (after chemotherapy or – if the previous examination was unavailable – at an appropriate time after radiotherapy). Among the four other patients, for whom PET/CT was performed, in one the SUV_{max} of the lesions was higher than SUV_{max} of the liver, while for the three other patients this value was within the interval between SUV_{max} of the liver and that of the MBPS. The changes in SUV_{max} according to the Deauville Criteria are presented in Table 2.

Discussion

According to histopathological and genomic findings, primary mediastinal B-cell lymphoma is considered to derive from a small population of thymus B cells [2]. This disease has a unique molecular and clinical characteristic, distinguishing it from DLBCL, more similar to NSCHL (Nodular Sclerosis classical Hodgkin Lymphoma). Both tumours are most common in young adults, and on diagnosis present as localised bulky tumours of the anterior

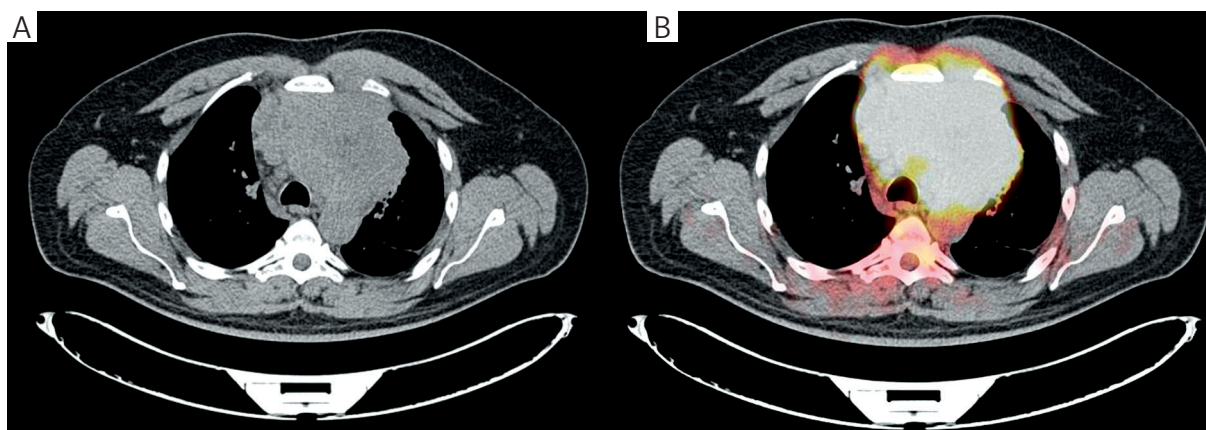


Fig. 1. CE-CT and PET/CT scan of a patient with PMBCL before the treatment. A bulky mediastinal mass, with extension into the left lung, is visible

Table 1. Tumour volumes and SPD of the tumours at different stages of the treatment, and their relative changes

	Staging (7 patients)	Early assessment (7 patients)	After chemotherapy (5 patients)	After IFRT (6 patients) Mean change compared with the interim PET/CT
Mean volume of tumour tissue (cm ³) ± SD (mean change compared with the previous study)	505.5 ±288.7	90.7 ±47.2 (−80.6%)	52.1 ±27.2 (−39.4%)	45.2 ±40.7 (−26.2%)
Median (cm ³)	427.0	74.5	52.5	33.7
Range (cm ³)	151.3–947.3	37.4–161	16.2–91.5	16.0–126
Mean SPD (cm ²) ± SD (mean change compared with the previous study)	101.5 ±45.2	29 ±20.5 (−88.6%)	16.3 ±10.8 (−36.2%)	18.1 ±17.3 (−26.7%)
Median (cm ²)	85.5	20.2	11.3	13.4
Range (cm ²)	56.7–181.9	10.6–69.5	5.4–29.4	4.8–50.4

Table 2. SUV_{max} of the lesions, according to the Deauville Criteria

	Staging	Early assessment	After chemotherapy	After IFRT
SUV _{max}				
1. no uptake	0	0	0	0
2. below the MBPS	0	0	1	0
3. between the MBPS and the liver	0	4	0	1
4. moderately more the liver	0	3	2	1
5. markedly increased uptake	4	0	0	0
(number of patients who underwent PET / CT)	(4)	(7)	(3)	(2)

mediastinum. In histopathology, fibrosis is a common finding. Moreover, on the PMBCL cells as well on the Hodgkin Reed-Stenberg (HRS) cells surface Ig are often. Both tumours are characterised by similar genomic abnormalities, including gains of chromosome 2p and 9p. In addition, they were described as rare cases of composite or sequential NScHL and PMBCL and “mediastinal grey-zone lymphomas”, with features between NScHL and PMBCL.

At the moment of diagnosis, primary mediastinal B-cell lymphoma manifests as a rapidly progressive tumour in the anterior mediastinum, which at the initial staging often measures more than 10 cm in diameter and can directly invade the lungs, thorax, pleura, or pericardium. In a short time, it results in symptoms of narrowing of the airways or great vessels, which may lead to upper vena cava syndrome. Despite the local invasiveness, infiltration of distant organs at the initial staging is rare. But at the time of recurrence, the involvement of extranodal organs, such as the liver, kidneys, or central nervous system [2, 22] is not uncommon.

CHOP-R-14 based regimens of chemotherapy, complemented by prophylaxis of the central nervous system involvement and involved field radiotherapy (standard treatment in the Department of Haematology of the University Hospital in Krakow), have shown good efficacy with an acceptable toxicity profile. The superiority of the CHOP-R regimens over the CHOP regimens is highly supported and widely accepted [23, 24]. However, mediastinal irradiation carries in survivors a high risk of late complications, of which secondary malignancies and heart failure are particularly dangerous. Conversely, the excellent results

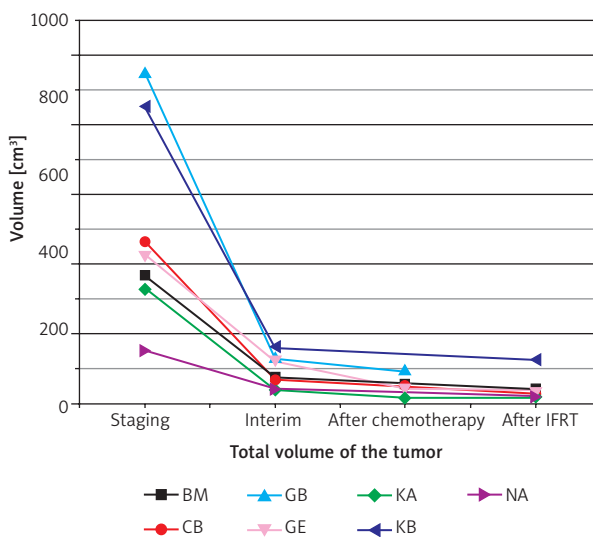


Fig. 2. Tumour volume changes in the course of the therapy

obtained in a GELA (Groupe d’Etude des Lymphomes de l’Adulte) study with different regimens but without irradiation [25] put the necessity of such consolidation therapy into question. Nowadays, in the era of rituximab, the application of CHOP-like schemes of chemotherapy is better documented. For example, Moskowitz *et al.* [17] evaluated the dose-dense CHOP-R/ICE consolidation chemotherapy program, obtaining in three years of observation time 78% progression-free survival, and they suggested avoiding radiotherapy and lack of benefits from the interim PET/CT.

In contrast, other authors [7–10] supported omitting the radiotherapy only in the group of good responders to the primary R-CHOP treatment.

Moreover, clinical decisions are complicated by the fact that in this type of lymphoma the residual masses usually persist even after successful treatment. There have been attempts to determine the prognosis on the basis of their volume: in the previous century Smith *et al.* [26] demonstrated that a tumour volume greater than 100 cm³ after completion of treatment is a statistically significant risk factor for recurrence. The same study showed that other information from the CT scans (obtained at the presentation and after completion of the first-line treatment) was not as important. In our study group, one patient had a mediastinal mass larger than 100 cm³ after radiotherapy, without any signs of recurrence.

The next step in assessing the response to therapy was evaluating the biology of the cells in residual masses, after completion of the therapy. Previous studies [27, 28] have shown very high usefulness of PET performed with 18F-fluorodeoxyglucose. The idea of this examination is to reveal an increased glucose metabolism in vivid lymphoma cells. Briefly, according to ICML recommendations [12], the most intense uptake in a site of initial disease, if present, should be scored according to the Deauville Criteria, taking into consideration the radioactivity of the mediastinal blood pool and the liver. Unfortunately, there is a high rate of false positive results in the case of mediastinal tumours relating to, *inter alia*, thymic hyperplasia in young adults after chemotherapy or inflammatory changes. According to the Lugano classification [4] and ICML recommendations [12], in the studied group there were as many as three patients with positive PET, considered as treatment failure after completion of the therapy (from five, who had undergone PET/CT in this moment), and there was 100% PFS during the observation. Thereby, results from the PET examination alone do not allow determining the outcome and taking decision about the therapy. Thus, a histological confirmation of the relapse in this type of lymphoma is often needed.

The prognostic value of interim PET in DLBCL has been assessed in earlier studies [15, 16, 29]. However, strong evidence of its role and consistent rules of interpretation, are not available. Indeed, it is a direct indicator of individual response to therapy, in opposition to pre-therapeutic, population-based indices, such as the International Prognostic Index. On the other hand, the high rate of false positive results caused by inflammatory processes, increased in the lesion by immunotherapy, and the effect of granulocyte colony-stimulating factor [15, 29], are severe drawbacks. Moreover, the usefulness of interim PET in PMBCL – a specific subtype of DLBCL – has been evaluated only in small series of patients [3, 17, 18] treated with different regimes.

There are two possible approaches to determine the individual response to therapy by interim PET/CT in DLBCL. The first one, highly subjective, is based on visual assessment. The second one is a quantitative assessment, using SUV_{max} or SUV_{mean}. The SUV_{mean} method is more sensitive, but with large inter-observer differences in the drawing of

the VOI. Therefore, in our study, we adopted the approach based on SUV_{max} assessment.

Only in three cases out of the studied cohort, were the Deauville Criteria met, i.e. the SUV_{max} of the tumour in the interim PET/CT was lower than the SUV_{max} of the liver in the same examination. In the remaining four cases, the SUV_{max} of the tumour in the interim PET was higher than that of the liver. More promising results were obtained from the comparison between the initial staging and the interim PET/CT. The changes in tumour volume from the beginning of the treatment were absolutely amazing – ranging from 72% to 89%. Measurements, according to the change in SPD – a value easier for implementation than volumetric measurements – were also very high, but with greater variability: 59–86%.

Our findings are in line with recently growing recognition of the importance of volume-based metabolic response in DLBCL [30]. Ceriani *et al.* [31], who addressed the PMBCL as a distinct subtype of the disease, checked the utility of the metabolic tumour volume (MTV) – defined as the best fit between “metabolic edges” and anatomical boundaries – and the total lesion glycolysis (TLG), calculated as a product of SUV_{mean} and MTV. The authors showed that these two measurements in the baseline PET/CT were associated with the progression-free survival (PFS) and overall survival (OS). In contrast they did not find such correlation with the third examined parameter – the SUV_{max} of the lesion.

Very promising data was obtained using Δ SUV_{max}. In our small study group, the obtained results were coherent and very high (84–89%). This type of measurement has recently been implemented by some researchers [15, 21, 29, 32, 33] and has shown a high prognostic value, although consistent rules of implementation still need to be determined [12].

In conclusion, the results from both rounds of the PET-CT examination seem to be complementary and important in the management of primary mediastinal B-cell lymphoma. In the study group data from a single examination (size of the lesion, its volume, SUV_{max}) were not as important as the change in time. The relative change in SUV_{max}, Δ SUV_{max}, is easiest in implementation among the analysed measures, and gives the most coherent results. The usefulness of this approach may be very specific for PMBCL because the behaviour of this neoplasm is not typical. Thus, this method of assessment needs further evaluation in larger study groups, especially in prospective clinical trials.

The authors declare no conflict of interest.

References

1. Martelli M, Ferreri AJM, Johnson P. Primary mediastinal large B-cell lymphoma. *Crit Rev Oncol Hematol* 2008; 68: 256-63.
2. Savage KJ. Primary Mediastinal large B-cell lymphoma. *Oncologist* 2006; 11: 488-95.
3. Avigdor A, Sirotkin T, Kedmi M, et al. The impact of R-VACOP-B and interim FDG-PET/CT on outcome in primary mediastinal large B cell lymphoma. *Ann Hematol* 2014; 93: 1297-304.

4. Cheson BD, Fisher RI, Barrington SF, et al. Recommendations for initial evaluation, staging, and response assessment of hodgkin and non-hodgkin lymphoma: The Lugano classification. *J Clin Oncol* 2014; 32: 3059-67.
5. Vassilakopoulos TP, Prassopoulos V, Rondogianni P, Chatziioannou S, Konstantopoulos K, Angelopoulou MK. Role of FDG-PET/CT in staging and first-line treatment of Hodgkin and aggressive B-cell lymphomas. *Memo - Mag Eur Med Oncol* 2015; 8: 105-14.
6. Martelli M, Ceriani L, Zucca E et al. [18F]Fluorodeoxyglucose Positron Emission Tomography Predicts Survival After Chemoimmunotherapy for Primary Mediastinal Large B-Cell Lymphoma: Results of the International Extranodal Lymphoma Study Group IELSG-26 Study. *J Clin Oncol* 2014; 32: 1769-75.
7. Vassilakopoulos TP, Pangalis GA, Chatziioannou S, et al. PET/CT in primary mediastinal large B-cell lymphoma responding to rituximab-CHOP: An analysis of 106 patients regarding prognostic significance and implications for subsequent radiotherapy. *Leukemia* 2016; 30: 238-60.
8. Savage KJ, Yenson PR, Shenkier T, et al. The outcome of primary mediastinal large b-cell lymphoma (PMBCL) in the R-CHOP treatment era. *Blood ASH Annu Meet Abstr* 2012; 120: 303.
9. Zinzani PL, Broccoli A, Casadei B, et al. The role of rituximab and positron emission tomography in the treatment of primary mediastinal large B-cell lymphoma: experience on 74 patients. *Hematol Oncol* 2015; 33: 145-50.
10. Filippi AR, Piva C, Giunta F, et al. Radiation therapy in primary mediastinal B-cell lymphoma with positron emission tomography positivity after rituximab chemotherapy. *Int J Radiat Oncol Biol Phys* 2013; 87: 311-6.
11. Pinnix CC, Dabaja B, Ahmed MA, et al. Single-institution experience in the treatment of primary mediastinal B cell lymphoma treated with immunochemotherapy in the setting of response assessment by 18fluorodeoxyglucose positron emission tomography. *Int J Radiat Oncol Biol Phys* 2015; 92: 113-21.
12. Barrington SF, Mikhaeel NG, Kostakoglu L, et al. Role of imaging in the staging and response assessment of lymphoma: Consensus of the international conference on malignant lymphomas imaging working group. *J Clin Oncol* 2014; 32: 3048-58.
13. Jerusalem G, Beguin Y, Fassotte MF, Najjar F, Paulus P, Rigo P, Fillet G. Persistent tumor 18F-FDG uptake after a few cycles of polychemotherapy is predictive of treatment failure in non-Hodgkin's lymphoma. *Haematologica* 2000; 85: 613-8.
14. Spaepen K, Stroobants S, Dupont P, et al. Early restaging positron emission tomography with (18)F-fluorodeoxyglucose predicts outcome in patients with aggressive non-Hodgkin's lymphoma. *Ann Oncol* 2002; 13: 1356-63.
15. Pregno P, Chiappella A, Bello M, et al. Interim 18-FDG-PET/CT failed to predict the outcome in diffuse large B-cell lymphoma patients treated at the diagnosis with rituximab-CHOP. *Blood* 2012; 119: 2066-73.
16. Cheson B. The case against heavy PETing. *J Clin Oncol* 2009; 27: 1742-3.
17. Moskowitz C, Hamlin PA, Maragulia J, et al. Sequential Dose-Dense RCHOP Followed by ICE Consolidation (MSKCC protocol 01-142) without Radiotherapy for Patients with Primary Mediastinal Large B Cell Lymphoma. *Blood ASH Annu Meet Abstr* 2010; 116: 420.
18. Dabrowska-Iwanicka A, Walewski JA. Primary mediastinal large B-cell lymphoma. *Curr Hematol Malig Rep* 2014; 9: 273-83.
19. Cheson BD, Pfistner B, Juweid ME, et al. Revised response criteria for malignant lymphoma. *J Clin Oncol* 2007; 25: 579-86.
20. Meignan M, Gallamini A, Meignan M, et al. Report on the First International Workshop on Interim-PET-Scan in Lymphoma. *Leuk Lymphoma* 2009; 50: 1257-60.
21. Itti E, Lin C, Dupuis J, et al. Prognostic value of interim 18F-FDG PET in patients with diffuse large B-Cell lymphoma: SUV-based assessment at 4 cycles of chemotherapy. *J Nucl Med* 2009; 50: 527-33.
22. Banks P, Warnke R. Mediastinal (thymic) large B-cell lymphoma. *World Heal. Organ. Classif. Tumours Pathol. Genet. Tumours Hematop. Lymphoid Tissues*. Jaffe ES, Harris NL, Stein H, Vardiman JW. IARC, Lyon 2001; 175-8.
23. Rieger M, Österborg A, Pettengell R, et al. Primary mediastinal B-cell lymphoma treated with CHOP-like chemotherapy with or without rituximab: Results of the Mabthera International Trial Group study. *Ann Oncol* 2011; 22: 664-70.
24. Vassilakopoulos TP, Gerassimos PA, Kastigiannis A, et al. Rituximab, cyclophosphamide, doxorubicin, vincristine and prednisone with or without radiotherapy in primary mediastinal large B-cell lymphoma: the emerging standard of care. *Oncologist* 2012; 17: 239-49.
25. Cazalts-Hatem D, Lepage E, Brice P, et al. Primary mediastinal large B-cell lymphoma. A clinicopathological study of 141 cases compared with 916 nonmediastinal large B-cell lymphomas, a GELA ("Groupe d'Etude des Lymphomes de l'Adulte") study. *Am J Surg Pathol* 1996; 20:877-88.
26. Smith D, Shaffer K, Kirn D, Canellos GP, Mauch PM, Shulman LN. Mediastinal large cell lymphoma: prognostic significance of CT findings at presentation and after treatment. *Oncology* 1998; 55: 284-8.
27. Zinzani PL, Fanti S, Battista G, et al. Predictive role of positron emission tomography (PET) in the outcome of lymphoma patients. *Br J Cancer* 2004; 91: 850-4.
28. Jerusalem G, Beguin Y, Fassotte MF, et al. Whole-Body Positron Emission Tomography Using 18 F-Fluorodeoxyglucose for Post-treatment Evaluation in Hodgkin's Disease and Non-Hodgkin's Lymphoma Has Higher Diagnostic and Prognostic Value Than Classical Computed Tomography Scan Imaging. *Blood* 1999; 94: 429-34.
29. Ishii Y, Tomita N, Tateishi U, et al. The rate of reduction in the maximum standardized uptake value from the initial to the post-R-CHOP therapy in positron emission tomography scan predicts disease progression in diffuse large B cell lymphoma patients. *Med Oncol* 2014; 31: 880.
30. Kim TM, Paeng JC, Chun IK, et al. Total lesion glycolysis in positron emission tomography is a better predictor of outcome than the International Prognostic Index for patients with diffuse large B cell lymphoma. *Cancer* 2013; 119: 1195-202.
31. Ceriani L, Martelli M, Zinzani PL, et al. Utility of baseline 18FDG-PET/CT functional parameters in defining prognosis of primary mediastinal (thymic) large B-cell lymphoma. *Blood* 2015; 126: 950-7.
32. Lin C, Itti E, Haioun C, et al. Early 18F-FDG PET for prediction of prognosis in patients with diffuse large B-cell lymphoma: SUV-based assessment versus visual analysis. *J Nucl Med* 2007; 48: 1626-32.
33. Fuertes S, Setoain X, Lopez-Guillermo A, Carrasco JL, Rodríguez S, Rovira J, Pons F, et al. Interim FDG PET/CT as a prognostic factor in diffuse large B-cell lymphoma. *Eur J Nucl Med Mol Imaging* 2013; 40: 496-504.

Address for correspondence

Anna Kocurek

Department of Medical Education
Jagiellonian University Collegium Medicum
św. Łazarza 16
31-530 Krakow, Poland
e-mail: anna.kocurek@gmail.com

Submitted: 25.01.2015

Accepted: 22.06.2016