

Images in Nephrology
(Section Editor: G. H. Neild)

Foamy urine in nephrotic syndrome

Márcio Dantas¹, Gyl E. Barros Silva² and Miguel Moysés-Neto¹

¹Division of Nephrology, Department of Internal Medicine, University of São Paulo, Ribeirão Preto, SP, Brazil and ²Department of Pathology, Faculty of Medicine of Ribeirão Preto, University of São Paulo, Ribeirão Preto, SP, Brazil

Correspondence and offprint requests to: Márcio Dantas; E-mail: mdantas@fmrp.usp.br

Keywords: foamy urine; nephrotic syndrome; proteinuria

Several days after unprotected sex, a 21-year-old male was referred with generalized edema and enlarged painless lymph nodes. Urinalysis showed specific gravity 1036, proteinuria 4+, nitrites negative, urine microscopy with 4–6 erythrocytes/high power field (HPF), 8–10 leucocytes/HPF and the presence of hyaline and granular casts. Urine culture was negative. Proteinuria was 4.6 g/24 h, serum creatinine 88 $\mu\text{mol/L}$ (1.0 mg/dL) and albumin 9 g/L (0.9 g/dL). He denied foamy urine, but was astonished when he saw his foamy urine after urinating directly into a beaker (Fig. 1A). The VDRL test was reactive (1/64) and the *Treponema pallidum* haemagglutination assay was positive. A renal biopsy diagnosed membranous nephropathy that was assumed to be secondary to syphilis. He was treated with penicillin. Six weeks later the edema,

enlarged lymph nodes and foamy urine (Fig. 1C) had disappeared and proteinuria was 246 mg/24 h.

Protein in urine makes the urine foamy as it lowers the surface tension. Longer-term foamy urine (Fig. 1A and B) is usually caused by proteinuria and the onset may be recalled during anamnesis. However, some patients, like the one in the present case, do not recognize it. It is more easily identified by patients that have previous experience with nephrotic syndrome. Observing foamy urine may help date the onset of proteinuria.

Conflict of interest statement. None declared.

Received for publication: 17.12.12; *Accepted in revised form:* 7.2.13

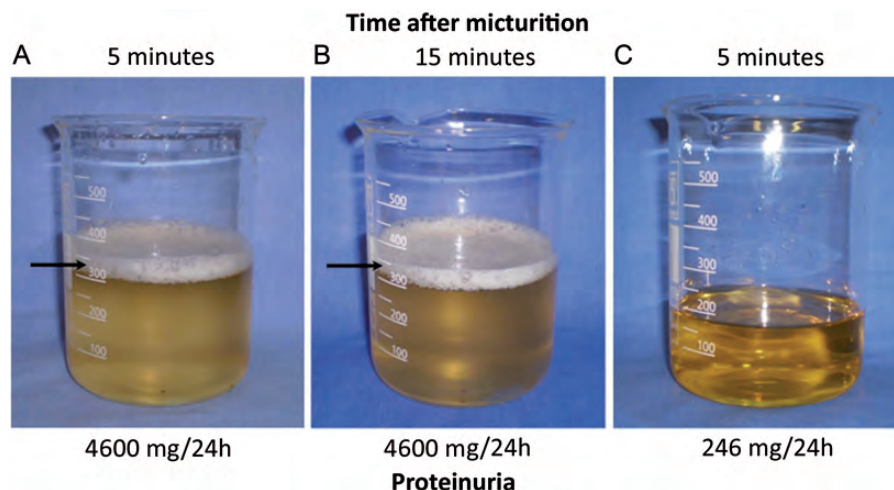


Figure 1. Prolonged foamy urine 5 minutes (A) and 15 minutes (B) after urinating directly into a beaker. Normal pattern (not foamy) urine after remission of the proteinuria (C).