

# Acute Respiratory Distress Syndrome after *Viscum album* Pleurodesis for Primary Spontaneous Pneumothorax

Dongsub Noh, M.D., Joon Suk Park, M.D., Doo Yun Lee, M.D., Ph.D.

Department of Thoracic and Cardiovascular Surgery, CHA Bundang Medical Center, CHA University

A 52-year-old male patient who underwent multiple wedge resections experienced postoperative acute respiratory distress syndrome in both lungs after *Viscum album* pleurodesis. Despite initial rapid deterioration in clinical condition and rapid progression of bilateral lung infiltration, he exhibited a relatively smooth clinical recovery with marked response to glucocorticoid treatment. Our case report suggests that care must be taken to guard against the development of acute respiratory complications in the use of *Viscum album* for pleurodesis. However, in view of the clinically benign course, initial aggressive management of complications can prevent suffering and sequelae.

**Key words:** 1. Pneumothorax  
2. Pleurodesis  
3. *Viscum album*  
4. Acute respiratory distress syndrome

## Case report

A 52-year-old male, 30-pack-year current smoker, visited the emergency room complaining of severe chest pain and dyspnea. A chest X-ray showed a large amount of pneumothorax in the right pleural cavity (Fig. 1A). Closed thoracostomy was performed to relieve symptoms and to prevent tension pneumothorax. Initial computed tomography showed diffuse lung emphysema, sequelae of tuberculosis in the right lung, and multiple bullae in the right upper and lower lobes. Surgery was required because of continuous air leakage through the chest drain for 4 days after a closed thoracostomy.

Multiple wedge resections were performed utilizing video-assisted thoracoscopic surgery. After multiple wedge resections of the right upper and lower lobes, the resection sites were covered with an absorbable

polyglycolic acid sheet (Neoveil; Gunze Ltd., Kyoto, Japan) and fibrin glue. A mixture of 40 mg of *Viscum album* extract (European Mistletoe, ABNOBA viscum F; ABNOBA Helmittel GmbH, Pforzheim, Germany) with 50 mL of normal saline was administered into the pleural space by needle instillation upon the visceral and parietal pleura. The total procedure time was 40 minutes. No air leakage was observed through the chest drain postoperatively. Until the second postoperative day, the recovery was uneventful, with both lung fields clear on chest X-ray (Fig. 1B).

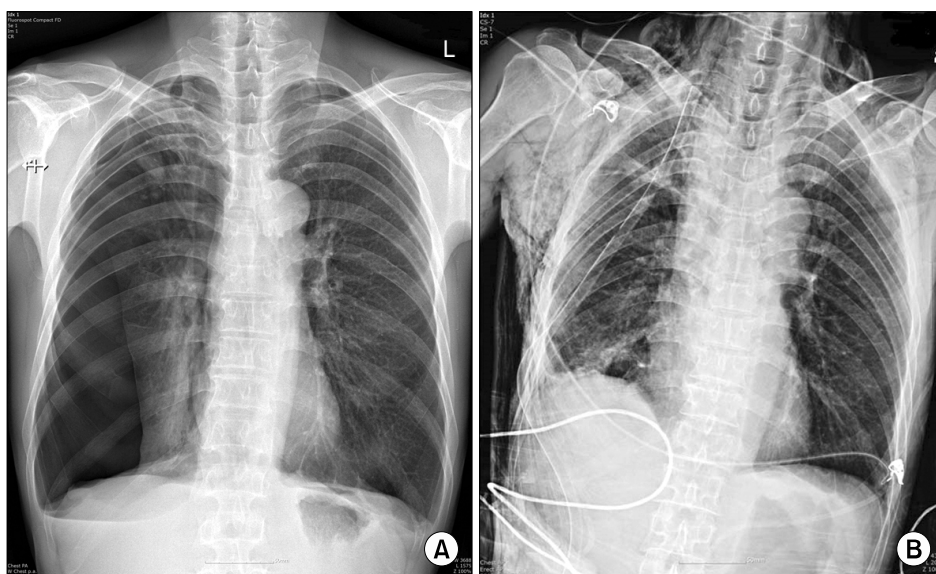
On the third postoperative day, the patient started to complain of worsening dyspnea even at rest, and a follow-up chest X-ray showed loculated right pleural effusion and bilateral lung infiltration. Arterial blood gas analysis under 5 L of oxygen inhalation showed that arterial oxygen pressure (PaO<sub>2</sub>) was 42.0 mm Hg and oxygen saturation was 78.9%. After

Received: February 15, 2016, Revised: May 3, 2016, Accepted: June 23, 2016, Published online: February 5, 2017

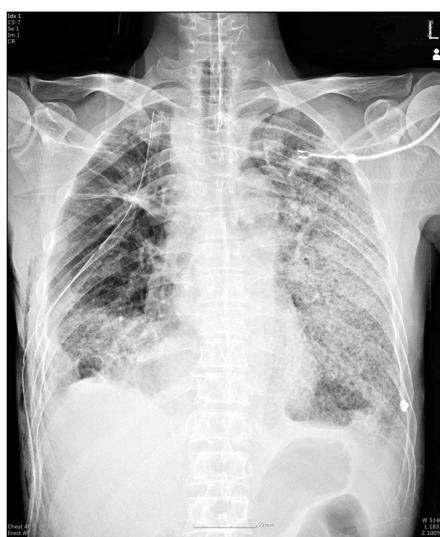
Corresponding author: Doo Yun Lee, Department of Thoracic and Cardiovascular Surgery, CHA Bundang Medical Center, CHA University, 59 Yatap-ro, Bundang-gu, Seongnam 13496, Korea  
(Tel) 82-31-780-5850 (Fax) 82-31-780-5857 (E-mail) [dylee4831@naver.com](mailto:dylee4831@naver.com)

© The Korean Society for Thoracic and Cardiovascular Surgery. 2017. All right reserved.

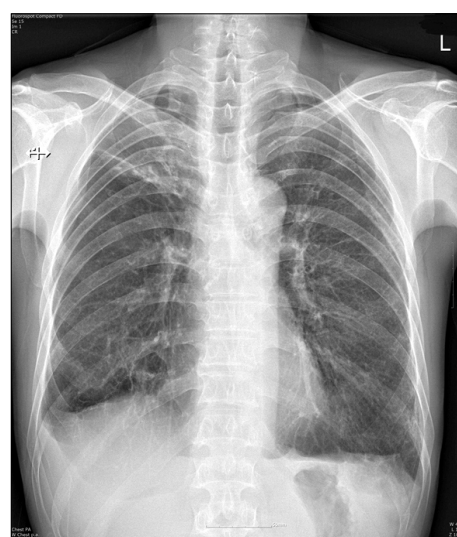
© This is an open access article distributed under the terms of the Creative Commons Attribution Non-Commercial License (<http://creativecommons.org/licenses/by-nc/4.0>) which permits unrestricted non-commercial use, distribution, and reproduction in any medium, provided the original work is properly cited.



**Fig. 1.** (A) A preoperative chest X-ray showed a large amount of right pneumothorax. (B) An immediate postoperative X-ray showed that both lung fields were clear.



**Fig. 2.** A follow-up chest X-ray on the third postoperative day showed loculated right pleural effusion and progressive lung infiltration that involved both lung fields.



**Fig. 3.** A chest X-ray on the 16th postoperative day showed no notable sequelae. The pulmonary infiltration rapidly resolved after the administration of glucocorticoids.

intubation and mechanical ventilator support, the follow-up arterial blood gas analysis showed a  $\text{PaO}_2$  of 66.9 mm Hg under with a fraction of inspired oxygen of 60%. In addition, the follow-up complete blood cell count showed a white blood cell count of  $10,940/\text{mm}^3$ , a neutrophil percentage of 88.0%, and a lymphocyte percentage of 10.0%. C-reactive peptide was elevated, at 18.84 mg/dL. Bronchoscopy indicated that bronchial secretion was minimally purulent, and there were no abnormal findings suggesting the presence

of bronchitis or pneumonia (Fig. 2). Based on these findings, the patient was diagnosed with acute respiratory distress syndrome (ARDS) resulting from insult and an immunologic response to *Viscum album*. Methylprednisolone (50 mg/day) was administered starting on the fourth postoperative day. Though the initial signs suggested the development of ARDS, the clinical course after mechanical ventilator support was quite smooth, with good response to glucocorticoid therapy. The lung infiltration on the chest X-ray

rapidly resolved after 3 days of steroid administration. The patient was discharged in good general condition on the 16th postoperative day (Fig. 3). A follow-up chest X-ray 1 month after discharge showed no pleural effusion and no abnormal lung infiltration.

## Discussion

Many therapeutic options have been used to treat uncontrolled air leaks from the lung or pleural effusion. Among these, chemical pleurodesis using sclerosing agents, such as tetracycline, erythromycin, hydrophilic fumed silica, and talc powder, is one of the most important treatment modalities. Irritation of the pleura by instilled chemical agents promotes the sealing of the visceral pleural defect and prevents fluid accumulation [1]. However, chemical pleurodesis is also associated with many complications, such as high fever, severe chest wall pain, fibrothorax, empyema thoracis, and acute respiratory failure. ARDS is the most serious respiratory complication associated with chemical pleurodesis. It is believed that transpleural absorption and intrapulmonary deposition of sclerosing agents occur via lymphatic stomata in the parietal pleura, resulting in the development of ARDS. The instilled drugs induce diffuse inflammation, pleural coagulation, fibrinolytic imbalance, formation of fibrin adhesions, and recruitment and subsequent proliferation of fibroblasts and collagen production in the pleural space [1]. Several new chemical agents are being investigated for their efficacy as pleurodesis agents with fewer complications, and *Viscum album* extract is one of the most promising. ABNOBA viscum F is an extract of *Viscum album* (European mistletoe), which grows on trees of the genus *Fraxinus*. This extract is one of the most frequently prescribed medications for the complementary treatment of cancer patients in a number of European countries. It is known to stimulate the immune system, thereby enhancing quality of life and alleviating the side effects of chemotherapy and radiotherapy, which may improve survival [2,3]. In addition, *Viscum album* instilled into the pleural cavity can induce diffuse inflammation and pleural coagulation/fibrinolytic imbalance, causing the formation of fibrin adhesions, recruitment and subsequent proliferation of fibroblast, and collagen production in the pleural space. These reactions irritate the pleural sur-

face, thus promoting the sealing of pleural defects and preventing fluid accumulation [1]. Thus, *Viscum album* is used for chemical pleurodesis of malignant pleural effusion. Complications of *Viscum album* pleurodesis have been reported and are mostly minor, including transient pleural effusion, a mild burning sensation, and mild fever episodes; there have been no reports of serious complications. *Viscum alum* can also serve as an effective agent for chemical pleurodesis in the treatment of congenital chylothorax and pneumothorax with continuous air leak [4,5]. Cho et al. [6] reported a case of *Viscum album*-related ipsilateral acute pneumonitis after wedge resection for pneumothorax, and stated that it was self-limiting and had a benign clinical course.

However, in our case, the patient complained of progressive dyspnea with chest pain 2 days after wedge resection and chemical pleurodesis with *Viscum album*. The follow-up chest X-ray showed loculated pleural effusion and bilateral lung infiltration. The blood gas analysis result and chest X-ray findings met the criteria of ARDS. The materials used in surgery, such as Neoveil and fibrin glue, are unlikely to be related to the development of ARDS, and we could not find any report of such an association. In addition, the intraoperative course and postoperative course were similar to that of any other routine wedge resection, and otherwise uneventful. Furthermore, the pathophysiology of ARDS is thought to be related to immune reaction, which is the modality of action for *Viscum album* as a pleurodesis and antitumor agent. Therefore, we assumed that the immune response to the *Viscum album* extract was the cause of this episode of ARDS. This is the first documented case of *Viscum album*-related ARDS, to our knowledge. Respiratory deterioration was acute and progressive, which required placing the patient under intubation and mechanical ventilation. Fortunately, the response to steroid therapy was almost instantaneous and the patient showed almost full recovery without any notable sequelae or relapse after scheduled tapering down of the steroid.

Based on our experience, even though *Viscum album* pleurodesis is considered to be a generally safe and effective procedure without serious complications, patients must be carefully monitored for signs of acute respiratory failure, which might be serious if appropriate treatment is not applied in time. In addi-

tion, the pathophysiology of ARDS due to the immunologic response to *Viscum album* extract must be investigated by scientific research, including animal studies.

### Conflict of interest

No potential conflict of interest relevant to this article was reported.

### References

1. Sonoda A, Jeudy J, White CS, et al. *Pleurodesis: indications and radiologic appearance*. Jpn J Radiol 2015;33:241-5.
2. Bock PR, Friedel WE, Hanisch J, Karasmann M, Schneider B. *Efficacy and safety of long-term complementary treatment with standardized European mistletoe extract (*Viscum album* L.) in addition to the conventional adjuvant oncologic therapy in patients with primary non-metastasized mammary carcinoma: results of a multi-center, comparative, epidemiological cohort study in Germany and Switzerland*. Arzneimittelforschung 2004;54:456-66.
3. Horneber MA, Bueschel G, Huber R, Linde K, Rostock M. *Mistletoe therapy in oncology*. Cochrane Database Syst Rev 2008;(2):CD003297.
4. Stumpf C, Bussing A. *Stimulation of antitumour immunity by intrapleural instillation of a *Viscum album* L. extract*. Anticancer Drugs 1997;8 Suppl 1:S23-6.
5. Cho HJ, Na KJ, Kim DW, Choi YE, Ma JS, Jeong IS. *Chemical pleurodesis using a *Viscum album* extract in infants with congenital chylothorax*. Eur J Pediatr 2014;173:823-6.
6. Cho SJ, Kim SW, Chang JW. *Acute pneumonitis consequent on pleurodesis with *Viscum album* extract: severe chest images but benign clinical course*. Multidiscip Respir Med 2014;9:61.