



REVIEW ARTICLE

Design and Validation of a Smile-Necklace Plate for Treating Inferior Patellar Pole Avulsion Fractures: A Review and Hypothesis

Wanbo Zhu, MD^{1,2†} , Lei Xu, MD^{2†}, Kai Xie, MD², Xinyuan Li, MD³, Xianlong Zhang, MD¹, Shiyuan Fang, MD², Jiazhao Yang, MD² 

¹Department of Orthopaedics, Shanghai Jiao Tong University, Affiliated Sixth People's Hospital and ³Shanghai Medical college, Fudan university, Shanghai and ²Department of Orthopaedics, The First Affiliated Hospital of University of Science and Technology of China, Hefei, China

The patella's inferior pole transmits force generated by contraction of the quadriceps muscle to the tibial tuberosity through the attached patellar ligament, thus completing knee extension. Therefore, fractures of the patella's inferior pole disrupt the coherence of mechanical transmission in the lower extremities. There appears to be no consensus among trauma centers regarding the treatment of infrapatellar pole fractures, primarily because there is no consistent design or application of internal fixation for this type of fracture. We designed a new internal implant similar to the smile necklace based on our previous study. This smile-necklace plate (SNP) has the advantage of both plate fixation and tension-band wiring fixation, permitting early rehabilitation, especially in osteoporotic comminuted infrapatellar pole fractures. Finite element analysis helped verify the biomechanical advantages of the SNP in comparison with existing studies. Hence, this novel implant is a promising treatment option for inferior pole patellar fractures.

Key words: Biomechanics; Inferior patellar pole avulsion fracture; Review; Smile-necklace plate

Introduction

Patellar fractures account for approximately 1% of all fractures, and inferior patellar pole avulsion fractures account for 9.3%–22.4% of patellar fractures requiring surgical treatment.^{1,2} The patella's inferior pole is a cancellous bone with no cartilage covering its surface and is not involved in the composition of the patellofemoral joint. It is surrounded by the patellar ligament and the infrapatellar fat pad, and the blood vessels in the infrapatellar fat pad flow from the patella's inferior pole and nourish the patella upward from the vascular pores on the surface. The patella's inferior pole is the attachment point of the patellar tendon, and stress concentration often results in the comminution of distal pole fragments during injury.^{3,4} Therefore, the treatment of inferior patellar pole fractures has its particularity in reduction and fixation and is directly related to the recovery

of knee function. The ideal type of internal fixation provides stable reduction without additional immobilization, thus allowing for early rehabilitation.⁵ There has not yet been a single identified type of internal fixation that is sufficiently accepted for wide use, and various studies on new internal fixation methods are published every year. Thus, treating inferior patellar pole fractures is challenging for all trauma and sports medicine surgeons, and the lack of a standardized treatment plan prevents patients from receiving uniform, high-quality surgical care at all trauma centers, especially in less-developed areas.

Our previous study combined the conventional micro-plate and wire tension-band (WTB) techniques to surgically treat inferior patellar pole fractures,⁶ and found that it led to early weight-bearing rehabilitation and good prognoses, demonstrating the advantages of this combined technique.

Address for correspondence Xianlong Zhang, MD, Department of Orthopaedics, Shanghai Jiao Tong University, Affiliated Sixth People's Hospital, Shanghai, China. Email: dr_zhangxianlong@sjtu.edu.cn; Shiyuan Fang, MD and Jiazhao Yang, MD, Department of Orthopaedics, The First Affiliated Hospital of University of Science and Technology of China, Hefei, China. Email: fangshiyuan2008@126.com and yangjiazhao@ustc.edu.cn

[†]Wanbo Zhu and Lei Xu contributed equally to this work

Received 2 July 2022; accepted 10 August 2022



The plate's increased surface area, which was used to hold up the fragmented bone, and the conversion of knee extension device tension into compressive stress, which promoted healing of the fracture fragments, helped to overcome the challenges associated with complex fixation of comminuted fractures. However, the use of >3 internal fixation devices in the combination technique makes uniform fixation difficult to achieve. Excessive dispersion of the internal fixation devices increases the risk of soft tissue irritation. Greater trauma is also predicted during internal fixation removal procedures. Combining the advantages of this technique with an integrated internal fixation device may help to maximize the benefits of this treatment.

Herein, we summarize the biomechanical characteristics of inferior patellar pole fractures and the currently prevailing forms of internal fixation through a literature review. At the same time, we propose a novel internal fixation hypothesis for treating inferior patellar pole fractures based on our previous study. We evaluated the biomechanical advantages of this new type of internal fixation using finite element analysis and provided a theoretical basis for this hypothesis.

Anatomy and Biomechanics

The patella, embedded in the quadriceps femoral tendon, is the largest sesamoid bone in the human body. The cartilage surface forms a joint with the cartilage surface between the two femoral condyles.⁷ The patella's inferior pole is a cancellous bone with no cartilaginous articular surface; therefore, it does not contribute to patellofemoral joint formation. Instead, it serves as the origin of the patellar ligament, which attaches to the tibial tuberosity, transmitting forces generated by the quadriceps muscles to the tibia in order to extend the knee.⁸ Polar vessels enter the bone through the distal pole between the articular cartilage and attachment of the patellar tendon.^{9,10} Magnetic resonance imaging has revealed that 80% of the patellar blood supply comes from the medial and inferior parts of the patella, which also explains the more pronounced hematomas caused by inferior pole fractures.¹¹

The inferior patellar pole is one of the stress concentration points of the knee joint and is balanced by complex loading patterns during knee joint flexion.¹² At the same time, owing to external tibial rotation during knee flexion, the lower patellar pole rotates laterally under traction from the patellar ligament.¹³ The lower patellar pole can be subjected to a direct reaction force caused by collision during injury. Intense contraction of the quadriceps femoris can cause excessive tension leading to avulsion of the lower patellar pole and avulsion fracture.¹⁴ At this point, because the medial tension is greater than the lateral tension, tears of the surrounding soft tissue can further aggravate the degree of fracture comminution.

Current Clinical Trends

Although inferior patellar pole fractures do not involve articular surfaces, internal fixation has been deemed to be to be

the less controversial treatment approach because of its unique role in knee movement. However, fixing the associated tiny fracture fragments is now becoming the focus of discussion. The general principles of treatment are to preserve the patella's length, restore the patella's biomechanical function, and reconstruct the knee extension mechanism. In addition, effective and reliable implants are necessary to achieve strong bone-to-bone healing, maintain stable reduction, and achieve early functional rehabilitation; thus, innumerable surgeons have applied their talents to this area. We reviewed and categorized current therapeutic techniques and aimed to review existing internal fixation methods.

Patellectomy and Suture Fixation

Partial patellectomy (Fig. 1A), the only treatment for comminuted inferior patellar pole fractures, is sometimes used in the absence of effective fixation or as a last resort.¹⁵ A series of studies comparing internal fixation with this traditional technique showed that partial patellectomy significantly affected knee function.¹⁶ There are many reasons for the controversy surrounding partial patellectomy, one of which is related to the inferiority of tendon-bone healing, in terms of strength and healing time, compared with osseous consolidation. Thus, there is a need for a period of immobilization after partial patellar resection (at least 6 weeks of cast immobilization is generally recommended), which is not conducive to early knee rehabilitation.¹⁷ Furthermore, partial patellectomy often results in a lower patellar position, leading to a shortening of the extensor mechanism.¹⁸ As a result, the compression forces in the patellofemoral joint increase, which can lead to cartilage damage. Therefore, this outdated approach has gradually been abandoned. However, in cases of inadequate fixation, it remains an effective treatment and should still be considered as a last resort.

The wire anchor system (Fig. 1B) consists of self-tapping screws and sutures used to bind and compress tissue or bone fragments.¹⁹ Wire anchors allow reattachment of the avulsed patella or patellar ligament to the bone, thus allowing for functional patellar reconstruction.²⁰ The main principle is to bury a screw proximal to the patellar fracture, and then insert an anchor nail with its own tail wire through the patellar ligament to reposition the fracture and soft tissue at the lower pole of the patella and restore the original anatomical shape.²¹ This procedure is minimally invasive, restores the anatomy of the knee extensor mechanism, and avoids the need for secondary surgery.²² However, Kadar *et al.* reported internal fixation failure due to limited fixation strength with wire anchors. The reoperation rate was 14.8%, with a high infection rate (11%),¹⁹ Also, the placement of a wire anchor nail after partial resection of the inferior pole bone may decrease patellar height and cause misalignment.²³ The use of wire anchors also requires careful evaluation in patients with osteoporosis, especially concerning the timing of functional exercise and early weight-bearing.²⁴

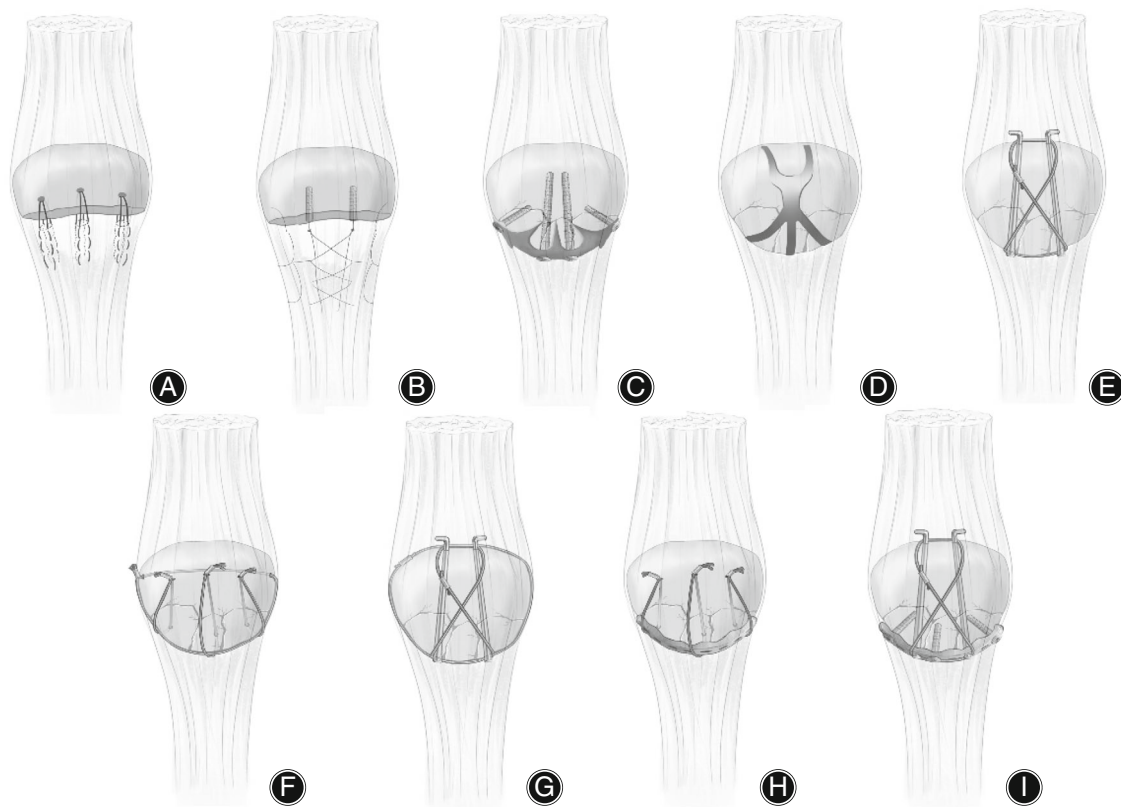


Fig. 1 Graphic review of current surgical treatments for inferior patellar pole avulsion fractures. (A) Partial patellectomy, (B) wire anchor system, (C) basket plate, (D) patellar concentrator, (E) tension-band wiring, (F) separate vertical wiring (SVW), (G) combination of the tension band wiring technique with cerclage wiring, (H) combination of a microplate technique with the SVW technique and (I) combination of a microplate technique with the tension band wiring technique.

Plate Fixation

The basket plate (Fig. 1C) method is probably the most well-known plate treatment strategy for inferior patellar pole fractures.²⁵ The basket plate was designed and used by Matejčić *et al.* to treat comminuted infrapatellar fractures.¹⁸ It was designed with tension screw holes and claws at the bottom and sides of the plate to hold the fragmented bone together. This plate can increase the postoperative outcome rate of patients with inferior patellar pole fractures to 90.1%, firmly fix the fracture fragment, restore knee extension, and provide early functional exercise capability.²⁵ However, basket plates can cause significant structural and functional damage to the patellar ligament, resulting in the significant shortening and rupture of the patellar ligament, risk of disruption of patellar ligament blood flow, and complications such as internal fixation provocation during knee flexion.²⁶

As an extension of plate fixation, the patellar concentrator (Fig. 1D) was designed according to the anatomical morphology and biomechanical characteristics of the patellar and patellofemoral joints.²⁷ The patellar concentrator is attached to the lumbar part of the anterior patellar body. When tightened, it can produce continuous centripetal

pressure on the patella to counteract tensile stress, thus repositioning and fixing the fracture and allowing the patient to perform functional knee exercises early after surgery.²⁸ However, the lower portion of the patellar claw sometimes does not completely encircle the fracture fragment, allowing lateral slippage between fragmented bones.²⁹ Additionally, the internal fixation failure rate is high, and complications such as decoupling and local augmentation are also possible.³⁰ Repeated intraoperative flushing with ice and hot water can lead to incisional inflammation and pain, respectively.

Wiring

Cerclage wiring is achieved by passing a wire through the quadriceps expansion and patellar ligament and wrapping it around the entire patella, causing the bone to converge.³¹ Unique cerclage wiring is unreliable for severe infrapatellar pole fractures; it cannot limit the anterior displacement of the fracture fragments during knee flexion and extension and is therefore prone to poor fixation.³² As a result, prolonged postoperative immobilization is required, often leading to complications, such as joint adhesions and stiffness.

Currently, this method is only used as the basis for combination fixation.^{33,34}

The WTB technique (Fig. 1E) is probably the most widely used technique for treating patellar fractures.³⁵ Due to contraction of the quadriceps muscle, the patellar surface tends to be subjected to considerable tension, and the patellofemoral articular surface to considerable pressure.³⁶ In the classical tension-band technique of the AO/OTA organization, two Kirschner wires are fixed in the center of the bone, and the “8” wire is fixed around the ends of the kerf pins to prevent angulation and rotation. The internal tension banding method converts tension into compressive stress and prevents displacement after fixation by eliminating the tendency of the fracture to separate during knee motion.³⁷ The biggest problem with using WTB fixation for inferior patellar pole fractures is the difficulty of maintaining fixation of small bone fragments.³⁸ The relatively small fracture fragments of the inferior patellar pole make it difficult to achieve firm fixation of the fracture end, which would effectively resist the pulling forces of the quadriceps muscle. Therefore, the WTB technique alone appears to be ineffective in managing inferior patellar pole fractures.³⁹

Separate vertical wiring (SVW) (Fig. 1F) is another widely used wiring technique.⁴⁰ Biomechanical studies have shown that its fixation strength is higher than tension-band wiring.⁴¹ SVW can be combined with other suturing techniques for small fragments, particularly in older adults. Biomechanical and clinical studies using ring-tie wire-reinforced vertical wiring alone have shown that combined fixation is superior to vertical wire fixation alone.⁴² In another modification of the SVW technique, the ring-tie wire was passed through the patellar body to improve damage to the patellar tendon caused by fixation of the ring-tie wire at the periphery of the patella.⁴³ Finite element analysis has suggested that this modified technique may achieve excellent biomechanical fixation and prevent bone fragmentation.⁴² Combining SVW with the Krachow suture technique has also yielded good results; however, caution is still needed regarding the cutting characteristics of SVW on the patellar ligament, especially in early rehabilitation exercises.⁵

Combined Technique

In recent years, combination techniques have been designed and developed when a single fixation technique cannot meet the challenges presented by inferior patellar pole fractures. Combination techniques have addressed various challenges, including comminuted bone fragments, patellar ligament shear, inferior patellar displacement, and limited early rehabilitation.⁴⁴ Combining the WTB technique with cerclage wiring (Fig. 1G) is a widely used fixation approach for treating inferior pole patellar fractures.³⁴ This combination fixation takes advantage of the WTB technique's ability to promote rapid healing of the fracture and the cerclage wiring technique's ability to compensate for the lack of fixation of comminuted bone fragments.

In 2014, Song *et al.* improved the SVW technique with interrupted vertical wire combined with ring ligation to treat adults over 50 years of age with osteoporosis.⁴¹ A cadaveric-specimen biomechanical study of the original and improved techniques was also conducted. The results showed a 41% increase in the fixation strength of the improved technique compared with that of the original technique. This improved technique also allowed early knee rehabilitation under postoperative brace protection. However, although the improved SVW technique is associated with better biomechanical performance and clinical efficacy, it has limitations.⁴² Postoperative limitation of range of motion is still required and the fixation strength, albeit improved, does not meet the needs for early unrestricted postoperative knee rehabilitation. Moreover, it is associated with complications such as mild limitation of knee extension and internal fixation fracture postoperatively.

Incorporating microplates into the existing technology has been another popular combined fixation technique in recent years. Microplates increase the contact area with the inferior patellar pole and can also be pre-bent to provide a more suitable fixation angle. At the same time, the screws fixed to the microplate provide additional fixation to the patella, equivalent to the microplate pocket of the bone. In view of these advantages, Cho *et al.* combined this microplate technique with the SVW technique (Fig. 1H).⁴³

Microplates avoid the cutting problem associated with SVW fixation while increasing the fixation area of the SVW. Compared with SVW fixation alone, a combined approach with microplates appears to achieve better clinical outcomes and firmer fixation, allowing earlier rehabilitation exercises. In addition, our previous research pioneered the combination of microplates with the tension-band wiring technique (Fig. 1I), and yielded surprising results.⁶ However, there are some problems with this combined technique, the most important of which are stress concentration and slight slippage at the multiple contact points of different forms of internal fixation. In particular, the contact between the wires and microplates causes local stress concentrations. In addition, the use of multiple combinations of internal fixation can lead to inconsistency in treatment and a prolonged learning curve for beginners. Therefore, owing to the disadvantages of single fixation and the shortcomings of combined fixation, designing a single form of internal fixation that considers the advantages of combined fixation becomes a potential necessity.

Medical Hypothesis

Inspired by our previous combined fixation study, we propose a novel internal fixation hypothesis for inferior patellar pole fractures. The main structure was composed of a supporting part resembling a miniature steel plate with titanium cables welded to both sides (Fig. 2A,B). During fixation, the fragmented bone of the inferior pole of the patella was picked up by the supporting part and held by locking screws inserted through the patellar body. Titanium cables

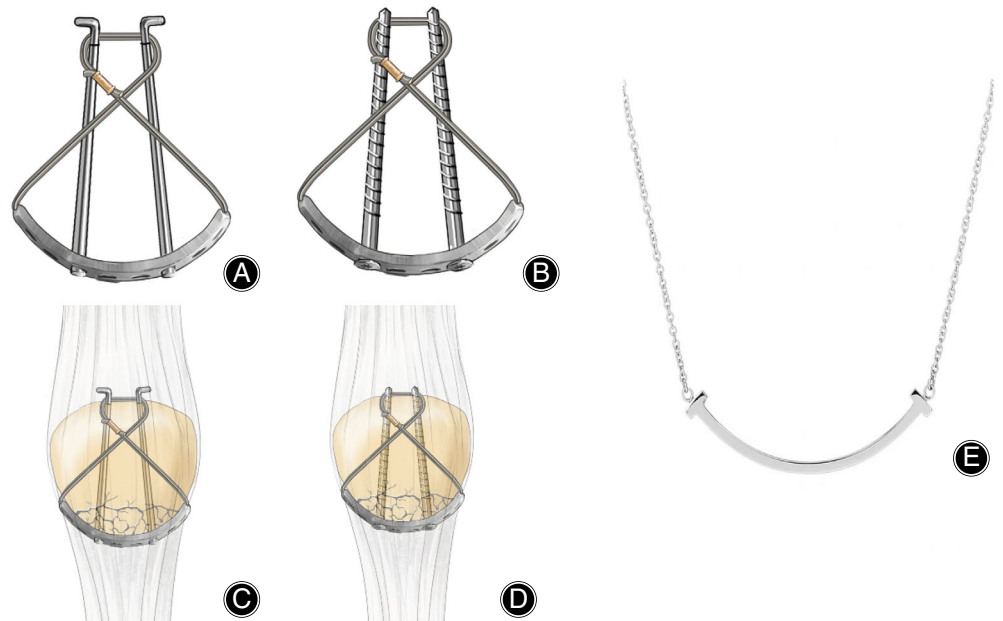


Fig. 2 The hypothesis and illustration of smile necklace plate (SNP) and its fixation for inferior patellar pole avulsion fractures. (A) and (B) two combination modes of SNP, (C) and (D) two fixation modes of SNP in the treatment of inferior patellar pole fractures, (E) famous smile necklace.

were wrapped around the screws to form a figure-of-eight tension-band structure in front of the patella and locked in place (Fig. 2C,D). Because the shape of the internal fixation resembled the famous jewelry smile necklace (Fig. 2E), we named it the smile-necklace plate (SNP).

This SNP combines the advantages of the large contact area of plate fixation with WTB fixation, which converts tension into compressive stress. The one-piece design reduces the risk of relative displacement associated with multiple internal fixations, thereby reducing the stress concentration when fixing the bone block. To better evaluate the biomechanical advantages of SNP, we used finite element analysis to compare SNP with six other common internal fixation methods. We compared the stress distribution, shear, and displacement values at fracture break after fixation with different implants to provide a theoretical basis for applying the SNP hypothesis.

Finite Element Analysis Results

We performed a computed tomography scan of the right knee of a healthy male volunteer and then created three-dimensional (3D) reconstructions of the patella using Mimics 17 software. The 3D reconstruction model was then imported into Geomagic Studio 2016 for denoising, wrapping, and smoothing, and a mesh was created (model materialization) using the surface modeling function of this software. Finally, the model parameters were imported into ANSYS R17.0 software for subsequent finite element model analysis. The volunteer provided informed consent for the experimental protocol.

Various parameters, such as the elastic modulus, Poisson's ratio, and density of the bone, wire, and plate in the 3D model, were defined according to a previous study

TABLE 1 Patella bone and titanium alloy material properties.

Materials	Young's modulus (MPa)	Poisson's ration
Cortical bone	16,300	0.3
Cancellous bone	2410	0.2
Cartilage bone	7	0.47
Steel	200,000	0.3
Titanium alloy	110,000	0.3

Table 2 Numbers of nodes and elements of patella fracture model.

Implants	Nodes	Elements
TBW	72,294	31,980
SVW	64,407	35,827
SVWM	70,955	38,172
TBWC	68,375	37,159
TBWM	66,265	36,191
SNPK	73,043	38,458
SNPS	71,873	37,914

(Table 1). The contact parameters between the metal and patella were set, and the friction between the metal and patella was defined as 0.2. The numbers of nodes and elements of patella fracture model are shown in Table 2. A fracture model of the inferior pole of the patella was constructed, which was defined as the distal non-articular surface of the inferior pole of the patella separated from the proximal patellar body and divided into three fragmented bones from medial to lateral a, b, and c (Fig. 3A). The

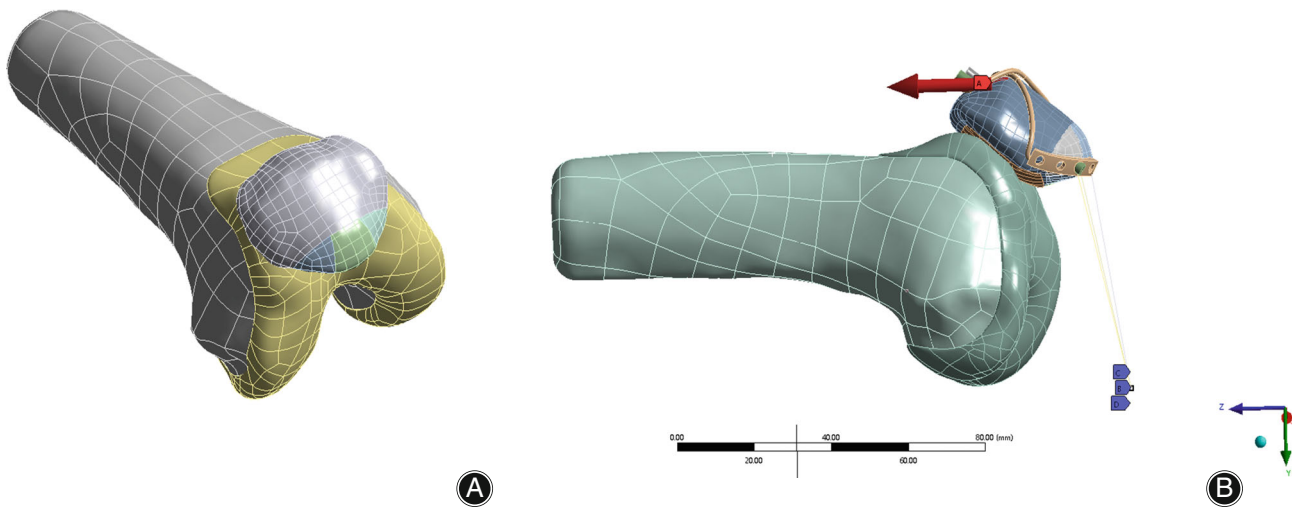


Fig. 3 Finite element model of inferior patellar pole avulsion fractures and loading conditions.

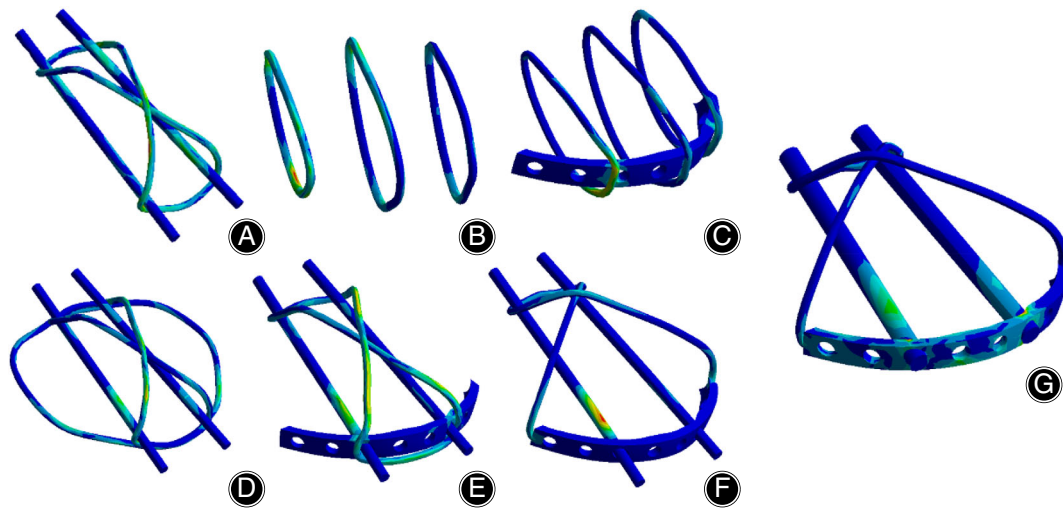


Fig. 4 The stress distribution illustration of the internal fixation in seven groups under different load conditions. (A) Tension-band wiring (TBW), (B) SVW, (C) SVW with microplate (SVWM), (D) TBW combined with cerclage wiring (TBWC), (E) TBW combined with microplate (TBWM), (F) SNP with Kirschner wire fixation (SNPK), (G) SNP with screw fixation (SNPS).

boundary conditions are shown in the figure, and the boundary conditions are applied through the coupling part of the reference point; the lower patellar pole is bound with constraints, and the upper patellar pole is loaded. By default, the distal patellar ligament attachment area was completely fixed in this model, that is, the displacement of the distal nodes in the X-, Y-, and Z-axes was 0. The load application path was set, and a tensile load of 0–500 N was gradually applied to the midpoint of the proximal patella within 2 s (Fig. 3B). ANSYS was used to analyze the models as follows: (i) stress distribution and stress values of the inferior patellar pole and endoprosthesis after fixation; (ii) relative displacement

distance of each bone block in the inferior patellar pole; (iii) shear stress on each bone block in the inferior patellar pole; and (iv) fatigue life of the SNP.

Seven types of internal fixation were used for biomechanical analysis of inferior pole patellar fractures using finite element analysis: SNP with screw fixation (SNPS), SNP with Kirschner wire fixation (SNPK), SVW, SVW with microplate (SVWM), conventional TBW fixation, TBW combined with cerclage wiring (TBWC) fixation, and TBW combined with microplate (TBWM) fixation. A stress distribution diagram is shown in Fig. 4. The stress of the TBW was concentrated on the tension side, and the stresses of the

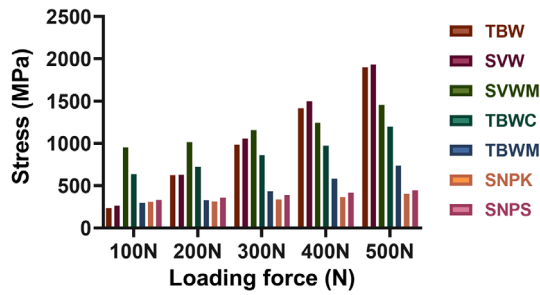


Fig. 5 The stress distribution of the internal fixation in seven groups under different load conditions.

SVW and SVWM were concentrated on the tension side and cut with the steel plate. In addition, the stress of the TBWC and TBWM was distributed on the tension side and metal contact, whereas the stress of the SNPK was distributed on the kerf pins in contact with the steel plate. The stress distribution of the SNPS was the least concentrated and sporadically distributed on the screw and steel plate. With a gradual increase in the load from 100–500 N, the maximum stress values in SVW and SVWM at a load of 500 N were 1458.3 and 1932.5 N, respectively. In contrast, the stress values of TBW and SNPS were the smallest, at 402.89 and 444.47 N, respectively (Fig. 5).

To investigate the effect of different implants on the displacement of bone fragments after fracture of the inferior pole of the patella, we compared the relative separation

distances of the overall bone mass (fracture contact surface) and the different comminuted bone fragments under different loads after fixation with seven implants. When the lower pole bone fragment was considered as a whole, the SNPS, SNPK, and TBWC groups had the lowest relative displacements under a load of 500 N with values of 0.62059, 0.93402, and 0.83387 mm, respectively (Fig. 6A). The relative displacements of the SNPS, SNPK, and SVWM groups were lowest when the lower pole bone block was crushed into three small bone fragments (a, b, and c bone fragments from the medial to the lateral sides). The relative displacements of the three bone blocks under a load of 500 N were 0.60035, 0.37936, and 0.42585 mm, respectively, in the SNPS group from the medial side to the lateral side, which were the smallest displacements among all groups (Fig. 6B,C).

To investigate the shearing forces of different endophytes on the patella, we tested the pressure at the contact point between the patella and implants in the X-Y, Y-Z, and X-Z directions for loads ranging from 100–500 N. The results are presented in Fig. 7A–C. The SVW and SVWM groups had the highest bone-implant shearing forces. The SNPS group had the smallest bone-implant shearing force, with pressures of 50.764, 61.22, and 89.623 MPa at a load of 500 N in the X-Y, Y-Z, and X-Z directions, respectively.

Finally, material fatigue was tested to assess the durability of SNPS. The minimum fracture test cycle of the SNP gradually decreased from 6.0018×10^6 as the load rose from 100–500 N but still met 5.2934×10^5 test cycles at 500 N (Fig. 8A,B).

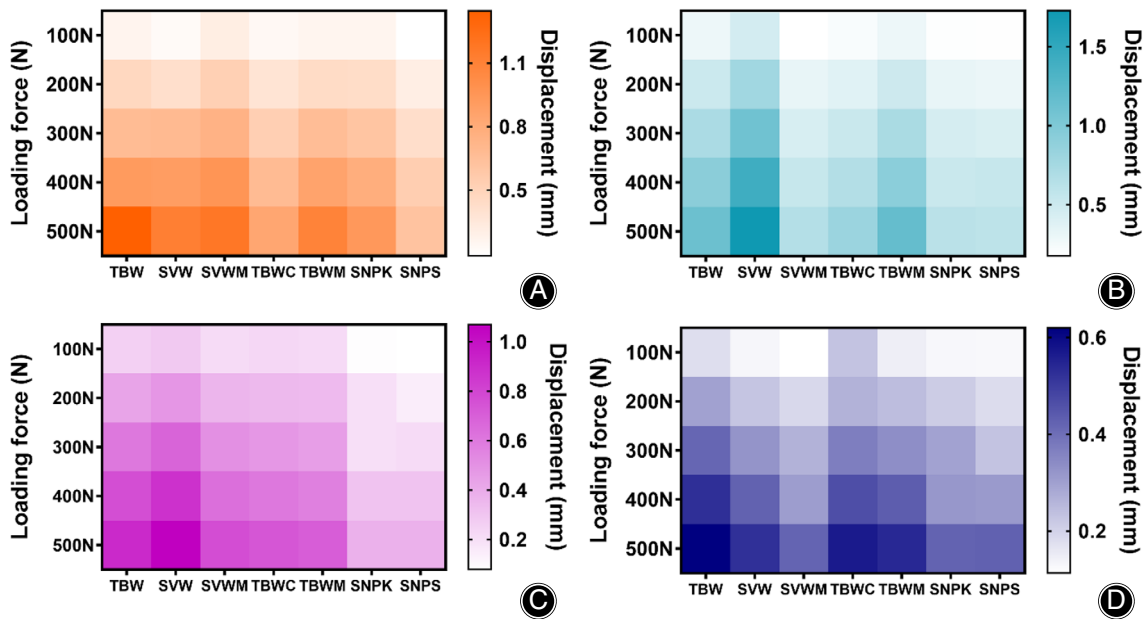


Fig. 6 The relative displacement of different distal fragments and main fragment in seven groups under different load conditions. (A) Displacement of face-fragment, (B–C) Displacement of fragments a-c.

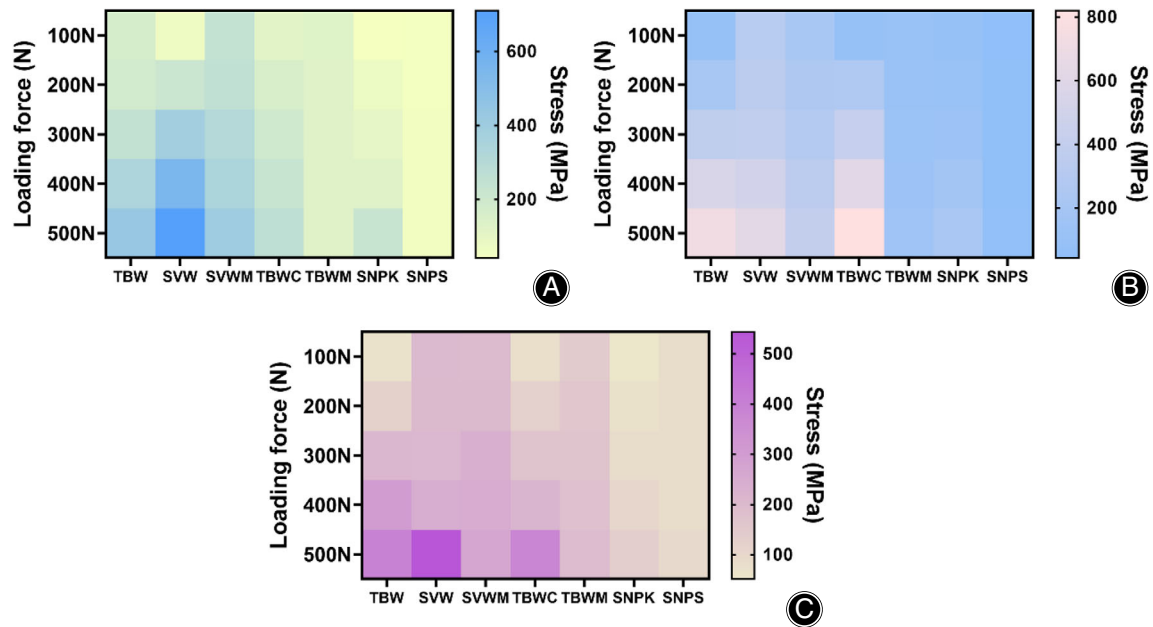


Fig. 7 Shear force of the internal fixation in seven groups in the X-Y(A), Y-Z(B), and X-Z(C) directions.

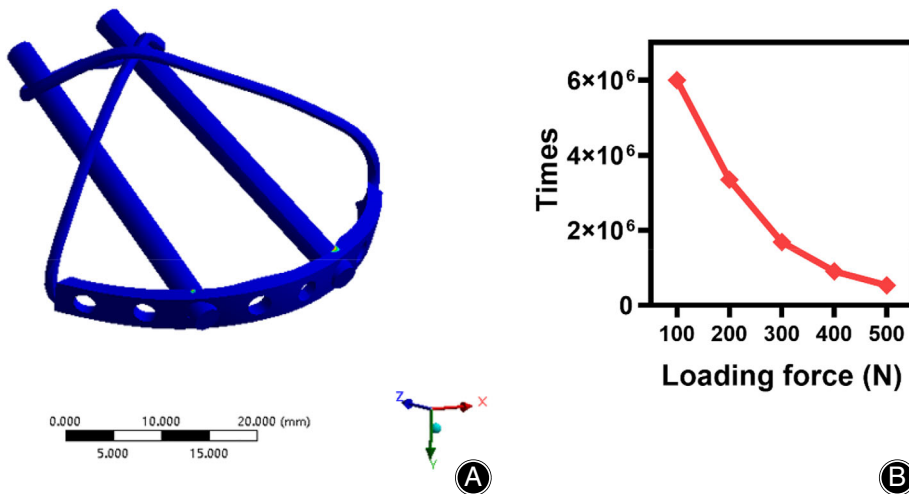


Fig. 8 Fatigue test (A) and curve (B) of necklace plate under different load conditions.

Discussion

Finite element analysis has been widely used in biomechanical studies of orthopedic implants, especially in analyzing the stress distribution and displacement of different internal fixation materials and surgical methods with unique advantages.⁴⁵ Finite element analysis can obtain results that are difficult to obtain using objective test methods by accurately simulating conceptual structural and material models subjected to special and complex loading and constraint conditions.⁴⁶ In this study, we explored the stress distribution of SNP and six conventional implants

using finite elements analysis. Implant stress reflects the force exerted by the implant during joint movement, and excessive stress may lead to fixation failure. The SNPS method showed less stress concentration, mainly in the distal implant region near the beginning of the patellar ligament.

In contrast, stresses in implants such as TBW and SVW were concentrated on the tension side and proximal end, which may lead to failure of internal fixation and impact the blood supply to the proximal patella and healing of the fracture. Subsequently, we explored the biomechanical performance of the SNPS in resisting bone fragment displacement.

When a 500 N tensile load was applied to the superior patellar pole, the contact surface displacement and point displacement of the three bony blocks from medial to lateral after SNPS fixation were 0.62059, 0.60035, 0.37936, and 0.42585 mm, respectively, which was significantly smaller than those of the other fixation groups, indicating that SNPS had better fixation strength. It has been shown that the quadriceps muscle generates a 316 N tensile load during knee extension and flexion; however, the displacement of the fracture end after SNPS fixation was only 0.42401 mm at 300 N and 0.54094 mm at 400 N.⁴⁷ This result indicates that SNPS fixation for inferior pole patellar fracture is sufficient to resist the large load generated by the quadriceps muscle during knee extension and flexion. Therefore, theoretically, SNPS fixation strength is adequate for allowing unrestricted functional exercise in the early postoperative period. Another biomechanical index of interest is the shear force exerted by the implant on bone. In cancellous bone, especially in combination with osteoporosis, the cable's shear forces may lead to internal fixation failure and patellar displacement, resulting in delayed fracture healing and failure of fixation.⁴⁸ Because the patella is subjected to numerous force directions and is often in motion, we compared the vertical shear forces at the contact point between the implant and bone in three different vector directions. The results showed that the SNPS exhibited low shear forces and would allow for early rehabilitation in older adults with osteoporosis.

There are some limitations to our study. The finite element model only included the patellofemoral joint and the corresponding cartilage contact surface and did not involve the associated ligaments and muscles, which may impact the results of the analysis. In addition, the SNP we designed is still hypothetical, and future industrial production and standard biomechanical experiments on cadavers are required.

In summary, we first reviewed and illustrated the current treatment strategies for inferior pole patellar fractures and analyzed the advantages and disadvantages of different endografts. We then hypothesized a novel endograft SNP for treating comminuted inferior pole patellar fractures and analyzed the biomechanical characteristics of the new implant using finite element analysis. The results showed that SNP has excellent biomechanical performance in stress distribution, resistance to fragment displacement, and bone-implant shear forces. Therefore, the SNP implant hypothesis may be a promising treatment option for inferior patellar pole fractures.

Author Contributions

WZ and LX conceived and designed the study, and WZ wrote the manuscript, WZ performed the analysis. XL finished all the illustrations. XZ, SF, and JY read, corrected, and approved the final manuscript. All authors read and approved the final manuscript.

Funding Information

This work was supported by the Key Research and Development Plan of Anhui Province (Grant No. 202104j07020047).

Ethics Statement

This study was approved by the Ethical Committee of the First Affiliated Hospital of the University of Science and Technology of China (2022-N(A)-033).

Data Availability Statement

The raw data supporting the conclusions of this article will be made available by the authors, without undue reservation.

References

- Bostrom A. Fracture of the patella. A study of 422 patellar fractures. *Acta Orthop Scand Suppl.* 1972;143:1–80.
- Kastelec M, Veselko M. Inferior patellar pole avulsion fractures: osteosynthesis compared with pole resection. *J Bone Joint Surg Am.* 2004;86:696–701.
- Lazaro LE, Wellman DS, Pardee NC, Gardner MJ, Toro JB, Macintyre NR 3rd, et al. Effect of computerized tomography on classification and treatment plan for patellar fractures. *J Orthop Trauma.* 2013;27:336–44.
- Bostman O, Kiviluoto O, Nirhamo J. Comminuted displaced fractures of the patella. *Injury.* 1981;13:196–202.
- Oh HK, Choo SK, Kim JW, Lee M. Internal fixation of displaced inferior pole of the patella fractures using vertical wiring augmented with Krachow suturing. *Injury.* 2015;46:2512–5.
- Zhu W, Xie K, Li X, Li L, Yang J, Xu L, et al. Combination of a miniplate with tension band wiring for inferior patellar pole avulsion fractures. *Injury.* 2020;51:764–8.
- Atesok K, Doral MN, Lowe J, Finsterbush A. Symptomatic bipartite patella: treatment alternatives. *J Am Acad Orthop Surg.* 2008;16:455–61.
- Fan M, Wang D, Sun K, Jiang W. Study of double button plate fixation in treatment of inferior pole of patella fracture. *Injury.* 2020;51:774–8.
- Scapinelli R. Blood supply of the human patella. Its relation to ischaemic necrosis after fracture. *J Bone Joint Surg Br.* 1967;49:563–70.
- Bjorkstrom S, Goldie IF. A study of the arterial supply of the patella in the normal state, in chondromalacia patellae and in osteoarthritis. *Acta Orthop Scand.* 1980;51:63–70.
- Lazaro LE, Wellman DS, Klinger CE, Dyke JP, Pardee NC, Sculco PK, et al. Quantitative and qualitative assessment of bone perfusion and arterial contributions in a patellar fracture model using gadolinium-enhanced magnetic resonance imaging: a cadaveric study. *J Bone Joint Surg Am.* 2013;95:e1401–7.
- Maquet P. Fractures of the patella. *J Bone Joint Surg Am.* 1994;76:1594. doi:10.2106/00004623-199410000-00023
- McMahon CJ, Ramappa A, Lee K. The extensor mechanism: imaging and intervention. *Semin Musculoskelet Radiol.* 2017;21:89–101.
- Koshino T. Changes in patellofemoral compressive force after anterior or anteromedial displacement of tibial tuberosity for chondromalacia patellae. *Clin Orthop Relat Res.* 1991;133–8.
- Saltzman CL, Goulet JA, McClellan RT, Schneider LA, Matthews LS. Results of treatment of displaced patellar fractures by partial patellectomy. *J Bone Joint Surg Am.* 1990;72:1279–85.
- Marder RAST, Sharkey NA, Duwelius PJ. Effect of patellectomy contact areas and reattachment of the patellar tendon on patellofemoral and pressures. *J Bone Joint Surg Am.* 1993;75:35–45.
- Sutton FS Jr, Thompson CH, Lipke J, Kettelkamp DB. The effect of patellectomy on knee function. *J Bone Joint Surg Am.* 1976;58:537–40.
- Matejčić A, Puljiz Z, Elabjer E, Bekavac-Beslin M, Ledinsky M. Multifragment fracture of the patellar apex: basket plate osteosynthesis compared with partial patellectomy. *Arch Orthop Trauma Surg.* 2008;128:403–8.
- Kadar A, Sherman H, Drexler M, Katz E, Steinberg EL. Anchor suture fixation of distal pole fractures of patella: twenty seven cases and comparison to partial patellectomy. *Int Orthop.* 2016;40:149–54.
- O'Donnell R, Lemme NJ, Marcaccio S, Walsh DF, Shah KN, Owens BD, et al. Suture anchor versus transosseous tunnel repair for inferior pole patellar fractures treated with partial patellectomy and tendon advancement: a biomechanical study. *Orthop J Sports Med.* 2021;9:23259671211022245.
- Xie J, Fu Y, Li J, Yu H, Zhang Y, Jing J. Anchor and Krackow-"8" suture for the fixation of distal pole fractures of the patella: comparison to Kirschner wire. *Orthop Surg.* 2022;14:374–82.
- Yu H, Dong H, Ruan B, Xu X, Wang Y, Hu L. Clinical effect of suture anchor and double-pulley technique in the treatment of inferior patellar fracture. *Comput Math Methods Med.* 2021;2021:4964195.

23. Huang W, Wu T, Wei Q, Peng L, Cheng X, Gao G. Suture repair of patellar inferior pole fracture: transosseous tunnel suture compared with anchor suture. *Exp Ther Med.* 2021;22:998.
24. Anand A, Kumar M, Kodikal G. Role of suture anchors in management of fractures of inferior pole of patella. *Indian J Orthop.* 2010;44:333–5.
25. Matejčić A, Smiljanic B, Bekavac-Beslin M, Ledinsky M, Puljiz Z. The basket plate in the osteosynthesis of comminuted fractures of distal pole of the patella. *Injury.* 2006;37:525–30.
26. Krkovic M, Bombac D, Balazic M, Kosel F, Hribernik M, Senekovic V, et al. Modified pre-curved patellar basket plate, reconstruction of the proper length and position of the patellar ligament—a biomechanical analysis. *Knee.* 2007;14:188–93.
27. Zhang Y, Wang P, Xia Y, Zhou P, Xie Y, Xu S, et al. Application of a shape-memory alloy concentrator in displaced patella fractures: technique and long-term results. *J Knee Surg.* 2017;30:166–73.
28. Zhao QM, Gu XF, Cheng L, Feng DH. Comparison of titanium cable tension band and nickel-titanium patella concentrator for patella fractures. *Adv Clin Exp Med.* 2017;26:615–9.
29. Chen R, Cao H, Sun Z, Jiang L, Li X, Zhao L, et al. The clinical outcome of the reduction of the patellar inferior pole fracture with wire cerclage through a generated bone hole, in combination with patellar concentrator: a retrospective comparative study. *J Orthop Surg Res.* 2022;17:117.
30. Lue TH, Feng LW, Jun WM, Yin LW. Management of comminuted patellar fracture with non-absorbable suture cerclage and Nitinol patellar concentrator. *Injury.* 2014;45:1974–9.
31. Singh RP, Shah RK, Srivastava MP. Treatment of inferior patellar pole avulsion fractures with pole resection and patellofemoral cerclage wire. *Nepal Med Coll J.* 2007;9:93–5.
32. Matsuo T, Watari T, Naito K, Mogami A, Kaneko K, Obayashi O. Percutaneous cerclage wiring for the surgical treatment of displaced patella fractures. *Strategies Trauma Limb Reconstr.* 2014;9:19–23.
33. Yan SG, Li D, Cui Y, Hua X, Hemmann P, Schmidutz F. Management of comminuted inferior patellar pole fractures with cerclage-wire-augmented separate vertical wiring: a retrospective clinical study. *Arch Orthop Trauma Surg.* 2021. doi: [10.1007/s00402-021-04034-4](https://doi.org/10.1007/s00402-021-04034-4)
34. Yang XWQ, Lai CH, Wang X. Management of displaced inferior patellar pole fractures with modified tension band technique combined with cable cerclage using Cable Grip System. *Injury.* 2017;48:2348–53.
35. Chang SM, Ji XL. Open reduction and internal fixation of displaced patella inferior pole fractures with anterior tension band wiring through cannulated screws. *J Orthop Trauma.* 2011;25:366–70.
36. Smith ST, Cramer KE, Karges DE, Watson JT, Moed BR. Early complications in the operative treatment of patella fractures. *J Orthop Trauma.* 1997;11:183–7.
37. Lefavre KA, O'Brien PJ, Broekhuysse HM, Guy P, Blachut PA. Modified tension band technique for patella fractures. *Orthop Traumatol Surg Res.* 2010;96:579–82.
38. Li J, Wang D, He Z, Shi H. Treatment of patellar lower pole fracture with modified titanium cable tension band plus patellar Tibial tunnel steel "8" reduction band. *J Invest Surg.* 2019;32:566–70.
39. Zhu L, Wang H, Song L, Wang B. Clinical application of suture anchor combined with Kirschner wires fixation for patella inferior pole fractures. *Asian J Surg.* 2022; 45:1418–9. doi:[10.1016/j.asjsur.2022.02.029](https://doi.org/10.1016/j.asjsur.2022.02.029)
40. Yang KHY. Separate vertical wiring for the fixation of comminuted fractures of the inferior pole of the patella. *J Bone Joint Surg Br.* 2003;85:1155–60.
41. Song HK, Yoo JH, Byun YS, Yang KH. Separate vertical wiring for the fixation of comminuted fractures of the inferior pole of the patella. *Yonsei Med J.* 2014; 55:785.
42. He S, Huang X, Yan B, Zhu J, Bao N, Zhao J. Modified technique of separate vertical wiring for the fixation of patellar inferior pole fracture. *J Orthop Trauma.* 2018;32:e145–e50.
43. Cho JW, Kim J, Cho WT, Gujjar PH, Oh CW, Oh JK. Comminuted inferior pole fracture of patella can be successfully treated with rim-plate-augmented separate vertical wiring. *Arch Orthop Trauma Surg.* 2018;138:195–202.
44. Li M, Qi H, Ma T, Li Z, Ren C, Huang Q, et al. Outcomes for a custom-made anchor-like plate combined with cerclage in the treatment of inferior pole patellar fracture. *BMC Musculoskelet Disord.* 2022;23:452.
45. Amirouche F, Choi KW, Goldstein WM, Gonzalez MH, Broviak S. Finite element analysis of resurfacing depth and obliquity on patella stress and stability in TKA. *J Arthroplasty.* 2013;28:978–84.
46. Kumaresan S, Yoganandan N, Pintar FA, Maiman DJ, Kuppa S. Biomechanical study of pediatric human cervical spine: a finite element approach. *J Biomech Eng.* 2000;122:60–71.
47. Patel VR, Parks BG, Wang Y, Ebert FR, Jinnah RH. Fixation of patella fractures with braided polyester suture: a biomechanical study. *Injury.* 2000;31:1–6.
48. Al-Obaedi O, RT R, Kundra R, Iqbal MJ. Gap non-union patella fractures: case report and review of the literature. *J Orthop Case Rep.* 2019;9:69–71.