

Parotid fistula from transparotid approach for mandibular subcondylar fracture reduction

S. M. Balaji

Director, Balaji Dental and Craniofacial Hospital, Teynampet, Chennai, Tamil Nadu, India

Address for correspondence:

Dr. S. M. Balaji, Balaji Dental and Craniofacial Hospital, 30, KB Dasan Road, Teynampet, Chennai - 600 018, Tamil Nadu, India.
E-mail: smbalaji@gmail.com

Access this article online

Website: www.amsjournal.com
DOI: 10.4103/2231-0746.119214
Quick Response Code: 

ABSTRACT

Injury and/or damage to the parotid salivary glandular element during mandible condylar fracture approach is a rare event that leads to accumulation of saliva in the gland, leading to formation of a sialocele. Huge sialocele often seeks drain through the most dependent area through an extraoral wound. A case of parotid fistula (PF) caused by damage to glandular elements during a transparotid approach for a subcondylar fracture reduction is reported. The mechanism of damage and all possible sequels for the condition is being discussed. The method of surgical intervention for this condition is also discussed.

Keywords: Parotid fistula, sialocele, subcondylar fracture, transparotid approach

INTRODUCTION

A parotid fistula-sialocele (PFS) is an uncommon, extremely unpleasant early complication following injury in the maxillofacial region. They have been reported to occur in a variety of situation including trauma, neoplastic process, surgeries for temporomandibular joint region, surgical treatment of parotid lesions, or secondary to drainage of facial/parotid abscess. The incidence of PF in a variety of settings is as high as 14%. Iatrogenic causes of parotid fistulae include mandibular osteotomy, use of external pin fixation, and as a complication of facial fracture treatment.^[1]

A working classification based on sialogram of PFS has been proposed by Parekh *et al.*^[2] This classification gives a basis of treatment that is needed to be provided. Literature has a consensus for management of acute parotid injury, indicating primary exploration and that all injured structures are repaired accurately. The treatment of chronic injury is controversial. Numerous methods of treatment, conservative as well as aggressive, have been described with varying success and morbidity in literature. Such options are listed in Figure 1.^[2]

CASE REPORT

A 24-year-old otherwise healthy male patient reported with the chief complaint of watery discharge from a swelling on the right side of the face for the past 1 month. Patient had a history of mandibular condylar fracture from a road traffic accident, for which he was treated elsewhere with direct open reduction and internal fixation of the condyle. The surgical scar was observed on the post-ramus swelling, and there was fistula in one end of the scar that was about 0.5 cm in diameter [Figures 2a and b]. The wound was 2 cm deep and had a healthy granulating margin with no obvious clinical signs of infection, but the wound continued to have a drain of a copious amount of clear, watery, and odorless fluid.

On examination of parotid papillae, intraorally, active secretion was present on the left side, but not on the right side. Neurological examination revealed no motor loss due to severance of any branch of facial nerve in the affected side. Location of the fistula and nature of the discharge suggested a laceration of the right parotid gland substance resulting in a sialocele and a right parotid fistula formation. Sialogram confirmed the clinical suspicion [Figures 3a-d].

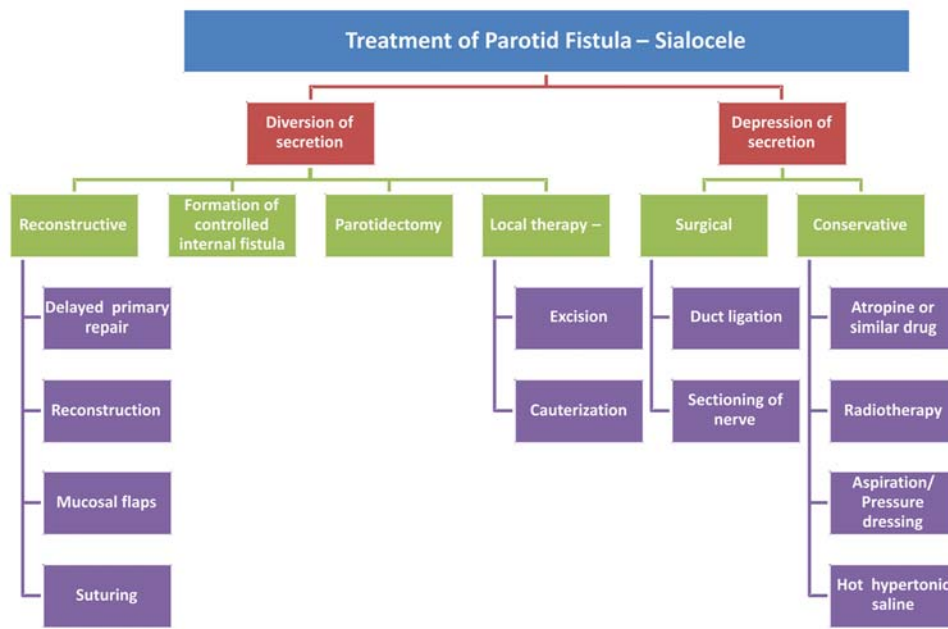


Figure 1: Methods to treat parotid fistula sialocele. [Modified from Ref. 2]

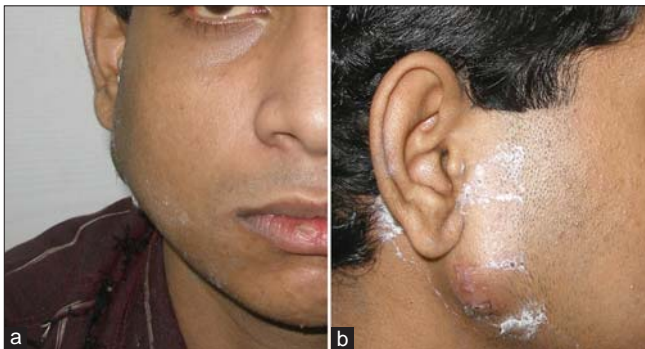

Figure 2: Clinical view of swelling with discharge (a) Frontal, (b) Lateral

In the present case, trauma in the parotid glandular substance lead to formation of sialocele by accumulation of extravasated saliva into glandular parenchyma. It was decided to create a controlled internal fistula with drainage intraorally under local anesthesia. After standard preparation, intraorally, a 1-cm long incision was placed on external oblique ridge behind the third molar. A small artery forceps was forced through the superficial fascia of masseter reaching the sialocele. With the help of this forceps, approximately 5-cm long, slender, sterile, punched plastic tube of diameter 4 mm was positioned with one end in the glandular substance and the other end in the mouth, seated along the vestibule, ensuring complete convenience. The tube was secured by suturing it to the mucosal surface of the cheek [Figure 4]. Extraorally, the wound was sutured primarily in layers, followed by compression dressing on the cheek. The patient was covered with Ciprofloxacin and Metronidazole for 5 days to prevent superadded infections. Saliva stopped draining by 10th postoperative day of surgery. The tube was subsequently removed to enable the internal fistula to close and salivary secretions to drain through the right Stenson's duct normally. The patient's recovery was uncomplicated and follow-up was done for 5 months and lost to follow-up.

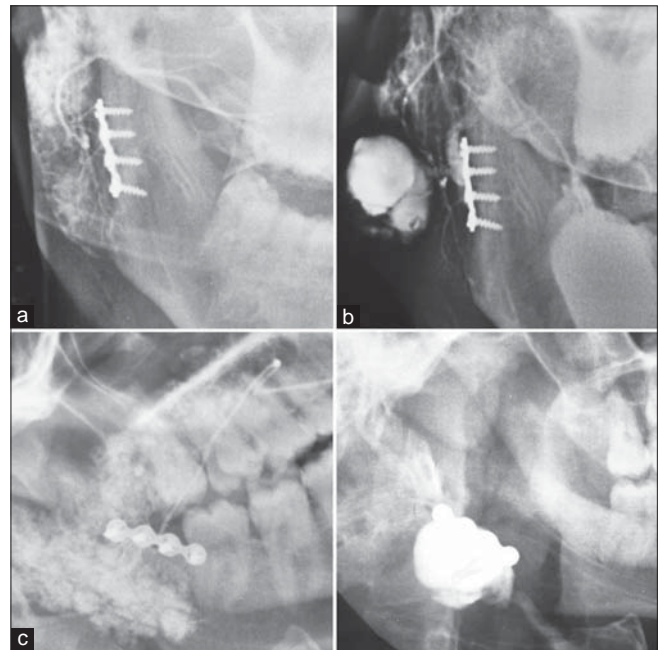


Figure 3: Sialography examination, (a) Scout examination, (b) Pre lime test-note the gland, (c) After lime test, (d) Note the accumulation of saliva in parotid substance

DISCUSSION

For surgical treatment of condylar fractures, many approaches including preauricular, submandibular, retromandibular, intraoral, and endoscopic approach have been advocated. Each approach has its own advantages and disadvantages. The transparotid is the most preferred choice as it gives a direct access, but is extremely technique sensitive and may significantly increase postoperative complications and morbidity in untrained hands.^[3,4] The choice

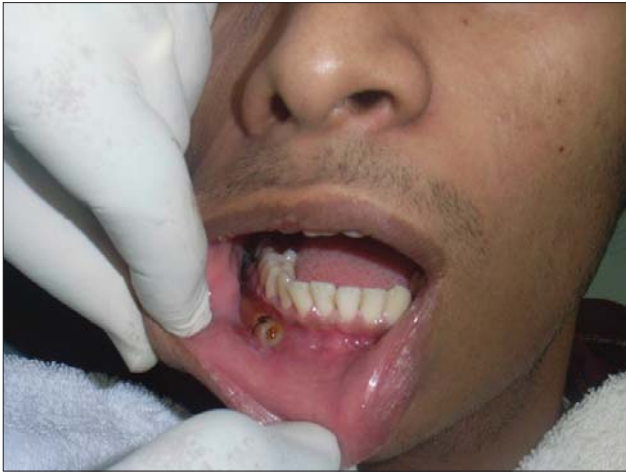

Figure 4: Intraoral opening of the inserted tube along the labial vestibule

of approach is dictated by the level of fracture and surgeon's preference.^[4]

Incision for transparotid approach for the condylar head is placed 1-5 mm below the lobule of the ear, running vertically and parallel to the posterior border of ramus. Extensions are made to improve access. A skin flap is raised superficial to parotid fascia and simultaneously retracted anteriorly. A convenient vertical release incision is placed on parotid fascia to visualize the gland as well as to allow retraction for access. Blunt dissection is usually done in the parotid substance as this will move away the facial nerve and its branches from the site of manipulation. On retraction of parotid, masseter is visualized and incised in a vertical plane. The fracture site is visualized and plated. The masseter and parotid fascia are usually closed in layers tightly to prevent formation of sialoceles.^[3]

In the present case, during condylar approach, parotid fascia has either been damaged and probably the closure of layers was not adequately tight to prevent the formation of sialoceles. Although sialoceles tend to subside by local treatment, this sialocele proceeded to form a parotid fistula. Hence, this case was surgically treated.

On sialogram, the most effective diagnostic modality,^[5] the defect was noticed in the parotid substance during rest and stimulation. Hence, this case had to be treated by surgery by internalization. Before the widespread use of sialogram, management of PFS was a problem. This was because the complex parotid anatomy and the nature of salivary drainage did not permit gauging the extent and accurate place of trauma. With the use of sialogram and classification of PFS by Parekh,^[2] understanding of the natural history of PFS was much easier.

Placing an internal drain created a better connection between oral cavity and parotid substance that helped to resolve the situation [Figure 4]. After placing such a drain, there would be no pooling of saliva in the glandular substance. This would allow healing of the gland and subsequent formation of structures necessary for drainage through the main Stensen's duct. A slender, thin, plastic drain saves the need of complex requirements.^[6]

The occurrence of such a PFS is rare. In a case series of 51 condylar fractures treated by transparotid approach, 1 case of sialocele and 1 case of parotid fistula was observed.^[3] PFS, although a possibility, can be prevented by correct preoperative evaluation of the fracture site, review of local anatomy, and planning. Intraoperatively, careful manipulation, looking for minor deviation in local anatomy, as well as tight closure would prevent such a complication.

CONCLUSION

A rare case of iatrogenic damage to parotid substance is presented. A relatively logical and cheaper alternative was used to surgically intervene and correct the defect. This episode highlights the necessity of surgical preplanning and careful closure with tight sutures in layers. Inadvertent mishaps such as this case are expected, but careful assessment and management will resolve the condition effectively.

REFERENCES

1. Rao JK, Gehlot N, Laxmy V, Siwach V. Management of parotid fistula using hypertonic saline. *Natl J Maxillofac Surg* 2011;2:177-80.
2. Parekh D, Glezeron G, Stewart M, Esser J, Lawson HH. Post-traumatic parotid fistulae and sialoceles. A prospective study of conservative management in 51 cases. *Ann Surg* 1989;209:105-11.
3. Downie JJ, Devlin MF, Carton AT, Hislop WS. Prospective study of morbidity associated with open reduction and internal fixation of the fractured condyle by the transparotid approach. *Br J Oral Maxillofac Surg* 2009;47:370-3.
4. Wilson AW, Ethunandan M, Brennan PA. Transmasseteric antero-parotid approach for open reduction and internal fixation of condylar fractures. *Br J Oral Maxillofac Surg* 2005;43:57-60.
5. Gadodia A, Bhalla AS, Sharma R, Thakar A, Parshad R. MR sialography of iatrogenic sialocele: Comparison with conventional sialography. *Dentomaxillofac Radiol* 2011;40:147-53.
6. Ajike SO, Omisakin OO, Ogbefun JO. The use of feeding tube in the treatment of a parotid duct fistula. *J Med Med Sci* 2011;2:1014-16.

Cite this article as: Balaji SM. Parotid fistula from transparotid approach for mandibular subcondylar fracture reduction. *Ann Maxillofac Surg* 2013;3:182-4.

Source of Support: Nil, **Conflict of Interest:** None declared.