



Original Article

Reconstruction of the anterior cruciate ligament by means of an anteromedial portal and femoral fixation using Rigidfix^{☆,☆☆}



André Manoel Inácio^{a,*}, Osmar Valadão Lopes Júnior^{a,b}, André Kuhn^b, José Idílio Saggin^b, Paulo Renato Fernandes Saggin^b, Leandro de Freitas Spinelli^{a,c}, Daniela Medeiros de Castro^d

^a Institute of Orthopedics and Traumatology of Passo Fundo, Passo Fundo, RS, Brazil

^b Hospital São Vicente de Paulo, Passo Fundo, RS, Brazil

^c Orthopedics and Traumatology Service of the Hospital Complex, Santa Casa de Porto Alegre, Porto Alegre, RS, Brazil

^d Radiology and Imaging Diagnostics Service, Kozma Clinic of Passo Fundo, Passo Fundo, RS, Brazil

ARTICLE INFO

Article history:

Received 25 June 2013

Accepted 15 October 2013

Available online 22 October 2014

Keywords:

Knee/surgery

Anterior cruciate ligament

Reconstruction

ABSTRACT

Objective: To evaluate a series of patients who underwent surgery for reconstruction of the anterior cruciate ligament with flexor tendons, by means of the anteromedial transportal technique using Rigidfix for femoral fixation, and to analyze the positioning of the pins by means of tomography.

Methods: Thirty-two patients were included in the study. The clinical evaluation was done using the Lysholm, subjective IKDC and Rolimeter. All of them underwent computed tomography with 3D reconstruction in order to evaluate the entry point and positioning of the Rigidfix pins in relation to the joint cartilage of the lateral condyle of the femur.

Results: The mean Lysholm score obtained was 87.81 and the subjective IKDC was 83.72. Among the 32 patients evaluated, 43% returned to activities that were considered to be very vigorous, 9% vigorous, 37.5% moderate and 12.5% light. In 16 patients (50%), the distal entry point of the Rigidfix pin was located outside of the cartilage (extracartilage); in seven (21.87%), the distal pin injured the joint cartilage (intracartilage); and in nine (28.12%), it was at the border of the lateral condyle of the femur.

Conclusion: The patients who underwent ACL reconstruction by means of the anteromedial transportal using the Rigidfix system presented satisfactory clinical results over the length of follow-up evaluated. However, the risk of lesions of the joint cartilage from the distal Rigidfix pin needs to be taken into consideration when the technique via an anteromedial portal is used. Further studies with larger numbers of patients and longer follow-up times should be conducted for better evaluation.

© 2014 Sociedade Brasileira de Ortopedia e Traumatologia. Published by Elsevier Editora Ltda. Este é um artigo Open Access sob a licença de [CC BY-NC-ND](#)

* Please cite this article as: Inácio AM, Lopes Júnior OV, Kuhn A, Saggin JI, Fernandes Saggin PR, de Freitas Spinelli L, de Castro DM. Reconstrução do ligamento cruzado anterior pelo portal anteromedial e fixação femoral com Rigidfix. Rev Bras Ortop. 2014;49:619-624.

☆☆ Work developed in the Institute of Orthopedics and Traumatology of Passo Fundo, Passo Fundo, RS, Brazil.

* Corresponding author.

E-mail: andremanoel.inacio@yahoo.com (A.M. Inácio).

<http://dx.doi.org/10.1016/j.rboe.2014.10.004>

2255-4971 © 2014 Sociedade Brasileira de Ortopedia e Traumatologia. Published by Elsevier Editora Ltda.

Este é um artigo Open Access sob a licença de [CC BY-NC-ND](#)

Reconstrução do ligamento cruzado anterior pelo portal anteromedial e fixação femoral com Rigidfix

R E S U M O

Palavras-chave:

Joelho/cirurgia
Ligamento cruzado anterior
Reconstrução

Objetivo: Avaliar uma série de pacientes submetidos à cirurgia de reconstrução do ligamento cruzado anterior com tendões flexores pela técnica transportal anteromedial com o uso de Rigidfix para fixação femoral e analisar o posicionamento dos pinos por meio de tomografia. **Métodos:** Foram incluídos no estudo 32 pacientes. A avaliação clínica foi feita com os escores de Lysholm, IKDC subjetivo e Rolimeter. Todos foram submetidos a tomografia computadorizada com reconstrução em 3D para avaliação do ponto de entrada e do posicionamento dos pinos do Rigidfix em relação à cartilagem articular do côndilo lateral do fêmur.

Resultados: A média do escore de Lysholm obtido foi de 87,81 e do IKDC subjetivo, de 83,72. Dos 32 pacientes avaliados, 43% retornaram a atividades consideradas muito vigorosas, 9% a vigorosas, 37,5% a moderadas e 12,5% a leves. Em 16 pacientes (50%), o ponto de entrada do pino distal do Rigidfix foi localizado fora da cartilagem (extracartilagem), em sete (21,87%) o pino distal lesou a cartilagem articular (intracartilagem) e em nove (28,12%) ficou na borda da cartilagem articular do côndilo lateral do fêmur.

Conclusão: Os pacientes submetidos à reconstrução do LCA com o sistema Rigidfix pela técnica transportal anteromedial apresentaram um resultado clínico satisfatório no tempo de seguimento avaliado. Entretanto, o risco de lesão da cartilagem articular pelo pino distal do Rigidfix deve ser considerado quando a técnica via portal anteromedial é usada. Outros estudos com maior número de pacientes e com um tempo de seguimento mais longo devem ser feitos para melhor avaliação.

© 2014 Sociedade Brasileira de Ortopedia e Traumatologia. Publicado por Elsevier Editora Ltda. Este é um artigo Open Access sob a licença de [CC BY-NC-ND](https://creativecommons.org/licenses/by-nc-nd/4.0/)

Introduction

Anterior cruciate ligament (ACL) injuries are among the commonest ligament injuries of the knee. Different techniques with different types of graft and different fixation methods have been described for surgical treatment, all with satisfactory clinical results. Today, ACL reconstruction using autologous grafts from the tendons of the gracilis and semitendinosus muscles has gained popularity because of the lower morbidity at the graft donor site, lower incidence of femoropatellar symptoms and lower incidence of contractures in flexion.^{1,2}

The success of ACL reconstruction surgery is related to various preoperative, transoperative and postoperative factors. Among these, the positioning of the bone tunnels in ACL reconstruction surgery, and consequently the positioning of the tendon graft, is considered to be one of the single most important factors. Recent studies have shown that when the femoral tunnel is positioned more anatomically in relation to the femoral insertion of the ACL, it provides better rotational control of the knee, better knee mobility and less chance of impact of the ACL on the posterior cruciate ligament (PCL) during flexion.³ There are three techniques for constructing the femoral tunnel: the transtibial technique, the outside-to-inside or two-incision technique and the transportal technique (anteromedial or accessory medial portal). Some studies have shown that with the transtibial technique, in which the femoral tunnel is constructed through the tibial tunnel, it is more difficult to achieve anatomical positioning

of the femoral tunnel.^{4,5} For this reason, the anteromedial transportal technique, with tunnels constructed independently and without the need for an additional incision in the lateral face of the femur, is a constant focus of discussion.

The different types of tendon graft and the pursuit of femoral tunnel positioning that is more horizontal in the lateral femoral condyle have given rise to adaptation of the fixation methods traditionally used in ACL reconstruction with flexor tendons. Thus, transverse fixation methods with fixed angles of implant entry in the lateral face of the femur have been reassessed, because they may put the posterolateral and intra-articular structures of the knee at risk.⁴

The Rigidfix system (Mytek, Norwood, MA) consists of two pins made of polylactic acid, diameter 2.7 mm, for femoral fixation of the graft in the femoral tunnel. The system transfixes the graft at two points, which produces compression against the tunnel wall and enables a wide bone-graft contact area.⁶ In an anatomical study, Castoldi et al.⁷ evaluated the positioning of the entry of Rigidfix pins in the lateral condyle in relation to the technique via an anteromedial portal. These authors concluded that the risk of chondral lesions resulting from the entry of the implant varied according to the angle of the pin insertion guides and also according to the size of the femoral condyles.

The present study had the objective of evaluating a series of patients who underwent ACL reconstruction surgery using flexor tendons by means of the anteromedial transportal technique, with the Rigidfix system for femoral fixation. This study

also had the secondary objective of evaluating the positioning of the entry of the Rigidfix pins, by means of 3D tomography.

Materials and methods

Thirty-two patients were selected for this study. All of them were operated by the same surgical team between January 2009 and July 2010. The patients included underwent ACL reconstruction surgery using a quadruple autologous graft from the flexor tendons (gracilis and semitendinosus), using Rigidfix for femoral fixation and Biointrafix (Mitek, Norwood, MA, USA) for tibial fixation. The operations were performed by means of the anteromedial transportal technique,⁸ with at least 24 months of postoperative follow-up. We excluded patients from the study in the following situations: if another type of graft was used for ACL reconstruction (patellar tendon, quadriceps tendon or an allograft); if a route other than the anteromedial transportal route was used for constructing the femoral tunnel; if the follow-up was less than 24 months; or if another method was used for femoral fixation of the graft. This study was approved by our institution's research bioethics committee and all the individuals evaluated signed a free and informed consent statement.

To evaluate the positioning of the point of entry and the Rigidfix pins, all the patients underwent multislice computed tomography examination with 3D reconstruction (Toshiba; Aquilion TSX-101 model with 64 channels) within six weeks after the surgery. The positioning of the point of entry of the proximal and distal Rigidfix pins in the lateral face of the lateral femoral condyle was classified as "intracartilage" (IC), "on the border of the cartilage" (BC) or "extracartilage" (EC) (Fig. 1).

For the clinical evaluation, the patients underwent objective measurements on the pre and postoperative anterior and functional translation using the Lysholm scale^{9,10} and the subjective IKDC scale.¹¹ The Lysholm scale uses ordinal assessment scores and these are defined as "excellent" if they are between 95 and 100 points, "good" if between 84 and 94 points, "fair" if between 65 and 83 points and "poor" if 64 points and under.^{9,10} The scores obtained using the subjective IKDC scale can vary from zero to 100 and the higher the score is, the better the function is considered to be. The objective evaluation of tibial translation was performed using a Rolimeter (Aircast).¹² The clinical assessment was performed by an independent evaluator without knowledge of the positioning of the pins obtained in the tomography examination.

All the patients underwent the same postoperative rehabilitation protocol. Partial weight-bearing using crutches was allowed after the first day after the surgery and this was maintained for two weeks. No type of brace was used. Exercises for achieving complete range of motion of the joint were allowed as tolerated. Closed kinetic chain exercises were started four weeks after the surgery. Running and open kinetic chain exercises were started three months after the operation and the patients were allowed to return to contact sports after eight months had passed.

The statistical evaluation was performed using the Excel software (Microsoft) and consisted of descriptive statistics and frequency distributions.

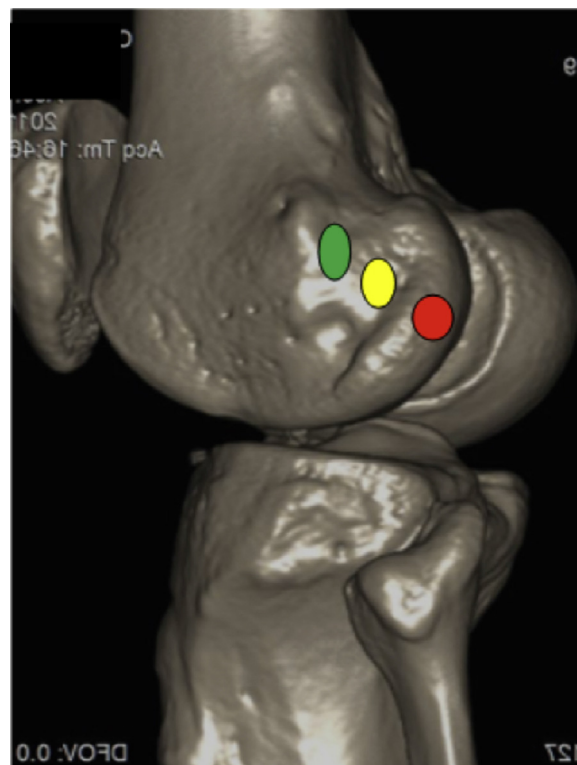


Fig. 1 – Tomographic image of the knee with 3D reconstruction, showing the references used for defining the points of entry of the Rigidfix pins in the lateral condyle of the femur, in relation to the joint cartilage. Green spot – extracartilage; yellow spot – border of cartilage; and red spot – intracartilage.

Surgical technique

The patient was positioned in dorsal decubitus under spinal anesthesia used in association with peripheral block of the ipsilateral femoral nerve. A pneumatic tourniquet was used on the proximal third of the thigh of the leg involved. After performing asepsis and antiseptics and placing sterile fields, the leg was positioned with hip flexion of 45° and knee flexion of 90°.

The graft from the tendons of the gracilis and semitendinosus muscles was harvested in the usual manner. A quadruple graft was prepared using Krackow stitches.¹³ The joint was then inspected and debridement of the ACL stumps was performed, along with arthroscopic treatment for the other lesions present. A guidewire was inserted through the anteromedial portal and was introduced into the femoral insertion of the ACL with the knee flexed at 120°, seeking the location of the insertion of the anteromedial band of the ACL. The femoral tunnel was constructed through the anteromedial portal, with a length of 30 mm. This measurement was marked on the proximal extremity of the tendon graft. The tibial tunnel was constructed with the aid of a tibial guide angled at 45° and placed at the center of the tibial insertion of the ACL. The Rigidfix femoral guide was introduced through the anteromedial portal into the femoral tunnel. By means of

the femoral guide, two guide cannulae for introducing Rigidfix were fixed to the lateral face of the lateral condyle by means of accessory incisions. The quadruple tendon graft was passed through the bone tunnels under arthroscopic guidance. The femoral fixation of the tendon graft was performed using the Rigidfix system (2.7 mm). The tibial fixation was performed with the knee flexed at 30°, using the Biointrafix system.

Results

For this study, 32 patients with a mean postoperative follow-up of 30 months (range: 24–36 months) were selected. There were 28 males and four females. Their mean age was 33.1 years (range: 16–56) at the time of the surgery. Twenty-nine patients presented meniscal lesions (90.6%), among which 20 were lesions of the medial meniscus alone (68.9%), five were lesions of the lateral meniscus alone (17.2%) and four were lesions of both menisci (13.8%). Partial meniscectomy was performed on the lesions in all cases.

Regarding the functional evaluation, the mean preoperative Lysholm score was 74.53 (range: 43–83) and the mean postoperative score was 87.81 (range: 53–95), and this result can be considered good.^{9,10} The mean subjective IKDC was 74.16 (range: 37.93–91.95) before the operation and 83.72 (57.5–100) after the operation.

Regarding the return to physical activity, 14 patients (43.75%) reported that they were regularly doing activities that can be considered to be very vigorous, such as soccer or basketball; three (9.3%) cited vigorous activities such as volleyball and tennis; 12 (37.5%) reported doing moderate activities, such as gym training or running; and four (12.5%) mentioned light activities such as walking and domestic work.

In relation to symptoms, 11 of the 32 patients reported pain on making effort (34.4%) and six reported sporadic edema (18.75%). In the physical examination, atrophy of the quadriceps muscle of the thigh was found in 20 patients (62.5%), but the atrophy was only considered severe in one patient (>2 cm difference in relation to the opposite side).

Regarding the evaluation of the positioning of the point of entry of the Rigidfix pins, the point of entry of the proximal pin was outside of the cartilage in all the patients (Fig. 2). The point of entry of the distal pin was in the peripheral region of the joint cartilage in seven patients (21.87%) (Fig. 3), at the border of the cartilage in nine (28.12%) and outside the cartilage in 16 (50%) (Table 1).

Combined analysis on the pin positions in relation to the joint cartilage and the results from the Lysholm and subjective IKDC scores showed that in the patients in whom the distal Rigidfix pin was positioned within the cartilage, the mean

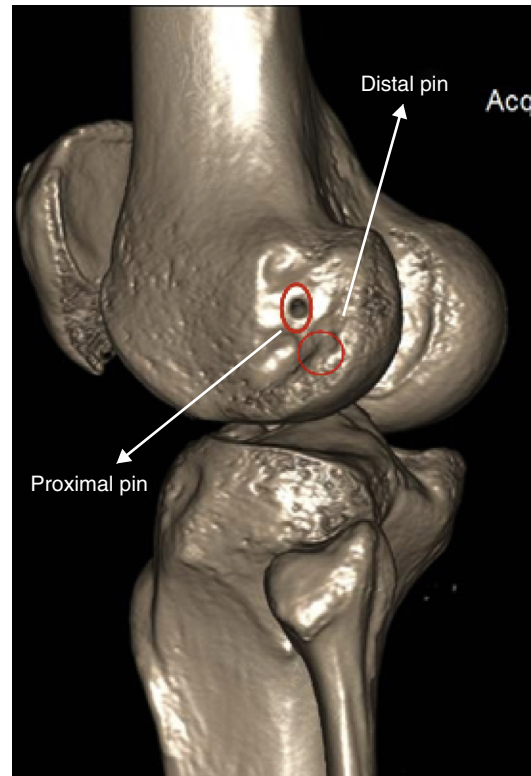


Fig. 2 – Tomographic image demonstrating the point of entry of the proximal Rigidfix pin outside of the joint cartilage and the point of entry of the distal Rigidfix pin at the border of the joint cartilage of the lateral face of the lateral femoral condyle.

Lysholm score was 89.85 (range: 89–93) and the mean IKDC score was 79.95 (range: 65.5–95.4); in those in whom the distal pin was at the border of the cartilage, the mean was 88.33 for the Lysholm score (range: 53–95) and 86.2 for the IKDC score (range: 69–100), while in those in whom the distal pin was positioned outside of the cartilage, the mean Lysholm score was 87.2 (range: 68–95) and the mean IKDC score was 83.82 (range: 62–98.9) (Table 2).

The anterior translation of the tibia in relation to the femur was found to be a mean of 2.09 mm in relation to the contralateral side (1–6 mm). One patient presented an increase in translation of 6 mm, relating to repeated tearing of the ACL, and underwent revision surgery after assessment and inclusion of the data for analysis.

Table 1 – Position of the Rigidfix pins in the lateral condyle in relation to the joint cartilage.

	Position of distal Rigidfix pin	Position of proximal Rigidfix pin
Extracartilage	16	32
Border of cartilage	9	–
Intracartilage	7	–

Table 2 – Relationship between the position of the distal Rigidfix pin and the mean Lysholm and subjective IKDC scores.

	Lysholm	Subjective IKDC
Intracartilage (n = 7)	89.85	79.95
Border of cartilage (n = 9)	88.33	89.28
Extracartilage (n = 16)	87.20	83.82

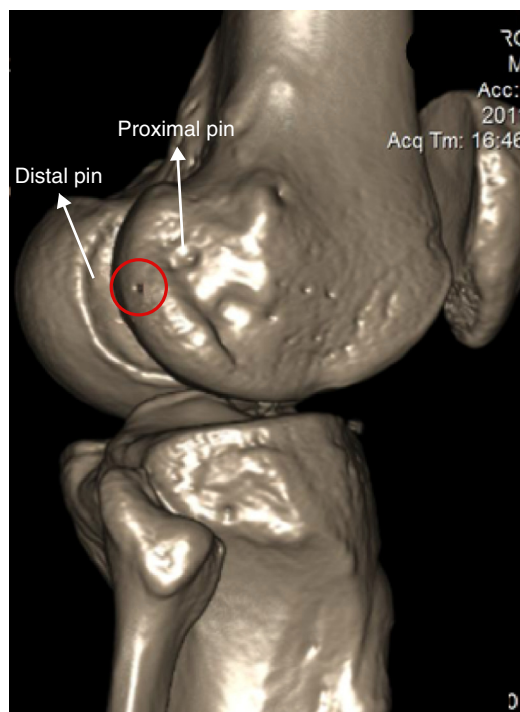


Fig. 3 – Tomographic image demonstrating the point of entry of the distal Rigidfix in the joint cartilage of the lateral face of the lateral femoral condyle.

Discussion

There are several surgical techniques and different fixation methods for ACL reconstruction surgery. However, none of these recreates the anatomy and tensional behavior of the fibers that make up the native ACL.¹⁴ The surgeon's objective in carrying out the ACL reconstruction procedure is simply to recreate the functional pattern of the ligament.¹⁵

The ideal positioning of the bone tunnels in ACL reconstruction surgery has been a subject of constant discussion in the literature. Some studies have shown that changes to the positioning of the femoral tunnel have a greater effect on the tensional behavior of the graft than do changes to the positioning of the tibial tunnel.^{15,16} Few fibers of the ACL are isometric throughout the range of motion of the knee.¹⁴ When a more isometric graft is desired, the femoral tunnel should be positioned as close as possible to the femoral insertion of the anteromedial band of the ACL.^{17,18}

There are three techniques that can be used for constructing the femoral tunnel within arthroscopic reconstruction of the ACL: the transtibial and anteromedial transportal techniques and use of both of these incisions, or the outside-in technique. In the transtibial technique, the femoral tunnel is constructed through the tibial tunnel and thus the positioning of the femoral tunnel is restricted by the positioning of the tibial tunnel. The tensional behavior of the neoligament is more isometric. However, there is a greater tendency toward posteriorization of the tibial tunnel and verticalization of the femoral tunnel, which does not seem to be a position that can be considered to be more anatomical.¹⁹ In the two-incision

technique, the bone tunnels are positioned independently, but an additional incision is needed in the lateral face of the femoral tunnel, with a femoral tunnel made along the entire lateral femoral condyle.⁸

The anteromedial transportal technique provides femoral tunnel positioning that is more anatomical and thus better rotational control and less chance of impact on the PCL during knee flexion.⁸ There is no need for additional incisions and the femoral tunnel is shorter than in the two-incision technique. With new concepts for femoral tunnel positioning, there is a need for new adaptation of the femoral fixation methods used and for graft fixation in a femoral tunnel that is more anatomical and lower and which has a point of entry in the medial wall of the lateral condyle.²⁰⁻²⁶ According to Chang et al.,²⁷ the current efforts for horizontalizing the femoral tunnel in the medial wall of the lateral condyle may compromise fixation using transverse-pin methods such as Rigidfix and lead to protrusion of these pins. The transverse fixation methods traditionally used were developed to be used by means of the anteromedial portal technique and they present a fixed angle of entry, which may put the lateral structures of the knee at risk, along with the joint surface of the lateral femoral condyle.^{4,20} In the present study, we chose to evaluate a series of patients in whom Rigidfix was used for fixation of a quadruple graft from the flexor tendons in a femoral tunnel, performed by means of an anteromedial portal. The Rigidfix system theoretically provides fixation that is more juxta-articular because of the presence of a second pin closer to the intra-articular opening of the femoral tunnel, in comparison with other transverse fixation methods. Moreover, it enables a greater area of bone-graft contact than do intratunnel fixation methods such as use of interference screws.^{7,20} Initially, Rigidfix was developed to provide fixation by means of the transtibial technique.⁶ According to Castoldi et al.,⁷ from a study on cadavers, the risk of chondral lesions through using this technique is high (between 80% and 100%), with at least one pin within the joint cartilage of the lateral femoral condyle. They therefore did not recommend using Rigidfix by means of the transportal technique for ACL reconstruction.

The present study was the first to have the objective of clinically evaluating patients who underwent ACL reconstruction by means of Rigidfix, used via an anteromedial portal. We observed that most of the patients presented satisfactory functional results within the short follow-up period evaluated. However, the risk of joint cartilage lesions needs to be taken into consideration. In 50% of the patients evaluated in this series, the point of entry of the distal Rigidfix pin was positioned outside of the cartilage. On the other hand, even in the patients in whom this point of entry was located on the border of the cartilage (Fig. 2) or within the cartilage (Fig. 3), the results from the functional clinical scores were considered to be satisfactory. In the other 50% of the patients, the distal pin was inserted at the border or within the joint cartilage, with some chondral lesions. This gives rise to the concern that, over the long term, knee arthrosis might be produced. Further studies with longer follow-up periods and large numbers of patients might be able to assess whether the presence of iatrogenic chondral lesions at the border of the joint cartilage interferes with the functional results.

This study presents some limitations. It was a descriptive study on preliminary results from a case series. A longer follow-up period and a larger number of patients, in a prospective study with a better design, are needed in order to obtain information of greater precision, with regard to whether the presence of chondral lesions in some patients is responsible for worsening of the clinical results.

Conclusion

The patients who underwent ACL reconstruction by means of the Rigidfix system with the anteromedial transportal technique presented a satisfactory clinical result. The risk of joint cartilage lesions due to the distal Rigidfix pin needs to be taken into consideration but, in the present study, the presence of chondral lesions did not interfere with the results over the short follow-up time evaluated.

Conflicts of interest

The authors declare no conflicts of interest.

REFERENCES

- Beynon BD, Johnson RJ, Abate JA, Fleming BC, Nichols CE. Treatment of anterior cruciate ligament injuries, part I. *Am J Sports Med.* 2005;33(10):1579-602.
- Webster KE, Feller JA, Hameister KA. Bone tunnel enlargement following anterior cruciate ligament reconstruction: a randomised comparison of hamstring and patellar tendon grafts with 2-year follow-up. *Knee Surg Sports Traumatol Arthrosc.* 2001;9(2):86-91.
- Cha PS, Chhabra A, Harner CD. Single-bundle anterior cruciate ligament reconstruction using the medial portal technique. *Oper Tech Orthop.* 2005;15:89-95.
- Gelber PE, Reina F, Torres R, Pelfort X, Tey M, Monllau JC. Anatomic single-bundle anterior cruciate ligament reconstruction from the anteromedial portal: evaluation of transverse femoral fixation in a cadaveric model. *Arthroscopy.* 2010;26(5):651-7.
- Gavriilidis I, Motsis EK, Pakos EE, Georgoulis AD, Mitsionis G, Xenakis TA. Transtibial versus anteromedial portal of the femoral tunnel in ACL reconstruction: a cadaveric study. *Knee.* 2008;15(5):364-7.
- Rodeo SA, Arnoczky SP, Torzilli PA, Hidaka C, Warren RF. Tendon-healing in a bone tunnel. A biomechanical and histological study in the dog. *J Bone Joint Surg Am.* 1993;75(12):1795-803.
- Castoldi F, Bonasia DE, Marmotti A, Dettoni F, Rossi R. ACL reconstruction using the Rigidfix femoral fixation device via the anteromedial portal: a cadaver study to evaluate chondral injuries. *Knee Surg Sports Traumatol Arthrosc.* 2008;16(3):275-8.
- Hantes ME, Dailiana Z, Zachos VC, Varitimidis SE. Anterior cruciate ligament reconstruction using the Bio-TransFix femoral fixation device and anteromedial portal technique. *Knee Surg Sports Traumatol Arthrosc.* 2006;14(5):497-501.
- Lysholm J, Gillquist J. Evaluation of knee ligament surgery results with special emphasis on use of a scoring scale. *Am J Sports Med.* 1982;10(3):150-4.
- Peccin MS, Ciconelli R, Cohen M. Questionário específico para sintomas do joelho Lysholm Knee Score Scale – Tradução e validação para a língua portuguesa. *Acta Ortop Bras.* 2006;14(5):268-72.
- Irrgang J. ACL outcomes. Paper presented at International Society of Arthroscopy, Knee Surgery and Orthopaedic Sports Medicine, 2001. Montreux, Switzerland: International Knee Documentation Committee; 2000. Available in http://www.udel.edu/PT/PT%20Clinical%20Services/journalclub/sojc/03_04/sep03/IKDC.pdf
- Ganko A, Engebretsen L, Ozer H. The rolimeter: a new arthrometer compared with the KT-1000. *Knee Surg Sports Traumatol Arthrosc.* 2000;8(1):36-9.
- Krackow KA, Thomas SC, Jones LC. A new stitch for ligament-tendon fixation. *J Bone Joint Surg Am.* 1986;68(5):764-6. Brief note.
- Van Eck CF, Lesniak BP, Schreiber VM, Fu FH. Anatomic single and double-bundle anterior cruciate ligament reconstruction flowchart. *Arthroscopy.* 2012;26(2):258-68.
- Hefzy MS, Grood ES, Noyes FR. Factors affecting the region of most isometric femoral attachments. Part II: the anterior cruciate ligament. *Am J Sports Med.* 1989;17(2):208-16.
- Woo SL, Kanamori A, Zeminski J, Yagi M, Papageorgiou C, Fu FH. The effectiveness of reconstruction of the anterior cruciate ligament with hamstrings and patellar tendon. A cadaveric study comparing anterior tibial and rotational loads. *J Bone Joint Surg Am.* 2002;84(6):907-14.
- Amis AA, Dawkins GP. Functional anatomy of the anterior cruciate ligament. Fibre bundle actions related to ligament replacements and injuries. *J Bone Joint Surg Br.* 1991;73(2):260-7.
- Bradley J, Fitzpatrick D, Daniel D, Shercliff T, O'Connor J. Orientation of the cruciate ligament in the sagittal plane. A method of predicting its length-change with flexion. *J Bone Joint Surg Br.* 1988;70(1):94-9.
- Arnold MP, Kooloos J, van Kampen A. Single-incision technique misses anatomical femoral anterior cruciate ligament insertion: a cadaver study. *Knee Surg Sports Traumatol Arthrosc.* 2001;9(4):194-9.
- Ahn JH, Park JS, Lee YS, Cho YJ. Femoral bioabsorbable cross-pin fixation in anterior cruciate ligament reconstruction. *Arthroscopy.* 2007;23(10):1093-9.
- Giron F, Cuomo P, Aglietti P, Bull AM, Amis AA. Femoral attachment of the anterior cruciate ligament. *Knee Surg Sports Traumatol Arthrosc.* 2006;14(3):250-6.
- Butler DL, Noyes FR, Grood ES. Ligamentous restraints to anterior-posterior drawer in the human knee. A biomechanical study. *J Bone Joint Surg Am.* 1980;62(2):259-70.
- Yagi M, Wong EK, Kanamori A, Debski RE, Fu FH, Woo SL. Biomechanical analysis of an anatomic anterior cruciate ligament reconstruction. *Am J Sports Med.* 2002;30(5):660-6.
- Engebretsen L, Lew WD, Lewis JL, Hunter RE, Benum P. Anterolateral rotator instability of the knee. Cadaver study of extraarticular patellar-tendon transposition. *Acta Orthop Scand.* 1990;61(3):225-30.
- Noyes FR. In comments to Engebretsen L, Lew WD, Lewis JL, Hunter RE, Benum P. Anterolateral rotatory instability of the knee. *Acta Orthop Scand.* 1990;61(3):225-30.
- Yasuda K, van Eck CF, Hoshino Y, Fu FH, Tashman S. Anatomic single- and double-bundle anterior cruciate ligament reconstruction, part 1: basic science. *Am J Sports Med.* 2011;39(8):1789-99.
- Chang CB, Yoo JH, Chung BJ, Seong SC, Kim TK. Oblique femoral tunnel placement can increase risks of short femoral tunnel and cross-pin protrusion in anterior cruciate ligament reconstruction. *Am J Sports Med.* 2010;38(6):1237-45.