

Invasive tracheobronchial aspergillosis progressing from bronchial to diffuse lung parenchymal lesions

Hiromitsu Ohta, Susumu Yamazaki, You Miura, Minoru Kanazawa, Fumikazu Sakai & Makoto Nagata

Department of Respiratory Medicine, Saitama Medical University, Saitama, Japan.

Keywords

Bronchoscopic examination, CT findings, invasive pulmonary aspergillosis, invasive tracheobronchial aspergillosis.

Correspondence

Hiromitsu Ohta, Department of Respiratory Medicine, Saitama Medical University, Iruma, Saitama 350-0495, Japan. E-mail: hoota@saitama-med.ac.jp

Received: 30 October 2015; Revised: 25 November 2015; Accepted: 25 November 2015.

Respirology Case Reports 2016; 4(1): 32–34

doi: 10.1002/rcr2.144

Abstract

Invasive tracheobronchial aspergillosis that is entirely limited or predominantly confined to tracheobronchial lesions is a relatively rare form of invasive pulmonary aspergillosis. Extended parenchymal opacities that are radiological manifestations of invasive aspergillosis sometimes occur following invasive tracheobronchial aspergillosis. However, it remains unclear whether or not invasive tracheobronchial aspergillosis is the initial stage of invasive pulmonary aspergillosis. A 61-year-old woman was admitted because of severe diarrhea and dehydration. Three days after admission, she complained of dyspnea. A computed tomography (CT) scan of the chest showed bronchial wall thickening. She developed respiratory failure despite antibiotic therapy. A CT scan showed obstructions of bronchial lumens and bronchiectasis in the right upper lobe. *Aspergillus fumigatus* was identified from samples obtained in bronchoscopic examination. Bronchial lesions rapidly progressed to be extended. *Aspergillus* infection with multiple parenchymal opacities was observed on CT scan. She responded to treatment with antifungal drugs.

Introduction

Invasive pulmonary aspergillosis (IPA) is a severe disease generally observed in immunocompromised patients such as those with hematological malignancies with neutropenia, bone-marrow transplantation recipients, solid-organ transplantation recipients, or those undergoing immune-suppressive therapy such as corticosteroid therapy. In most studies, the mortality rate of IPA is as high as 70–100%. IPA generally shows airway-centered lesions in 14–34% of cases. However, invasive tracheobronchial aspergillosis (ITBA), in which the infection is entirely limited or predominantly confined to tracheobronchial lesions, is a relatively rare form of IPA [1]. In some cases, isolated ITBA progressed to IPA with diffused lung parenchyma lesions [2]. We present a case of *Aspergillus* infection that progressed from minute bronchial lesions to diffuse lung parenchymal lesions over a short time.

Case Report

A 61-year-old woman was admitted with severe diarrhea and dehydration. She was a current smoker, with a history

of 40 pack-years. Her medical history showed monoclonal gammopathy of undetermined significance and chronic kidney disease, for which she had been visiting the nephrology department of our hospital monthly and receiving medical treatment for 5 years. Three days after admission, she developed a fever and hypoxia, complaining of dyspnea. A chest radiograph showed no abnormalities, but thoracic computed tomography (CT) showed thickening of bronchial walls, suggesting bronchitis (Fig. 1). Her respiratory distress progressed despite empirical antibiotic therapy. She was transferred to our section 25 days after admission. A chest radiograph showed infiltrative shadows and a cavity in the right middle lung field, while thoracic CT demonstrated consolidation along with obstructed bronchi. Distal portion of the obstructed bronchi showed cystic bronchiectatic lesions in the right upper lobe (Fig. 1). Laboratory findings showed an elevated leukocyte count of 18,370 cells/mm³ (neutrophil 84.3%, lymphocytes 10.6%, monocytes 3.0%, eosinophils 1.8%, basophils 0.3%). C-reactive protein level, 9.86 mg/dL; procalcitonin (PCT) level, 0.72 U/mL; serum albumin, 1.7g/dL; lactate dehydrogenase, 295 IU/L; creatinine 1.35 mg/dL; and

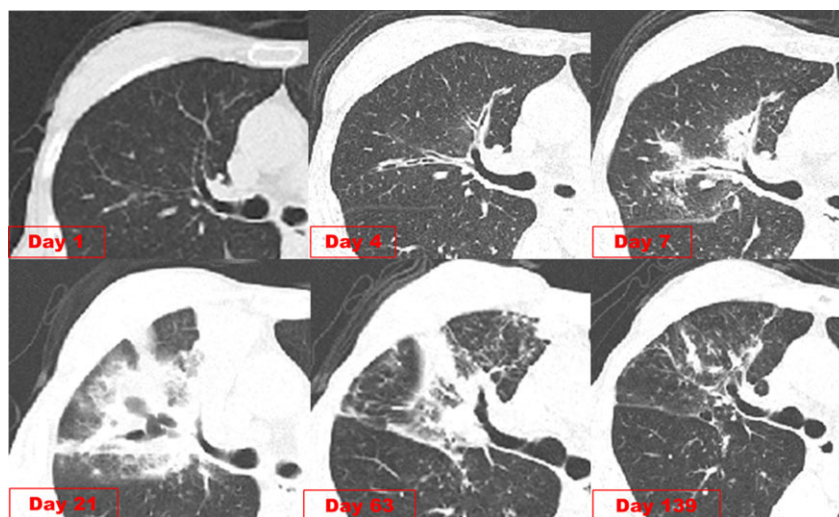


Figure 1. Thoracic computed tomography (CT) of the right upper lobe. The initial CT showed no abnormality. Four days after admission, CT showed increased thickness of the bronchial wall. In a short period, the bronchiole was obstructed and enlarged. Extended parenchymatous opacity was observed along the obstructed bronchi 7 days after admission. Twenty-one days after admission, progression of consolidation including cystic bronchiectatic lesions. Sixty-three days after admission, CT showed remarkable improvement of the infiltrative shadows. One hundred thirty-three days after admission, most infiltrative shadows had disappeared.

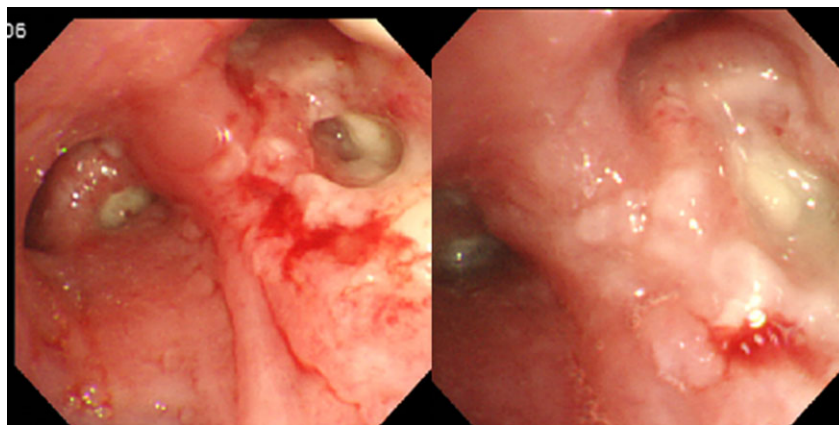


Figure 2. Bronchoscopic examination revealed extensive tissue necrosis and pseudomembrane formation in the right upper lobe bronchus. These bronchi were occluded by the membrane.

β -D-glucan, 236.9 pg/dL. The influenza antigen test was negative. Her IgG value was 1683 mg/dL and she was hepatitis B surface antigen negative, hepatitis C virus antibody negative, and human immunodeficiency virus antibody negative, with a CD4 positive cell count of 1044/ μ L. Her neutrophil function tests showed normal values. Considering the ineffectiveness of empirical antibiotic therapy and the elevated β -D-glucan level, a pulmonary fungal infection was suspected. Intravenous voriconazole was started. The patient underwent flexible bronchoscopy 27 days after admission, which revealed multiple, discrete whitish plaques involving the trachea and the right upper lobe bronchus (Fig. 2). A biopsy under bronchoscopy showed

chronic active inflammation with necrotic tissue, in which numerous filamentous fungal hyphae were seen. *Aspergillus fumigatus* was isolated from bronchial lavage fluid cultures. After administration of voriconazole, her symptoms and chest radiograph findings gradually improved. Thoracic CT showed remarkable improvement of the infiltrative shadows. The patient was discharged 70 days after admission.

Discussion

Based on the host–fungus relationship, tracheobronchial aspergillosis can be classified into three forms: allergic

disease, saprophytic infections, and invasive disease [1]. Invasive tracheobronchial aspergillosis (ITBA) without parenchymal disease is relatively rare, seen in less than 10% of IPA cases [3]. Based on the bronchoscopic and/or pathologic features, ITBA is classified into three subtypes; *Aspergillus* tracheobronchitis, ulcerative *Aspergillus* tracheobronchitis, and pseudomembranous *Aspergillus* tracheobronchitis.

Dennig et al. defined *Aspergillus* tracheobronchitis as a tracheobronchial disease caused by *Aspergillus* spp. It is characterized by bronchial/tracheal inflammation and excessive mucus production without invasion of the bronchial mucosa. It was originally described in three patients with acquired immunodeficiency syndrome and in a heart transplant recipient. Ulcerative *Aspergillus* tracheobronchitis is characterized by the presence of variable, ulcerative, or plaque-like lesions in the bronchial walls. Pseudomembranous *Aspergillus* tracheobronchitis is characterized by extensive involvement of the lower airways, with pseudomembranes coating the mucosal surface. Pseudomembranous *Aspergillus* tracheobronchitis sometimes occurs in immunocompetent patients and rapidly progresses to lung parenchymal involvement [4]. The macroscopic appearance of tracheobronchial lesion, however, may easily change, and these three forms may coexist. This classification is conceptual rather than practical.

In 2011, Wu et al. proposed a novel classification of isolated ITBA (iITBA) based on bronchoscopic findings [2]. Namely, iITBA is classified into four categories: type I, superficial infiltration; type II, full-layer involvement; type III, occlusive (air way occlusion $\geq 50\%$); and type IV, mixed. In their report, five patients died of uncontrolled iITBA, three with Type IV and two with Type II. All five patients showed full-thickness invasion of the involved bronchi. Full-thickness involvement of the bronchi is associated with increased morbidity or worse prognosis. iITBA may be considered as the early stage of *Aspergillus* invasion; without proper treatment, it can progress to more extensive and invasive forms.

Invasive pulmonary aspergillosis occurring in immunocompetent patients is sometimes associated with influenza infection [5]. In our case, the patient suffered from diarrhea and suspected viral infection; however, the serological test for influenza was negative.

In our case, the lesion progressed from mere tracheobronchial wall thickness to diffuse parenchymal lesions. We could observe the progression of disease on CT. The bronchial lesions obstructed the bronchi, caused atelectasis, and extended to the parenchymal lesions. Her bronchoscopic findings corresponded to type IV, based on the classification by Wu et al.

We reported this case because of the suggestive clinical course showing that iITBA can progress to IPA with extended parenchymal lesions within a short period.

Disclosure Statements

No conflict of interest declared.

Appropriate written informed consent was obtained for publication of this case report and accompanying images.

References

1. Krenke R, and Grabczak EM. 2011. Tracheobronchial manifestations of *Aspergillus* infections. *ScientificWorldJournal* 11:2310–2329.
2. Wu N, Huang Y, Li Q, et al. 2010. Isolated invasive *Aspergillus* tracheobronchitis: a clinical study of 19 cases. *Clin. Microbiol. Infect.* 16(6):689–695.
3. Fernandez-Ruiz M, Silva JT, San-Juan R, et al. 2012. *Aspergillus* tracheobronchitis: report of 8 cases and review of the literature. *Medicine* 91(5):261–273.
4. Li Y, Yu F, Parsons C, et al. 2013. Pseudomembranous *Aspergillus* tracheobronchitis: a potential for high mortality in low-risk patients. *Am. J. Med. Sci.* 346(5):366–370.
5. Wauters J, Baar I, Meersseman P, et al. 2012. Invasive pulmonary aspergillosis is a frequent complication of critically ill H1N1 patients: a retrospective study. *Intensive Care Med.* 38(11):1761–1768.