




## Letter to the Editor

# Recurrent Cytokine Storm in SARS-CoV-2 Infected Patients with Hematolymphoid Malignancy: A New Perspective

Sujeet Kamtalwar<sup>1</sup> Sumeet Mirgh<sup>2</sup>  Ashwini More<sup>1</sup> Palak Sharma<sup>3</sup>  
Nikhil Patkar<sup>4</sup> Sweta Rajpal<sup>4</sup> Gaurav Chatterjee<sup>4</sup>  
Nitin Shetty<sup>5</sup> Anant Gokarn<sup>2</sup>



Sujeet Kamtalwar

<sup>1</sup> Department of General Medicine, Advanced Centre for Treatment, Research & Education in Cancer (ACTREC), Navi Mumbai and Homi Bhabha National Institute (HBNI), Maharashtra, India

<sup>2</sup> Department of Medical Oncology, Advanced Centre for Treatment, Research & Education in Cancer (ACTREC), Navi Mumbai and Homi Bhabha National Institute (HBNI), Maharashtra, India

<sup>3</sup> Department of Medical Administration, Advanced Centre for Treatment, Research & Education in Cancer (ACTREC), Navi Mumbai and Homi Bhabha National Institute (HBNI), Maharashtra, India

<sup>4</sup> Department of Hematopathology Laboratory, Advanced Centre for Treatment, Research & Education in Cancer (ACTREC), Navi Mumbai and Homi Bhabha National Institute (HBNI), Maharashtra, India

<sup>5</sup> Department of Radiodiagnosis, Advanced Centre for Treatment, Research & Education in Cancer (ACTREC), Navi Mumbai and Homi Bhabha National Institute (HBNI), Maharashtra, India

**Address for correspondence** Sumeet Mirgh, MD, DM, Department of Medical Oncology Adult Hematolymphoid and BMT unit, Advanced Centre for Treatment, Research and Education in Cancer (ACTREC), Kharghar 410210, Navi Mumbai and Homi Bhabha National Institute (HBNI), Maharashtra 400094, India (e-mail: drsumeetmirgh@gmail.com).

**South Asian J Cancer 2024;13(2):157–162.**

Cancer patients, especially with hematological malignancies are at higher risk of contracting coronavirus disease 2019 (COVID-19) because of the immunosuppressed state both due to the malignancy and medications administered as a part of cancer management. Cytokine storm or acute respiratory distress syndrome (ARDS) is the major cause of deaths due to COVID-19. However, delayed cytokine storm can be seen until 21 days of illness. Herein, we report two patients of hematolymphoid malignancy with COVID-19 who had recurrent cytokine storm which is uncommon.

India alone has witnessed over 41 million cases of COVID-19 with approximately 1.19% mortality.<sup>1</sup> Though severe acute respiratory syndrome coronavirus 2 (SARS-CoV-2) may be asymptomatic or present with mild symptoms in majority, patients can progress to ARDS. Seventeen studies from 2,486 hospitals over 5 countries performed from the beginning of the pandemic to July 2020 reported a variable incidence of ARDS in SARS-CoV-2 infection ranging from 2 to 68%.<sup>2</sup> Most cases with COVID-19 and ARDS were either

elderly or having comorbidities.<sup>3</sup> According to a meta-analysis<sup>4</sup> performed in 2020, cancer patients with COVID-19 infection were associated with a 28% day-28 mortality, much higher as compared with noncancer patients. We reported from our institute that cancer patients have 10 times higher mortality as compared with noncancer patients (10% vs. 1.1%).<sup>5</sup> However, repeated episodes of ARDS in the same patient have not been described in literature. We present here two case scenarios of patients with B cell non-Hodgkin lymphoma (B-NHL) who presented with two discrete episodes of severe COVID-19 with cytokine storm with an interim asymptomatic period.

## Case 1

A 73-year-old male patient with relapsed B-NHL tested positive for SARS-CoV-2, with a 3-day history of fever and cough. Considering a high-risk patient in view of elderly age and relapsed malignancy, he was hospitalized. On admission,

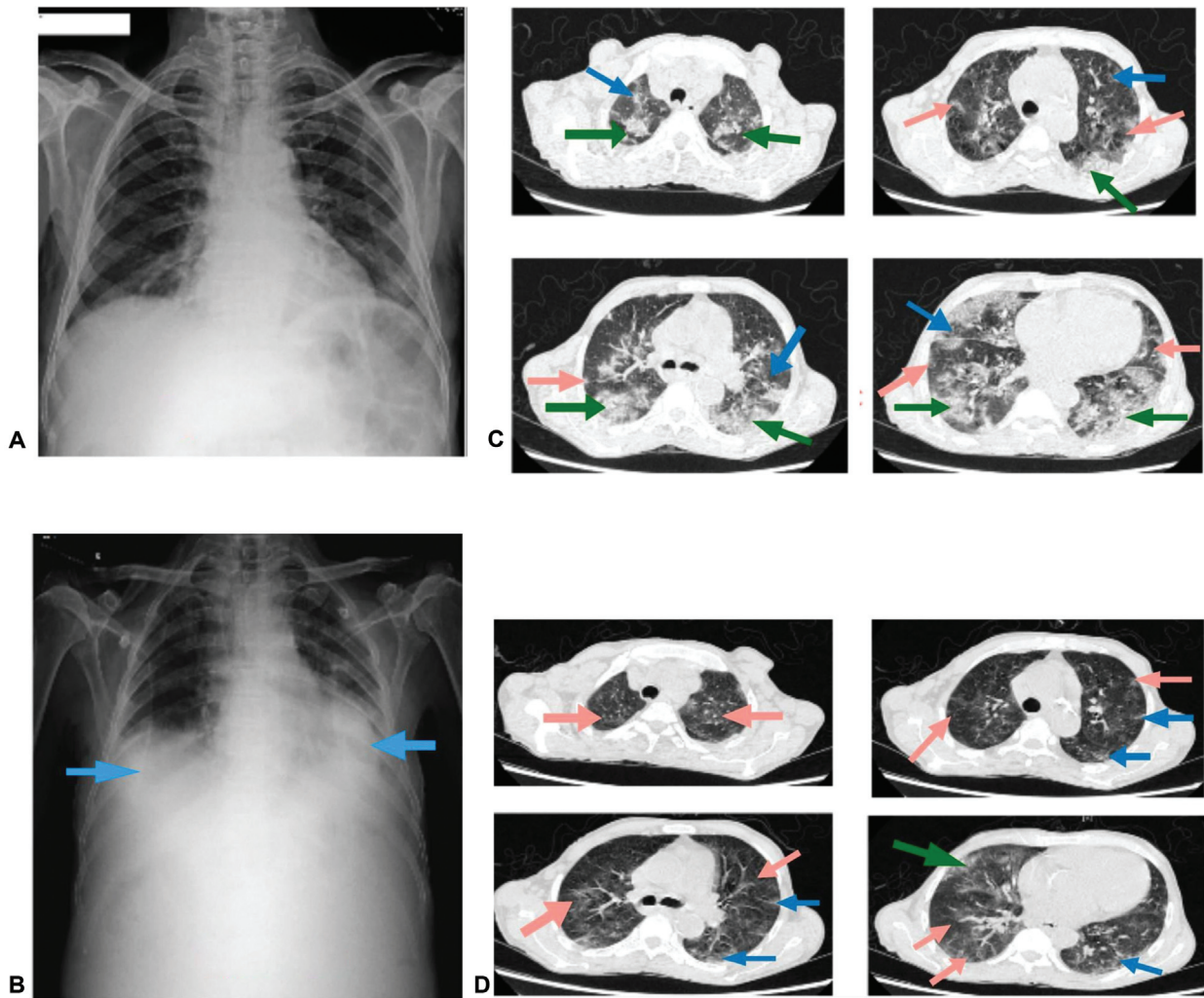
DOI <https://doi.org/10.1055/s-0043-1761443> ISSN 2278-330X

**How to cite this article:** Kamtalwar S, Mirgh S, More A, et al. Recurrent Cytokine Storm in SARS-CoV-2 Infected Patients with Hematolymphoid Malignancy: A New Perspective. *South Asian J Cancer* 2024;13(2):157–162.

© 2023. MedIntel Services Pvt Ltd. All rights reserved.

This is an open access article published by Thieme under the terms of the Creative Commons Attribution-NonDerivative-NonCommercial-License, permitting copying and reproduction so long as the original work is given appropriate credit. Contents may not be used for commercial purposes, or adapted, remixed, transformed or built upon. (<https://creativecommons.org/licenses/by-nc-nd/4.0/>)

Thieme Medical and Scientific Publishers Pvt. Ltd., A-12, 2nd Floor, Sector 2, Noida-201301 UP, India



**Fig. 1** (A) No significant findings. (B) Right basal, left mid and basal opacities. (C) Multifocal patches of ground-glass opacities (orange arrow) with associated inter- and intralobular septal thickening (blue arrow), few of which are forming patches of subsegmental consolidation (green arrow), are seen scattered in predominantly peripheral, subpleural locations. (D) Significant decrease with fibrotic changes in the multifocal patches of ground-glass opacities with associated inter- and intralobular septal thickening. Near-complete resolution of patches of subsegmental consolidation.

he had mild COVID-19 (score 5 as per ordinal scale)<sup>6</sup> with a normal chest X-ray (→ Fig. 1A). On day 4 of SARS-CoV-2 positivity, he had worsening of his respiratory symptoms (dyspnea Modified Medical Research Council [MMRC] grade 5) with hypoxia (oxygen saturation [SpO<sub>2</sub>] of 90% on room air) (severe COVID-19 [score 3]). Cardiac workup for an acute coronary event was negative. Imaging showed bilateral lung infiltrates (→ Fig. 1B). He was treated with oxygen support by high-flow nasal cannula (HFNC), intravenous remdesivir (5 days), and dexamethasone (6 mg). He responded well to treatment and required oxygen support for a period of 9 days. Dexamethasone was administered for 6 days, as per data from RECOVERY trial.<sup>7</sup> After an asymptomatic duration of 3 days and a normal 6-minute walk test, he was discharged in stable condition on day 15 of SARS-CoV-2 positivity and was kept on twice-a-day telephonic follow-up.

Seventy-two hours after discharge (day 18 of SARS-CoV-2 positivity), he reported having low grade fever (maximal temperature 100°F) with minimal cough. On day 22 of positivity, he was readmitted in view of exertional dyspnea

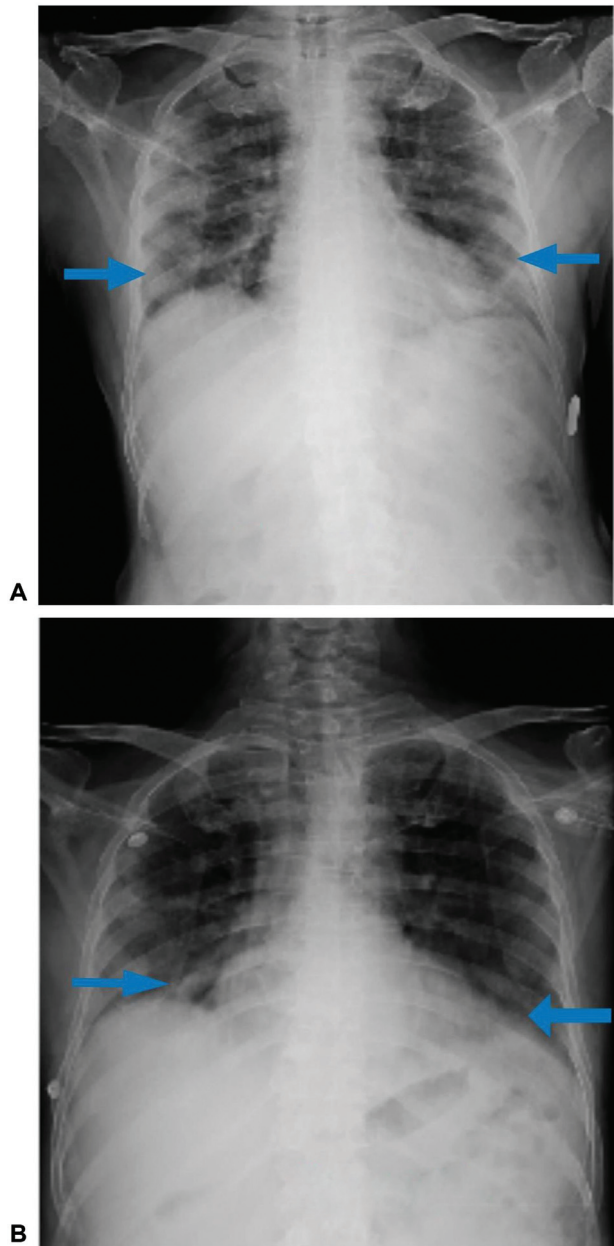
(MMRC grade 5). On admission, he was tachypneic (respiratory rate 36 cycles/minute) and hypoxic (SpO<sub>2</sub> 86–88% on room air). In view of recent history of steroids and immunocompromised status, suspecting the possibility of secondary bacterial infection, he was administered broad-spectrum antibiotics (intravenous meropenem and teicoplanin) empirically, pending culture reports. However, after 3 days of admission, he required escalation of oxygen support with HFNC in view of worsening respiratory distress. Chest imaging with high-resolution computerized tomogram (HRCT) revealed multifocal ground-glass opacities (GGOs) with inter- and intralobular septal thickening in all segments of both the lungs (→ Fig. 1C). These findings were suggestive of severe COVID-19 pneumonia with a CT-severity score of 18 out of 25. In view of diffuse infiltrates on imaging and elevated inflammatory markers (increased interleukin [IL-6], C-reactive protein [CRP]) with negative cultures, he was diagnosed to have cytokine storm due to severe COVID-19.

Our patient developed a second episode of ARDS and merited treatment with anti-inflammatory agents. In view

of a recurrent cytokine storm in spite of prior receipt of dexamethasone within 2 weeks, and rationale for better lung penetration of methylprednisolone,<sup>8</sup> our patient was treated with intravenous methylprednisolone (40 mg once daily–1 mg/kg). Taking into consideration the scarcity of tocilizumab in COVID-19 pandemic and recent evidence for utility of bevacizumab in severe COVID-19<sup>9</sup> at the time of patient management, he was given a single dose of intravenous bevacizumab 400 mg. Similar to first admission, prophylactic anticoagulation with enoxaparin was continued. Patient responded well to the combination of steroids plus bevacizumab. Over the next 96 hours, he improved with resolution of tachypnea and his oxygen support was gradually tapered (total oxygen duration 14 days). His methylprednisolone was tapered at a dose of 10 mg every fourth day (total steroid duration of 17 days). Repeat HRCT thorax on day 43 of SARS-CoV-2 positivity showed significant improvement of GGOs, without any pulmonary fibrosis (–Fig. 1D). After 19 days of hospitalization (day 45), he was discharged in a stable hemodynamic condition with advice for chest physiotherapy. On last outpatient follow-up on day 148, he continues to be well and asymptomatic.

## Case 2

A 72-year-old male, diagnosed with chronic lymphocytic leukemia (CLL), required treatment in view of symptomatic bulky abdominal lymphadenopathy. Ten days after his second chemotherapy cycle (R-CVP – rituximab, cyclophosphamide, vincristine, prednisolone), he required admission for severe COVID-19 infection (COVID score 3 on admission). In view of severe COVID-19 (–Fig. 2A), he was treated with remdesivir, oxygen support with HFNC, and tocilizumab (400 mg – 8 mg/kg intravenously). Defervescence was achieved within 24 hours of tocilizumab, and over the next 4 days, he gradually improved with weaning of oxygen support and clearance of infiltrates on imaging. After an asymptomatic interval of 3 days (day 11 of positivity), he was discharged in a hemodynamically stable condition after 10 days of hospitalization. While on regular follow-up, he was asymptomatic. Since it was necessary to treat him for his CLL, a repeat swab was done after 3 weeks of initial SARS-CoV-2 positivity. He tested negative for SARS-CoV-2 on two occasions, 3 days apart. Hence, he was given a third chemotherapy cycle with R-CVP. Two weeks after his third chemotherapy cycle (day 42 of initial SARS-CoV-2 positivity), he complained of fever and breathlessness for 1 day, requiring readmission. On admission, he was dyspneic with SpO<sub>2</sub> of 78% on room air. Oxygen support with HFNC and broad-spectrum antibiotics were initiated. He tested positive for SARS-CoV-2. Presence of elevated CRP and IL-6, with new-onset bilateral infiltrates (–Fig. 2B), without any signal on blood cultures and normal procalcitonin, in the absence of an alternate cause, pointed to the possibility of a cytokine storm due to severe COVID-19. Hence, in addition to broad-spectrum antibiotics, we treated him with parenteral steroids (dexamethasone 6 mg) and a second course of intravenous remdesivir (second time). Prophylactic enoxaparin was



**Fig. 2** (A) Bilateral predominantly basal opacities. (B) Right-sided mid-basal opacities, left-sided basal opacities.

given during both the admissions for the duration of hospital stay. His fever and tachypnea improved within 72 hours of steroid administration. He was weaned off his oxygen over a period of 9 days. He responded well to the treatment and was discharged after 11 days of hospitalization. He remained well on his last outpatient follow-up on day 30 postdischarge (day 41 of second SARS-CoV-2 positivity). Considering his age, frailty, and two episodes of life-threatening pulmonary infections, he was put on supportive care after a detailed discussion with the family.

In this case, the patient tested negative in between his two hospital admissions which were on day 23 and day 27 post first SARS-CoV-2 positivity. While we considered the second report as a possibility of reinfection at the time of patient management, however, recently released Indian Council of

**Table 1** Laboratory values and treatment received for both patients during first and second admission

Parameters	Patient 1		Patient 2	
	1st admission	2nd admission	1st admission	2nd admission
Day of positivity on admission	Day 1	Day 27	Day 1	Day 38
CT value at diagnosis	N gene 21.6 E gene 21.8	N gene 26.5 E gene 26.35	N gene 24.6 E gene 24.9	N gene 32.3 E gene 33.4
Day of positivity on discharge	Day 15	Day 45	Day 11	Day 49
Hb (g/dL)	7.9 g/dL	9.6 g/dL	11.6 g/dL	13.4 g/dL
TLC	$1.59 \times 10^9/L$	$5.0 \times 10^9/L$	$0.77 \times 10^9/L$	$3.70 \times 10^9/L$
ANC	$0.64 \times 10^9/L$	$3.96 \times 10^9/L$	$0.06 \times 10^9/L$	$2.78 \times 10^9/L$
ALC	$0.82 \times 10^9/L$	$0.82 \times 10^9/L$	$0.42 \times 10^9/L$	$0.69 \times 10^9/L$
Platelets	$87 \times 10^9/L$	$198 \times 10^9/L$	$256 \times 10^9/L$	$387 \times 10^9/L$
CRP (0–0.33 mg %)	3.0 mg%	6.8 mg%	6.0 mg%	8.2 mg%
Procalcitonin (< 0.05 ng/mL)	0.16 ng/mL	0.10 ng/mL	< 0.05 ng/ml	< 0.05 ng/mL
IL-6 (0–4.4 pg/mL)	94.6 pg/mL	39.4 pg/mL	53.4 pg/mL	6.9 pg/mL
D-dimer (< 255 ng/mL)	640 ng/mL	< 200 ng/mL	233 ng/mL	< 200 ng/mL
Oxygen support	High-flow nasal cannula	High-flow nasal cannula	Nasal oxygen at 4 L/min	High-flow nasal cannula
Antibiotics	Meropenem, Cefoperazone + sulbactam	Meropenem, Cefoperazone + sulbactam, teicoplanin	Cefepime-tazobactam	Meropenem, teicoplanin
Antivirals	Remdesivir	No	Remdesivir	Remdesivir
Steroids	Yes, Dexamethasone (6 mg for 6 d)	Yes, Methylprednisolone (40 mg for 5 d f/b tapering doses over total 17 d)	No	Yes, Dexamethasone (6 mg for 6 d)
Anti-inflammatory therapy	No	Yes, bevacizumab	Yes, tocilizumab	No
Anticoagulation	Yes, enoxaparin	Yes, enoxaparin	Yes, enoxaparin	Yes, enoxaparin
Outcome	Recovered, alive	Recovered, alive	Recovered, alive	Recovered, alive
SARS-CoV-2 antibody	NA	NA	Negative	Negative

Abbreviations: ALC, absolute lymphocyte count; ANC, absolute neutrophil count; CRP, C-reactive protein; CT value, cycle threshold value; f/b, followed by; Hb, hemoglobin; IL-6, interleukin 6; NA, not applicable; SARS-CoV-2, severe acute respiratory syndrome coronavirus 2; TLC, total leucocyte count.

Medical Research guidelines (reinfection means two positive SARS-CoV-2 PCR reports 102 days apart, with a negative molecular test in between) refute that likelihood.<sup>10</sup> ▶ **Table 1** shows laboratory values and treatment received for both patients during first and second admission.

Cytokine storm in COVID-19 is a known complication causing severe respiratory failure. Cytokine storm does not have a standard definition. It is a very wide term encompassing constitutional symptoms, mostly high-grade fever and fatigue. Manifestations of cytokine storm occur because of immune cell-mediated damage. Mostly, there is dysregulation between stimulatory pathways and inhibitory pathways. Cytokine storm or hyperinflammation can occur in absence of a pathogen, for example, in genetic diseases like Castleman's disease, with an inappropriate response to the pathogen causing excess immune cell activation, higher

pathogen burden, and failure of inhibitory pathways. The diagnosis of a cytokine storm can be supported with elevated cytokine levels, elevated IL levels, and increased acute phase reactants such as CRP, ferritin, and low albumin. Cytokine levels are elevated during a cytokine storm. As cytokines have a very short half-life, it is not necessary to have elevated cytokine levels on every instance of disease. Thus, any cytokine storm can cause collateral organ damage (liver, lung, kidney, brain) which can lead to multiorgan dysfunction and death.

The immunosuppressed state of cancer patients increases their risk of infection as compared with the general population. As per Liang et al,<sup>11</sup> patients with cancer have an increased risk of severe COVID-19 with greater than 3.5-fold increase in risk of mechanical ventilation, intensive care unit admission or death. Interestingly, cancer has been

shown to have a synergistic effect on mortality, because the death rate was greater than the sum of their individual effects. The death rate was 14.93% in cancer and COVID-19 infection, much more as compared with 5.26% in noncancer patients.<sup>8</sup> A meta-analysis reported the overall case-fatality rate among COVID-19 patients with cancer was 22.4%.<sup>12</sup> A study from India has reported that among patients with hematological malignancies, elderly patients with severe COVID-19, with disease not in remission have the worst outcomes.<sup>13</sup>

Prolonged detection of SARS-CoV-2 has been described in literature in hemato-oncology patients, especially those with lymphomas.<sup>14,15</sup> However, the clinical consequences of the same are not fully understood. Cases with a prolonged course of COVID-19 disease in patients treated with rituximab, have been described in literature.<sup>16-18</sup> Similarly, a recent multicenter retrospective French study showed that age > 70 years, relapsed-refractory disease, and rituximab therapy were risk factors for prolonged hospital stay of > 30 days. This reiterates the importance of humoral immunity, and persistent viral infection due to an inability to generate SARS-CoV-2 antibodies, consequent to B cell depletion.<sup>16,19</sup> However, both of our cases developed recurrent episodes of severe COVID-19, akin to a cytokine storm, with an interim asymptomatic period, including documentation of SARS-CoV-2 negativity in the second patient. Similar to another case,<sup>19</sup> we too used two courses of remdesivir, with clinical benefit in our second patient. Importantly, both of our patients were unvaccinated. Whether we would see such disease kinetics in vaccinated patients on rituximab is unknown.

Elderly lymphoma patients on rituximab therapy are prone for persistent SARS-CoV-2 positivity. Hence, in case of recurrence of symptoms, the possibility of severe COVID-19 should not be excluded, only on the basis of history of a recently treated infection.

#### Declaration of Patient Consent

The authors certify that they have obtained all appropriate patient consent forms. In the form the patient has given his consent for his images and other clinical information to be reported in the journal. The patient understands that his name and initials will not be published and due efforts will be made to conceal his identity, but anonymity cannot be guaranteed.

The manuscript has been read and approved by all the authors, that the requirements for authorship have been met, and that each author believes that the manuscript represents honest work.

#### Conflict of Interest

None declared.

#### References

- 1 Accessed January 31, 2022, at: <https://www.mohfw.gov.in/>
- 2 Tzozos SJ, Fischer B, Fischer H, Zeitlinger M. Incidence of ARDS and outcomes in hospitalized patients with COVID-19: a global literature survey. *Crit Care* 2020;24(01):516
- 3 Sanyaolu A, Okorie C, Marinkovic A, et al. Comorbidity and its impact on patients with COVID-19. *SN Compr Clin Med* 2020;2(08):1069-1076
- 4 Assaad S, Zrounba P, Cropet C, Blay JYONCOVID-19 study Consortium. Mortality of patients with solid and haematological cancers presenting with symptoms of COVID-19 with vs without detectable SARS-CoV-2: a French nationwide prospective cohort study. *Br J Cancer* 2021;125(05):658-671
- 5 Mirgh SP, Gokarn A, Rajendra A, et al. Clinical characteristics, laboratory parameters and outcomes of COVID-19 in cancer and non-cancer patients from a tertiary cancer centre in India. *Cancer Med* 2021;10(24):8777-8788
- 6 Goldman JD, Lye DCB, Hui DS, et al; GS-US-540-5773 Investigators. Remdesivir for 5 or 10 days in patients with severe Covid-19. *N Engl J Med* 2020;383(19):1827-1837
- 7 Horby P, Lim WS, Emberson JR, et al; RECOVERY Collaborative Group. Dexamethasone in hospitalized patients with Covid-19. *N Engl J Med* 2021;384(08):693-704
- 8 Ranjbar K, Moghadami M, Mirahmadizadeh A, et al. Methylprednisolone or dexamethasone, which one is superior corticosteroid in the treatment of hospitalized COVID-19 patients: a triple-blinded randomized controlled trial. *BMC Infect Dis* 2021;21(01):337
- 9 Pang J, Xu F, Aondio G, et al. Efficacy and tolerability of bevacizumab in patients with severe Covid-19. *Nat Commun* 2021;12(01):814
- 10 Mukherjee A, Anand T, Agarwal A, et al. SARS-CoV-2 re-infection: development of an epidemiological definition from India. *Epidemiol Infect* 2021;149:e82
- 11 Liang W, Guan W, Chen R, et al. Cancer patients in SARS-CoV-2 infection: a nationwide analysis in China. *Lancet Oncol* 2020;21(03):335-337
- 12 Zhang H, Han H, He T, et al. Clinical characteristics and outcomes of COVID-19-infected cancer patients: a systematic review and meta-analysis. *J Natl Cancer Inst* 2021;113(04):371-380
- 13 Borah P, Mirgh S, Sharma SK, et al; AIIMS Hematology Alumni Group. Effect of age, comorbidity and remission status on outcome of COVID-19 in patients with hematological malignancies. *Blood Cells Mol Dis* 2021;87:102525
- 14 Shah V, Ko Ko T, Zuckerman M, et al. Poor outcome and prolonged persistence of SARS-CoV-2 RNA in COVID-19 patients with haematological malignancies; King's College Hospital experience. *Br J Haematol* 2020;190(05):e279-e282
- 15 Avanzato VA, Matson MJ, Seifert SN, et al. Case study: prolonged infectious SARS-CoV-2 shedding from an asymptomatic immunocompromised individual with cancer. *Cell* 2020;183(07):1901-1912.e9
- 16 Kos I, Balensiefer B, Roth S, et al. Prolonged course of COVID-19-associated pneumonia in a B-cell depleted patient after rituximab. *Front Oncol* 2020;10:1578
- 17 Yasuda H, Tsukune Y, Watanabe N, et al. Persistent COVID-19 pneumonia and failure to develop anti-SARS-CoV-2 antibodies during rituximab maintenance therapy for follicular lymphoma. *Clin Lymphoma Myeloma Leuk* 2020;20(11):774-776
- 18 Baang JH, Smith C, Mirabelli C, et al. Prolonged severe acute respiratory syndrome coronavirus 2 replication in an immunocompromised patient. *J Infect Dis* 2021;223(01):23-27
- 19 Helleberg M, Niemann CU, Moestrup KS, et al. Persistent COVID-19 in an immunocompromised patient temporarily responsive to two courses of remdesivir therapy. *J Infect Dis* 2020;222(07):1103-1107

