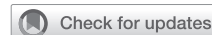

Transcatheter mitral valve repair clip embolization to the right coronary artery



Jonathan Nitz, MD, Manish Karamchandani, MD, Tina Phan, BS, Phil Carpino, PA-C, and Gregory Couper, MD, Boston, Mass

From the Department of Cardiac Surgery, Tufts Medical Center, Boston, Mass.

Read at the American Association for Thoracic Surgery Mitral Conclave 2023, New York, New York, May 4-5, 2023.

Received for publication May 4, 2023; revisions received July 25, 2023; accepted for publication July 30, 2023; available ahead of print Sept 19, 2023.

Address for reprints: Jonathan Nitz, MD, Department of Cardiac Surgery, Tufts Medical Center, 2 Sigmund St, Lynnfield, MA 01940 (E-mail: Jonathan.Nitz@gmail.com).

JTCVS Techniques 2023;22:118-9
2666-2507

Copyright © 2023 The Author(s). Published by Elsevier Inc. on behalf of The American Association for Thoracic Surgery. This is an open access article under the CC BY-NC-ND license (<http://creativecommons.org/licenses/by-nc-nd/4.0/>).

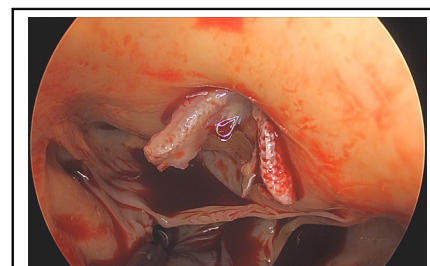
<https://doi.org/10.1016/j.jtc.2023.07.029>

To view the AATS Annual Meeting Webcast, see the URL next to the webcast thumbnail.

Although transcatheter mitral repair with MitraClip (Abbott) has been deemed a safe procedure for high-risk surgical populations, it does carry the possibility of complications. MitraClip procedure complications can be categorized as procedural (related to the deployment itself) or device-related and can result in reintervention, extended hospital stay, and increased mortality.¹ Among the rarest structural complications is MitraClip embolization, in which the entire MitraClip or a fragment embolizes into the left ventricle or out of the heart. Two cases of right coronary artery (RCA) embolization have been reported, both of which were treated nonsurgically by catheter-based methods, were not successful in seeing the patient to discharge.^{2,3} We describe a patient who experienced MitraClip embolization to the ostium of the RCA, resulting in non-ST segment elevation myocardial infarction (NSTEMI) from occlusion of the RCA, as well as refractory severe mitral regurgitation (MR) and congestive heart failure. The patient provided written informed consent for publication of study data; institutional review board approval was not required.

HISTORY

The patient is a 65-year-old morbidly obese man with severe MR, hypertrophic cardiomyopathy, nonobstructive coronary artery disease, atrial fibrillation, prior transient ischemic attack, hypertension, and asthma. He was deemed to be a poor surgical candidate because of these comorbidities and the patient wanted to avoid surgery at nearly any cost. He was treated for his MR with 2 MitraClips in the A1-P1 and A2-P2 positions with improvement in his MR



The Mitraclip can be seen embolized to the right coronary artery ostium.

CENTRAL MESSAGE

Although rare, MitraClip embolization can be life-threatening. We report the treatment of 1 such case as the only survival to discharge in the literature.

to mild. Although his 2 MitraClips were still firmly implanted on the mitral apparatus, the patient developed further dilation of the left ventricle with functional MR, prompting return a year later for reintervention. A third MitraClip was placed in the A1-P1 location. The repair was deemed satisfactory, and his symptoms improved.

Six months after the second MitraClip application, he presented to an outside hospital with 24-hour history of severe shortness of breath with minimal exertion. His workup included computed tomography of the chest, and cardiac catheterization (Figure 1). A MitraClip was identified in the RCA ostium. A transesophageal echocardiogram confirmed this along with an iatrogenic atrial septal defect (ASD), severe MR, and severe right ventricle dysfunction. He was eventually transferred to our institution after several days at outside hospitals.

He was medically optimized and then taken to the operating room urgently. After initiating cardiopulmonary bypass, the aorta was crossclamped, and the heart was arrested. The aorta was opened and the MitraClip was immediately seen embedded in the ostium of the RCA (Figure 2). The device was easily removed with no obvious adverse sequelae. However, a No. 3 probe could not be passed via the ostium. Due to concern for thrombus beyond the opening, the RCA was bypassed using a saphenous vein graft. When irrigating the coronary in a retrograde fashion, minimal

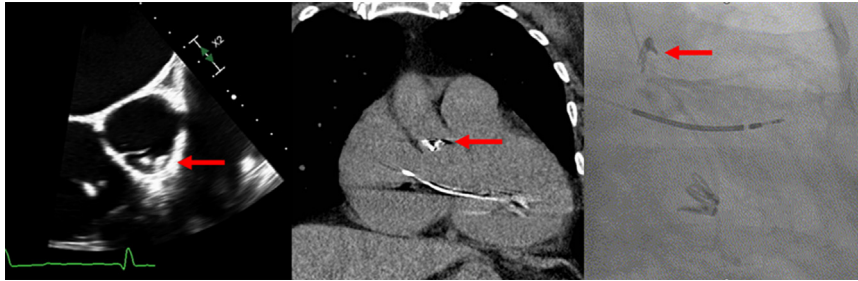


FIGURE 1. Echo, CT, and cardiac catheterization images demonstrating the MitraClip embolized to the RCA ostium. The embolized device is indicated by the red arrow.

flow was noted out the RCA ostium. Attention was turned to the mitral valve. Operative findings include 2 disassociated MitraClips located on A2 with several segments of P2 disrupted. He underwent a mitral valve replacement with 31/33 mm On-X Mechanical Valve (Artivion Inc), and his moderate tricuspid regurgitation was treated with a 34-mm Medtronic Simulus Band. He also had ligation of left and right atrial appendages, Cox IV maze, and ASD closure.

While attempting to come off bypass, a hematoma was noted in the left ventricle and on further inspection a small tear was noted adjacent to the RCA ostium requiring a patch repair with bovine pericardium and externally knotted Prolene stitches. It was hypothesized that the clip may have partially eroded into the coronary wall creating a weak area that ruptured once the aortic root was pressurized again.

He had a prolonged intensive care unit stay due to inotrope and epoprostenol weans, transferring to the general ward on postoperative day 5. His hospital course was complicated by acute kidney injury that resolved by discharge on postoperative day 11. Follow-up at 6 months showed recovery from surgery and resolution of symptoms. A poor-quality echocardiogram was performed but could not evaluate the mitral valve. It did show a severely dysfunctional right ventricle consistent with the preoperative findings and the chronicity of his RCA occlusion, despite our efforts to protect the right ventricle by bypassing the vessel.

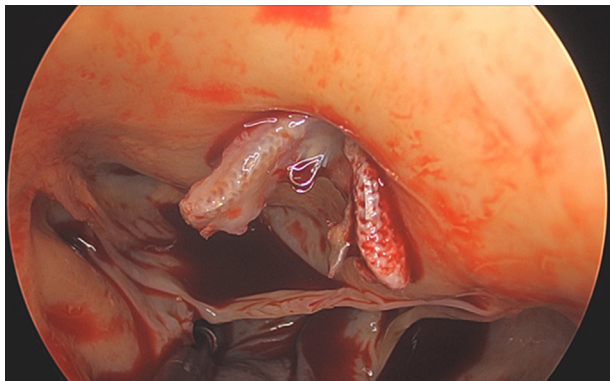


FIGURE 2. The Mitraclip can be seen embolized to the right coronary artery ostium.

DISCUSSION

Embolization of MitraClip is a rare complication.¹ There have been 2 other reports of MitraClip embolization to the coronary artery.^{2,3} Both patients had significant comorbidities. Both patients had the embolized MitraClip captured and removed via catheter-based methods, and neither survived the hospitalization. The first patient developed progressive refractory cardiogenic shock with multiorgan failure despite support and died within 2 days. The second patient died due to sepsis 2 weeks after clip retrieval. The latter also needed thrombolysis to the right coronary due to presumed thrombosis, correlating with concerns we had in our case.

CONCLUSIONS

We describe successful surgical management of a patient after MitraClip embolization of the coronary artery.

Webcast

You can watch a Webcast of this AATS meeting presentation by going to: <https://www.aats.org/resources/mitra-clip-embolization-to-the-rca-a-rare-and-potentially-devastating-complication-a-case-report>.



Conflict of Interest Statement

The authors reported no conflicts of interest.

The *Journal* policy requires editors and reviewers to disclose conflicts of interest and to decline handling manuscripts for which they may have a conflict of interest. The editors and reviewers of this article have no conflicts of interest.

References

1. Schnitzler K, Hell M, Geyer M, Kreidel F, Münzel T, von Bardeleben RS. Complications following Mitraclip implantation. *Curr Cardiol Rep.* 2021;23:131.
2. Chitsaz S, Jumean M, Dayah T, Rajagopal K, Kar B. Late Mitraclip embolization: a new cause of ST-segment-elevation myocardial infarction. *Circ Cardiovasc Interv.* 2016;9:e004271.
3. Schueler R, Jensen C, Wolf A, Schmitz T. Acute occlusion of the right coronary artery: an unusual case. *Eur Heart J.* 2018;39:4126.