

Daptomycin for the Treatment of Gram-Positive Periprosthetic Hip Infections: Can Daptomycin Prevent the Implant Removal?

Kenichi Oe¹, Masahiro Sawada¹, Tomohisa Nakamura¹, Hirokazu Iida¹, Takanori Saito¹

1. Department of Orthopaedic Surgery, Kansai Medical University, Hirakata, JPN

Corresponding author: Kenichi Oe, oeken@hirakata.kmu.ac.jp

Abstract

Introduction

Management of periprosthetic hip infections (PHIs) generally consists of implant removal and thorough debridement, accompanied by appropriate antibiotic therapy. Daptomycin (DAP) is a novel antibiotic, which allowed for implant retention in several patients after treating their infected joints. However, there is no consensus about implant retention or removal during the treatment of PHIs. The aim of this study was to examine the effect of DAP and to determine a surgical treatment strategy.

Methods

This study retrospectively evaluated 20 patients between August 2014 and December 2018, divided into implant retention (n=9) and implant removal groups (n=11). Infection control and risk of recurrent infection were evaluated. Infection control was defined as not requiring implant removal after the final treatment.

Results

Infection control rates in implant retention and implant removal groups were 67% and 90%, respectively. All late chronic infections resulted in failure cases within the implant retention group. In the implant retention group, mean preoperative risk scores for successful cases were significantly higher than those for failure cases ($p < 0.05$).

Conclusions

Patients with low risk did not require implant removal, suggesting that DAP may be a breakthrough alternative to traditional PHI management.

Categories: Infectious Disease, Orthopedics

Keywords: daptomycin, periprosthetic joint infection, implant retention, infection control rates, preoperative risk scores

Introduction

The gold standard for managing periprosthetic joint infection (PJI) generally consists of implant removal and thorough debridement, accompanied by appropriate antibiotic therapy. According to the guidelines for the management of PJIs by the Infectious Diseases Society of America (IDSA) [1], the probability of implant retention is limited; only patients diagnosed with a PJI who (1) have a well-fixed prosthesis without a sinus tract and (2) are within approximately 30 days of prosthesis implantation or less than three weeks from the onset of infectious symptoms should be considered for debridement and retention of the prosthesis. However, there is no consensus for the treatment of PJIs regarding the choice of specific antibiotic therapy.

Daptomycin (DAP) could be an option for PJI treatment because it exerts bactericidal activity against Gram-positive bacteria, including multiple-resistant isolates, and stationary-phase bacteria in biofilm present on implants [2]. DAP is currently available as a novel antibiotic therapy worldwide; the European Registry demonstrated high clinical success in PJI treatment with DAP therapy, including implant retention in 56% of patients [3]. However, PJI treatment with implant retention remains controversial and challenging. The aim of this study was to examine the effect of DAP on implant retention in patients with periprosthetic hip infection (PHI) and to determine a surgical treatment strategy. The hypothesis of the study was that DAP would prevent implant removal for patients with low-risk PHIs.

This article was previously published in a preprint server (<https://www.researchsquare.com/article/rs-6833/v1>).

Materials And Methods

How to cite this article

Oe K, Sawada M, Nakamura T, et al. (June 22, 2021) Daptomycin for the Treatment of Gram-Positive Periprosthetic Hip Infections: Can Daptomycin Prevent the Implant Removal?. Cureus 13(6): e15842. DOI 10.7759/cureus.15842

Review began 05/25/2021

Review ended 06/13/2021

Published 06/22/2021

© Copyright 2021

Oe et al. This is an open access article distributed under the terms of the Creative Commons Attribution License CC-BY 4.0., which permits unrestricted use, distribution, and reproduction in any medium, provided the original author and source are credited.

Study population

Between August 2014 and December 2018, 33 patients provided with DAP (Cubicin®, MSD K.K., Tokyo, Japan) as a treatment for a PHI at our institution. DAP was administered when an infection was suspected, right after aspiration of the joint for subsequent cell culture. However, some of those patients changed the antibiotic treatment to a more appropriate one after the identification of the pathogen. In cases where no identification was made by joint aspiration, DAP therapy was initiated, and if the C-reactive protein (CRP) levels decreased, the treatment continued. Thus, a retrospective study for the treatment of infections caused by Gram-positive pathogens with DAP was conducted in only 20 patients (follow-up rate of 100%; Figure 1). In accordance with the IDSA guideline [1], the implant retention was initially selected, but the final decision was made intraoperatively by the surgeons. Rifampicin (RFP) was added whenever possible, and other antibiotics were not used with DAP therapy.

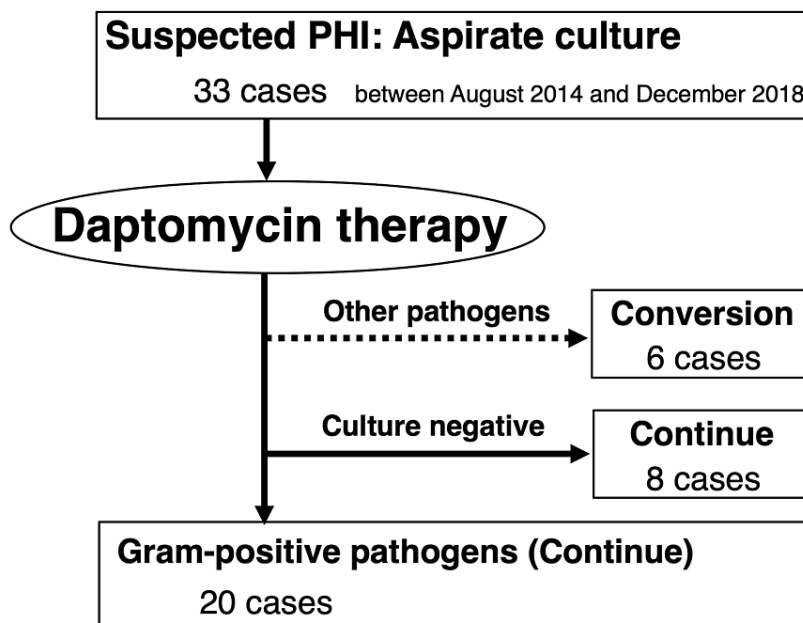


FIGURE 1: Study flowchart.

PHI, periprosthetic hip infection.

Surgical options included implant retention in 9 patients (no surgery in four and only debridement in five) and implant removal in 11 patients (one-staged and two-staged revisions in three and eight, respectively). The implant retention group included three men and six women, with a mean age of 69 years (range: 36-85 years) and a mean follow-up period of 24 months (6-39 months). The mean duration of DAP therapy was 30 days (12-106 days), at a mean daily dose of 5.6 mg/kg/day (3.8-8.3 mg/kg/day). The implant removal group included four men and seven women, with a mean age of 69 years (53-88 years) and a mean follow-up period of 23 months (4-50 months). The mean duration of DAP therapy was 37 days (1-60 days), at a mean daily dose of 5.8 mg/kg/day (3.8-10.0 mg/kg/day; Table 1). During DAP therapy, adverse events including increased creatine phosphokinase or decreased renal function were monitored. After DAP therapy, we switched to oral antibiotics depending on the pathogen and susceptibility when the decreased CRP level was continued. The study was approved by our institutional review board. All patients provided informed consent for study participation and publication of findings.

Characteristics	Implant retention	Implant removal	p-value
Number of joints	9	11	
Mean age at surgery, years (range)	69 (36–85)	69 (53–88)	0.580 ^a
Gender, male/female	3:6	4:7	0.630 ^b
Mean follow-up period, months (range)	24 (6–39)	23 (4–50)	0.061 ^a
Number of patients previously administered with other antibiotics	7	9	0.625 ^b
Mean dose, mg/kg/day (range)	5.8 (3.8–8.3)	5.8 (3.8–10.0)	0.313 ^a
Mean duration of daptomycin therapy, day (range)	30 (12–106)	37 (1–60)	0.095 ^c
Number of patients administered with rifampicin	7	8	0.604 ^b
Infected implant			0.579 ^b
Bipolar hip arthroplasty	1	2	
Total hip arthroplasty	8	9	
Surgical intervention during this therapy, number			
None	4	0	0.026 ^b
Only debridement	5	0	0.008 ^b
One-staged revision	0	3	0.145 ^b
Two-staged revision	0	8	0.001 ^b

TABLE 1: Preoperative patient characteristics.

^aStudent t-test.

^bFisher exact test.

^cMann-Whitney U test.

Bacterial infection diagnosis

PHI was diagnosed according to the criteria of the Musculoskeletal Infection Society [4]. PHI was classified into four clinical categories: type I (early postoperative infection), type II (late chronic infection), type III (acute hematogenous infection), and type IV (positive intraoperative cultures) [5,6]. An early postoperative infection was defined as a wound infection that developed less than one month after surgery. A late chronic infection corresponded to an infection that developed one month or more after the index operation and that had an insidious clinical course. Acute hematogenous infection was associated with a documented or suspected antecedent bacteremia and was characterized by an acute onset of symptoms in the affected joint with the prosthesis. A patient was considered to be in the type IV group if at least two specimens obtained at the time of revision surgery were positive on culture.

Patients follow-up

After antibiotic administration, patients were followed up at weeks: 1, 2, 3, 4, 8, and 12, at months 6 and 9, at one year, and annually thereafter. Data were retrospectively analyzed by two orthopedic surgeons who were blinded to the treatment regimens. Pathogens causing PHIs, reasons for the discontinuation of an antibiotic, and infection control rates were evaluated. Infection control was defined as the lack of clinical signs, symptoms, and radiological signs of infection, a CRP level <10 mg/L, an erythrocyte sedimentation rate <20 mm/h, and not requiring implant removal after the final treatment. Therefore, a successful case was defined as one not requiring implant removal after treatment; failure was defined as implant removal due to recurrent infection.

Clinical parameters

For the laboratory assessment, CRP levels (mg/L) were investigated. Furthermore, the risk of recurrent infection was evaluated using the scoring system (Figure 2) [7], based on six parameters: (1) general condition, (2) duration of infection, (3) wound complication, (4) presence of microorganisms, (5) CRP levels, and (6) necessity for bone grafting. Each parameter was rated from 0 to 2 points, giving a maximum score of 12 points for low-risk.

Criterion	Points (Total = 12)
1. General condition	
Poor (American Society of Anesthesiologists's class ≥ 3 , etc.)	0
Moderate (Diabetes Mellitus, Steroid, Autoimmune disease, etc.)	1
Good	2
2. Duration of infection, Number of past operations	
Past operations ≥ 2 (including Osteotomy, Debridement, etc.)	0
Late infection	1
Early or Delayed infection	2
3. Wound complication after initial operation	
Sinus tract, Abscess	0
Slightly damaged (reddish, local heat, etc.)	1
Intact	2
4. Presence of microorganism	
Organism resistance to the antibiotics, Gram-negative, MRSA or MRSE	0
Unknown	1
Organism sensitive to the antibiotics	2
5. C-reactive protein (mg/L)	
> 50	0
50-5	1
< 5	2
6. Necessity for bone grafting	
Necessity	0
Unnecessity	2

FIGURE 2: Pre-operative scoring system to assess the risk of recurrent infection.

Each parameter was rated from 0 to 2 points, giving a maximum score of 12 points for low-risk.

Statistical analysis

Two-group comparisons were conducted using the Student t-test or Mann-Whitney U test. To compare qualitative variables, Fisher's exact test was applied. The Wilcoxon signed-rank test was used to compare differences in parameters before and after patient treatment. Statistical significance was defined as $p < 0.05$. All analyses were performed using SAS 9.2 (SAS Institute Inc., Cary, NC, USA).

Results

The summary of results for each patient is shown in Table 2. In one patient (case 14), DAP was discontinued because of an anaphylactic shock, and statistical analyses were performed except in case 14. Other adverse events have not occurred. Infection control rates in the implant retention and implant removal groups were 67% (6/9) and 90% (9/10), respectively. Clinical success rates of the implant removal group were significantly higher than those of the implant retention group ($p < 0.05$). In case of no methicillin-resistant bacteria, infection control rates in the implant retention and implant removal groups were 60% (3/5) and 67% (2/3), respectively. In the case of methicillin-resistant bacteria, infection control rates in the implant retention and implant removal groups were 75% (3/4) and 100% (7/7), respectively. In the implant retention group, successful cases experienced type I (three patients) and type III (three patients) infections, whereas failure cases only presented type II infections (three patients). The mean daily dose of DAP (mg/kg/day) in the implant retention group was 5.0 (3.8-5.9) and 7.1 (5.9-8.3) for successful and failure cases, respectively. Similarly, in the implant removal group, DAP daily dose was 5.9 (3.8-10.0) and 5.8 for successful and failure cases, respectively.

Case	Age/gender	Infected implant	Pathogen	Infection type ^a	Duration of DAP (day)	DAP daily dose (mg/kg/day)	Preoperative scoring	Surgical intervention	Additional surgery or adverse event
1	81/female	THA	<i>Streptococcus sp.</i>	III	15	4.2	9	No surgery	(-)
2	75/female	THA	CNS	III	16	5.1	8	No surgery	(-)
3	77/female	BHA	MRCNS	I	12	5.3	7	No surgery	(-)
4	62/female	THA	MRSE	II	14	8.3	7	No surgery	Two-staged revision
5	36/male	THA	MRSE	I	27	5.9	8	Only debridement	(-)
6	64/male	THA	<i>Staphylococcus sp.</i>	III	36	5.7	8	Only debridement	(-)
7	85/male	THA	MRSA	I	27	3.8	7	Only debridement	(-)
8	64/female	THA	<i>Streptococcus sp.</i>	II	19	5.9	6	Only debridement	Two-staged revision
9	75/female	THA	CNS	II	106	7.0	6	Only debridement	Two-staged revision
10	76/female	THA	<i>Streptococcus sp.</i>	II	49	7.6	10	One-staged revision	(-)
11	88/male	BHA	MRSE	III	22	5.3	8	One-staged revision	(-)
12	82/female	THA	MSSE, CNS	II	31	3.8	7	One-staged revision	(-)
13	62/female	THA	MSSE	I	42	6.0	8	Two-staged revision	(-)
14	55/female	THA	MSSA	I	1	4.4	8	Two-staged revision	Anaphylaxis
15	66/male	BHA	MRSE	I	60	4.5	7	Two-staged revision	(-)
16	53/male	THA	MSSA	II	25	4.9	7	Two-staged revision	(-)
17	62/male	THA	CNS	II	31	5.0	7	Two-staged revision	(-)
18	65/female	THA	MRSE	II	57	10.0	6	Two-staged revision	(-)
19	74/female	THA	MRSA	II	48	5.8	6	Two-staged revision	(-)
20	74/female	THA	<i>Streptococcus sp.</i>	II	44	5.8	5	Two-staged revision	Two-staged revision

TABLE 2: Characteristics and results of each patient infected with Gram-positive pathogens before and after DAP treatment.

DAP: daptomycin, THA: total hip arthroplasty, BHA: bipolar hip arthroplasty, CNS: coagulase-negative *Staphylococcus*, MRCNS: methicillin-resistant coagulase-negative *Staphylococcus*, MRSE: methicillin-resistant *Staphylococcus epidermidis*, MRSA: methicillin-resistant *S. aureus*, MSSE: methicillin-sensitive *S. epidermidis*, MSSA: methicillin-sensitive *S. aureus*.

^aInfection type: type I (early postoperative infection), type II (late chronic infection), type III (acute hematogenous infection), and type IV (positive intraoperative cultures).

The mean CRP values for each group were recorded for eight weeks, and the results were grouped according to the outcome of the DAP treatment (success or failure) for each group (Figure 3). CRP levels in all cases, except for the failure case in the implant removal group, were significantly decreased. Mean preoperative risk scores of the implant retention group were 7.8 points (7-9 points) and 6.3 points (6-7 points) for successful and failure cases, respectively. Mean preoperative risk scores for successful cases were significantly higher than those for failure cases ($p < 0.05$). In the implant removal group, the score for success and failure cases were 7.3 points (6-10 points) and 5.0 points, respectively.

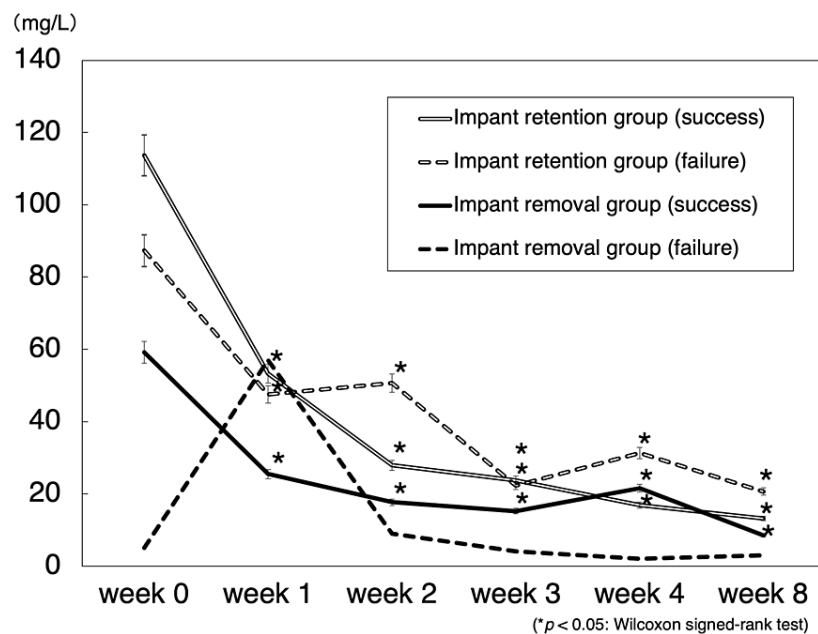


FIGURE 3: Mean C-reactive protein concentration in patients infected with Gram-positive bacteria and treated with DAP.

The Wilcoxon signed-rank test was used to compare differences before and after treatment of patients. Data are expressed as the means and two-sided 95% confidence interval.

Additionally, antibiotic conversion to DAP was observed in some cases. A one-staged revision was performed in one patient (case 12) because of acetabular cup loosening and dislocation due to PHI. After DAP therapy, the treatment continued its normal course (Figures 4 and 5).

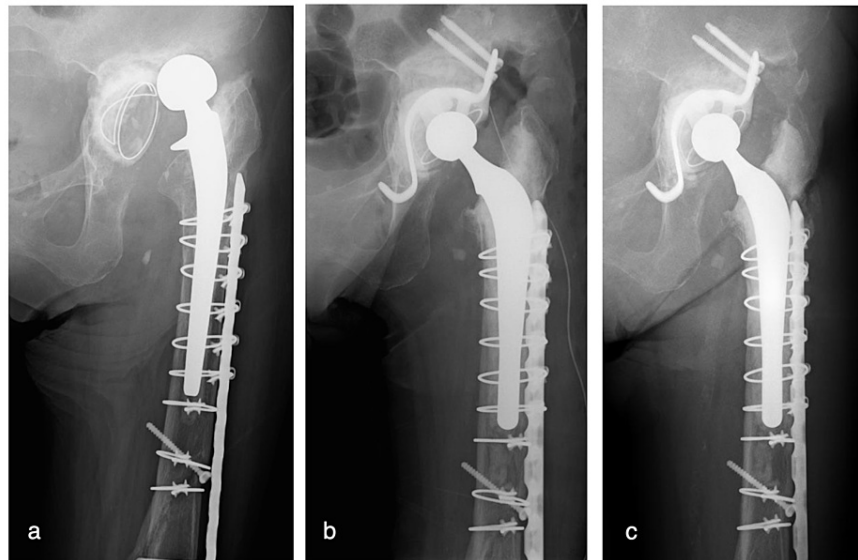


FIGURE 4: Anteroposterior hip radiographs of an 82-year-old woman who underwent primary THA 14 years ago and revision THA 1 year ago, with rheumatoid arthritis and hemodialysis (case 12, preoperative score of 7 points).

(a) Radiograph showing acetabular cup loosening and dislocation due to periprosthetic hip infection; (b) radiograph immediately after one-staged revision THA, including cup and stem; (c) radiograph at four years postoperatively. THA: total hip arthroplasty.

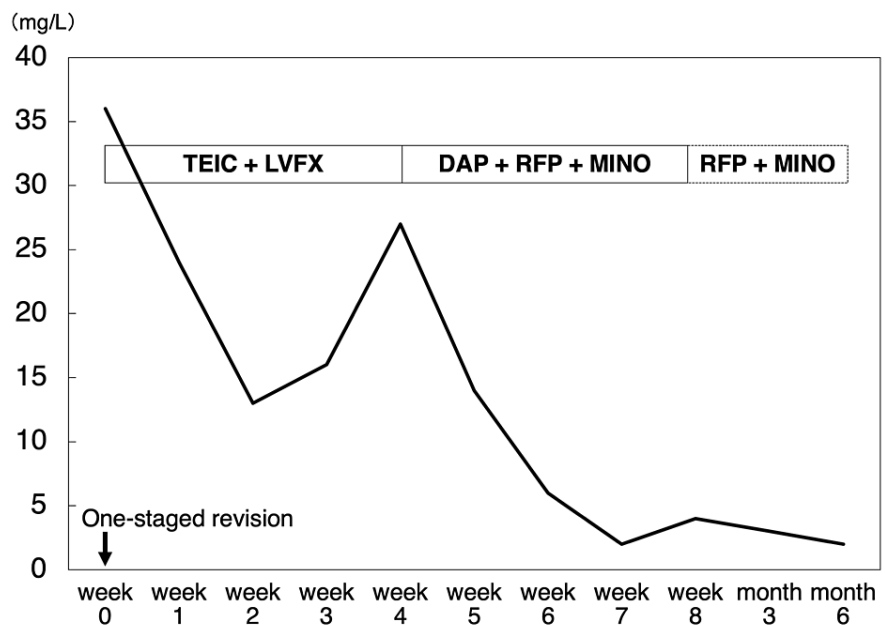


FIGURE 5: Treatment course and C-reactive protein concentration after DAP therapy in case 12.

TEIC: teicoplanin, LVFX: levofloxacin, DAP: daptomycin, RFP: rifampicin, MINO: minocycline hydrochloride.

Discussion

The frequency of PJIs is increasing, according to the Nordic Arthroplasty Register Association [8], and the treatment of PJIs should target Gram-positive pathogens because such organisms cause the majority of PJIs, and especially those that became antibiotic-resistant [9-12]. In Japan, the proportion of Gram-positive PJIs is over 70%, while 42% of those are methicillin-resistant *S. aureus* (MRSA) [9]. In Europe and the United States, more than 50% of PJIs are typically caused by staphylococcal organisms; and this percentage value is expected to increase [11,12]. The increased frequency of Gram-positive infections and the rise in resistance to commonly used antibiotics have led to the need for novel antibiotic therapies, such as DAP, which has high antimicrobial penetration into biofilms with low bactericidal concentration [13]. According to the European Registry, DAP was effective and safe in patients with osteomyelitis or those with orthopedic device infections; it was also a valuable treatment option for the management of Gram-positive infections [3,14]. However, in the treatment of PJIs by using DAP, there is no consensus on whether the implant should be removed or not.

In the current study, the clinical success rates in the implant removal group were significantly higher than those in the implant retention group. However, the patients without chronic late infection and with a score higher than 7 points did not require implant removal. Tsukayama et al. [5] analyzed the relationship between clinical settings and outcomes in 106 patients with PHIs and reported that all patients with early postoperative infections (success rates: 71%) or acute hematogenous infection (success rates: 50%) had the only debridement, while all patients with late chronic infection (success rates: 85%) were subjected to revision arthroplasty. Therefore, patients with late chronic infections may not be approved for implant retention even if DAP is administered.

Past reports of DAP treatment of PJI are shown in Table 3, and even some authors recommended the use of high-dose of DAP for the treatment of PJI with implant retention [2,15-21]. Furthermore, the European Registry demonstrated high clinical success with DAP therapy, including both implant retention (56%) and removal (44%). Additionally, patients receiving both DAP and RFP showed higher success rates than those who did not concomitantly receive RFP [3]. Interestingly, in vitro experiments showed that DAP had the fastest eradication rate for MRSA embedded in a biofilm; therefore, the combination of DAP and RFP may be a promising treatment option for implant-associated MRSA infections [22,23]. Moreover, the combination of high-dose DAP (equivalent to 8-10 mg/kg/day in humans) and RFP was highly effective for the treatment of foreign body-related MRSA infections [24,25]. Lora-Tamayo et al. [19] also analyzed 18 Staphylococcal PJIs in a multicenter study and concluded that high-dose DAP (10 mg/kg/day) plus RFP was a good initial treatment for PJIs with implant retention. In the current study, however, the mean daily dose of DAP for successful cases of implant retention was not always high, although RFP was administered whenever possible. Either way, RFP may be an important addition to consider when treating PJIs with DAP, with or without implant removal.

Author	Year published	Number of joints	Daily dose of daptomycin (mg/kg/day)	Infection control rates	
				Implant retention	Implant removal
Rao and Regalla [2]	2006	11	4	25% (1/4)	71% (5/7)
Antony et al. [15]	2008	30	6	None	67% (20/30)
Licitra et al. [16]	2010	14	≥6	100% (3/3)	100% (11/11)
Corona Pérez-Cardona et al. [17]	2012	14	6.6	100% (5/5)	67% (6/9)
Jugun et al. [18]	2013	13	≥8	100% (4/4)	100% (9/9)
Lora-Tamayo et al. [19]	2014	18	10	50% (9/18)	None
Kuo et al. [20]	2016	22	6	None	100% (22/22)
Chang et al. [21]	2017	16	8.3	80% (4/5)	91% (10/11)
Current study		19 (hips)	5.8	67% (6/9)	90% (9/10)

TABLE 3: Past reports of daptomycin treatment of periprosthetic joint infections.

Some limitations of our study must be noted. First, the sample size was small, involving only 20 individuals, due to the difficulties of obtaining a larger patient sample from a single institution. Furthermore, the current study was not performed as a randomized controlled trial. Patients with refractory PHIs required treatment on a case-by-case basis; therefore, the optimal surgical intervention and daily DAP dose also differed.

Second, some patients, who did not undergo implant removal after treatment, continued to take other antibiotics orally. As a consequence, because they did not undergo implant removal, they may have actually experienced recurrent infections. Third, we administered DAP when a PHI was suspected prior to the identification of the specific pathogen because such organisms cause the majority of PHIs, and DAP still works in presence of antibiotic resistance. However, such an approach may lead to the administration of excessive levels of antibiotics if treatments need to be switched to a more appropriate antibiotic after pathogen identification.

Conclusions

Infection control rates in the implant retention and implant removal groups were 67% and 90%, respectively. Late chronic infection was the infection type for all the failure cases in the implant retention group. Furthermore, in the implant retention group, the mean preoperative risk score for the successful cases was significantly higher than that for the failure cases. Patients with low-risk, who did not present chronic late infection but received a preoperative risk score higher than 7 points, may not require implant removal, suggesting that DAP may be a breakthrough alternative to traditional PHI management.

Additional Information

Disclosures

Human subjects: Consent was obtained or waived by all participants in this study. Kansai Medical University Review Board issued approval H160737. This study was approved by our institutional review board. **Animal subjects:** All authors have confirmed that this study did not involve animal subjects or tissue. **Conflicts of interest:** In compliance with the ICMJE uniform disclosure form, all authors declare the following: **Payment/services info:** All authors have declared that no financial support was received from any organization for the submitted work. **Financial relationships:** All authors have declared that they have no financial relationships at present or within the previous three years with any organizations that might have an interest in the submitted work. **Other relationships:** All authors have declared that there are no other relationships or activities that could appear to have influenced the submitted work.

References

- Osmon DR, Berbari EF, Berendt AR, et al.: Diagnosis and management of prosthetic joint infection: clinical practice guidelines by the Infectious Diseases Society of America. *Clin Infect Dis*. 2013, 56:e1-e25. [10.1093/cid/cis803](https://doi.org/10.1093/cid/cis803)
- Rao N, Regalla DM: Uncertain efficacy of daptomycin for prosthetic joint infections: a prospective case series. *Clin Orthop Relat Res*. 2006, 451:34-7. [10.1097/01.blo.0000224021.73163.61](https://doi.org/10.1097/01.blo.0000224021.73163.61)
- Malizos K, Sarma J, Seaton RA, et al.: Daptomycin for the treatment of osteomyelitis and orthopaedic device infections: real-world clinical experience from a European registry. *Eur J Clin Microbiol Infect Dis*. 2016, 35:111-8. [10.1007/s10096-015-2515-6](https://doi.org/10.1007/s10096-015-2515-6)
- Parvizi J, Zmistowski B, Berbari EF, et al.: New definition for periprosthetic joint infection: from the Workgroup of the Musculoskeletal Infection Society. *Clin Orthop Relat Res*. 2011, 469:2992-4. [10.1007/s11999-011-2102-9](https://doi.org/10.1007/s11999-011-2102-9)
- Tsukayama DT, Estrada R, Gustilo RB: Infection after total hip arthroplasty. A study of the treatment of one hundred and six infections. *J Bone Joint Surg Am*. 1996, 78:512-23. [10.2106/00004623-199604000-00005](https://doi.org/10.2106/00004623-199604000-00005)
- Cui Q, Mihalko WM, Shields JS, Ries M, Saleh KJ: Antibiotic-impregnated cement spacers for the treatment of infection associated with total hip or knee arthroplasty. *J Bone Joint Surg Am*. 2007, 89:871-82. [10.2106/JBJS.E.01070](https://doi.org/10.2106/JBJS.E.01070)
- Oe K, Iida H, Ueda N, Nakamura T, Okamoto N, Ueda Y: Pre-operative scoring system to determine the surgical strategy for periprosthetic hip infection. *Int Orthop*. 2015, 39:19-25. [10.1007/s00264-014-2493-9](https://doi.org/10.1007/s00264-014-2493-9)
- Dale H, Fenstad AM, Hallan G, et al.: Increasing risk of prosthetic joint infection after total hip arthroplasty. *Acta Orthop*. 2012, 83:449-58. [10.3109/17453674.2012.733918](https://doi.org/10.3109/17453674.2012.733918)
- Yamamoto K, Masaoka T, Ishii Y, et al.: Epidemiology of surgical site infection following implant surgery. *Orthop Surg Traumatol*. 2010, 53:419-25.
- Tande AJ, Patel R: Prosthetic joint infection. *Clin Microbiol Rev*. 2014, 27:302-45. [10.1128/CMR.00111-13](https://doi.org/10.1128/CMR.00111-13)
- Aggarwal VK, Bakhshi H, Ecker NU, Parvizi J, Gehrke T, Kendoff D: Organism profile in periprosthetic joint infection: pathogens differ at two arthroplasty infection referral centers in Europe and in the United States. *J Knee Surg*. 2014, 27:399-406. [10.1055/s-0033-1364102](https://doi.org/10.1055/s-0033-1364102)
- Kapadia BH, Berg RA, Daley JA, Fritz J, Bhavs A, Mont MA: Periprosthetic joint infection. *Lancet*. 2016, 387:386-94. [10.1016/S0140-6736\(14\)61798-0](https://doi.org/10.1016/S0140-6736(14)61798-0)
- Tiemersma EW, Bronzwaer SL, Lyytikäinen O, et al.: Methicillin-resistant *Staphylococcus aureus* in Europe, 1999-2002. *Emerg Infect Dis*. 2004, 10:1627-34. [10.3201/eid1009.040069](https://doi.org/10.3201/eid1009.040069)
- Gonzalez-Ruiz A, Gargalianos-Kakolyris P, Timerman A, et al.: Daptomycin in the clinical setting: 8-year experience with Gram-positive bacterial infections from the EU-CORE(SM) registry. *Adv Ther*. 2015, 32:496-509. [10.1007/s12325-015-0220-6](https://doi.org/10.1007/s12325-015-0220-6)
- Antony SJ, Tiscareno-Grajeda I, Misenhiemer G, Heyderman J: Use of daptomycin in the treatment of prosthetic joint infections: A prospective observational study of 30 patients with infected prosthetic joint infections. *Internet J Infect Dis*. 2008, 7:6.
- Licitra CM, Crespo A, Licitra D, Wallis-Crespo M: Daptomycin for the treatment of osteomyelitis and prosthetic joint infection: Retrospective analysis of efficacy and safety in an outpatient infusion center. *Internet J Infect Dis*. 2010, 9:9.
- Corona Pérez-Cardona PS, Barro Ojeda V, Rodríguez Pardo D, Pigrau Serrallach C, Guerra Farfán E, Amat

- Mateu C, Flores Sanchez X: Clinical experience with daptomycin for the treatment of patients with knee and hip periprosthetic joint infections. *J Antimicrob Chemother.* 2012, 67:1749-54. [10.1093/jac/dks119](https://doi.org/10.1093/jac/dks119)
18. Jugun K, Vaudaux P, Garbino J, Pagani L, Hoffmeyer P, Lew D, Uçkay I: The safety and efficacy of high-dose daptomycin combined with rifampicin for the treatment of Gram-positive osteoarticular infections. *Int Orthop.* 2013, 37:1375-80. [10.1007/s00264-013-1856-y](https://doi.org/10.1007/s00264-013-1856-y)
 19. Lora-Tamayo J, Parra-Ruiz J, Rodríguez-Pardo D, et al.: High doses of daptomycin (10 mg/kg/d) plus rifampin for the treatment of staphylococcal prosthetic joint infection managed with implant retention: a comparative study. *Diagn Microbiol Infect Dis.* 2014, 80:66-71. [10.1016/j.diagmicrobio.2014.05.022](https://doi.org/10.1016/j.diagmicrobio.2014.05.022)
 20. Kuo FC, Yen SH, Peng KT, Wang JW, Lee MS: Methicillin-resistant Staphylococcal periprosthetic joint infections can be effectively controlled by systemic and local daptomycin. *BMC Infect Dis.* 2016, 16:48. [10.1186/s12879-016-1366-9](https://doi.org/10.1186/s12879-016-1366-9)
 21. Chang YJ, Lee MS, Lee CH, Lin PC, Kuo FC: Daptomycin treatment in patients with resistant staphylococcal periprosthetic joint infection. *BMC Infect Dis.* 2017, 17:736. [10.1186/s12879-017-2842-6](https://doi.org/10.1186/s12879-017-2842-6)
 22. Raad I, Hanna H, Jiang Y, et al.: Comparative activities of daptomycin, linezolid, and tigecycline against catheter-related methicillin-resistant Staphylococcus bacteremic isolates embedded in biofilm. *Antimicrob Agents Chemother.* 2007, 51:1656-60. [10.1128/AAC.00350-06](https://doi.org/10.1128/AAC.00350-06)
 23. John AK, Baldoni D, Haschke M, Rentsch K, Schaeferli P, Zimmerli W, Trampuz A: Efficacy of daptomycin in implant-associated infection due to methicillin-resistant Staphylococcus aureus: importance of combination with rifampin. *Antimicrob Agents Chemother.* 2009, 53:2719-24. [10.1128/AAC.00047-09](https://doi.org/10.1128/AAC.00047-09)
 24. Garrigós C, Murillo O, Euba G, et al.: Efficacy of usual and high doses of daptomycin in combination with rifampin versus alternative therapies in experimental foreign-body infection by methicillin-resistant Staphylococcus aureus. *Antimicrob Agents Chemother.* 2010, 54:5251-6. [10.1128/AAC.00226-10](https://doi.org/10.1128/AAC.00226-10)
 25. Saleh-Mghir A, Muller-Serieys C, Dinh A, Massias L, Crémieux AC: Adjunctive rifampin is crucial to optimizing daptomycin efficacy against rabbit prosthetic joint infection due to methicillin-resistant Staphylococcus aureus. *Antimicrob Agents Chemother.* 2011, 55:4589-93. [10.1128/AAC.00675-11](https://doi.org/10.1128/AAC.00675-11)