



# ICD lead extraction: Not a benign procedure. External chest compression: Not a benign manoeuvre

Federico Sertic, Paolo Bosco, Antonella Ferrara, Patrick Heck and Yasir Abu-Omar

## Abstract

This is the case of a 45-year-old man who was electively admitted to our hospital for revision and extraction of his faulty implantable cardioverter–defibrillator lead and box. The procedure was complicated by cardiac tamponade requiring pericardiocentesis (unsuccessful) and cardiopulmonary resuscitation. The patient was then rushed to theatre for emergency sternotomy and institution of cardiopulmonary bypass. A tear in the superior vena cava was identified and repaired. Unfortunately, the patient suffered of a liver laceration, due to chest compression, which required emergency laparotomy. The aim of this report is to highlight the combination and management of two rare life-threatening complications that occurred in a single case.

## Keywords

Cardiology, CPR and emergency cardiac care, emergency sternotomy and emergency laparotomy, ICD lead extraction, superior vena cava repair, treatment

Date received: 26 April 2017; revised: 6 August 2017; accepted: 11 August 2017

## Introduction

External chest compression is an essential manoeuvre in cardiopulmonary resuscitation. Although it is life-saving, it may result in unusual traumatic injury. Some of the latter are well-recognised, rather common and rarely incur a negative effect on patients' outcome. These include injuries to lungs, heart, sternum, rib cage and chest wall. Others are rare, often only identified at autopsy and can result in significant mortality secondary to massive hemorrhage (injuries to liver, spleen and other intra-abdominal organs).<sup>1–4,6</sup> This report describes the case of a patient admitted for a laser-assisted extraction and replacement of a mal-functioning implantable cardioverter–defibrillator (ICD) lead and box. This procedure led to cardiac tamponade and pulseless electrical activity. External chest compression caused a deep laceration of the right lobe of the liver, which resulted in a massive hemoperitoneum and severe hemodynamic instability requiring emergency surgery.

## Case report

A fit 45-year-old man, with a background of Brugada Syndrome had an ICD inserted 10 years previously for

secondary prevention. He was initially admitted for lead replacement and ICD box change. This procedure was attempted, however failed due to an occlusion of the brachiocephalic vein. Therefore, a laser-assisted lead extraction was undertaken. Immediately following the procedure, the patient showed sign of tamponade and a pericardiocentesis was carried out. This was unsuccessful and the patient became hemodynamically unstable. He was transferred immediately to the operating theatre, intubated, ventilated and proceeded for emergency sternotomy. On arrival to theatre, the patient developed pulseless electrical activity and external chest compressions were delivered for 30–60 s.

Following sternotomy, the pericardium was opened and copious amounts of blood and clots were removed with prompt restoration of spontaneous circulation.

Cardiothoracic Surgery, Papworth Hospital, Cambridge, UK

### Corresponding author:

Federico Sertic, Cardiothoracic Surgery, Papworth Hospital, Cambridge CB23 3RE, UK.  
Email: federico.sertic@nhs.net



A bleeding point was identified on the right ventricular acute margin, which was repaired using a single 3/0 pledgeted Prolene suture. A large volume of blood was also noted in the right pleura, with extensive infiltration of the extra-pericardial portion of the superior vena cava. Careful dissection revealed a 5–7 cm linear tear extending from the right subclavian vein to the pericardial reflection of the Superior Vena Cava (SVC; Figure 1). In order to repair this, the patient was connected to cardiopulmonary bypass and cooled to 25° without circulatory arrest. A patch of bovine pericardium was used to reconstruct the SVC and the right subclavian vein (Figure 1). The patient was rewarmed and hemostasis secured.

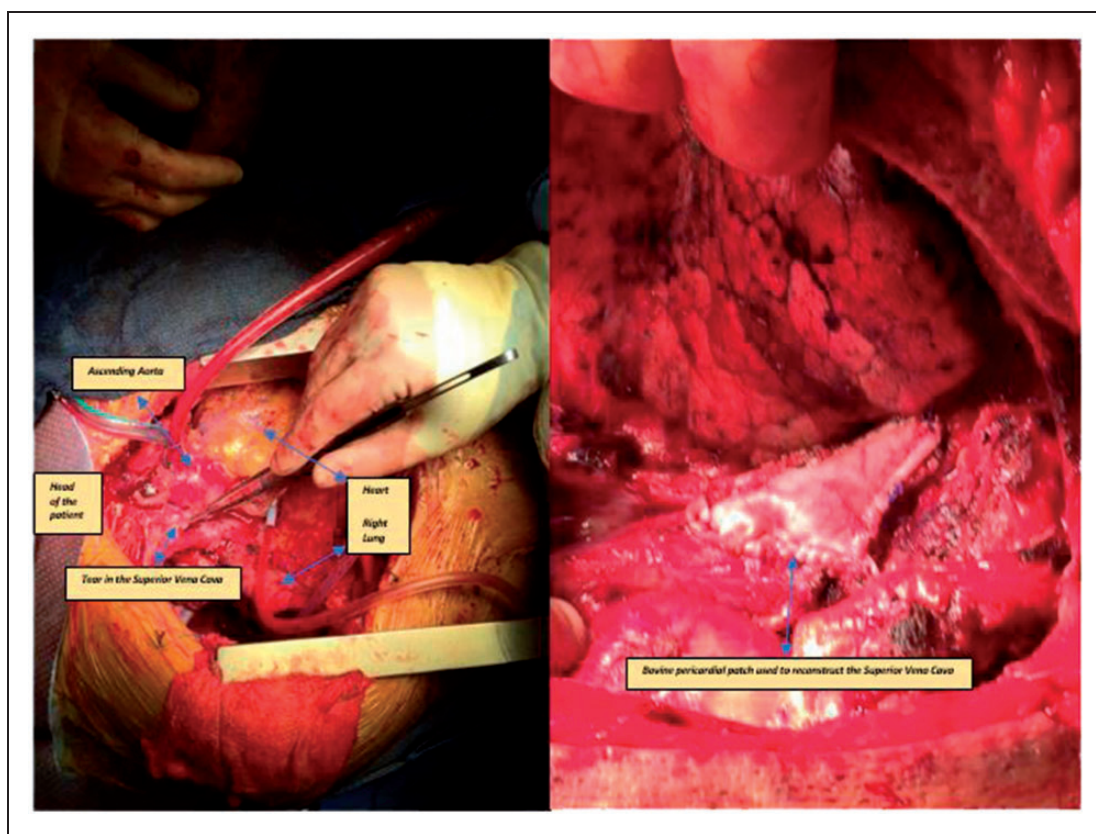
However, the patient remained hemodynamically unstable and the hemoglobin was noted to be low. The abdomen was very distended and an ultrasound demonstrated free abdominal fluid. The possibility of having a CT scan was dismissed due to the unstable condition of the patient. He proceeded for an emergency laparotomy with 4 L of blood drained from the abdomen. A deep laceration in the posterior part of the right lobe of the liver was eventually identified. The bleeding was difficult to control requiring

mobilization of the liver and packing. The bleeding was eventually controlled. After 48 hours, a re-exploration of the abdomen was carried out and the liver laceration was still bleeding on pack removal requiring specialist repair by the hepatic surgeons. The patient eventually made a good recovery and remains alive and well.

## Discussion

This report describes a case of liver laceration following external chest compression. The need of cardiopulmonary resuscitation was the result of a complication that occurred during laser-assisted extraction and replacement of an ICD lead and box to repair injury to the right ventricle and superior vena cava.

Liver laceration is a rare and life-threatening complication of external chest compression during cardiopulmonary resuscitation. As demonstrated by Meron et al. in a retrospective analysis of a cardiac arrest registry within 14.5 years, major liver injury (rupture/laceration, haemorrhage/haematoma) was found in 15 of 2558 cardiac arrest victims (0.6%). The site of injury was mostly the left liver lobe in 11 of 15



**Figure 1.** (a) The 5–7 cm linear tear in the superior vena cava vein. (b) The patch of bovine pericardium used to reconstruct the superior vena cava.

(73%).<sup>5</sup> One of the reasons for the occurrence of this complication has been attributed to excessive pressure and improper positioning of hands during compression. However, it has been demonstrated that this kind of complication can occur even with correctly performed Cardiopulmonary Resuscitation (CPR).<sup>1,2,6–8</sup>

Furthermore, in comparison to thoracic trauma due to cardiopulmonary resuscitation which rarely negatively affect the patient's outcome, a trauma to the liver can result in significant mortality due to massive hemorrhage.<sup>6</sup>

This severe complication was the result of laser-assisted extraction and replacement of an ICD lead. An estimated 10,000–15,000 pacemaker and ICD leads are extracted annually worldwide using specialized tools and techniques.<sup>9</sup> The Food and Drug Administration's (FDA) Manufacturers and User Defined Experience (MAUDE) database reports between 1995 and 2008, 57 peri-operative deaths and 48 serious procedural injuries associated with device-assisted lead extraction. Forty-five of these were due to laser-assisted lead extraction. The MAUDE data reports that the majority of deaths were caused by lacerations of the right atrium, superior vena cava or innominate vein.<sup>9</sup> Of the 34 patients who underwent emergency thoracotomy or sternotomy to repair venous lacerations or myocardial perforations, 17 (50%) died during or after surgery.<sup>9</sup> A subsequent non-randomized European multicentre study of excimer laser-assisted pacemaker and ICD lead extractions in 292 patients reported a 5.1% complication rate, including 10 non-fatal vascular and cardiac perforations.<sup>10</sup> Several studies have shown that patient's age, sex and calcification around the lead represent risk factors for laser-assisted procedures. The experience of the physician performing the procedure is inversely related to the risk of complications.<sup>11–14</sup> A recent survey of Heart Rhythm Society members found that just 18% of physicians perform more than 50 extractions a year, and 25% of extraction procedures are done without a surgeon or operating room on standby.<sup>15</sup>

In conclusion, the aim of this report is to highlight two major matter of interest. On the one hand, we want to describe a rare and life-threatening complication that can result from external chest compression during cardiopulmonary resuscitation and that need to be kept in mind when assessing a patient after CPR with Return Of Spontaneous Circulation (ROSC). One the other hand, our aim is to highlight a complication that can occur during laser-assisted extraction and replacement of his ICD lead and box and the strong need of a cardiothoracic surgery team and an operating theatre on stand-by when performing this procedure.

## Declaration of conflicting interests

The author(s) declared no potential conflicts of interest with respect to the research, authorship, and/or publication of this article.

## Funding

The author(s) received no financial support for the research, authorship, and/or publication of this article.

## Ethical approval

None.

## Guarantor

Federico Sertic.

## Contributorship

Federico Sertic: draft writing and literature review, Antonella Ferrara and Paolo Bosco: article editing, Patrick Heck: article editing and responsible consultant cardiologist, Yasir Abu Omar: article editing and responsible cardiothoracic surgeon.

## References

1. Jin Wi and Dongho S. Liver laceration with hemoperitoneum after cardiopulmonary resuscitation. *Korean J Crit Care Med* 2014; 29(2): 141–143.
2. Kuboyama K, Safar P, Radovsky A, et al. Delay in cooling negates the beneficial effect of mild resuscitative cerebral hypothermia after cardiac arrest in dogs: a prospective, randomized study. *Crit Care Med* 1993; 21: 1348–1358.
3. Rosen J, Tucheck JM and Hartmann JR. Liver laceration in the hemodynamically unstable post-cardiac massage patient: early recognition and management-case report. *J Trauma* 1999; 47: 408–409.
4. Ziegenfuss MD and Mullany DV. Traumatic liver injury complicating cardio-pulmonary resuscitation. The value of a major intensive care facility: a report of two cases. *Crit Care Resusc* 2004; 6: 102–104.
5. Meron G, Kurkciyan I, Sterz F, et al. Cardiopulmonary resuscitation-associated major liver injury. *Resuscitation* 2007; 75: 445–453.
6. Jain V, Lutchmansingh D, Kaur D, et al. Liver laceration as a complication of cardiopulmonary resuscitation. *ATS J* 2014; 189: A6468.
7. Kuboyama K, Safar P, Radovsky A, et al. Delay in cooling negates the beneficial effect of mild resuscitative cerebral hypothermia after cardiac arrest in dogs: a prospective, randomized study. *Crit Care Med* 1993; 21: 1348–1358.
8. Morgan RR. Laceration of the liver from closed-chest cardiac massage. *N Engl J Med* 1961; 265: 82–83.
9. Hauser RG, Katsiyannis WT, Gornick CC, et al. Deaths and cardiovascular injuries due to device assisted implantable cardioverter-defibrillator and pacemaker lead extraction. *Europace* 2010; 12: 395–401.

10. Kennergren C, Bucknall CA, Butter C, et al. Laser assisted lead extraction: the European experience. *Europace* 2007; 9: 651–656.
11. Jones SO, Eckart RE, Albert CM, et al. Large, single-center, single-operator experience with transvenous lead extraction: outcomes and changing indications. *Heart Rhythm* 2008; 5: 520–525.
12. Byrd CL, Wilkoff BL, Love CJ, et al. Clinical study of the laser sheath for lead extraction: the total experience in the United States. *Pacing Clin Electrophysiol* 2002; 25: 804–808.
13. Smith HJ, Fearnot NE, Byrd CL, et al. Five-years experience with intravascular lead extraction. *Pacing Clin Electrophysiol* 1994; 17: 2016–2020.
14. Byrd CL, Wilkoff BL, Love CJ, et al. Intravascular extraction of problematic or infected permanent pacemaker leads: 1994–1996. *Pacing Clin Electrophysiol* 1999; 22: 1348–1357.
15. Henrikson CA, Zhang K and Brinker JA. Lead extraction practice in the United States. (Abstract). *J Am Coll Cardiol* 2009; 53: A129.