

Received: 2016.07.13
Accepted: 2016.11.08
Published: 2017.02.09

Rituximab Can Induce Remission in a Patient with Ankylosing Spondylitis Who Failed Anti-TNF- α Agent

Authors' Contribution:
Study Design A
Data Collection B
Statistical Analysis C
Data Interpretation D
Manuscript Preparation E
Literature Search F
Funds Collection G

ABCDEF 1 **Fahmi AlDhaheeri**
ABCDEF 2 **Talal Almeri**
E 1 **Naji Dwid**
E 2 **Ahd Majdali**
E 1 **Nahed Janoudi**
ABCDEF 1,2,3 **Hani Almoallim**

1 Department of Internal Medicine, Dr. Soliman Fakeeh Hospital, Jeddah, Saudi Arabia
2 Department of Internal Medicine, Medical College, Umm-Al Qura University, Makkah, Saudi Arabia
3 Alzaidi Chair of Research in Rheumatic Diseases, Medical College, Umm-Al Qura University, Makkah, Saudi Arabia





Corresponding Author: Hani Almoallim, e-mail: HaniAlmoallim@gmail.com
Conflict of interest: None declared
Source of support: Alzaidi Chair of Research in Rheumatic Diseases provided funding for this paper

Patient: **Male, 38**
Final Diagnosis: **Ankylosing spondylitis**
Symptoms: **Back pain • morning stiffness**
Medication: **—**
Clinical Procedure: **Not applicable**
Specialty: **Rheumatology**

Objective: **Unusual or unexpected effect of treatment**
Background: Ankylosing spondylitis (AS) is a chronic inflammatory disease that predominantly affects the axial skeleton. The ability of anti-TNF- α agents to reduce disease activity in patients with axial spondyloarthritis (axSpA), including AS, has been demonstrated in multiple randomized trials and several meta-analyses. Reports on the efficacy of rituximab in treatment of AS have described good results. We report on a patient with AS who failed anti-TNF- α therapy but showed good clinical improvement with rituximab therapy.
Case Report: A 38-year-old male patient was diagnosed with AS and showed poor response to sulfasalazine and non-steroidal anti-inflammatory drugs (NSAIDs). Infliximab was initiated with marked improvement as per the Bath ankylosing spondylitis disease activity index (BASDAI). Due to disease flare, the patient was switched to etanercept. He subsequently acquired papillary thyroid cancer and etanercept was discontinued. He underwent a total thyroidectomy followed by radioiodine therapy. For his ongoing active disease, NSAIDs and sulfasalazine were resumed with a lack of response (BASDAI=7.1). Rituximab was started and resulted in significant improvement (BASDAI=2.3).
Conclusions: Rituximab can be a potential target therapy for patients who start to lose response to TNF-inhibitors or for those who develop solid malignancies. Further placebo-controlled studies are required.

MeSH Keywords: **Anti-Inflammatory Agents, Non-Steroidal • Antirheumatic Agents • Spondylitis, Ankylosing**

Full-text PDF: <http://www.amjcaserep.com/abstract/index/idArt/900563>

 1578  —  4  23



Background

Ankylosing spondylitis (AS) is a disorder that primarily targets the axial skeleton in a background of autoimmune activity as part of the disease pathogenesis [1]. Recent recommendations from the American College of Rheumatology, Spondylitis Association of America, and Spondyloarthritis Research and Treatment Network 2015 stated that there are only two groups of drugs that are effective for predominant axial manifestations of AS, which are: non-steroidal anti-inflammatory drugs (NSAIDs) and anti-TNF- α agents [2]. The ability of anti-TNF- α agents to halt AS progression has been reported in several meta-analyses [3].

The major sites of AS pathology are the articulations of the axial skeleton [4]. Inflammation, structural damage, and excessive bone formation are the main findings in the entheses and fibrous connections of ligaments to bone [5]. Based on histopathological studies, CD3+, CD4+, and CD8+ T cells, in addition to CD20+ B cells, were found to be infiltrated in the cartilage and subchondral bone [6]. Interestingly, the number of B cells infiltrated was higher than the T cells infiltration [7]. Genetic involvement in the pathogenesis of AS has been proposed, and the human leukocyte antigen HLA-B27 has been studied as a potential involved gene in AS pathophysiology [8]. The role of HLA-B27 was first recognized in 1973, and since that time around 90% of AS cases have been linked to HLA-B27 across all ethnic groups [9]. Potential roles of HLA-B27 have been proposed through several hypotheses, including an influence of HLA-B27 on gut microbiome, protein misfolding hypothesis, heavy chain homodimer hypothesis, and arthrogenic peptide hypothesis [10]. In fact, the genetic contribution to AS pathogenesis is not limited to HLA-B27, several non-HLA genes have also been reported to play a role, for example; the IL-23/IL-17 pathway has been reported to be involved in AS development [11]. IL-23 receptors have been found in the ilium of AS patients and elevated in the sera of AS patients. One study showed the association between the *pentraxin 3* (*PTX3*) gene and AS [12]. *PTX3* protein is encoded by the *PTX3* gene located on chromosome 3q25. Three single nucleated polymorphisms (rs2305619, rs3816527, and rs3845978) were studied to figure out their association with AS [12]. AA genotype of rs2305619 and CC genotype of rs3816527 might be correlated with AS development. More open-label studies are required to clearly establish this association. However, two phenomena have been clearly linked to AS pathogenesis; inflammation and ossification [13]. Infections can cause enthesal stress that leads to micro-lesions and progenitor cell activation. Some of these acute events tend to progress to a chronic inflammatory pattern resulting in permanent ossification [13].

Rituximab is a B cell therapy used to treat several autoimmune diseases. It causes B cell depletion via several pathways,

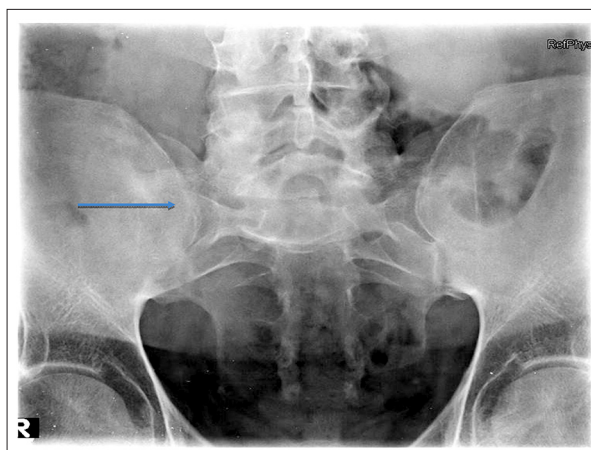


Figure 1. X-ray of the sacroiliac joint shows bilateral sacroiliitis (arrow) with decreased joint space and bony fusion.

including complement mediated cell lysis, growth arrest, and B cell apoptosis [14]. Efficacy of rituximab therapy in AS patients has been examined in several reports and has shown promising results [15].

Here we report on the case of a patient with AS who failed anti-TNF- α therapy but showed good clinical improvement with rituximab.

Case Report

A 38-year-old male patient was diagnosed with AS in 2001. He had chronic inflammatory lower back pain with morning stiffness, which improved on exercise and hot shower, and was associated with uveitis and Achilles tendonitis. He had a strong family history of AS. His treatment consisted of NSAIDs and sulfasalazine but he showed no significant improvement. In October 2005, he was seen by our rheumatology service and the decision was made to start him on infliximab 5 mg/kg intravenously at 0, 2, and 6 weeks, then every 6 weeks as a maintenance dose. At that time, he had marked limitation of spinal movement, chest expansion was 1 cm, modified Schober test was 1 cm, ASDAS was 4.6, BASDAI was 7.2, CRP was 92 mg/dL, and x-ray showed grade 3 sacroiliitis (Figure 1). MRI showed bilateral ankylosis and fusion of both sacroiliac joints (Figure 2). The lumbar region x-ray showed mild spondylitic changes with decreased L5-S1 disc space (Figure 3).

After 12 weeks of treatment (January 2006), the patient had marked improvement of spinal movement. Chest expansion became 1.5 cm, modified Schober test was 4 cm, ASDAS was 1.3, BASDAI was 3.00, and CRP became normal. The maintenance dose of infliximab was increased in frequency to reach a single dose every 4 weeks due to increasing pain.

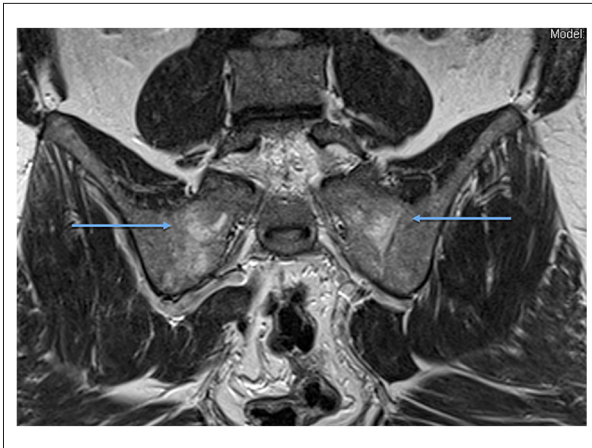


Figure 2. Bilateral ankylosis and fusion of both sacroiliac joints with abnormal bone (arrows) marrow signal that displays slightly low signal on T1 and high signal on T2.

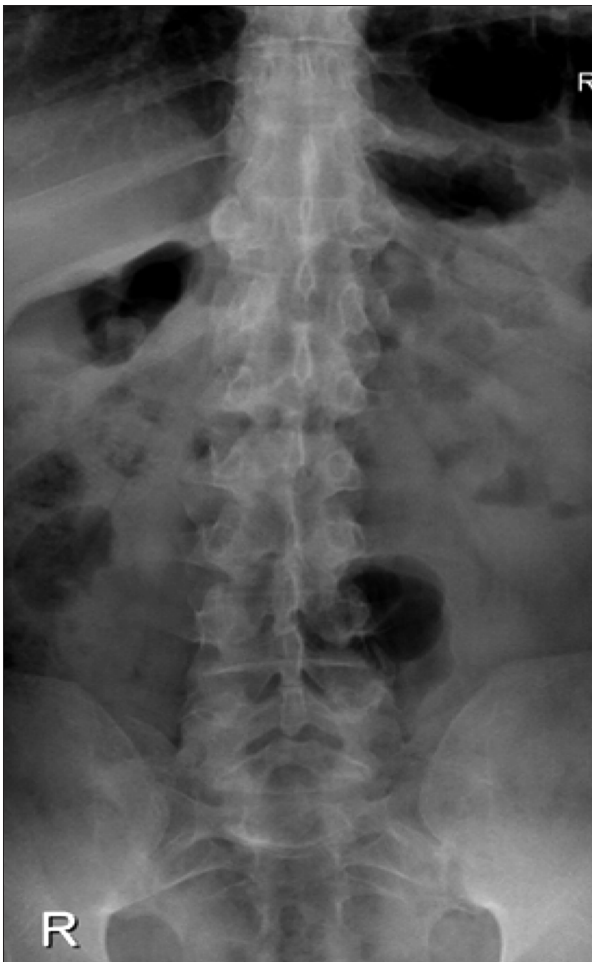

Figure 3. X-ray of the lumbar area shows mild spondylitic changes with relative decreased L5–S1 disc space posteriorly with noted facet joints arthropathy

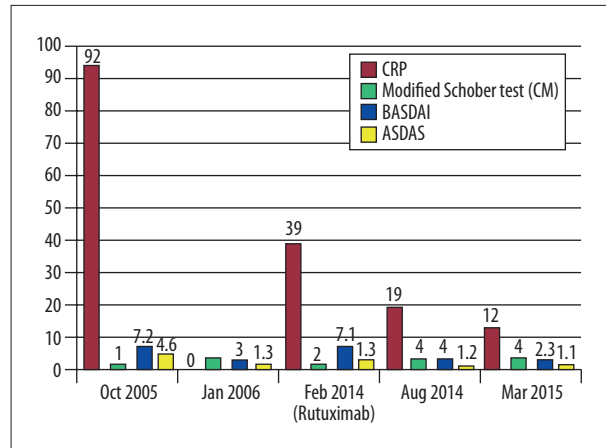


Figure 4. The parameters used to monitor the patient's response before and after the addition of rituximab on February 2014.

After several years of interrupted follow-up, the patient presented again in February 2013 with severe intolerable pain. He was switched to etanercept 50 mg SC every week and he received it for two months with no significant improvement. He developed a right lump below his right ear after initiation of etanercept, which was treated as lymphadenitis with antibiotic with no improvement. Fine needle aspiration findings were negative for malignancy. For ongoing suspicion of a malignant disease process, the patient underwent left hemi-thyroidectomy in June 2013 and biopsy showed an encapsulated variant of papillary carcinoma. Total thyroidectomy was done on June 22, 2013 without residual tumor tissue and the patient was started on Eltroxin and iodine radiotherapy. He was maintained on NSAIDs and sulfasalazine to control symptomatic AS. This resulted in partial control of his disease.

In February 2014, the patient had a flare of his disease; BASDAI was 7.1 and CRP 39 mg/dL. With the recent diagnosis of malignancy, anti-TNF- α agents were not considered; the decision was to start him on rituximab 375 mg/m² at 0 and 2 weeks followed by another dose after 6 months. He had marked improvement clinically; BASDAI was 4 and CRP was 19 mg/dL. In March 2015, he received the third cycle of rituximab and continued to improve. His BASDAI was 2.3 and CRP 12 mg/dL. Currently, he is on NSAIDs as needed and regular exercise. Figure 4 shows the clinical and biochemical response to rituximab since February 2014.

Discussion

This case report describes a good response to rituximab in a patient who had previously failed to respond significantly on anti-TNF- α agents. His disease started to lose responsiveness gradually, and his treatment was interrupted due to the

diagnosis of a solid malignancy. The patient showed significant response to rituximab. The BASDAI was reduced from 7.1 to 4, and the CRP levels also decreased significantly from 39 to 12 mg/dL (Figure 4).

Generally, rituximab is a well-tolerated drug with a low toxicity profile [16]. Rare side effects include progressive multifocal leukoencephalopathy, reactivation of latent tuberculosis infection (LTBI), hepatitis, and late onset neutropenia (LON) [16]. Successful treatment of rituximab-induced LON with granulocyte-macrophage colony stimulated factor has been reported [16]. Thus, early identification and proper management of patients who are on rituximab and presented with leukopenia is warranted.

TNF- α blockers represent an important therapeutic modality for several inflammatory diseases, including rheumatoid arthritis (RA), inflammatory bowel disease, and seronegative spondyloarthropathies [17]. TNF- α blockers have several side effects, including injection site reaction, infusion reaction either acute or delayed, and increased risk of infection. Acute infusion reaction can deliver a true type 1 hypersensitivity (IgE mediated) that presents as hypotension, bronchospasm wheezing, and urticarial. Early recognition and treatment is warranted because this reaction is a real medical emergency [18]. Neutropenia is a frequent finding in patients on TNF- α blockers, with up to 10% experiencing at least one episode of neutropenia during their treatment course [19]. The risk of serious infection increases with use of TNF- α blockers. TNF- α plays a central role in maintaining the granuloma [20]; any use of TNF- α blockers is associated with higher risk of reactivation of tuberculosis (TB). Urinary tract TB during etanercept therapy for RA has been described [21]. Early recognition and administration of anti-TB agents can result in successful eradication of this infection, with gradual resumption of etanercept therapy with close observation in cases of both TB recurrence and RA disease activity [21].

References:

1. Braun J, Sieper J: Ankylosing spondylitis. *Lancet*, 2007; 369(9570): 1379–90
2. Ward MM, Deodhar A, Akl EA et al: American College of Rheumatology/ Spondylitis Association of America/Spondyloarthritis Research and Treatment Network 2015 Recommendations for the treatment of ankylosing spondylitis and nonradiographic axial spondyloarthritis. *Arthritis Rheumatol*, 2016; 68(2): 282–98
3. Callhoff J, Sieper J, Weiss A et al: Efficacy of TNF α blockers in patients with ankylosing spondylitis and non-radiographic axial spondyloarthritis: A meta-analysis. *Ann Rheum Dis*, 2015; 74(6): 1241–48
4. Rudwaleit M, Haibel H, Baraliakos X et al: The early disease stage in axial spondylarthritis: Results from the German Spondyloarthritis Inception Cohort. *Arthritis Rheum*, 2009; 60(3): 717–27
5. Braun J, Bollow M, Seyrekbasan F et al: Computed tomography guided corticosteroid injection of the sacroiliac joint in patients with spondyloarthropathy with sacroiliitis: Clinical outcome and followup by dynamic magnetic resonance imaging. *J Rheumatol*, 1996; 23(4): 659–64
6. Braun J, Bollow M, Neure L et al: Use of immunohistologic and *in situ* hybridization techniques in the examination of sacroiliac joint biopsy specimens from patients with ankylosing spondylitis. *Arthritis Rheum*, 1995; 38(4): 499–505
7. Appel H, Kuhne M, Spiekermann S et al: Immunohistologic analysis of zygapophyseal joints in patients with ankylosing spondylitis. *Arthritis Rheum*, 2006; 54(9): 2845–51
8. Appel H, Loddenkemper C, Grozdanovic Z et al: Correlation of histopathological findings and magnetic resonance imaging in the spine of patients with ankylosing spondylitis. *Arthritis Res Ther*, 2006; 8(5): R143

In one prospective open-label trial evaluated the efficacy of rituximab in AS [22]. Rituximab, which is a monoclonal antibody against CD20, was administered intravenously at weeks 0 and 2 with a total dose of 1000 mg. A total of 20 patients with active AS were enrolled, with 10 patients naive to anti-TNF therapy. In the anti-TNF-inhibition group, there was no clear response at 24 weeks. The response was significantly higher in the anti-TNF naive group. At one-year follow-up, among the nine responders, a flare-up was noted in five patients; a second course of rituximab was administered showing marked improvement in BASDAI, ASDAS, and CRP [22]. Small sample size remains one of the greatest limitations to show statistical significance in such trials. In our case study we describe a patient who failed to improve on TNF-inhibitors, and who had a significant response to rituximab. This may be contrary to what has been found in studies where rituximab showed better response in anti-TNF- α naive patients [23].

There is an unmet need for medicines with a different mechanism than anti-TNF- α agents for patients with AS who do not benefit from such therapies, who are intolerant to anti-TNF- α agents, or who have a solid malignancy. The main pathognomonic mechanism in AS is focused on the presence of T cells. However, the presence of B cell clusters in the subchondral bone marrow reflects a crucial role for B cells in AS pathogenesis. Therefore, B cell-directed therapies are a newly identified trend in AS therapeutic modalities.

Conclusions

Rituximab can be a potential target therapy for patients who start to lose response to TNF-blockers or for those who develop a solid malignancy. Further placebo-controlled studies are required.

Conflict of interest

The authors declare that they have no conflicts of interest.

9. Boye J, Elter T, Engert A: An overview of the current clinical use of the anti-CD20 monoclonal antibody rituximab. *Ann Oncol*, 2003; 14(4): 520–35
10. Colbert RA, DeLay ML, Layh-Schmitt G, Sowders DP: HLA-B27 misfolding and spondyloarthropathies. *Prion*, 2009; 3(1): 15–26
11. Sherlock JP, Buckley CD, Cua DJ: The critical role of interleukin-23 in spondyloarthropathy. *Mol Immunol*, 2014; 57(1): 38–43
12. Zhang X, Ding W: Association of genetic variants in Pentraxin 3 gene with ankylosing spondylitis. *Med Sci Monit*, 2016; 22: 2911–16
13. Shimada Y, Asanuma YF, Yokota K et al: Pentraxin 3 is associated with disease activity but not atherosclerosis in patients with systemic lupus erythematosus. *Modern Rheumatol*, 2014; 24(1): 78–85
14. Smith JA: Update on ankylosing spondylitis: Current concepts in pathogenesis. *Curr Allergy Asthma Rep*, 2015; 15(1): 489
15. Rodriguez-Escalera C, Fernández-Nebro A: The use of rituximab to treat a patient with ankylosing spondylitis and hepatitis B. *Rheumatology*, 2008; 47(11): 1732–33
16. Reitblat T, Wechsler A, Reitblat O: Rituximab-related late-onset neutropenia in patients with rheumatic diseases: successful re-challenge of the treatment. *Am J Case Rep*, 2015; 16: 211–14
17. Roach DR, Bean AG, Demangel C et al: TNF regulates chemokine induction essential for cell recruitment, granuloma formation, and clearance of mycobacterial infection. *J Immunol*, 2002; 168(9): 4620–27
18. Cheifetz A, Mayer L: Monoclonal antibodies, immunogenicity, and associated infusion reactions. *Mt Sinai J Med*, 2005; 72(4): 250–56
19. Hastings R, Ding T, Butt S et al: Neutropenia in patients receiving anti-tumor necrosis factor therapy. *Arthritis Care Res (Hoboken)*, 2010; 62(6): 764–69
20. Keane J, Gershon S, Wise RP et al: Tuberculosis associated with infliximab, a tumor necrosis factor α -neutralizing agent. *N Engl J Med*, 2001; 345(15): 1098–104
21. Shibata S, Shono E, Nishimagi E, Yamaura K: A patient with urinary tract tuberculosis during treatment with etanercept. *Am J Case Rep*, 2015; 16: 341–46
22. Song IH, Heldmann F, Rudwaleit M et al: Different response to rituximab in tumor necrosis factor blocker-naïve patients with active ankylosing spondylitis and in patients in whom tumor necrosis factor blockers have failed: A twenty-four-week clinical trial. *Arthritis Rheum*, 2010; 62(5): 1290–97
23. Song I-H, Heldmann F, Rudwaleit M et al: One-year follow-up of ankylosing spondylitis patients responding to rituximab treatment and re-treated in case of a flare. *Ann Rheum Dis*, 2013; 72(2): 305–6