





CASE REPORT

REVISED Case Report: Focal leptomenigeal disease, atypical cancer of unknown primary site [version 2; peer review: 2 approved]

Miguel A. Vences ¹, Mary M. Araujo-Chumacero¹, Diego Urrunaga-Pastor ^{2,3},
Leila Barreto¹, Liliana Rodríguez-Kadota¹, Elliot Barreto-Acevedo¹,
César Saavedra-Rocha¹, Elder V. Quispe-Huamaní¹

¹Departamento de Neurología, Hospital Nacional Edgardo Rebagliati Martins, EsSalud, Lima, Peru

²Unidad para la Generación y Síntesis de Evidencias en Salud, Universidad San Ignacio de Loyola, Lima, Peru

³Dirección de Investigación en Salud, Instituto de Evaluación de Tecnologías en Salud e Investigación – IETSI, EsSalud, Lima, Peru

V2 First published: 02 Aug 2022, 11:885
<https://doi.org/10.12688/f1000research.122434.1>
Latest published: 21 Sep 2022, 11:885
<https://doi.org/10.12688/f1000research.122434.2>

Abstract

Background: Leptomeningeal metastasis is an infrequent form of cancer expression, and it has a poor prognosis due to its torpid evolution and its challenging diagnosis.





Case report: We report the case of a 68-year-old woman with rapidly progressing cognitive decline and focal epilepsy. Brain magnetic resonance imaging showed extensive gyriform hypersignal in the right precentral sulcus region, without mass effect, tenuous contrast uptake, and hydrocephalus with transependymal edema. The body tomographic study was negative for solid cancer and the 18F-FDG PET-CT revealed a severe hypermetabolism in the right lung upper lobe. These findings were suggestive of lung cancer with leptomenigeal metastasis. We performed a brain biopsy, finding atypical cells in the leptomenigeal region with positive immunohistochemical staining for CK7 and negative for CK20 corresponding to lung adenocarcinoma. The patient was evaluated in the oncology service and scheduled for radiotherapy and chemotherapy.

Conclusions: Focal leptomenigeal disease is an entity that should be considered as a differential diagnosis in all cases of focal leptomenigitis. Timely diagnosis and adequate cancer management can increase patient survival.

Keywords

Dementia, Brain metastasis, Nervous System Neoplasms, PET-CT scan, Leptomeningeal Neoplasms


Open Peer Review**Approval Status**  

	1	2
version 2 (revision) 21 Sep 2022		 view
version 1 02 Aug 2022	 view	  view

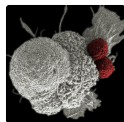
1. **Miguel Oswaldo Cadena-Sanabria** ,

University Hospital of Santander,
Bucaramanga, Colombia

Universidad Autónoma de Bucaramanga,
Bucaramanga, Colombia

2. **José Percy Amado Tineo** , Universidad
Nacional Mayor de San Marcos, Lima, Peru

Any reports and responses or comments on the article can be found at the end of the article.



This article is included in the **Oncology** gateway.

Corresponding authors: Miguel A. Vences (vens1793@hotmail.com), Diego Urrunaga-Pastor (diego.urrunaga.pastor1@gmail.com)

Author roles: **Vences MA:** Conceptualization, Data Curation, Methodology, Writing – Original Draft Preparation, Writing – Review & Editing; **Araujo-Chumacero MM:** Conceptualization, Data Curation, Methodology, Writing – Original Draft Preparation, Writing – Review & Editing; **Urrunaga-Pastor D:** Data Curation, Methodology, Writing – Original Draft Preparation, Writing – Review & Editing; **Barreto L:** Conceptualization, Data Curation, Methodology, Writing – Original Draft Preparation, Writing – Review & Editing; **Rodríguez-Kadota L:** Conceptualization, Data Curation, Methodology, Writing – Original Draft Preparation, Writing – Review & Editing; **Barreto-Acevedo E:** Conceptualization, Data Curation, Methodology, Writing – Original Draft Preparation, Writing – Review & Editing; **Saavedra-Rocha C:** Conceptualization, Data Curation, Methodology, Writing – Original Draft Preparation, Writing – Review & Editing; **Quispe-Huamaní EV:** Conceptualization, Data Curation, Methodology, Writing – Original Draft Preparation, Writing – Review & Editing

Competing interests: No competing interests were disclosed.

Grant information: The author(s) declared that no grants were involved in supporting this work.

Copyright: © 2022 Vences MA *et al.* This is an open access article distributed under the terms of the [Creative Commons Attribution License](#), which permits unrestricted use, distribution, and reproduction in any medium, provided the original work is properly cited.

How to cite this article: Vences MA, Araujo-Chumacero MM, Urrunaga-Pastor D *et al.* **Case Report: Focal leptomeningeal disease, atypical cancer of unknown primary site [version 2; peer review: 2 approved]** F1000Research 2022, 11:885 <https://doi.org/10.12688/f1000research.122434.2>

First published: 02 Aug 2022, 11:885 <https://doi.org/10.12688/f1000research.122434.1>

REVISED Amendments from Version 1

In this new version we have clarified the possible role of COVID-19 in patient cognitive impairment, as well as revised comments suggested by the reviewers. The title has also been changed.

Any further responses from the reviewers can be found at the end of the article

Introduction

Leptomeningeal metastasis is an infrequent form of cancer expression, and its association has been described with solid cancer such as breast, lung and melanoma.¹ This entity has a poor prognosis due to its torpid evolution and its diagnosis is a challenge, since on certain occasions it is the first systemic manifestation of cancer not yet diagnosed.²

We present the case of a 68-year-old woman with leptomeningeal metastasis as the first systemic manifestation of an unknown primary origin cancer. In addition, we carried out a review of the literature.

Case report

We describe the case of a 68-year-old self-sufficient housewife and Latin woman, with no significant family health history, diagnosed of hypothyroidism since she was young and who suffered from COVID-19 pneumonia with no severity criteria four months before admission. She was admitted to the neurology service due to a clinical course of insidious onset and progressive course of 4 months, characterized by cognitive decline and change in her behavior with affective flattening. In the seven days prior to admission, she developed mutism and an episode of tonic-clonic epileptic seizure of unknown onset and self-limited with a postictal dystonic posture in the left upper limb lasting less than one minute. She did not receive treatment for these symptoms prior to admission.

The neurological examination showed an apathy-abulic patient, person-oriented, with significantly impaired working memory, language without fluency with null judgment and introspection. In addition, she had mild left brachio-crural motor deficit. The rest of the physical examination showed no alterations.

In the neuropsychological assessment, we found cognitive impairment evidenced by a low score in the Folstein Minimal State Examination (MMSE)³ and the Montreal Cognitive Assessment (MoCA),⁴ with 9 points and 12 points, respectively.

Regarding the imaging studies performed, brain tomography without contrast did not show alterations and brain magnetic resonance imaging showed extensive leptomeningeal gyriform hypersignal in the right precentral sulcus region without mass effect and tenuous contrast uptake, associated with hydrocephalus and transependymal edema (Figure 1).

Due to the leptomeningeal gyriform finding in the brain magnetic resonance imaging and the patient's clinical course, laboratory tests and cerebrospinal fluid examination were requested. They reported hyperproteinorrhachia (149.4 milligrams per deciliter) without glucose consumption or pleocytosis. The rest of the studies were negative for

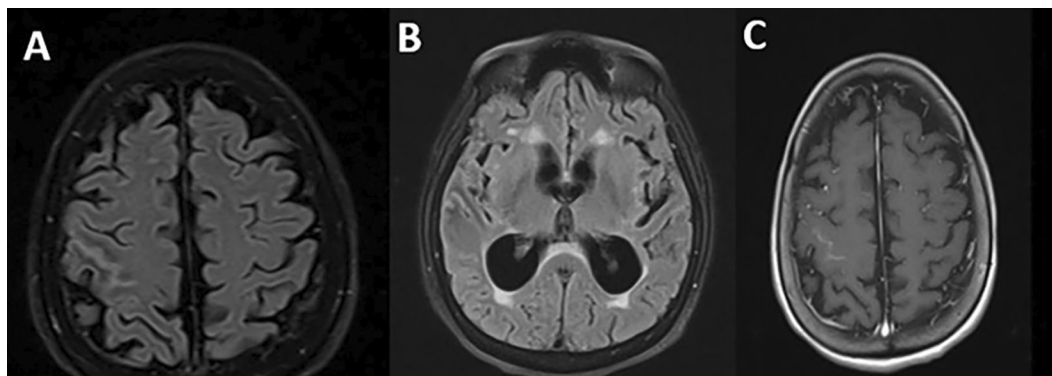


Figure 1. Brain magnetic resonance imaging: A. Irregular leptomeningeal thickening at the right Rolando fissure (thickness 2 mm), as well as smaller adjacent focal parietal leptomeningeal thickening (FLAIR sequence); B. Supratentorial hydrocephalus of recent onset associated with interstitial/transependymal edema (FLAIR sequence); C. No expansive lesions or enhancements in the brain parenchyma (T1 with contrast).

inflammatory disease (oligoclonal bands in serum and cerebrospinal fluid), autoimmune (C3, C4, antinuclear antibodies, antineutrophil cytoplasmic antibodies, extractable nuclear antigens and rheumatoid factor), neoplastic (cerebrospinal fluid Papanicolaou smear, cytometry and immunofixation in cerebrospinal fluid) and associated infectious (serological test for syphilis; antibody serological test for toxoplasmosis, rubella, cytomegalovirus, herpes simplex; cytomegalovirus viral load; John Cunningham virus in serum and cerebrospinal fluid; herpes virus in cerebrospinal fluid; HIV ELISA; Epstein-Barr virus in serum and cerebrospinal fluid; human T-lymphotropic virus type I and II; adenosine deaminase in cerebrospinal fluid and Koch's bacillus in sputum, urine, gastric juice, feces and cerebrospinal fluid). Tumor markers as CA 125, CA 15-3 and CYFRA 21.1 were negative, excepting carcinoembryonic antigen (CEA) and alpha fetoprotein (AFP) at levels of 246.24 ng/mL and 12.63 ng/mL, respectively. Contrast-enhanced cervical, thoracic, abdominal, and pelvic tomography excluded the presence of solid neoplasms.

Based on these results, the case was approached as a leptomeningeal metastasis of unknown primary origin, probably from the gastrointestinal tract. For this reason, they extended the study with a fecal occult blood test, which was positive on two opportunities, and performed endoscopic studies twice (upper digestive endoscopy and colonoscopy), with no evidence of cancer in the gastrointestinal tract studied. The gastroenterologists suggested expanding the study with high-resolution enterography to investigate a possible cancer lesion in the midgut. They performed it, without obtaining a positive result.

A total body 18F-fluorodeoxyglucose positron emission tomography (18F-FDG PET-CT) was performed on the patient with a GEMINI TF64 equipment in helical mode. It revealed severe hypermetabolism in the anterior segment of the right lung upper lobe (SUVmax: 5.47) and at the right precentral cerebral sulcus. These findings were suggestive of pulmonary neoplasia with leptomeningeal metastases (Figure 2).

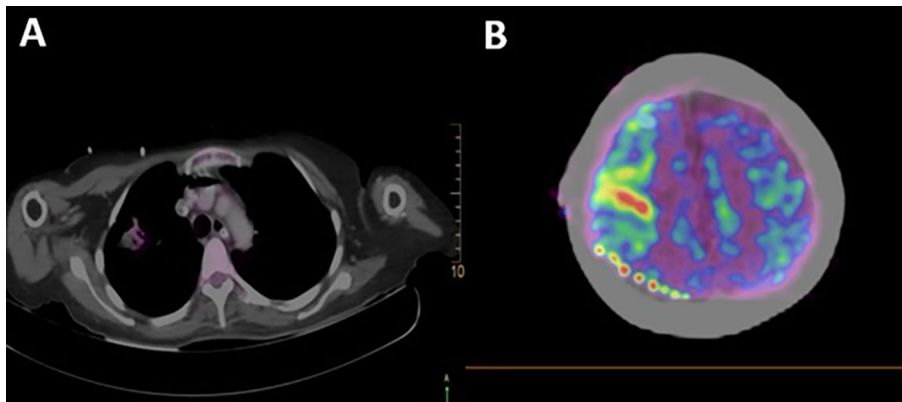


Figure 2. Total body 18F-fluorodeoxyglucose positron emission tomography (18F-FDG PET-CT): A. Pulmonary hypermetabolism without neoplastic mass in tomographic scanning (lung); B. FDG hypermetabolism at the right parietal region (cerebral).

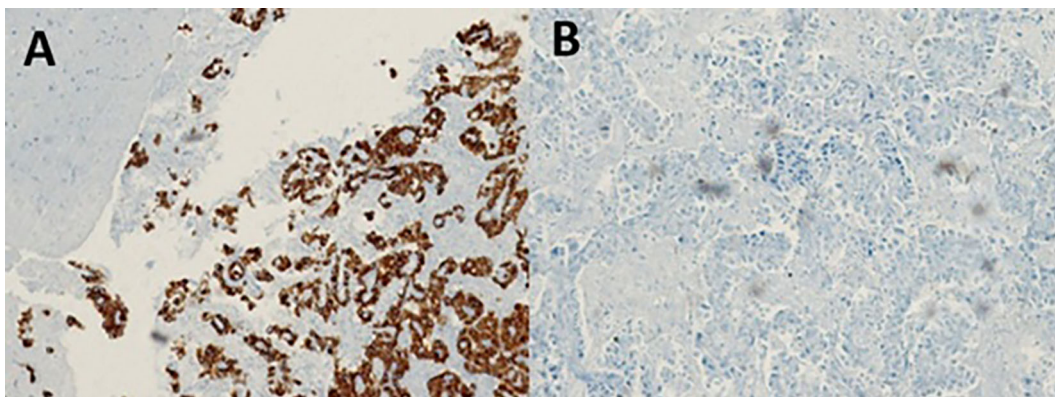


Figure 3. Pathology slides with immunohistochemistry and markers used in unknown primary adenocarcinoma and corresponding to lung adenocarcinoma: A. Atypical cells in the leptomeningeal region with positive staining for CK7; B. Atypical cells in the leptomeningeal region with negative staining for CK20.

With the suggestive result of the PET-CT that the focus of the primary cancer was pulmonary, the patient underwent bronchoalveolar lavage with a transbronchial biopsy without a positive result. For this reason, we decided to perform a stereotactic-guided brain biopsy, whose pathology result was inconclusive, and the pathology service requested a new sample. The patient underwent a new intervention with an open brain biopsy, obtaining samples from the right leptomeningeal region, confirming the diagnosis of poorly differentiated primary non-small cell lung adenocarcinoma (Figure 3). We performed a ventriculoperitoneal shunt due to the hydrocephalus that she presented.

The patient was evaluated by the oncology service, where they applied the Karnofsky Performance State (KPS) scale,⁵ in which the patient obtained 40 points. Then, they opted for a therapeutic plan of radiotherapy and subsequent chemotherapy.

Three months after diagnosis, she has completed 10 sessions of brain radiotherapy with no adverse events and is undergoing outpatient chemotherapy. The patient's family reports an improvement in the attention and language level, with better fluency. Neuropsychological tests showed an improvement of the cognitive disorder (MMSE: 15 and MoCA: 19).

Discussion

Classic leptomeningeal metastasis is the result of the infiltration of cancer cells in the meninges.⁶ Breast cancer, melanoma, and lung cancer, which occurs in up to 5% of cases, are the neoplasms with greater tropism for the meninges.⁷ This pathology does not require a biopsy for its diagnosis and the classification according to the European Society of Neuro-oncology is based on the cerebrospinal fluid study and the magnetic resonance images. However, performing a biopsy is recommended when there is no previously demonstrated solid cancer, since the oncological treatment will depend on this.⁸

In this report, we describe a difficult diagnosis case, with a particular pattern of leptomeningeal metastasis of unknown primary origin called focal leptomeningeal disease.⁹ Previous reports have described this entity in non-small cell lung cancer patients. They found in them a higher survival compared to classic leptomeningeal disease patients after a targeted treatment specific to the cancer cells mutation.^{10,11}

Regarding the physiopathology of this disease, it has been postulated that the perivascular spaces with the perivascular channels act as a bridge through angiotropic mechanisms.^{9,12,13} In addition, the association of dural thickening and enhancement has been reported, as a radiological expression of tumor involvement and venous congestion secondary to the perivascular involvement of the disease.^{9,11,14}

The neurological symptoms associated with this condition have been described as less severe than those associated with classic leptomeningeal disease. The most frequent symptoms in focal leptomeningeal disease were motor deficit, headache, and cognitive impairment.^{9,15} In our patient, we also reported a self-limited focal onset epileptic seizure, being consistent with the right parietal structural lesion.

The cases described by Dasgupta *et al.* have the same radiological pattern of focal leptomeningeal enhancement in patients with epidermal growth factor receptor-mutated non-small cell lung cancer treated with tyrosine kinase inhibitors and radiation therapy.⁹ However, our case is atypical because solid lung cancer was not demonstrated as in the previous case. Then, we highlight PET-CT as a highly supportive tool for diagnosis in cancer of unknown primary origin.¹⁶

We do not consider COVID-19 history as an important element for the onset of temporal cognitive impairment. Our patient presented additional clinical manifestations that do not correspond to this association,¹⁷ as mutism, focal neurological deficit, and epileptic seizure. This could be confirmed after observing the leptomeningeal hypersignal in the MRI, then, we extended the study searching for other etiologies.

The main strength of our case report was the access to important diagnostic tests, including PET-CT and immunohistochemistry, which allowed us to identify the final diagnosis despite the atypical manifestation of the disease. However, the main limitation was the limited follow-up time (no more than three months), thus, we were unable to perform more clinical and radiological controls.

In conclusion, this is an atypical case of leptomeningeal metastasis in the absence of solid cancer in the tomography, demonstrated with the support of PET-CT and histologically confirmed by leptomeningeal biopsy. Focal leptomeningeal disease is an entity that should be considered as a differential diagnosis in focal leptomeningitis cases with rapidly cognitive impairment progression. Timely diagnosis and adequate oncological management can increase patients' survival.

Ethical approval and informed consent

This article has been approved by the institutional ethics committee of the Red Prestacional Rebagliati (REGISTER 086-2021). We obtained the patient's written informed consent to participate in this study and for the publication of images and data included in this case report.

Authors' contributions

MAV, MMAC, LB, LRK, EBA, CSR, EVQH treated the patient, interpreted the neuroradiologic imaging and laboratory markers. All authors participated in design, writing, critical review and approved the final version of the manuscript.

Data availability

All data underlying the results are available as part of the article and no additional source data are required.

Acknowledgements

We want to thank the health personnel who remain firm on the front line during this COVID-19 pandemic. In addition, we want to thank the Universidad San Ignacio de Loyola for the financial support in the payment of the article processing charge.

References

1. Graber JJ, Kesari S: **Leptomeningeal metastases**. *Curr. Treat. Options Oncol.* 2018; **19**(1): 1–14.
[Publisher Full Text](#)
2. Cheng H, Perez-Soler R: **Leptomeningeal metastases in non-small-cell lung cancer**. *Lancet Oncol.* 2018; **19**(1): e43–e55.
[Publisher Full Text](#)
3. Escobar JJ, Burnam A, Karno M, et al.: **Use of the Mini-Mental State Examination (MMSE) in a community population of mixed ethnicity: Cultural and linguistic artifacts**. *J. Nerv. Ment. Dis.* 1986; **174**: 607–614.
[PubMed Abstract](#) | [Publisher Full Text](#)
4. Nasreddine ZS, Phillips NA, Bédirian V, et al.: **The Montreal Cognitive Assessment, MoCA: a brief screening tool for mild cognitive impairment**. *J. Am. Geriatr. Soc.* 2005; **53**(4): 695–699.
[Publisher Full Text](#)
5. Crooks V, Waller S, Smith T, et al.: **The use of the Karnofsky Performance Scale in determining outcomes and risk in geriatric outpatients**. *J. Gerontol.* 1991; **46**(4): M139–M144.
[PubMed Abstract](#) | [Publisher Full Text](#)
6. Patil S, Rathnum KK: **Management of leptomeningeal metastases in non-small cell lung cancer**. *Indian J. Cancer.* 2019; **56**(5): 1–59.
[PubMed Abstract](#) | [Publisher Full Text](#)
7. Sahebjam S, Forsyth PA, Smalley KS, et al.: **Experimental treatments for leptomeningeal metastases from solid malignancies**. *Cancer Control.* 2017; **24**(1): 42–46.
[PubMed Abstract](#) | [Publisher Full Text](#)
8. Alexander M, Lin E, Cheng H: **Leptomeningeal metastases in non-small cell lung cancer: optimal systemic management in NSCLC with and without driver mutations**. *Curr. Treat. Options Oncol.* 2020; **21**(9): 1–15.
[Publisher Full Text](#)
9. Dasgupta A, Moraes F, Rawal S, et al.: **Focal Leptomeningeal Disease with Perivascular Invasion in EGFR-Mutant Non-Small-Cell Lung Cancer**. *Am. J. Neuroradiol.* 2020; **41**(8): 1430–1433.
[PubMed Abstract](#) | [Publisher Full Text](#)
10. Lin C-Y, Chang C-C, Su P-L, et al.: **Brain MRI imaging characteristics predict treatment response and outcome in patients with de novo brain metastasis of EGFR-mutated NSCLC**. *Medicine.* 2019; **98**: e16766.
[Publisher Full Text](#)
11. Sener U, Lin A, Yang J, et al.: **Radiographic Appearance of Leptomeningeal Disease in Patients with EGFR Mutated Non-Small Cell Lung Carcinoma Treated with Tyrosine Kinase Inhibitors—A Case Series (P2. 6-032)**. AAN Enterprises; 2019; vol. 8: CNS42.
[PubMed Abstract](#) | [Publisher Full Text](#)
12. Groeschel S, Chong WK, Surtees R, et al.: **Virchow-Robin spaces on magnetic resonance images: normative data, their dilatation, and a review of the literature**. *Neuroradiology.* 2006; **48**(10): 745–754.
[PubMed Abstract](#) | [Publisher Full Text](#)
13. Yamaguchi Y, Wada M, Kimihira L, et al.: **Cognitive impairment due to widespread enlarged perivascular spaces**. *Radiol. Case Rep.* 2021; **16**(9): 2640–2645.
[PubMed Abstract](#) | [Publisher Full Text](#)
14. Bhambhani HP, Rodrigues AJ, Umeh-Garcia MC, et al.: **Leptomeningeal carcinomatosis: Molecular landscape, current management, and emerging therapies**. *Neurosurg. Clin.* 2020; **31**(4): 613–625.
[PubMed Abstract](#) | [Publisher Full Text](#)
15. Wang N, Bertalan MS, Brastianos PK: **Leptomeningeal metastasis from systemic cancer: review and update on management**. *Cancer.* 2018; **124**(1): 21–35.
[PubMed Abstract](#) | [Publisher Full Text](#)
16. Bolton RCD, Calapaquí-Terán AK, Giammarile F, et al.: **Role of 18F-FDG-PET/CT in establishing new clinical and therapeutic modalities in lung cancer. a short review**. *Revista Española de Medicina Nuclear e Imagen Molecular (English Edition).* 2019; **38**(4): 229–233.
[PubMed Abstract](#) | [Publisher Full Text](#)
17. Mattioli F, Stampatori C, Righetti F, et al.: **Neurological and cognitive sequelae of Covid-19: a four month follow-up**. *J. Neurol.* 2021; **268**(12): 4422–4428.
[PubMed Abstract](#) | [Publisher Full Text](#) | [Free Full Text](#)

Open Peer Review

Current Peer Review Status:  

Version 2

Reviewer Report 23 September 2022

<https://doi.org/10.5256/f1000research.138679.r151090>

© 2022 Amado Tineo J. This is an open access peer review report distributed under the terms of the [Creative Commons Attribution License](#), which permits unrestricted use, distribution, and reproduction in any medium, provided the original work is properly cited.



José Percy Amado Tineo 

Facultad de Medicina Humana, Universidad Nacional Mayor de San Marcos, Lima, Peru

I have reviewed the answers of the authors and they seem adequate to me. I have no further observations.

Competing Interests: No competing interests were disclosed.

Reviewer Expertise: Internal medicine

I confirm that I have read this submission and believe that I have an appropriate level of expertise to confirm that it is of an acceptable scientific standard.

Version 1

Reviewer Report 06 September 2022

<https://doi.org/10.5256/f1000research.134420.r146382>

© 2022 Amado Tineo J. This is an open access peer review report distributed under the terms of the [Creative Commons Attribution License](#), which permits unrestricted use, distribution, and reproduction in any medium, provided the original work is properly cited.



José Percy Amado Tineo 

Facultad de Medicina Humana, Universidad Nacional Mayor de San Marcos, Lima, Peru

I appreciate the opportunity to review this case report, I find it very interesting and well written.

I have some observations that I will mention:

- I do not think it is necessary to include the name of the country in the title, since the place of origin is not relevant in this case.
- It would be necessary to include a comment on the association between COVID-19 and cognitive impairment, giving more detail to this history in the patient, since it has a temporal relationship with the onset of cognitive impairment (4 months)
- Although it is true that the PET-SCAN shows lesions suggestive of lung cancer, this could not be confirmed by pathological anatomy, can we comment on the possibility that the origin of the adenocarcinoma found in the meninges is from another organ?
- It would be appropriate to know the final destination of the patient, if chemotherapy was completed after radiotherapy and her survival, considering that having distant metastases would be a clinical stage IV with low short-term survival.
- When writing bibliographical references, the first 6 authors are usually mentioned and in several references only 3 are mentioned.

Is the background of the case's history and progression described in sufficient detail?

Yes

Are enough details provided of any physical examination and diagnostic tests, treatment given and outcomes?

Yes

Is sufficient discussion included of the importance of the findings and their relevance to future understanding of disease processes, diagnosis or treatment?

Yes

Is the case presented with sufficient detail to be useful for other practitioners?

Yes

Competing Interests: No competing interests were disclosed.

Reviewer Expertise: Internal medicine

I confirm that I have read this submission and believe that I have an appropriate level of expertise to confirm that it is of an acceptable scientific standard, however I have significant reservations, as outlined above.

Author Response 14 Sep 2022

Diego Urrunaga-Pastor, Universidad San Ignacio de Loyola, Lima, Peru

Thanks for the comments. We answered to comments in detail.

1. I do not think it is necessary to include the name of the country in the title, since the place

of origin is not relevant in this case.

Answer: Thanks for the comment. We have deleted the country of origin from the title case.

2. It would be necessary to include a comment on the association between COVID-19 and cognitive impairment, giving more detail to this history in the patient, since it has a temporal relationship with the onset of cognitive impairment (4 months).

Answer: Thanks for the comment. We added in first paragraph from case report section that our patient COVID-19 pneumonia did not have severity criteria. In addition, we do not consider COVID-19 history as an important element for the onset of temporal cognitive impairment because the patient presented additional clinical manifestations that do not correspond to this association (1), as mutism, focal neurological deficit, and epileptic seizure. This could be confirmed after observing the leptomenigeal hypersignal in the MRI, then, we extended the study searching for other etiologies. We added a paragraph in discussion about this topic.

3. Although it is true that the PET-SCAN shows lesions suggestive of lung cancer, this could not be confirmed by pathological anatomy, can we comment on the possibility that the origin of the adenocarcinoma found in the meninges is from another organ?

Answer: Thanks for the comment. We obtained samples from the right leptomenigeal region through a brain biopsy, confirming the diagnosis of poorly differentiated primary non-small cell lung adenocarcinoma (Figure 3). We performed a ventriculoperitoneal shunt due to the hydrocephalus that she presented. This was described in the case report.

4. It would be appropriate to know the final destination of the patient, if chemotherapy was completed after radiotherapy and her survival, considering that having distant metastases would be a clinical stage IV with low short-term survival.

Answer: Thanks for the comment. We agree with the importance of follow-up in this patient, however, we could only follow-up her to 3 months. Then, we described it as a limitation.

5. When writing bibliographical references, the first 6 authors are usually mentioned and in several references only 3 are mentioned.

Answer: Thanks for the comment. We reviewed the references and most of them had fewer than 6 authors, so we did not mention et al.

References

1. Mattioli F, Stampatori C, Righetti F, Sala E, Tomasi C, De Palma G. Neurological and cognitive sequelae of Covid-19: a four month follow-up. *Journal of neurology*. 2021;268(12):4422-8.

Competing Interests: No competing interests were disclosed.

Reviewer Report 23 August 2022

<https://doi.org/10.5256/f1000research.134420.r146386>

© 2022 Cadena-Sanabria M. This is an open access peer review report distributed under the terms of the [Creative Commons Attribution License](#), which permits unrestricted use, distribution, and reproduction in any medium, provided the original work is properly cited.



Miguel Oswaldo Cadena-Sanabria 

¹ Internal Medicine Department, Industrial University of Santander, University Hospital of Santander, Bucaramanga, Colombia

² Universidad Autónoma de Bucaramanga, Bucaramanga, Colombia

This case highlights the importance of a standardized and progressive approach to elderly people with rapidly progressive cognitive impairment, whose etiologies include paraneoplastic or metastatic lesions. To highlight the gradual development of microbiological, cytological and imaging diagnostic aids. The PET Scan is becoming more and more important in the determination of hypermetabolic lesions that guide towards a possible tumor lesion. It is also important to discourage studies with tumor markers, since in this case they only generated confusion of a possible primary at the gastrointestinal level. Since it is lung adenocarcinoma, it is important to document the presence of mutated epidermal growth factor receptor [EGFR] and anaplastic lymphoma kinase [ALK] translocation due to its implications for immunotherapy and prognosis, as well as thromboembolic risk. Finally, being an older woman, I share a reference about the need to carry out an approach guided by her comprehensive geriatric assessment. Here the authors share with us the evolution in neuropsychological tests, evidencing the positive impact of radiotherapy intervention.

References

1. Cadena Sanabria MO, López Ramírez JH, Insuasty Enriquez JS, Santacruz Escudero JG, et al.: Importancia de la valoración geriátrica integral en el manejo de pacientes con cáncer. *Médicas UIS*. **25** (2). [Reference Source](#)

Is the background of the case's history and progression described in sufficient detail?

Yes

Are enough details provided of any physical examination and diagnostic tests, treatment given and outcomes?

Yes

Is sufficient discussion included of the importance of the findings and their relevance to future understanding of disease processes, diagnosis or treatment?

Yes

Is the case presented with sufficient detail to be useful for other practitioners?

Yes

Competing Interests: No competing interests were disclosed.

Reviewer Expertise: Geriatric assessment, frailty, cognitive disorders, onco-geriatrics

I confirm that I have read this submission and believe that I have an appropriate level of expertise to confirm that it is of an acceptable scientific standard.

The benefits of publishing with F1000Research:

- Your article is published within days, with no editorial bias
- You can publish traditional articles, null/negative results, case reports, data notes and more
- The peer review process is transparent and collaborative
- Your article is indexed in PubMed after passing peer review
- Dedicated customer support at every stage

For pre-submission enquiries, contact research@f1000.com

F1000Research