




Contents lists available at ScienceDirect

Journal of Clinical Tuberculosis and Other Mycobacterial Diseases

journal homepage: www.elsevier.com/locate/jctube

Mycobacterium iranicum septic arthritis and tenosynovitis



Eugene M. Tan*, Aaron J. Tande, Douglas R. Osmon, John W. Wilson

Division of Infectious Diseases, Mayo Clinic, 200 First Street SW Rochester MN, 55905, USA

ARTICLE INFO

Article history:

Received 4 February 2017

Revised 16 May 2017

Accepted 19 May 2017

Keywords:

Mycobacterium

Iranicum

Septic arthritis

Tenosynovitis

ABSTRACT

Mycobacterium iranicum is a newly reported nontuberculous mycobacterial (NTM) species that has been previously isolated in twelve patients. Our report presents the thirteenth known case of *M. iranicum*, which caused septic arthritis of the right third proximal interphalangeal joint and associated tenosynovitis in a 39-year-old female following a rose thorn injury.

© 2017 The Authors. Published by Elsevier Ltd.

This is an open access article under the CC BY-NC-ND license.

(<http://creativecommons.org/licenses/by-nc-nd/4.0/>)

Introduction

Nontuberculous mycobacteria (NTM) comprise over 175 species and are ubiquitous in soil, water, and animals. [1,2] *Mycobacterium iranicum* is a novel NTM species that has been isolated in the Americas, Asia, and Europe. However, this species was named *iranicum* as attention was first drawn to this organism in Iran. In the few case reports that exist worldwide, *M. iranicum* has been isolated from various sites, including sputum, cerebrospinal fluid, and a cutaneous wound. *M. iranicum* was identified as a new species based on 16S rRNA gene sequencing that showed the characteristic signature of rapidly growing mycobacteria but also showed uniqueness in its pattern of four-nucleotide deletions and *rpoB* gene sequences. It is most closely related to *M. gilvum* but also shares similarities with *M. farcinogenes*, *M. senegalense*, *M. fortuitum*, and *M. houstonense*. [3] The following report illustrates a case of *M. iranicum* septic arthritis and tenosynovitis.

Case report

A 39-year-old female with type 2 diabetes mellitus (hemoglobin A1c 7.9%) sustained a penetrating rose thorn injury on the dorsal aspect of her right third proximal interphalangeal (PIP) joint. Over the course of four months, she experienced gradual progressive pain, edema, and inability to completely flex the finger. She had no other pertinent exposures to animals, insects, or water. Her symptoms progressed over a four-month period despite being treated

twice with oral clindamycin. She did not describe any constitutional symptoms or fevers.

Physical examination was significant for edema around the right third PIP joint, which also had a 15-degree flexion contracture. There was no erythema or concern for cellulitis. Laboratory evaluation revealed a normal erythrocyte sedimentation rate (ESR) of 25 mm/h but an elevated C-reactive protein (CRP) of 10.1 mg/L (reference ≤ 8.0 mg/L). Given the chronicity of her symptoms and the exposure to a rose thorn, a *Sporothrix* serology was obtained and was negative.

Magnetic resonance imaging (Fig. 1) showed edematous changes in the third finger centered about the PIP joint. There was a small amount of fluid and mild enhancement after contrast administration around the PIP joint. Findings were nonspecific but compatible with synovitis and periarticular inflammation. There was no evidence for osteomyelitis.

Given the persistent edema in the finger, she was taken to the operating room for an irrigation and debridement. Intraoperative findings (Fig. 2) included edema around the third PIP joint suggestive of effusion or synovial thickening. Brown tissue was found within the joint as well as between the flexor digitorum superficialis and flexor digitorum profundus muscles. Post-operatively, she was provided two weeks of cephalexin for possible bacterial infection.

Twenty days after her irrigation and debridement, growth of an acid-fast bacillus was detected from one mycobacterial culture of the PIP joint and subsequently identified as *Mycobacterium iranicum*. Five specimens were collected during debridement. No other pathogen was identified in culture. Using a broth dilution micro-titer susceptibility platform as per Clinical Laboratory and Standards Institute (CLSI) guidelines [4], the organism was susceptible to cefoxitin, moxifloxacin, tobramycin, imipenem,

* Corresponding author.

E-mail addresses: tan.eugene@mayo.edu (E.M. Tan), tande.aaron@mayo.edu (A.J. Tande), osmon.douglas@mayo.edu (D.R. Osmon), wilson.john@mayo.edu (J.W. Wilson).

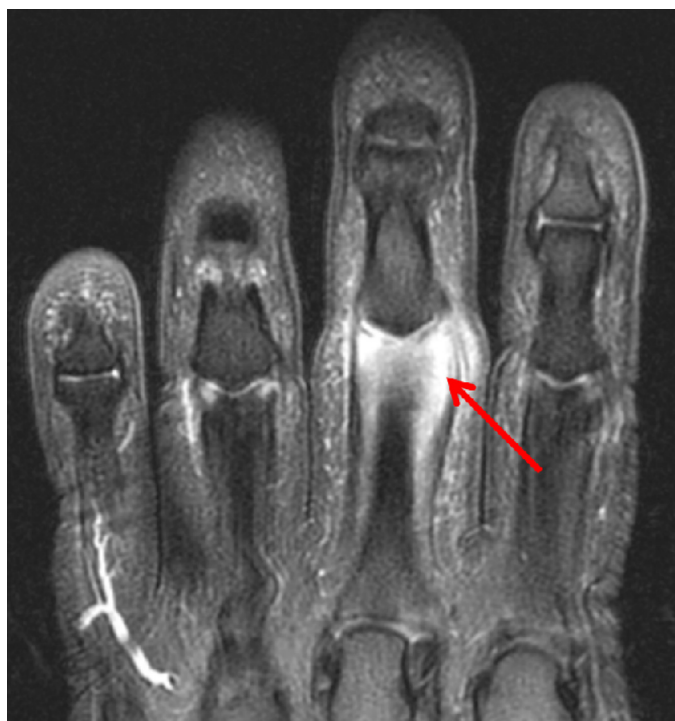

Fig. 1. Coronal T2 magnetic resonance imaging (MRI) of the palmar aspect of the right hand illustrates an edematous third proximal interphalangeal joint with mild enhancement (red arrow) after contrast administration, suggesting synovitis.

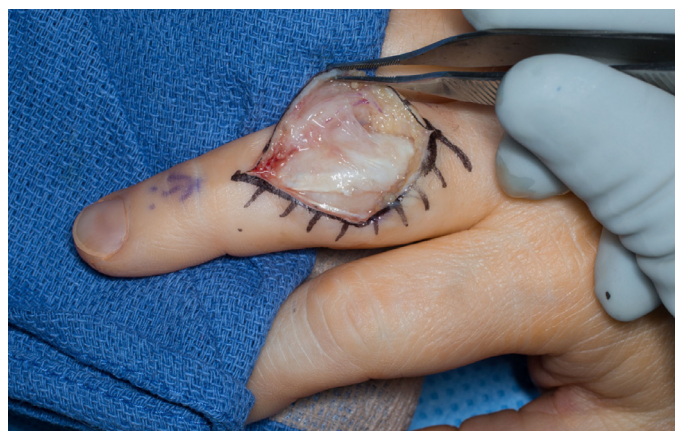

Fig. 2. Intraoperative findings during irrigation and debridement included edema around the third proximal interphalangeal joint suggestive of effusion or synovial thickening.

clarithromycin, doxycycline, trimethoprim-sulfamethoxazole, ciprofloxacin, amikacin, minocycline, and linezolid. She was therefore initiated on clarithromycin 500 mg twice a day and minocycline 100 mg twice a day for a planned duration of three to six months. She experienced significant improvement on this antibiotic regimen. As she had partially improved at the three-month time point, the decision was made to extend the treatment course for another three months. At the time of this report, she completed five months of therapy and improved significantly without any adverse drug events.

Discussion

M. iranicum is a rapidly growing mycobacteria that produces a yellow-orange pigment [5]. Rapidly growing mycobacteria are typ-

ically detectable within 3–7 days of subculture; however, this time to growth detection may be delayed if there is a low organism burden, which may have been the case in this patient [6].

It can grow at 25°C and 37°C on various media including Löwenstein-Jensen medium and solid egg-media. Biochemical characteristics include positivity for urease, iron uptake, tellurite reduction, arylsulfatase, and heat-stable (68°C) catalase. [3] Aside from culture methods, sequencing of the 16S rRNA gene and 65-kDa heat shock protein gene (*hsp95*) can confirm identification of *M. iranicum*. [7]

In a comparative genome analysis, *M. iranicum* was found to have a close genetic association with other environmental mycobacteria. [8] Based on phylogenetic analysis, *M. iranicum* may be closely related to another rapid grower *M. gilvum*. [9] It may have acquired virulence genes via horizontal transfer with other mycobacteria, Gram-positive bacteria (*Rhodococcus*, *Corynebacterium*, *Nocardia*), and Gram-negative bacteria (*Achromobacter*). [8]

M. iranicum has been isolated in various regions including Iran; the Mediterranean (Italy, Greece); Northern Europe (the Netherlands, Sweden); the United States; and Asia (Malaysia, Japan). [7–9] It is a newly discovered species, with the first documented case reports dating back to 2005 [3]. Prior to the publication of this current report, *M. iranicum* was isolated in both immunocompetent patients and those with immunocompromising conditions, including renal transplantation, cancer, diabetes mellitus, Crohn's disease, and human immunodeficiency virus (HIV) infection (Table 1). [3,7,8]

As with many other NTM species, the isolation of *M. iranicum* must be interpreted with caution before establishing pathogenicity, especially with this uncommon species. *M. iranicum* was not always deemed clinically significant in past cases (Table 2). For example, isolates from the cerebrospinal fluid of a 57-year-old Greek female and from the sputum of an 89-year-old Dutch female were deemed clinically insignificant. [3] Though six isolates were from sputum, these did not meet the American Thoracic Society (ATS) criteria for clinical significance. [5] *M. iranicum*, however, was implicated as a true pathogen in a Japanese patient who developed peritonitis after washing his peritoneal dialysis catheter exit site with tap water, which may have been contaminated with soil after he had finished cultivating flowers. [9] *M. iranicum* was also isolated three times from a hand wound of a renal transplant recipient, who was subsequently treated with amikacin. [3]

Extra-pulmonary NTM disease is typically treated with at least two antibiotics to which the organism is susceptible. [1,9,10] Based on minimum inhibitory concentrations of five clinical strains, *M. iranicum* is usually susceptible to amikacin, cefoxitin, clarithromycin, ethambutol, imipenem, minocycline, sulfamethoxazole, and linezolid. However, it may be intermediately susceptible to ciprofloxacin, rifampicin, and streptomycin. [3] Given the relative paucity of clinical data to base treatment recommendations for *M. iranicum* infections, one must clinically interpret drug susceptibility testing results with caution. In past case reports, combinations containing amikacin, ciprofloxacin, levofloxacin, minocycline, or clarithromycin have been used successfully [3,5,7,9]. Treatment duration was three months in patients with other sites of infection, but must be based on the syndrome being treated. [7,9]

In summary, our case is the first known report of *M. iranicum* causing an osteoarticular infection. Our case's environmental exposure history, chronicity of symptoms, and lack of response to prior clindamycin usage all collectively favor the true pathogenic role of *M. iranicum* in her septic arthritis and tenosynovitis. Sterile saline was used in the operating room, so the likelihood of water contamination is low. Most importantly, the patient's favorable response to anti-mycobacterial therapy supports the pathogenic role of *M. iranicum*. However, the *M. iranicum* was isolated in only one culture. Though previously considered to be less important mem-

Table 1
Prior human isolates of *Mycobacterium iranicum* that were treated as pathogenic.

Demographics [reference]	Site of culture	Cultures (positive/total)	Clinical presentation	Past medical history	Treatment
60-year-old female [3]	Bronchoalveolar lavage	2/2	Chronic lung disease	Lung disease	Amikacin, ciprofloxacin
44-year-old male [7]	Bronchoalveolar lavage	2/3	Pneumonia	Human immunodeficiency virus, chronic obstructive pulmonary disease	Ciprofloxacin and amikacin for 3 months
18-year-old male [3]	Hand wound	3/3	Hand wound	Renal transplant	Amikacin
68-year-old male [9]	Dialysate	Unknown	Peritonitis (retained peritoneal dialysis catheter)	End-stage renal disease	Levofloxacin, clarithromycin, IP imipenem, minocycline x 6 months

Table 2
Prior human isolates of *Mycobacterium iranicum* that had an unknown pathogenic role and were not treated.

Demographics [reference]	Site of culture	Cultures (positive/total)	Clinical presentation	Past medical history
74-year-old male [3]	Sputum	1/1	Chronic obstructive pulmonary disease	Unknown
26-year-old female [3]	Sputum	Unknown	Unknown	Unknown
89-year-old female [3]	Sputum	1/3	Pneumonia	Unknown
21-year-old female [3]	Sputum	1/3	Leukopenia	Cystic fibrosis, Crohn's disease
Male of unknown age [8]	Sputum	Unknown	Suspected tuberculosis	Coronary artery disease, diabetes mellitus
58-year-old female [5]	Sputum	Unknown, 3 total cultures	Pneumonia	Bronchiectasis
57-year-old female [3]	Cerebrospinal fluid	1/1	Meningitis	Unknown
Male of unknown age [3]	Cerebrospinal fluid	1/1	Unknown	Cancer of unknown type

bers of rapidly growing mycobacteria, human disease caused by *M. iranicum* is becoming increasingly recognized [3].

Consent

Written informed consent was obtained from the patient for publication of this case report. A copy of the written consent is available for review by the Editor-in-Chief of this journal on request.

Funding

This work did not receive any specific grant from funding agencies in the public, commercial, or not-for-profit sectors.

References

- [1] Griffith DE, et al. An official ATS/IDSA statement: diagnosis, treatment, and prevention of nontuberculous mycobacterial diseases. *Am J Respir Crit Care Med* 2007;175(4):367–416.
- [2] *Genus Mycobacterium*. List of prokaryotic names with standing in nomenclature 2016 [cited 2016 December 27, 2016]; Available from: <http://www.bacterio.net/mycobacterium.html>.
- [3] Shojaei H, et al. *Mycobacterium iranicum* sp. nov., a rapidly growing scotochromogenic species isolated from clinical specimens on three different continents. *Int J Syst Evol Microbiol* 2013;63:1383–9 (Pt 4).
- [4] Woods GL, B-EB, Conville PS, Desmond EP, Hall GS, Lin G, et al. Susceptibility testing of *Mycobacteria*, nocardia and other aerobic Actinomycetes. Approved standard, 31. 2nd ed. Clinical and Laboratory Standards Institute; 2011. M24-A2.
- [5] Balakrishnan N, et al. Isolation of a novel strain of *Mycobacterium iranicum* from a woman in the United States. *J Clin Microbiol* 2013;51(2):705–7.
- [6] Kim CJ, et al. Differentiating rapid- and slow-growing mycobacteria by difference in time to growth detection in liquid media. *Diagn Microbiol Infect Dis* 2013;75(1):73–6.
- [7] Hashemi-Shahraki A, et al. *Mycobacterium iranicum* infection in HIV-infected patient, Iran. *Emerg Infect Dis* 2013;19(10):1696–7.
- [8] Tan JL, et al. Comparative genomic analysis of *Mycobacterium iranicum* UM_TJL against representative mycobacterial species suggests its environmental origin. *Sci Rep* 2014;4:7169.
- [9] Inagaki K, et al. Successful Treatment of Peritoneal Dialysis-related Peritonitis due to *Mycobacterium iranicum*. *Intern Med* 2016;55(14):1929–31.
- [10] Kasperbauer S, Huitt G. Management of extrapulmonary nontuberculous mycobacterial infections. *Semin Respir Crit Care Med* 2013;34(1):143–50.