Pacing and Clinical Electrophysiology

WILEY
PACE

CASE REPORT OPEN ACCESS

First Report on Atrial Leadless Pacing in an Extra-Cardiac Fontan Patient

Daniel Cortez

Department of Pediatric Cardiology, University of California at Davis, Sacramento, USA

Correspondence: Daniel Cortez (dancortez@ucdavis.edu; dr.danielcortez@gmail.com)

Received: 13 October 2025 | **Revised:** 9 December 2025 | **Accepted:** 15 December 2025

Keywords: atrial pacing | Fontan | leadless pacemaker

ABSTRACT

No reports on atrial leadless pacing have been demonstrated in patients with the extra-cardiac Fontan palliation. We present a case of a patient with an extra-cardiac Fontan and an alternative to pacing for symptomatic bradycardia in the setting of sinus node dysfunction. After internal review board approval, a retrospective case review was performed with follow-up of atrial leadless pacing in a patient with an extra-cardiac Fontan. A 19-year-old male with a medical history of dextro-transposition of the great arteries and valvar and sub-valvar pulmonary stenosis, hypoplastic pulmonary arteries, and an aberrant right coronary artery with eventual Glenn and Fontan palliation had intermittent sinus pauses with a failing epicardial pacemaker system. Given extremely low impedance values and eventual unipolar phrenic pacing after failed bipolar capture, he underwent an atrial pacing study and leadless pacemaker implant. Implant values demonstrated an atrial threshold of 5.5 V at 0.4 ms, impedance at 550 ohms, and sensing at < 1 mV. He was programmed AAIR (VVIR) 60 bpm and discharged on Xarelto 20 mg once a day. Follow-up at 3 months demonstrated no intracardiac thrombus, 8% atrial pacing, threshold of 2.0 V@0.4 ms, impedance of 470 ohms, and R-wave of 1 mV. The estimated device longevity was 17.9 years at last follow-up. Atrial leadless pacing is feasible in the extracardiac Fontan patient from outside of the atrium with higher but acceptable capture threshold, without complication. Larger patient population data sets are needed to assess the safety of this type of pacing long-term.

1 | Introduction

The Fontan operation is a widespread surgical palliation for congenital heart disease patients with a single ventricle, encompassing 0.08–0.4 per 1000 births [1, 2]. Since the 1980s, surgical modifications, including now predominantly the extra-cardiac Fontan, have improved outcomes to a 30-year survival rate of 80%–90% following a completed Fontan operation [3].

Brady-arrhythmias, which can result in significant symptoms, remain a significant aspect of morbidity in these patients [3]. Up to 15% of patients will require pacing due to this sinus node dysfunction [4]. Repeat access via sternotomies or thoracotomies and lack of pacing site availability can further complicate effective pacing in patients with an extra-cardiac Fontan palliation [4]. Transvenous pacing in patients with Fontan palliation has demonstrated success in case studies, but the high surface area of the leads remains a possible thrombus source and risk for pulmonary embolism, life-long anticoagulation is needed when employed [5, 6]. Only ventricular leadless pacing has been demonstrated in patients with the Fontan palliation, including via trans-fenestration or via carotid cutdown; however, no atrial leadless pacing has been demonstrated in patients with the extra-cardiac Fontan palliation [7].

Abbreviations: AAI, atrial pacing, atrial sensing, inhibiting; AR, atrial, right; DDD, dual pacing, dual sensing, inhibiting/tracking; mm, millimeter; ms, milliseconds; mV, millivolts; USA, United States of America; V, volts; VR, ventricle, right.

This is an open access article under the terms of the Creative Commons Attribution-NonCommercial-NoDerivs License, which permits use and distribution in any medium, provided the original work is properly cited, the use is non-commercial and no modifications or adaptations are made.

© 2025 The Author(s). *Pacing and Clinical Electrophysiology* published by Wiley Periodicals LLC.

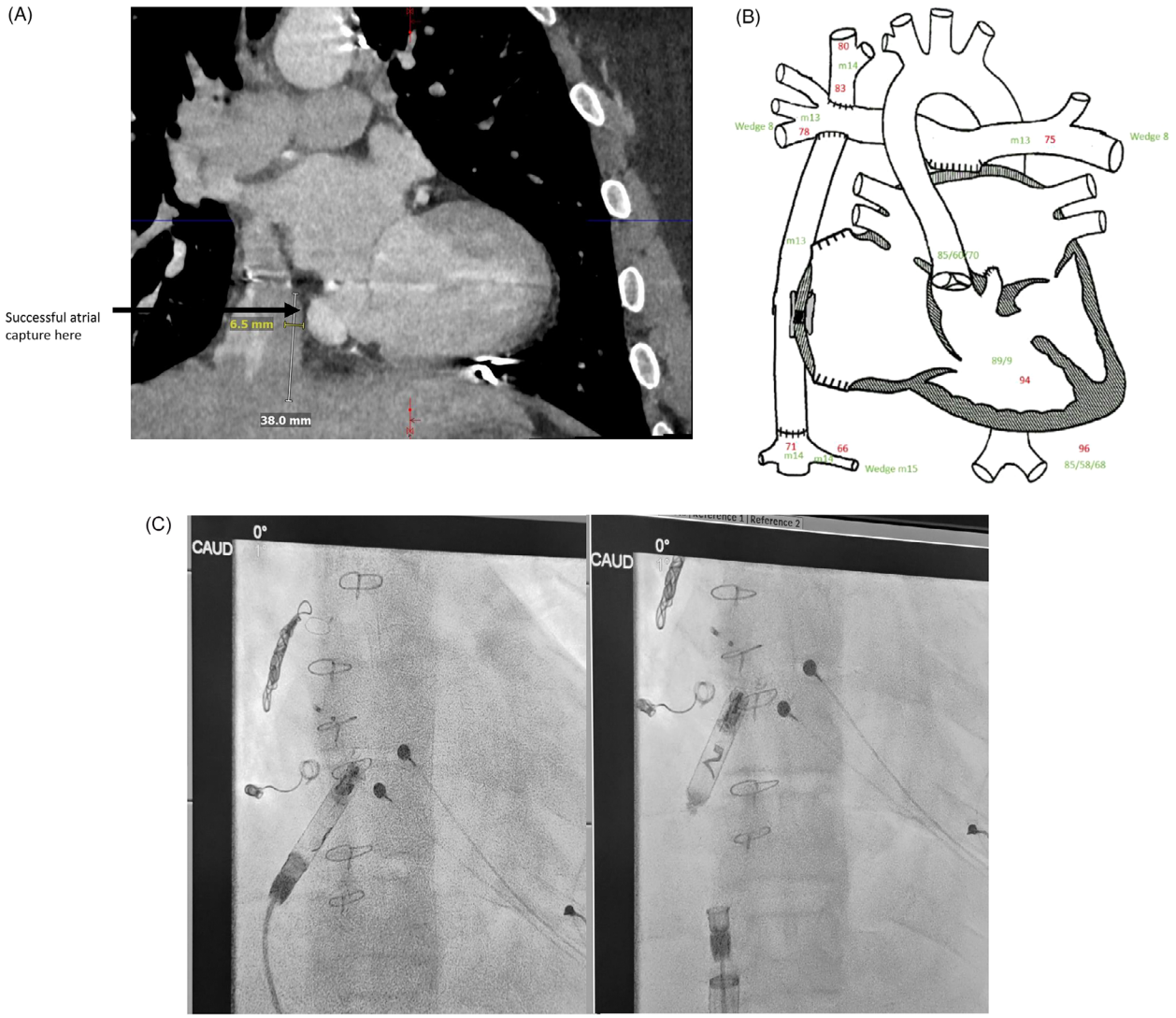

FIGURE 1 | (A) Pre-operative cardiac computerized tomography scan measurements of the extra-cardiac atrial implant site. (B) Cardiac catheterization and figure of Fontan. (C) Antero-posterior view (left) and lateral views (right) prior to and after release. (D): AP (left) and lateral (right) chest x-ray of Aveir VR in atrial pacing position. (E) baseline electrocardiogram. [Color figure can be viewed at wileyonlinelibrary.com]

We report the first successful implantation of an atrial leadless pacemaker in a patient with an extra-cardiac Fontan patient for symptomatic bradycardia in the setting of sinus node dysfunction.

2 | Internal Review Board Review

The study was approved by the internal review board of the University of California at Davis, with consent waived, given the retrospective nature of the case report.

3 | Case Presentation

A 19-year-old male with a medical history of dextro-transposition of the great arteries and valvar and sub-valvar pulmonary stenosis, hypoplastic pulmonary arteries, and an aberrant right coronary artery with eventual Glenn and Fontan palliation and intermittent sinus pauses with a failing epicardial pacemaker system presented for leadless pacemaker implant. The patient had undergone multiple pacemaker-related procedures, including generator changes and lead revisions (1 prior epicardial set of leads). He had chronically low and worsening atrial lead impedance with loss of capture in bipolar configuration and phrenic stimulation in unipolar configuration.

Holter monitoring did show intermittent significant episodes of minute-long pacing when pacing was programmed to AAI 30 beats per min off of beta blockade during monitoring. A pre-operative computerized tomography scan demonstrated adequate margins (38 mm in length and 6.5 mm in width, for implant of the Aveir VR) below the Fontan with atrial tissue next to the inferior vena cava and thus as a potential pacing site (Figure 1A). Given his symptomatic bradycardia and lack of hemodynamic assessment for years, he underwent a combined cardiac catheterization and temporary atrial pacing study. Baseline hemodynamics were noted below (Figure 1B). Initial access was in the right femoral vein under ultrasound guidance, via micropuncture needle and sheath (Cook Medical Bloomington, USA) was with subsequent upsizing of the 8-French sheath,

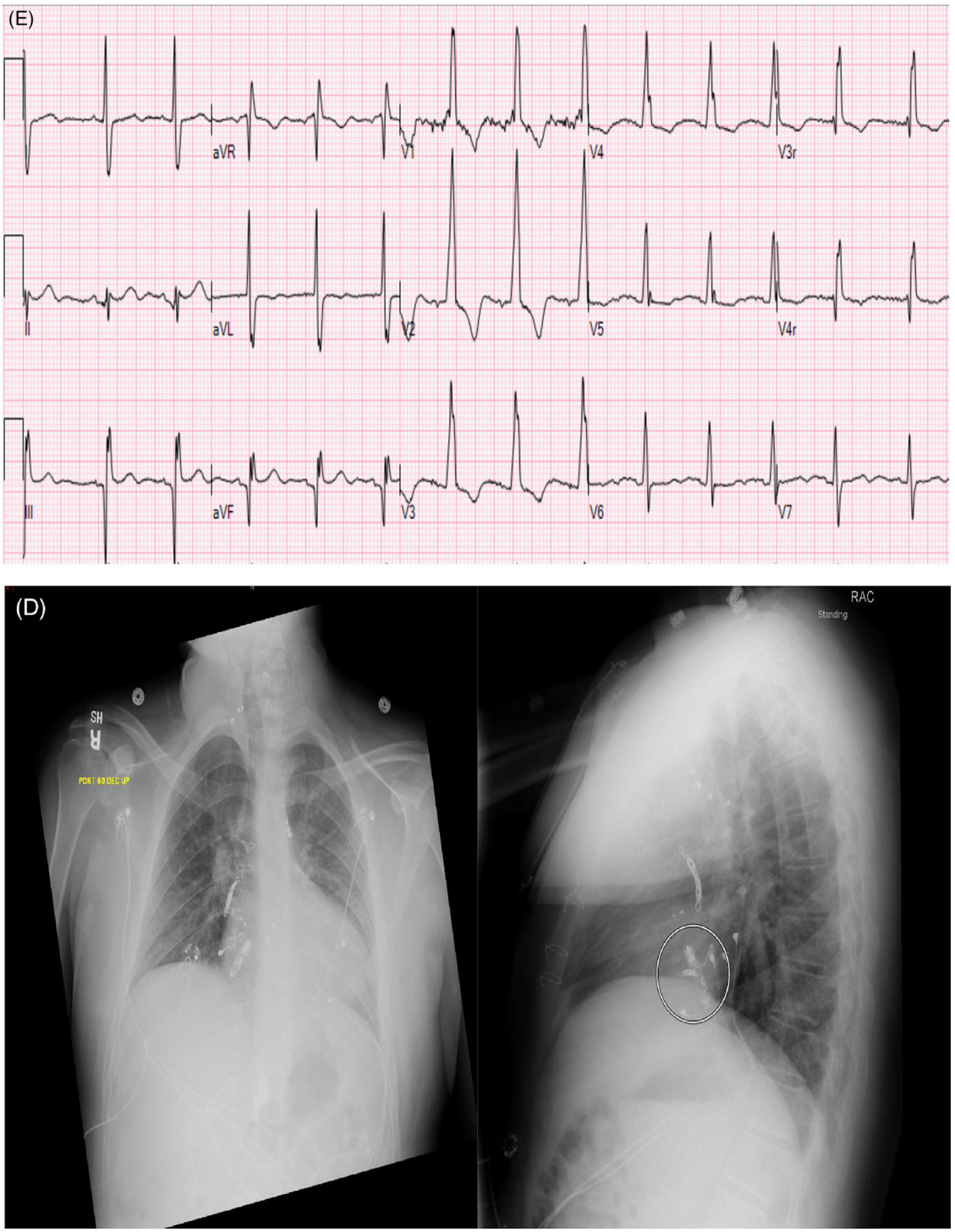

FIGURE 1 | (Continued)

used for the cardiac catheterization, then performed over wire by 2-French size transitions to 24-French, and subsequently the Aveir delivery sheath (Abbott, Sylmar, CA, USA) then advanced over a 0.035″ Amplatz Super Stiff guidewire (Boston Scientific, Marlborough, MA, USA) into the inferior-right atrial junction, below the extra-cardiac Fontan. The Aveir VR, which was chosen due to longevity. To avoid obstruction of the Fontan, a similar pacing site (to the temporary pacing site via Livewire decapolar pacing wire, Abbott, Chicago, USA) was used below the extra-cardiac Fontan within the inferior vena cava/right atrial junction (Figure 1C and see arrow on Figure 1A where favorable pacing and sensing characteristics/injury pattern were noted). Atrial pacing also demonstrated a Wenckebach rate of 200 beats per min. Implant values demonstrated an atrial threshold of 5.5 V at 0.4 ms, impedance at 550 ohms, and a P-wave at 1 mV. The device was programmed for AAI 60 beats per min and discharged on Xarelto 20 mg per day (planned for 6 months). Figure 1D demonstrates a two-view chest x-ray, which demonstrates the position in the anteroposterior (left) and lateral (right) views. Given the patient's baseline electrocardiogram had a normal PR interval and high

Wenckebach rate, only atrial pacing was performed (Figure 1E). Follow-up at 3 months demonstrated no intracardiac thrombus, 8% atrial pacing, a threshold of 2.0 V@0.4 ms, an impedance of 440 ohms, and a P-wave of 1 mV. The predicted longevity at that time was noted to be 17.9 years with output at 2.5 V@0.4 ms.

4 | Discussion

Atrial leadless pacing is possible in a patient with an extracardiac Fontan from outside of the atrium (within the inferior vena cava). Given the disproportionately high rate of sinus node dysfunction in the single ventricle population and failure of epicardial leads, other modalities of atrial pacing should be considered. Ventricular leadless pacing in Fontan patients has been demonstrated via trans-fenestration versus carotid cut-down, although these typically require lifelong anticoagulation, but atrial pacing has yet to be demonstrated in the extra-cardiac Fontan patient [7, 8]. Extra-cardiac atrial leadless pacing has not been demonstrated in this population; however, it may offer a way to minimize stroke risk long-term. Given the risk of pulmonary embolism may still exist, at least short-term anticoagulation is still likely warranted.

With atrial leadless pacing as well, Fontan patients may be able to have true atrioventricular synchronous dual-chamber pacing with leadless pacemakers. The question of where to put the ventricular leadless is still worth sorting out. We think there may be extra-cardiac placement locations aside from what has been reported regarding intraventricular placement. Otherwise, similar atrial pacing results were present with transvenous atrial pacing; however, with a clot burden needing consideration, given typically 5 times the surface area [6]. The Aveir AR or Aveir VR devices, with their smaller surface area compared to transvenous leads and a footprint more similar to a heart failure monitoring device, may pose lower thrombotic risk, requiring only short-term anticoagulation [9]. Regarding whether to implant an Aveir AR (32 mm) versus an Aveir VR (38 mm) device in this atrial position, it is always an interesting question given the improved longevity of the Aveir VR device compared to the Aveir AR device, but an active fixation helix is present in the Aveir AR device, and also allows for future upgrade to a dual-chamber system if needed. The Aveir AR device; however, was not used in this case as longevity was the biggest concern without significant concern for the chance of atrioventricular block subsequently. We also recommend atrial pacing to identify atrioventricular block cycle length prior to using an atrial-only device (or the Aveir VR for atrial pacing).

Otherwise, one weakness of the current leadless technology is the lack of electrical arrhythmia recording storage, other than the first 4 electrograms, of atrial fibrillation mode switches only in DDD mode. There is also a lack of ventricular electrogram recording, and no atrial anti-tachycardia pacing is available currently as well. Clearly, more data is needed to support widespread use of this extra-cardiac technique, as epicardial pacing is still the most common and well-studied pacing type in this patient population, and the duration of anticoagulation will need to be considered in this case, especially in patients with open fenestrations, including possibly other types of coatings to reduce thromboses [10]. However, given the apparent reduced risk of infection in leadless devices, as well as other benefits such as reducing baffle obstruction based on smaller size, these devices may have future use in this subpopulation [11]. Additionally, echocardiographic assistance may be considered a helpful adjunct peri-procedurally in these patients.

5 | Conclusion

Stable atrial leadless pacing can be performed within the inferior vena cava below the level of the extracardiac Fontan, without complication and with good short-term follow-up parameters. A larger patient population follow-up is needed to assess the safety of this type of pacing long-term in this population.

Acknowledgments

The always helpful/knowledgable electrophysiology/cardiac catheterization staff at UC Davis.

Funding

The authors have nothing to report.

Conflicts of Interest

Dr. Cortez is a proctor for Abbott Aveir implants, and is a consultant for Abbott educational programs.

Data Availability Statement

Given this is a case report only, the data presented are already available in the manuscript.

References

1. F. Fontan and E. Baudet, "Surgical Repair of Tricuspid Atresia," *Thorax* 26, no.3 (1971): 240–248, https://doi.org/10.1136/thx.26.3.240.

2. W. A. Helbing, J. P. G. van der Ven, E. van den Bosch, and A. J. C. C. Bogers, "State of the Art of the Fontan Strategy for Treatment of Univentricular Heart Disease," *F1000Research* 7, (2018): F1000, https://doi.org/10.12688/f1000research.13792.1.

3. J. Rychik, A. M. Atz, D. S. Celermajer, et al., "Evaluation and Management of the Child and Adult With Fontan Circulation: A Scientific Statement From the American Heart Association," *Circulation* 140, no. 6 (2019): e234–e284, https://doi.org/10.1161/CIR.0000000000000963.

4. M. I. Cohen, N. D. Bridges, J. W. Gaynor, et al., "Modifications to the Cavopulmonary Anastomosis Do Not Eliminate Early Sinus Node Dysfunction," *Journal of Thoracic and Cardiovascular Surgery* 120, no. 5 (2000): 891–900, https://doi.org/10.1067/mtc.2000.109708.

5. W. J. Hoyt, J. P. Moore, K. M. Shannon, P. J. Kannankeril, and F. A. Fish, "Epicardial Atrial Pacing After the Extracardiac Fontan Operation: Feasibility of an Entirely Transvenous Approach," *Journal of Cardiovascular Electrophysiology* 33, no. 1 (2022): 128–133, https://doi.org/10.1111/jce.15285. Epub 2021 Nov 24.

6. I. E. Assaad, T. Pastor, E. O'Leary, et al., "Atrial Pacing in Fontan Patients: The Effect of Transvenous Lead on Clot Burden," *Heart Rhythm* 18, no. 11 (2021): 1860–1867, https://doi.org/10.1016/j.hrthm.2021.06.1191. Epub 2021 Jun 25.

7. C. J. Goulden, D. Khanra, J. Llewellyn, A. Rao, A. Evans, and R. Ashrafi, "Novel Approaches for Leadless Pacemaker Implantation in the Extra-Cardiac Fontan Cohort: Options to Avoid Leaded Systems or Epicardial

Pacing," *Journal of Cardiovascular Electrophysiology* 34, no. 11 (2023): 2386–2392, https://doi.org/10.1111/jce.16072. Epub 2023 Sep 15.

8. P. Hayle, F. Altayeb, A. Hale, A. Rao, and R. Ashrafi, "Case Report Demonstrating Novel Approaches for Leadless Pacemaker Implantation in the Single Ventricle Heart," *European Heart Journal—Case Reports* 9, no. 4 (2025): ytaf146, https://doi.org/10.1093/ehjcr/ytaf146.

9. W. H. Marshall 5th, S. Rajpal , M. L. Mah, et al., "Early Experience and Lessons Learned Using Implanted Hemodynamic Monitoring in Patients With Fontan Circulation," *Journal of the American Heart Association* 12, no. 24 (2023): e031836, https://doi.org/10.1161/JAHA.123.031836. Epub 2023 Dec 8.

10. D. Hao, J. Lin, R. Liu, et al., "A Bio-Instructive Parylene-Based Conformal Coating Suppresses Thrombosis and Intimal Hyperplasia of Implantable Vascular Devices," *Bioactive Materials* 28 (2023): 467–479, https://doi.org/10.1016/j.bioactmat.2023.06.014.

11. M. F. El-Chami, M. Bonner, R. Holbrook, et al., "Leadless Pacemakers Reduce Risk of Device-Related Infection: Review of the Potential Mechanisms," *Heart Rhythm* 17, no. (8) (2020): 1393–1397, https://doi.org/10.1016/j.hrthm.2020.03.019. Epub 2020 Apr 2.