

Arterial and venous injuries: the combined injury conundrum

David J Skarupa,¹ Matthew P Kochuba,¹ David V Feliciano²

¹Department of Surgery,
University of Florida College
of Medicine - Jacksonville,
Jacksonville, Florida, USA

²University of Maryland
School of Medicine, Baltimore,
Maryland, USA

Correspondence to

Dr David J Skarupa; david.
skarupa@jax.ufl.edu

HISTORY

A 35-year-old man presented to the trauma center with two gunshot wounds to the left thigh that were reportedly from a handgun. Prehospital transport time was about 15 minutes and he received 1 L of intravenous crystalloid fluid for hypotension. It was reported that the patient fell after he was shot and that he hit his head and lost consciousness.

EXAMINATION

The patient was pale and diaphoretic on arrival at the trauma center. His blood pressure was 83/53, heart rate was 82 beats per minute, respiratory rate was 18 breaths per minute, and oxygen saturation was 98% on room air. There was a missile wound in the proximal lateral left thigh and another in the distal posterior thigh. He had hard signs of an arterial injury in the left thigh, including arterial bleeding from the distal gunshot wound, an expanding hematoma, and a pulseless left foot, as well as decreased motor function and sensation in the left foot.

MANAGEMENT

A massive transfusion protocol was initiated as X-rays of the left lower extremity were completed (no fracture). After pressure dressing was applied to the site of hemorrhage in the left thigh (distal gunshot wound), the patient was taken to the CT scanner to evaluate for a traumatic brain injury and then to the operating room emergently for exploration of the left thigh.

Skin preparation was applied from the umbilicus to the toes bilaterally and was circumferential on the lower extremities. An incision was made along the left medial thigh to expose the superficial femoral artery (SFA). Nearly circumferential injuries to the distal SFA and popliteal vein at the adductor hiatus (Hunter's canal) were identified. Proximal and distal control with the application of vascular clamps to both vessels was obtained, and systemic heparin (7000 units, or approximately 100U/kg) was administered intravenously.

QUESTION

What would be your next step in management?

- Repair SFA with saphenous vein graft and popliteal vein with panel graft.
- Ligate popliteal vein, reconstruct SFA with polytetrafluoroethylene (PTFE) graft.
- Shunt the SFA and popliteal vein.
- Extra-anatomic bypass of both artery and vein.

MANAGEMENT

The calf was 'milked' to force distal clot out of the popliteal vein. The vessel ends were flushed with

heparinized saline, and brisk bleeding from the vein was seen. A 14 Fr Argyle shunt was then inserted into the popliteal vein. After a thrombectomy was performed in the SFA with a Fogarty balloon catheter and the vessel was flushed with heparinized saline, a 12 Fr Argyle shunt was inserted ([figure 1](#)).

A left below-knee, two-incision, four-compartment fasciotomy was performed in standard fashion. The contralateral greater saphenous vein was then harvested from the saphenofemoral junction to proximal to the right knee. The greater saphenous vein was much smaller in caliber than both the injured SFA and popliteal vein. At that point, the patient was hemodynamically normal after 4 units of packed red blood cells.

QUESTION

What would be your next step in management?

- PTFE graft into SFA, ligate popliteal vein.
- PTFE grafts into SFA and popliteal vein.
- Spatulated saphenous vein into SFA, PTFE graft into popliteal vein.
- Dacron graft into SFA, umbilical vein into popliteal vein.

MANAGEMENT

The popliteal vein was reconstructed first with an 8 mm interposition, heparin-bonded, ringed PTFE graft using an end-to-end, non-spatulated anastomosis with a continuous 6-0 Prolene suture. A continuous Doppler signal was then heard proximal to, within, and distal to the PTFE graft.

A 4 Fr Fogarty balloon catheter was passed proximally and distally into the SFA once again, and some thrombus was removed with good antegrade and retrograde bleeding. The artery was debrided sharply, flushed with heparinized saline again, and dilated with vascular dilators. The ends of the SFA were spatulated to accommodate for the size discrepancy with the greater saphenous vein, and proximal and distal anastomoses were performed with continuous 6-0 Prolene suture with knots at 180° ([figure 2](#)).

A completion arteriogram was performed using a 19 Fr butterfly needle placed into the proximal left SFA and showed patent artery-vein graft anastomoses with brisk filling of the trifurcation and two-vessel run-off to the foot. The patient had a palpable left dorsalis pedis pulse at the conclusion of the procedure.

The patient was continued on therapeutic heparin and antiplatelet therapy (aspirin 81 mg orally daily) postoperatively. The muscles in his leg decompressed quickly. On the fifth postoperative day a

© Author(s) (or their employer(s)) 2021. Re-use permitted under CC BY-NC. No commercial re-use. See rights and permissions. Published by BMJ.

To cite: Skarupa DJ, Kochuba MP, Feliciano DV. *Trauma Surg Acute Care Open* 2021;**6**:e000746.

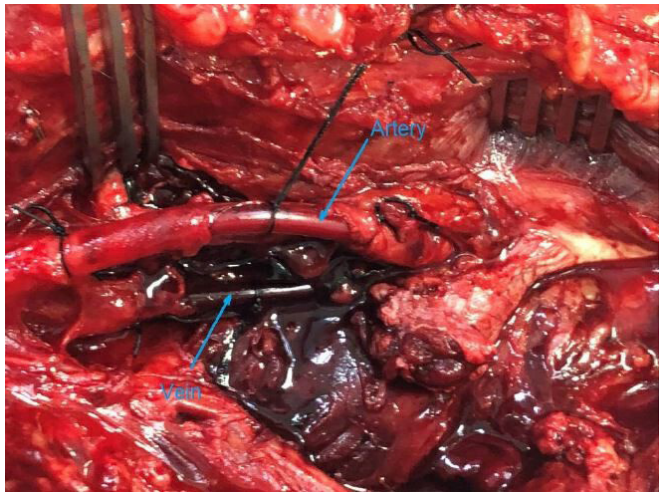


Figure 1 Arterial and venous shunts in place.

delayed primary closure of his medial left leg fasciotomy wound as well as part of his lateral fasciotomy wound was performed. In addition, the remainder of his lateral fasciotomy incision was covered with a split-thickness skin graft.

Prior to discharge the patient had a duplex ultrasonography that showed a patent venous PTFE graft with normal flow and no evidence of thrombus in the deep venous system. He had palpable dorsalis pedis and posterior tibial artery pulses bilaterally that were equal and symmetric. The patient was ambulating with a rolling walker at discharge on day 16 after injury, while still taking Eliquis (apixaban) 5 mg orally two times per day and aspirin 81 mg orally daily.

Surveillance duplex ultrasonography of the left lower extremity arterial and venous systems was performed 4 months postoperatively. The venous ringed PTFE graft was patent with normal spontaneous and phasic flow and no evidence of deep venous thrombus. The arterial duplex showed elevated velocities at the proximal SFA–saphenous vein anastomosis; however, triphasic waveforms were noted distally with well-preserved ankle-brachial indices. The patient underwent an arteriogram that showed a scarred valve near the proximal anastomosis, which was then corrected

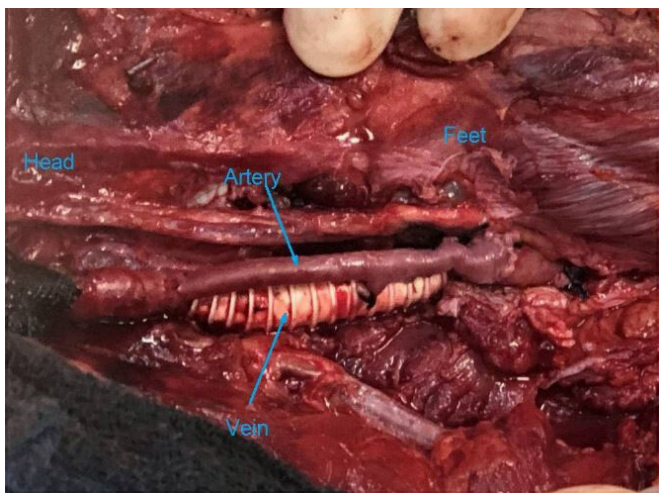


Figure 2 The 8-mm ringed polytetrafluoroethylene interposition graft for venous reconstruction and interposition spatulated reversed greater saphenous vein graft for arterial reconstruction.

with a percutaneous transluminal angioplasty. His oral anti-coagulation was stopped.

DISCUSSION

Venous ligation versus repair still depends on the vein injured, the magnitude of the venous injury, presence and magnitude of associated injuries (especially to an adjacent artery), the patient's hemodynamic status, and the surgeon's training and experience. Kochuba *et al*¹ recently published a review article on the management of injured veins and suggested that combined major arterial and venous injuries in one lower extremity was one scenario when venous reconstruction should be done to avoid the potential detrimental effects of ligation.

Arterial and venous reconstruction should follow the basic principles of vascular surgery once proximal and distal vascular control has been obtained.² Cracked intima, intramural hematomas, or frayed adventitia must be removed from the injured vessel. Complex or long injuries require resection and a primary anastomosis, if no significant tension, or insertion of venous and arterial interposition grafts. If there are combined injuries, the vein is reconstructed first, depending on the arterial ischemia time, to relieve any outflow obstruction and allow for a better initial arterial patency rate.

When there are significant arterial and venous injuries combined with orthopedic injuries, a mangled extremity not mandating immediate amputation, or there has been near exsanguination from a vascular injury in an extremity, the insertion of arterial and venous shunts is appropriate. Temporary intravascular shunts in such patients with vascular injuries in an extremity have been shown to decrease amputation rates when compared with patients who did not undergo shunting.³ In addition, decreasing warm ischemia time improves neuromuscular outcomes. In the patient described, the largest available shunt was inserted into the vein first to ensure outflow.

Postoperative surveillance of the artery-graft suture lines helps evaluate for neointimal hyperplasia, as well as patency of the venous repair. The arterial duplex surveillance in this patient helped to identify a stenosis at the proximal anastomosis, despite no abnormality on physical examination. Data on venous patency vary, but studies have shown that even with early thrombosis subsequent recanalization noted on a 30-day venogram may prevent distal edema.⁴ In addition, patency of venous reconstruction, even if it is just for 24 to 72 hours, may help relax venospasm and allow for the opening of venous collaterals.⁵ Also, such studies will aid in the decision on continuing anticoagulation and/or anti-platelet therapy.

CONCLUSION

Combined arterial and venous injuries can be difficult to manage, especially at the level of the femoropopliteal vessels. In the majority of patients who will require interposition grafts for repair, salvage is improved with early shunting of the vein and artery, followed by reconstruction of the vessels. The sequence of reconstruction is controversial, but the vein was shunted and reconstructed first in this patient.

Funding The authors have not declared a specific grant for this research from any funding agency in the public, commercial or not-for-profit sectors.

Competing interests None declared.

Patient consent for publication Not required.

Provenance and peer review Commissioned; internally peer reviewed.

Open access This is an open access article distributed in accordance with the Creative Commons Attribution Non Commercial (CC BY-NC 4.0) license, which permits others to distribute, remix, adapt, build upon this work non-commercially, and license their derivative works on different terms, provided the original work is properly cited, appropriate credit is given, any changes made indicated, and the use is non-commercial. See: <http://creativecommons.org/licenses/by-nc/4.0/>.

REFERENCES

- 1 Kochuba M, Rozycki GF, Feliciano D. Outcome after ligation of major veins for trauma. *J Trauma Acute Care Surg* 2021;90:e40–9.
- 2 Feliciano DV. Extremity vascular injuries. In: Britt LD, Peitzman AB, Barie PS, eds. *Acute care surgery*. Philadelphia PA: Wolters Kluwer/Lippincott, Williams & Wilkins, 2012:426–37.
- 3 Polcz JE, White JM, Ronaldi AE, Dubose JJ, Grey S, Bell D, White PW, Rasmussen TE. Temporary intravascular shunt use improves early limb salvage after extremity vascular injury. *J Vasc Surg* 2020
- 4 Rich NM, Sullivan WG. Clinical recanalization of an autogenous vein graft in the popliteal vein. *J Trauma* 1972;12:919–20.
- 5 Parry NG, Feliciano DV, Burke RM, Cava RA, Nicholas JM, Dente CJ, Rozycki GS. Management and short-term patency of lower extremity venous injuries with various repairs. *Am J Surg* 2003;186:631–5.