

# Delorme's Procedure: An Effective Treatment for a Full-Thickness Rectal Prolapse in Young Patients

Mohammad Sadegh Fazeli, Ali Reza Kazemeini, Amir Keshvari, Mohammad Reza Keramati

Department of Surgery, Imam Khomeini Medical Center, Tehran University of Medical Sciences, Tehran, Iran

**Purpose:** Delorme's procedure is infrequently applied in young adults because of its assumed higher recurrence rate. The aim of this prospective study was to assess the efficacy of the Delorme's technique in younger adults.

**Methods:** Fifty-two consecutive patients were entered in our study. We followed patients for at least 30 months. Their complaints and clinical exam results were noted.

**Results:** Our study included 52 patients (mean age, 38.44 years; standard deviation, 13.7 years). Of the included patients, 41 (78.8%) were younger than 50 years of age, and 11 (21.1%) were older than 50 years of age. No postoperative mortalities or major complications were noted. Minor complications were seen in 5 patients (9.6%) after surgery. The mean hospital stay was 2.5 days. In the younger group (age  $\leq 50$  years), fecal incontinence was improved in 92.3% (12 out of 13 with previous incontinence) of the patients, and recurrence was seen in 9.75% (4 patients). In the older group (age  $> 50$  years), fecal incontinence was improved in 20% (1 out of 5 with previous incontinence) of the patients, and recurrence was seen in 18.2% (2 patients). In 50% of the patients with a previous recurrence (3 out of 6 patients) following Delorme's procedure as a secondary procedure, recurrence was observed.

**Conclusion:** Delorme's procedure, especially in younger patients, is a relatively safe and effective treatment and should not be restricted to older frail patients. This procedure may not be suitable for recurrent cases.

**Keywords:** Rectal prolapse; Aged; Recurrence; Fecal incontinence

## INTRODUCTION

A full-thickness rectal prolapse is a formidable and debilitating condition that needs surgical management. It can usually be easily diagnosed with a careful history and physical exam. The associated symptoms are tenesmus, incomplete evacuation, obstructed defecation, mucus discharge, bleeding, the need to manually assist in defecation by pushing in the perineum, and functional complaints like incontinence, constipation and even diarrhea.

More than 100 procedures have been described for the correc-

tion of rectal procidentia [1], but no clear procedure of choice exists. The aim of treatment is to repair the prolapse and to resolve functional problems like incontinence and constipation with a low complication rate, an acceptable mortality rate, and a low recurrence rate [2, 3]. Delorme's procedure was initially described in 1900 as a technique to correct an overt rectal mucosal prolapse [4].

Perineal procedures such as the Delorme's technique are reserved for older frail patients with significant comorbidity because a higher recurrence rate is assumed when using perineal procedures [5-7]. However, the recurrence rate in younger ( $\leq 50$  years of age) patients who undergo Delorme's procedure has recently been shown to be comparable with those of transabdominal approaches [8]. Moreover, neurologic complications (including sexual or urologic disturbances) related to extensive dissection within the pelvic region have been reported in transabdominal approaches. This study was performed to investigate the effectiveness of Delorme's procedure and to review the clinical outcomes for patients who underwent that procedure, with a special focus on patients 50 years of age or younger.

Received: February 11, 2013 • Accepted: March 12, 2013

Correspondence to: Mohammad Reza Keramati, M.D.

Department of Surgery, Imam Khomeini Medical Center, Keshavarz Blvd., Tehran 13145-158, Iran

Tel: +98-912-1147406, Fax: +98-912-1147406

E-mail: dr\_morezak@yahoo.com

© 2013 The Korean Society of Coloproctology

This is an open-access article distributed under the terms of the Creative Commons Attribution Non-Commercial License (<http://creativecommons.org/licenses/by-nc/3.0>) which permits unrestricted non-commercial use, distribution, and reproduction in any medium, provided the original work is properly cited.

## METHODS

Our study was a prospective descriptive study conducted from 2009 to 2012. Fifty-two consecutive patients who had undergone Delorme's procedure for treatment of full-thickness rectal prolapses with diameters of 2 to 12 cm were included in the study. Patients with a history of treatment failure with other procedures, including Delorme's procedure, were also included. Patients who had undergone a modified Delorme's procedure were excluded. Preoperational defecography was done in a group of patients, and proctoscopy, rectosigmoidoscopy or anal manometry were done selectively. A complete history, including symptoms, signs, family history, and past surgeries, was taken before the operation. Patients were considered continent if they could hold air, liquid, and solid.

Preoperative mechanical bowel preparation with a polyethylene glycol solution, preoperative administration of an antibiotic preparation of oral erythromycin or metronidazole, and administration of postoperative intravenous antibiotics (three doses) were used in all of patients. Preoperative anticoagulation therapy was administered for deep venous thrombosis prophylaxis if indicated. All the patients signed an informed consent form before surgery. Patients were positioned in the lithotomy position. Spinal anesthesia was carried out in 40 cases (77%), and general anesthesia was done in 12 (23%) according to patient's will.

The standard Delorme's procedure was used. The prolapse was fully extended, and a circumferential mucosal incision, about 2 centimeters above the dentate line, was made after injection of epinephrine solution (1:100,000) into the submucosa. The mucosa was dissected from the muscularis layer. The exposed muscular layer was then folded, and eight plicating sutures of long-acting absorbable material were inserted in the muscular wall of the rectum and then gently tied. Eventually, the cut ends of the mucosa were sutured together.

The patients were usually helped out of bed the evening of the surgery and were fed orally within the first 24 hours after surgery.

**Table 1.** Demographic information on the patients

Gender	No.	Age (yr)	Age ≤50 yr	Age >50 yr
Female	20	37 (12.28)	17	3
Male	32	38.87 (14.7)	24	8
All	52	38.44 (13.7)	41	11

Values are presented as mean (standard deviation).

**Table 2.** Preoperative and postoperative incontinence in the patients

	Before surgery	First year after surgery				Second year after surgery		Third year after surgery
		3 mo	6 mo	9 mo	12 mo	6 mo	12 mo	6 mo
Exclusive gas incontinence	11	8	4	4	4	3	2	1
Solid incontinence	7	4	4	3	3	2	2	2
Recurrence		2	3	4	4	5	6	6

The discharge date was determined based on the patient's medical condition and complications. On discharge, patients were educated about dietary fiber and adequate fluids. All patients were followed up for at least 30 months postoperatively, trimonthly in the first year and then every 6 months. During the follow-up period, data were collected in the presence of a colorectal surgeon. All patients were questioned about improvements of symptoms or any complaints and were examined. A recurrence was defined as a full-thickness protrusion of the rectal wall discovered upon examination.

## RESULTS

Our study included 52 patients (31 males and 21 females; male: female ratio, 1.47:1) (Table 1). Two of them had a family history of full-thickness rectal prolapse in their first-degree relatives. The mean hospital stay was 2.5 days. Twenty-one patients (40.3%) had a history of past anorectal surgeries, including surgical repair of a rectal prolapse (n = 6, 4 abdominal procedures and 2 Delorme's procedures), a hemorrhoid (n = 8), a perianal abscess or fistula (n = 3), a pilonidal sinus (n = 2), an anal fissure (n = 1) or a rectovaginal fistula (n = 1). On the preoperative pelvic examination, 23 patients (44%) had a large prolapse (diameter, >5 cm), and 29 (56%) had a small prolapse (diameter, <5 cm).

No perioperative deaths and no intraoperative complications were noted. Minor postoperative complications occurred in 8 patients (15.4%); 4 patients (7.7%) had urinary retention requiring short-term catheterization, and 4 patients (7.7%) had minor surgical site bleeding (one after 7 days). All eight patients with minor postoperative complications were treated conservatively. No dehiscence, hematoma, cellulites or strictures were noted.

The types and prevalences of symptoms at the times of the follow-up visits are summarized in Tables 2 and 3. Eleven of the 52 patients (21%) had complained of exclusive gas incontinence preoperatively, and 7 of the 52 (13.4%) had had solid incontinence and soiling (mucus discharge). Solid incontinence was always associated with gas incontinence. On the first follow-up visit after surgery, 12 of the patients exclusively had gas incontinence (2 new incidences after surgery); however, the prevalence decreased to 7, 4 and 3 persons by the ends of the first, second and last follow-up visits, respectively. No new incidents of gas incontinence were noted at the last follow-up visit. Fecal incontinence was still present in four patients on the first follow-up visit after surgery (three with a history of incontinence before surgery), two of which were

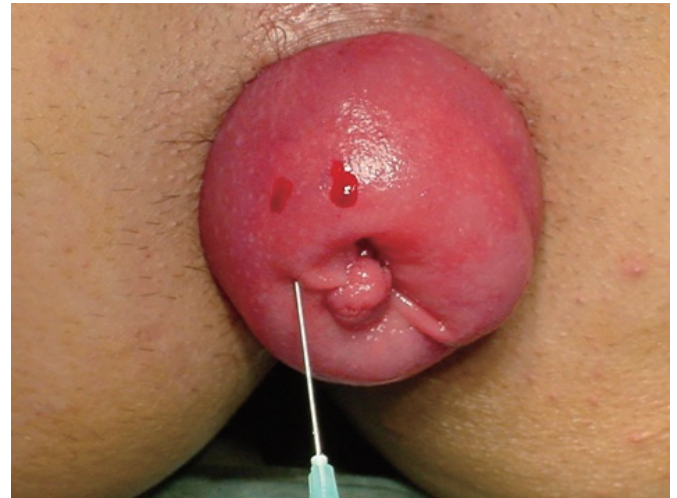found to be continent on the last follow-up visit. Incontinence was resolved in 92% of the patients in the younger group and was improved in 60% of the patients in the older group (Fig. 1). The preoperative constipation and cure rates are shown in Table 3. Two of the 52 patients had had sexual complaints before surgery: a 27-year-old man with a history of impotence and dry ejaculation after an abdominal repair of a rectal prolapse and a 62-year-old man with 2 years of impotence and decreased libido and with a 4-year history of a rectal prolapse.

In 3 of the 6 patients (50%) with recurrence, Delorme's procedure as a secondary procedure after the primary procedure (2 abdominal procedures and 1 previous Delorme's procedure) had failed. In the other 3, 1 of whom had had a past history of anal fissure repair, Delorme's procedure was a primary procedure. Four of the 6 patients with recurrence underwent further surgery (1 abdominal procedure, 1 Delorme's procedure, 2 Altemeire procedures); and 2 of the 6 did not desire additional treatment because of the annoyance (Kaplan-Meier curve).

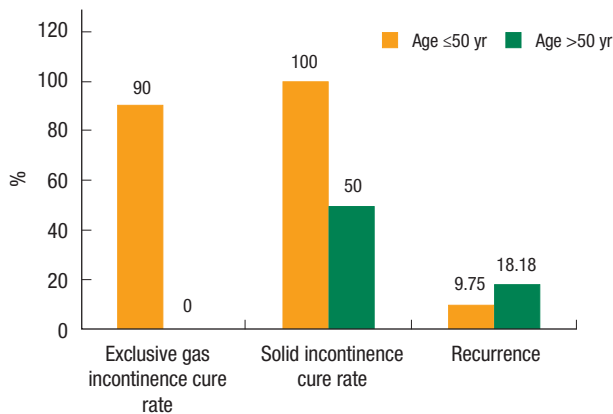
## DISCUSSION

Our study prospectively evaluated the anatomical and the functional outcomes (and showed the efficacy) of Delorme's procedure in patients with a full-thickness rectal prolapse. Figs. 2 to 6 depicts the procedure in detail. To our knowledge, only a few studies have been published on the efficacy of Delorme's procedure in the repair of a rectal prolapse in young patients [8, 9]. Surgical tech-

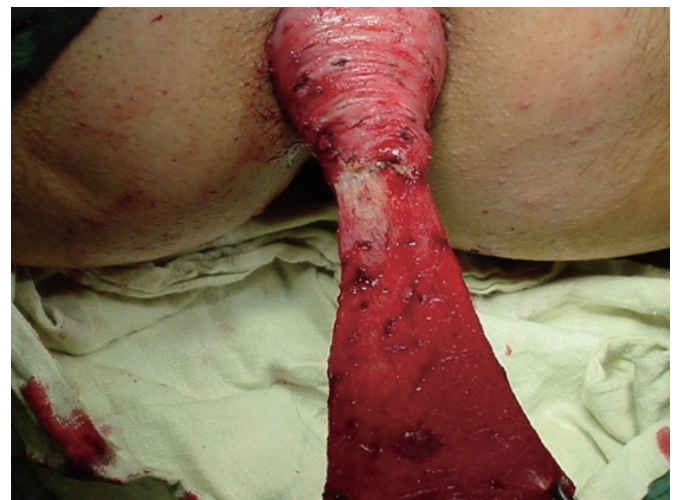niques used to repair rectal prolapse are generally categorized into perineal or abdominal approaches. Abdominal procedures mainly involve fixation of the rectum to the sacrum with or without resection of the rectum or the sigmoid colon. The method used for rectopexy may vary in different procedures. Constipation is a



**Fig. 2.** Injection of epinephrine solution (1:100,000) into the submucosa in patients with a full-thickness rectal prolapsed.



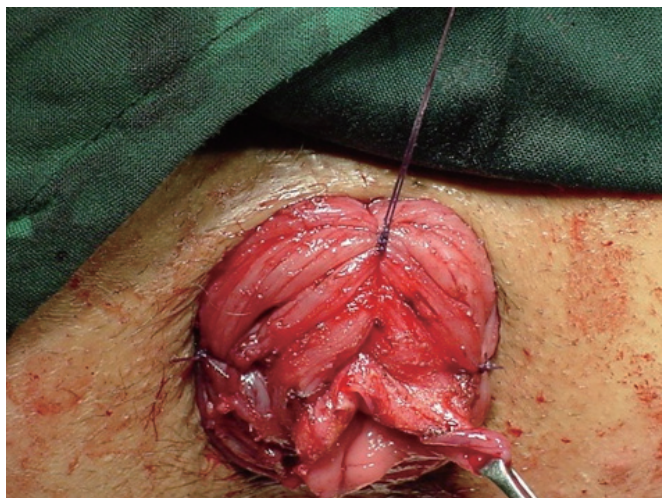**Fig. 1.** Incontinence cure rate in two different age groups.



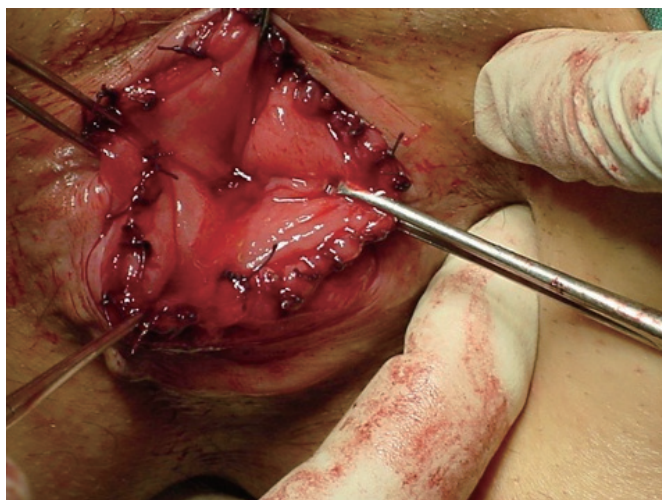
**Fig. 3.** Mucosal layer dissected from the muscular layer.

**Table 3.** Preoperative and postoperative incontinence among two age groups

Complaint	Age ≤50 yr			Age >50 yr			Total		
	Before delorme	Last visit	Cure rate (%)	Before delorme	Last visit	Cure rate (%)	Before delorme	Last visit	Cure rate (%)
Exclusive gas incontinence	10	1	90.0	1	2	0	11	3	72.7
Solid incontinence	3	0	100.0	4	2	50.0	7	2	71.4
Constipation	6	3	50.0	18	4	77.8	23	7	69.6
Visible prolapse	41	4	9.8	11	2	18.2	52	6	11.5

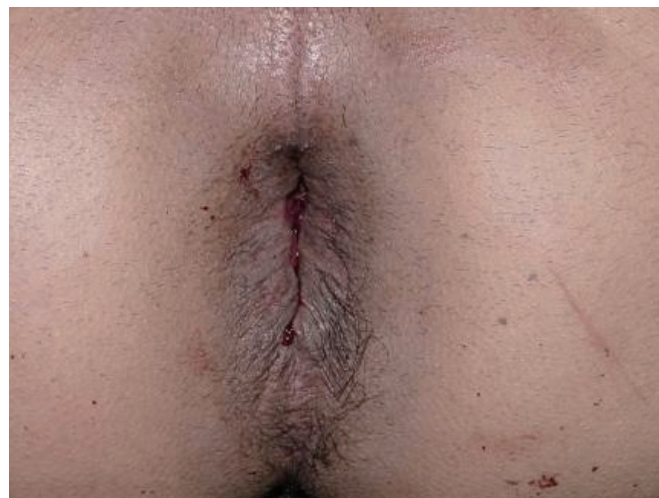

**Fig. 4.** Insertion of plicating sutures in the muscular wall of the rectum after dissection of the mucosa from the muscularis layer.



**Fig. 5.** Suturing the cut ends of the mucosa together.

known complication of abdominal rectopexy; however, a concomitant sigmoid resection may decrease the constipation rate [10, 11]. Bruch et al. [12] also suggested that preservation of the “lateral ligaments” might improve the postoperative constipation. In addition to the general hazards of laparotomies, these procedures involve the risk of pelvic nerve damage, which may cause sexual dysfunction in men, and adhesion formation, which may affect fertility in women. In one study, retrograde ejaculation and impotence were seen in 17.2% of the patients and were major causes of dissatisfaction after posterior rectopexy [3]. Perineal procedures have been suggested as initial options in certain groups of patients: young men in whom pelvic dissection and associated risk of injury to the pelvic nerves may hazard sexual dysfunction [13, 14], young nulliparous women in whom potential injury to the ovaries



**Fig. 6.** Outcome following the surgery.

**Table 4.** Delorme’s procedures for rectal prolapse

Author	Year	No.	Age (yr)	Recurrence (%)	Incontinence improved	Follow-up period (mo)
Monson et al. [20]	1986	27	74	7		35
Abulafi et al. [21]	1990	22	75	4.5		29
Lechoux et al. [9]	1995	41		5	45	
		44		22.5		
Senapati et al. [5]	1994	32	70	12.5		24
Oliver et al. [22]	1994	41	82	22	58	47
Kling et al. [7]	1996	6	78	16.7	67	11
Pescatori et al. [6]	1998	33	59	21		39
Tsunoda et al. [14]	2003	31	70	13	63	39
Watkins et al. [18]	2003	52	68	10	83	61
Marchal et al. [17]	2005	60	67	23	42	29
Lieberth et al. [8]	2009	76	74	14.5	85	43
		13	36	8		57

and the fallopian tubes should be avoided [15, 16], and frail, debilitated patients who are not suitable for a transabdominal approach.

Traditionally, the recurrence rate has been the most important issue in determining the procedure, but recently, functional outcome, operational morbidities and overall costs have been considered. So far, abdominal procedures have been thought to have lower recurrence rates [6, 10, 17]. The various available abdominal procedures have recurrence rates between 0% to 11.9% (Table 3). The recurrence rates in Delorme’s procedure and the Altemeire procedure are between 0% to 16% and 4.5% to 23%, respectively (Tables 4–6). The wide variability of reported recurrence rates may be due to different follow-up periods and patient selection. Prior studies reporting high recurrence rates for Delorme’s proce-

**Table 5.** Altemier's procedures for rectal prolapse

Author	Year	No.	Age (yr)	Recurrence (%)	Follow-up period (mo)
Johansen et al. [23]	1993	20		0	26
Agachan et al. [24]	1997	32	75	12.5	27
Kim et al. [25]	1999	183	64	16	64
Kimmins et al. [26]	2001	63	79	6.4	20

cedure made its less popular and caused it to be reserved for older, medically-unfit patients [18]. Thus, many studies comparing the results of abdominal and perineal procedures suffer from selection bias. If recurrence rates are statistically corrected for age and medical condition, the differences may not be significant.

Recent studies on Delorme's procedure have reported low recurrence in young patients [8, 9]. The recurrence rate of 9.75% in our young group is comparable with those of popular transabdominal procedures. With success rates comparable to abdominal procedures, it may be reasonable to use Delorme's procedure as the first choice in the treatment of a full-thickness rectal prolapse in all patients. However, the improvement rates varied dramatically between our groups. The functional outcomes and the complication rate in our young group were more favorable than they were in our older group, with the patients in our older group showing results similar to those in previously published reports. Delorme's procedure is a fast and easy procedure that can be carried out under any type of anesthesia (even local). Lower operative risk, lack of abdominal-surgery complications and quicker recovery make it a safe choice. There is rarely need to wait for ileus resolution, and the time interval before stool passage is often much shorter than it is in abdominal procedures [19]. The shorter hospital stay and the earlier return to work result in a lower cost. With a lower, but acceptable, incontinence improvement, reported to range from 45% to 85%, and a lower postoperative constipation rate, Delorme's procedure has an encouraging functional outcome and is even used for symptomatic relief in constipated patients. Despite the efficacy of Delorme's procedure in treating a primary prolapse, the success results in secondary cases are disappointing. Some investigators have reported high recurrence rates of 47–50% for repeated Delorme's procedures [15, 17]. Surprisingly, even in our young population, the recurrence rate for the secondary procedure was 50%. Consequently, an abdominal repair is suggested for further surgical treatment in recurrent cases, especially in medically-fit patients.

In conclusion, the most appropriate surgical procedure in the treatment of complete rectal prolapse is a matter of controversy. The surgeon should balance the related hazards and advantages in selecting the procedure. Our results indicate the efficacy of Delorme's procedure and its significantly better functional outcome and recurrence rate among young patients. With its minor complications, acceptable recurrence rate and good functional results, we believe that Delorme's procedure should be considered as the first

**Table 6.** Transabdominal resection procedures

Author	Year	No.	Age (yr)	Recurrence (%)	Follow-up period (mo)
Huber et al. [27]	1995	39	61	0	54
Cirocco and Brown [28]	1993	41	56	7	72
Madoff et al. [29]	1992	6		6	65
Stevenson et al. [30]	1998	30		0	18
Bruch et al. [12]	1999	72	62	0	30
Kellokumpu [31]	2000	34		7	24
Marceau et al. [32]	2005	28		7.14	25
Pescatori and Zbar [33]	2009	42		11.9	61

choice for all patients, particularly young adults, presenting with a complete rectal prolapse. Transabdominal techniques may be considered in recurrent cases because of the high recurrence rate for secondary Delorme's procedures.

## CONFLICT OF INTEREST

No potential conflict of interest relevant to this article was reported.

## REFERENCES

- Uhlir BE, Sullivan ES. The modified Delorme operation: its place in surgical treatment for massive rectal prolapse. *Dis Colon Rectum* 1979;22:513-21.
- Kuijpers HC. Treatment of complete rectal prolapse: to narrow, to wrap, to suspend, to fix, to encircle, to plicate or to resect? *World J Surg* 1992;16:826-30.
- Yakut M, Kaymakcioglu N, Simsek A, Tan A, Sen D. Surgical treatment of rectal prolapse. A retrospective analysis of 94 cases. *Int Surg* 1998;83:53-5.
- Classic articles in colonic and rectal surgery. Edmond Delorme 1847-1929. On the treatment of total prolapse of the rectum by excision of the rectal mucous membranes or recto-colic. *Dis Colon Rectum* 1985;28:544-53.
- Senapati A, Nicholls RJ, Thomson JP, Phillips RK. Results of Delorme's procedure for rectal prolapse. *Dis Colon Rectum* 1994;37:456-60.
- Pescatori M, Interisano A, Stolfi VM, Zoffoli M. Delorme's operation and sphincteroplasty for rectal prolapse and fecal incontinence. *Int J Colorectal Dis* 1998;13:223-7.
- Kling KM, Rongione AJ, Evans B, McFadden DW. The Delorme procedure: a useful operation for complicated rectal prolapse in the elderly. *Am Surg* 1996;62:857-60.
- Lieberth M, Kondylis LA, Reilly JC, Kondylis PD. The Delorme repair for full-thickness rectal prolapse: a retrospective review. *Am J Surg* 2009;197:418-23.
- Lechaux JP, Lechaux D, Perez M. Results of Delorme's procedure

- for rectal prolapse. Advantages of a modified technique. *Dis Colon Rectum* 1995;38:301-7.
10. Madiba TE, Baig MK, Wexner SD. Surgical management of rectal prolapse. *Arch Surg* 2005;140:63-73.
  11. Benoist S, Taffinder N, Gould S, Chang A, Darzi A. Functional results two years after laparoscopic rectopexy. *Am J Surg* 2001;182:168-73.
  12. Bruch HP, Herold A, Schiedeck T, Schwandner O. Laparoscopic surgery for rectal prolapse and outlet obstruction. *Dis Colon Rectum* 1999;42:1189-94.
  13. Berman IR. Different strokes for different folks in repair of rectal prolapse. *Dis Colon Rectum* 1995;38:330.
  14. Tsunoda A, Yasuda N, Yokoyama N, Kamiyama G, Kusano M. Delorme's procedure for rectal prolapse: clinical and physiological analysis. *Dis Colon Rectum* 2003;46:1260-5.
  15. Watts AM, Thompson MR. Evaluation of Delorme's procedure as a treatment for full-thickness rectal prolapse. *Br J Surg* 2000;87:218-22.
  16. Hetzer FH, Roushan AH, Wolf K, Beutner U, Borovicka J, Lange J, et al. Functional outcome after perineal stapled prolapse resection for external rectal prolapse. *BMC Surg* 2010;10:9.
  17. Marchal F, Bresler L, Ayav A, Zarnegar R, Brunaud L, Duchamp C, et al. Long-term results of Delorme's procedure and Orr-Loygue rectopexy to treat complete rectal prolapse. *Dis Colon Rectum* 2005;48:1785-9.
  18. Watkins BP, Landercasper J, Belzer GE, Rechner P, Knudson R, Bintz M, et al. Long-term follow-up of the modified Delorme procedure for rectal prolapse. *Arch Surg* 2003;138:498-502.
  19. Hoel AT, Skarstein A, Ovrebo KK. Prolapse of the rectum, long-term results of surgical treatment. *Int J Colorectal Dis* 2009;24:201-7.
  20. Monson JR, Jones NA, Vowden P, Brennan TG. Delorme's operation: the first choice in complete rectal prolapse? *Ann R Coll Surg Engl* 1986;68:143-6.
  21. Abulafi AM, Sherman IW, Fiddian RV, Rothwell-Jackson RL. Delorme's operation for rectal prolapse. *Ann R Coll Surg Engl* 1990;72:382-5.
  22. Oliver GC, Vachon D, Eisenstat TE, Rubin RJ, Salvati EP. Delorme's procedure for complete rectal prolapse in severely debilitated patients. An analysis of 41 cases. *Dis Colon Rectum* 1994;37:461-7.
  23. Johansen OB, Wexner SD, Daniel N, Noguerras JJ, Jagelman DG. Perineal rectosigmoidectomy in the elderly. *Dis Colon Rectum* 1993;36:767-72.
  24. Agachan F, Pfeifer J, Joo JS, Noguerras JJ, Weiss EG, Wexner SD. Results of perineal procedures for the treatment of rectal prolapse. *Am Surg* 1997;63:9-12.
  25. Kim DS, Tsang CB, Wong WD, Lowry AC, Goldberg SM, Madoff RD. Complete rectal prolapse: evolution of management and results. *Dis Colon Rectum* 1999;42:460-6.
  26. Kimmins MH, Evetts BK, Isler J, Billingham R. The Altemeier repair: outpatient treatment of rectal prolapse. *Dis Colon Rectum* 2001;44:565-70.
  27. Huber FT, Stein H, Siewert JR. Functional results after treatment of rectal prolapse with rectopexy and sigmoid resection. *World J Surg* 1995;19:138-43.
  28. Cirocco WC, Brown AC. Anterior resection for the treatment of rectal prolapse: a 20-year experience. *Am Surg* 1993;59:265-9.
  29. Madoff RD, Williams JG, Wong WD, Rothenberger DA, Goldberg SM. Long-term functional results of colon resection and rectopexy for overt rectal prolapse. *Am J Gastroenterol* 1992;87:101-4.
  30. Stevenson AR, Stitz RW, Lumley JW. Laparoscopic-assisted resection-rectopexy for rectal prolapse: early and medium follow-up. *Dis Colon Rectum* 1998;41:46-54.
  31. Kellokumpu I. Surgical treatment of rectal prolapse. *Duodecim* 2009;125:207-14.
  32. Marceau C, Parc Y, Debroux E, Tiret E, Parc R. Complete rectal prolapse in young patients: psychiatric disease a risk factor of poor outcome. *Colorectal Dis* 2005;7:360-5.
  33. Pescatori M, Zbar AP. Tailored surgery for internal and external rectal prolapse: functional results of 268 patients operated upon by a single surgeon over a 21-year period. *Colorectal Dis* 2009;11:410-9.