

# Laparoscopic Management of Unruptured Interstitial Pregnancy Using Purse-string Suture Technique

Mikaela Erlinda Germar Martinez\*, Regina Paz Airoso Tan-Espiritu

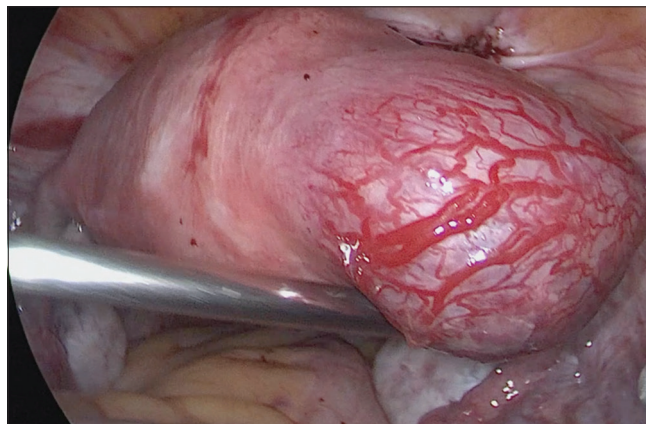
Department of Obstetrics and Gynecology, Philippine General Hospital, University of the Philippines, Manila, Philippines

A 37-year-old woman, gravida 2 para 1, was admitted for abdominal pain at 11 weeks of gestation. Transvaginal ultrasound revealed a gestational sac located at the right cornual area and an empty endometrium. Human chorionic gonadotropin was 11,282 mIU/ml. The diagnosis was right interstitial pregnancy. The surgical plan was laparoscopic cornual resection.

Intraoperatively, a bulging vascular mass was found at the right cornual area, lateral to the insertion of the right round ligament, measuring 5 cm × 4 cm × 4 cm [Figure 1]. A 2-0 barbed suture was then passed deep into the myometrium around the base of the interstitial mass in a purse-string manner. The suture was pulled to tighten around the lesion and was not cut to allow the application of more tension as required to achieve hemostasis [Figure 2]. Cornual resection began with a single linear incision cornuotomy using laparoscopic scissors [Figure 3]. After removal of the products of conception, the myometrium was then excised at the base in an elliptical fashion right above the hemostatic suture using advanced bipolar. The uterine defect was repaired by a single layer of continuous full-thickness sutures using a 2-0 barbed suture [Figure 4]. Right salpingectomy was performed. The products of conception, overlying myometrium and fallopian tube were placed inside an improvised specimen bag and extracted through the 10-mm umbilical port. No injection of vasopressin was given at any time of the operation. Intra-operative blood loss was 82 ml; operative time was 49 min. The patient was discharged improved, with a marked decrease in human chorionic gonadotropin (BHCG) levels.

Interstitial pregnancy is an ectopic pregnancy wherein the gestational sac is implanted at the interstitial portion of the tubal segment that traverses the muscular wall of the uterus.<sup>[1-4]</sup> These occur in approximately 2% of ectopic pregnancies but are associated with a high rate of morbidity due to the proximity of the gestational sac to the intramyometrial arcuate vasculature. Interstitial pregnancies rupture at an advanced gestation due to the distensibility of the surrounding myometrium, often leading to catastrophic hemorrhage.<sup>[4]</sup> Hence, timely diagnosis and management are vital to prevent maternal morbidity or mortality and to maintain fertility.<sup>[1]</sup>

Conventionally, conservative surgical management of interstitial pregnancy would entail cornual wedge resection



**Figure 1:** The ectopic pregnancy was seen as a bulging mass at the right cornual area. The overlying myometrium was vascular and thinned out

**Address for correspondence:** Dr. Mikaela Erlinda Germar Martinez, Department of Obstetrics and Gynecology, Philippine General Hospital, Taft Avenue, Malate, Manila, Philippines. E-mail: mgmartinez2@up.edu.ph

#### Article History:

Submitted: 30 June 2020

Revised: 13 July 2020

Accepted: 08 October 2020

Published: 30 January 2021

#### Access this article online

Quick Response Code:



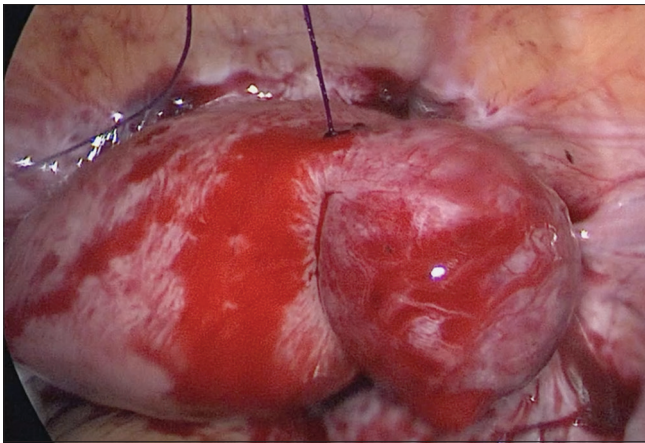
Website:  
www.e-gmit.com

DOI:  
10.4103/GMIT.GMIT\_94\_20

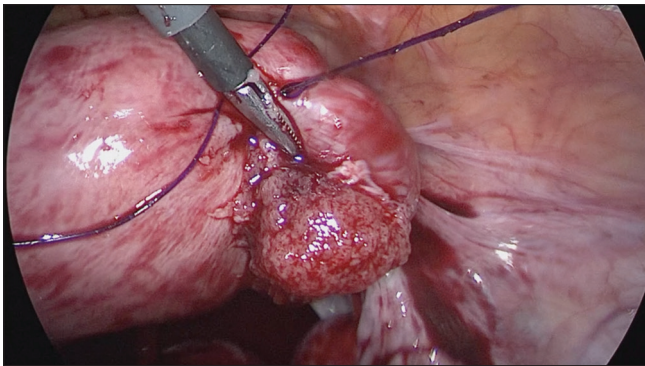
This is an open access journal, and articles are distributed under the terms of the Creative Commons Attribution-NonCommercial-ShareAlike 4.0 License, which allows others to remix, tweak, and build upon the work non-commercially, as long as appropriate credit is given and the new creations are licensed under the identical terms.

**For reprints contact:** WKHLRPMedknow\_reprints@wolterskluwer.com

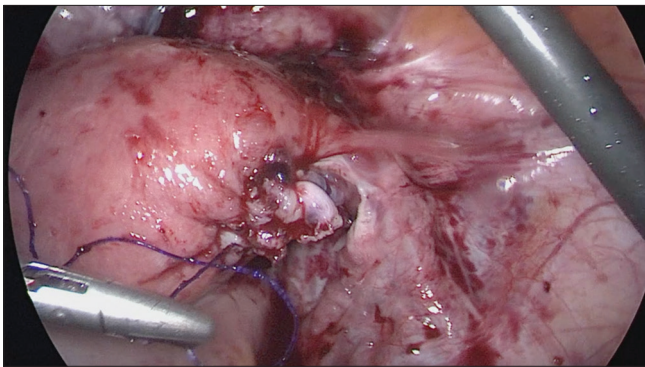
**How to cite this article:** Martinez ME, Tan-Espiritu RP. Laparoscopic management of unruptured interstitial pregnancy using purse-string suture technique. *Gynecol Minim Invasive Ther* 2021;10:65-6.



**Figure 2:** A purse-string suture was applied around the base of the interstitial mass and pulled to tighten around the lesion with enough tension to achieve adequate hemostasis



**Figure 3:** Cornual resection was done by first performing linear incision over the interstitial mass using laparoscopic scissors then evacuating the products of conception. The surrounding myometrium was excised



**Figure 4:** The uterine defect was repaired using continuous full-thickness sutures using a 2-0 barbed suture

through laparotomy. However, laparoscopy can be done as a less invasive and less traumatic surgical option.<sup>[4]</sup> Among the emerging laparoscopic approaches is the purse-string technique, where a hemostatic suture is passed at the base of the interstitial mass and drawn tight to close the lesion off before resection. The need for vasopressin is obviated, thus preventing its potentially harmful effects.

Removal of the ectopic mass can be performed either by cornual resection or cornuotomy, both of which have comparable complication rates and incidence of persistent ectopic pregnancy.<sup>[2,4]</sup> Cornual resection is preferred for cases where implantation is deep in the myometrium or when the size of the lesion is relatively large (>4 cm).<sup>[1,2]</sup> For this case, the surgeons removed the ectopic gestation first by performing a linear cornuostomy, decompressing the mass. After which, they proceeded with excision of the surrounding suspicious myometrium, based on its color and texture.<sup>[2]</sup> This approach avoids creating a deep circumferential incision that can cause bleeding and obscure the surgical field. In addition, this prevents the excessive removal of myometrium, which may increase the risk for uterine rupture due to the loss of tissue and extensive uterine scarring.<sup>[4]</sup> A continuous full-thickness repair decreases the risk of uterine rupture in subsequent pregnancies.<sup>[1]</sup>

### Ethical statement

University of the Philippines Manila Research Ethics Board exempted ethical review (UPMREB No. 2020-389-EX) on June 19, 2020. UPM REB has waived informed consent.

### Financial support and sponsorship

Nil.

### Conflicts of interest

There are no conflicts of interest.

### REFERENCES

1. Cucinella G, Rotolo S, Calagna G, Granese R, Agrusa A, Perino A. Laparoscopic management of interstitial pregnancy: The “purse-string” technique. *Acta Obstet Gynecol Scand* 2012;91:996-9.
2. Lee MH, Im SY, Kim MK, Shin SY, Park WI. Comparison of laparoscopic cornual resection and cornuotomy for interstitial pregnancy. *J Minim Invasive Gynecol* 2017;24:397-401.
3. Lei R, Liang J, Ling X, Xu J, Liang S, Zhou H, *et al*. Use of laparoscopic slip knot with purse-string suture in surgical management of unruptured heterotopic intersitial pregnancies. *Med Sci Monit* 2020;26:e921185.
4. Brincat M, Bryant-Smith A, Holland TK. The diagnosis and management of interstitial ectopic pregnancy: A review. *Gynecol Surg* 2019;16:2.