

# Choroidal thickness profile in inherited retinal diseases in Indian subjects

Jay Chhablani, Ashraya Nayaka, Padmaja Kumari Rani, Subhadra Jalali

**Purpose:** To evaluate changes in choroidal thickness (CT) in inherited retinal diseases and its relationship with age, spherical equivalent, visual acuity, and macular thickness. **Methods:** Retrospective analysis of 51 eyes with features of retinal dystrophy of 26 subjects, who underwent enhanced depth imaging using spectral domain (SD) optical coherence tomography (OCT), were included. The CT measurements were made at the fovea and at 5 points with an interval of 500 microns in both directions, nasal and temporal from the fovea and were compared with age-matched healthy subjects. Step-wise regression was used to find the relationship between age, spherical equivalent, best-corrected visual acuity (BCVA), central macular thickness (CMT), and subfoveal CT. **Results:** Disease distribution was as follows: Stargardt's disease 18 eyes (9 subjects); Best disease 5 eyes (3 subjects); cone-rod dystrophy 26 eyes (13 subjects); and Bietti's crystalline dystrophy 2 eyes (1 subject). Mean subfoveal CT was  $266.33 \pm 76$  microns. On regression analysis, no significant correlation was found between subfoveal CT and any other variable such as age ( $P = 0.9$ ), gender ( $P = 0.5$ ), CMT ( $P = 0.1$ ), spherical equivalent ( $P = 0.3$ ) and BCVA ( $P = 0.6$ ). While comparing with age-matched healthy subjects, no significant statistical difference was noted ( $P < 0.05$ ) among all age groups. **Conclusion:** Our study reports quantitative changes in CT in various common inherited retinal diseases seen in Indian populations. To validate changes in choroid, a longitudinal study with larger sample size is warranted.

**Key words:** Choroidal imaging, choroidal thickness, retinal dystrophies

Inherited retinal diseases are important causes of vision loss, especially, in younger age group.<sup>[1]</sup> These can be classified depending upon the structure primarily involved such as choroid (choroideremia), retinal pigment epithelium (RPE, Best's disease), photoreceptor outer segments (Stargardt's disease, cone-rod dystrophies, Bietti's crystalline dystrophy), and bipolar and Mueller cells (x-linked retinoschisis). Inherited retinal diseases could be localized to the central retina (Best's disease and Stargardt's disease) or generalized (cone-rod dystrophies and Bietti's crystalline dystrophy). Most of the inherited retinal diseases eventually lead to damage to outer retinal structures and choriocapillaris. Relative choroidal ischemia is increased in severely visually impaired eyes with retinitis pigmentosa.<sup>[2]</sup> Falsini *et al.*, reported a relationship between the choroidal blood flow and reduced focal electroretinography responses.<sup>[3]</sup> Compromised choroidal circulation leads to choriocapillaris atrophy and eventually to damage to photoreceptors in other inherited retinal diseases as well.<sup>[4-6]</sup> Further assessment of the choroidal morphology may improve the clinical understanding and management strategies of inherited retinal diseases.

With the advent of enhanced depth imaging (EDI), quantitative analysis of the choroid is possible. Changes in choroidal thickness (CT) are noted in various ocular and systemic diseases.<sup>[7-9]</sup> However, there is very limited literature available describing change in CT in inherited retinal

diseases,<sup>[10]</sup> especially, none from the Indian population. There are no studies comparing CT changes in comparison to age-matched healthy controls. In the present study, we report changes in CT in common inherited retinal diseases in Indian population, in comparison to age-matched healthy Indian subjects and its relationship with age, spherical equivalent, visual acuity, and macular thickness.

## Methods

This retrospective study was performed at the L. V. Prasad Eye Institute in India from September 2012 to January 2013. Prior approval from the Institutional Review Board of the Institute was obtained, and informed consent was obtained from each study subject for the diagnostic procedures. This study was conducted in accordance with the tenets of the Declaration of Helsinki.

Fifty-one eyes (26 patients) with a diagnosis of some form of macular dystrophy other than retinitis pigmentosa were included in this study. All participants underwent a comprehensive ophthalmic examination including best-corrected visual acuity (BCVA) testing using Early Treatment Diabetic Retinopathy Study charts, slit-lamp biomicroscopy, intraocular pressure measurement using Goldmann applanation tonometer and dilated fundoscopic examination. All patients underwent electroretinography and electrooculogram for diagnosis of dystrophy as per physician's discretion.

Exclusion criteria included optic atrophy, visually significant cataract, high myopia or hyperopia ( $>-6$  or  $+3$  diopters of refractive error), poor image quality, any other associated retinal pathology, or history of any intraocular surgery. Control group included age-matched healthy subjects with no ocular disease and without high refractive power (more than  $-6D$  or  $+3D$ ), which included 251 subjects (467 eyes), ranging from 5 to 80 years (unpublished data).

Access this article online

Website:

[www.ijo.in](http://www.ijo.in)

DOI:

10.4103/0301-4738.159862

Quick Response Code:



Smt. Kanuri Santhamma Retina Vitreous Centre, L. V. Prasad Eye Institute, Hyderabad, Telangana, India

**Correspondence to:** Dr. Jay Chhablani, Smt. Kanuri Santhamma Retina Vitreous Centre, L. V. Prasad Eye Institute, Kallam Anji Reddy Campus, L. V. Prasad Marg, Banjara Hills, Hyderabad - 500 034, Telangana, India. E-mail: [jay.chhablani@gmail.com](mailto:jay.chhablani@gmail.com)

Manuscript received: 02.11.14; Revision accepted: 20.03.15

### Choroidal imaging

The SD-OCT scans were obtained using Cirrus high-definition (HD)-OCT (Carl Zeiss Meditec, Inc., Dublin, CA, USA) after dilatation of the pupil with 1% tropicamide and 10% phenylephrine eye drops. The scan used for imaging in this study is HD 1-line raster with EDI which is a 6-mm line consisting of 4096 A-scans, an imaging speed of 27,000 A-scans per second, an axial resolution of 5 microns, and a transverse resolution of 15 microns in tissue and averages 20 frames (B-scans). EDI, which automatically sets the choroid closer to the zero-delay line and thus theoretically provides better visualization of the choroidescleral interface, was used for all scans. Scans with a signal strength of more than or equal to 6 were used for analysis.

### Image analysis

#### Choroidal thickness measurement

Using the Cirrus linear measurement tool, a single observer measured CT perpendicularly from the outer portion of the hyperreflective line corresponding to the RPE, to the inner surface of the sclera at 500 microns intervals temporal and nasal from the fovea, up to 3000 microns as published in the literature.<sup>[11]</sup> Intraclass correlation coefficient for intra-observer reproducibility was 0.97.

We also evaluated choroidal contour to note if any area of focal thinning was noted, especially in the areas of outer retinal thinning.

### Statistical analysis

Descriptive statistics included mean and standard deviation for continuous variables. As both eyes of 25 subjects were included for analysis, the correlation between the two eyes of

the same subject was adjusted using generalized estimating equations (GEE) during the calculation of summary descriptive parameters. Multivariate models adjusted using GEE methods were fit to assess the effects of age, gender, and macular thickness on the CT measurements. Statistical analyses were performed using MedCalc for Windows, version 12.5 (MedCalc Software, Ostend, Belgium). The alpha level (type I error) was set at 0.05. All the graphs were performed made using GraphPad Prism (GraphPad Software, version 6.00 for Windows, La Jolla California, USA, www.graphpad.com).

### Results

Present study included 51 eyes of 26 subjects with inherited retinal disease other than RP. Mean age of the study group was  $28.49 \pm 16.7$  years, with 20 males and 6 females. Mean BCVA was  $0.59 \pm 0.33$  logMAR (Snellen equivalent 20/70), ranging from 0 to 1.1 (Snellen equivalent 20/20–20/250). Mean spherical equivalent was  $1.2D \pm 0.75D$ . All patients were phakic with clear lens. Mean subfoveal CT and central macular thickness (CMT) among study subjects was  $266.33 \pm 76$  microns and  $122.39 \pm 77$  microns respectively. CT at different points from fovea is shown in Table 1 and Fig. 1.

Age-matched control groups included 466 eyes of 233 eyes subjects with mean age of  $25.9 \pm 18.11$  years (range: 5–80 years). Mean spherical equivalent in control group was  $-0.22D \pm 0.9D$ . All patients were phakic. Mean subfoveal CT and CMT was  $297.66 \pm 48$  microns and  $204.4 \pm 32.2$  microns respectively. On regression analysis, no significant correlation was found between subfoveal CT and any other variable such as age ( $P = 0.9$ ), gender ( $P = 0.5$ ), CMT ( $P = 0.1$ ), spherical equivalent ( $P = 0.3$ ), and BCVA ( $P = 0.6$ ). While comparing with age-matched healthy subjects decade-wise, no significant statistical difference was noted ( $P > 0.05$ ) among all age groups [Table 2].

We did not find any areas of focal choroidal thinning at the areas of outer retinal damage irrespective of the type of dystrophy.

### Discussion

Our study reports CT distribution at different locations in hereditary retinal diseases in Indian population. Age, gender, spherical equivalent has been shown to be related to CT in normal population;<sup>[12]</sup> however, we did not find any significant correlation between subfoveal CT and any other variables among eyes with inherited retinal diseases. There was no significant difference between study group and age-matched healthy subjects, among all age groups.

There is only one study by Yeoh *et al.*,<sup>[10]</sup> which reports changes in choroidal structures in eyes with inherited retinal

**Table 1: CT profile at different points from fovea in study subjects**

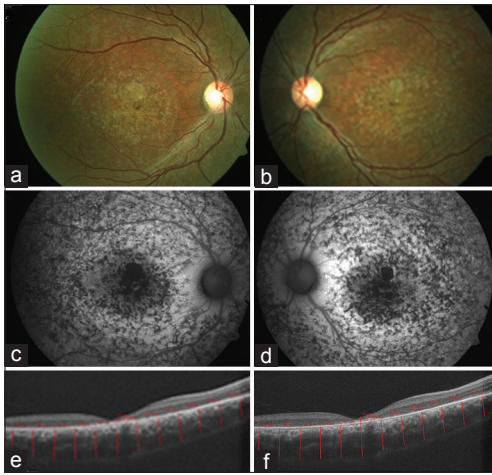
Locations	CT (microns)
N2500 microns	201.05±63.00
N2000 microns	222.15±67.17
N1500 microns	237.56±69.10
N1000 microns	243.88±75.46
N500 microns	253.01±76.29
Subfoveal	266.33±76.17
T500 microns	258.72±73.44
T1000 microns	251.78±73.03
T1500 microns	243.01±76.28
T2000 microns	233.01±76.07
T2500 microns	219.21±73.55

N: Nasal, T: Temporal, CT: Choroidal thickness

**Table 2: Clinical and OCT characteristics of study subjects**

Disease	Number of eyes (subjects)	Mean age±SD	Mean BCVA (LogMAR)	Mean CMT	Mean subfoveal CT	Mean age-matched subfoveal CT	P
Stargardt's disease	18 (9)	26.9±18.9	0.6±0.3	96.3±83.9	288.9±52.3	294.8±46.5	0.3
Cone-rod dystrophy	26 (13)	25.46±14.1	0.5±0.3	138.4±68.9	249±83.9	294.8±46.5	0.001
Best disease	5 (3)	42.2±15.1	0.6±0.3	86±36.4	275.2±111.8	289.5±40.0	0.29
Bietti's crystalline dystrophy	2 (1)	48	0.4±0.2	239.5±78.4	266.5±12.0	289.5±40.0	0.2

SD: Standard deviation, BCVA: Best-corrected visual acuity, CT: Choroidal thickness, CNT: Central macular thickness, OCT: Optical coherence tomography



**Figure 1:** Composite image showing color photograph (a and b), and autofluorescence (c and d) and spectral domain optical coherence tomography (e and f) with choroidal thickness measurements in a case of Stargardt's disease

diseases. They analyzed CT as well as focal thinning using EDI scans. However, the results were not compared with age-matched healthy controls. They reported focal areas of mild to moderate choroidal thinning on EDI OCT in 5 patients, which corresponded with the clinically visible areas of discrete outer retinal, RPE and choriocapillaris atrophy. In our study, we did not notice any focal thinning, and change in contour of choroid in relation to outer retinal structure damage. As reported by Yeoh *et al.*, we also noticed a choroidal thinning in eyes with Bietti's crystalline dystrophy and Best disease.<sup>[10]</sup> Yeoh *et al.*, reported 3 of 6 eyes with Stargardt's having thinning of choroid; however, in our study, we did not notice any significant choroidal thinning in eyes with Stargardt's disease.

While the histopathological studies have demonstrated the degeneration of choriocapillaris, loss of photoreceptors, and RPE in the region of atrophy in eyes with various dystrophies,<sup>[4-6]</sup> we did not find any choroidal thinning in areas of retinal thinning, specifically outer retinal thinning in our study subjects. Due to limited resolution of presently available SD-OCT devices, measurement of choriocapillaris thickness is not possible. As there was no choroidal thinning noted in areas of outer retinal damage, further improvement in resolution or angiographic studies will be required to evaluate choriocapillaris changes.

Limitations of our study include retrospective nature; small sample size and unavailability of genetic analysis for our subjects, however, clinical diagnosis as supported by investigations when required. No statistically significant difference compared to age-matched controls could be due to small sample size; however, our study provides an outline for future studies.

## Conclusion

Our study reports quantitative changes in CT in various common inherited retinal diseases seen in Indian populations. To validate changes in choroid, a longitudinal study with larger sample size is warranted. Further understanding of individual layers of choroid may provide more insight into inherited retinal diseases, which may help to plan therapeutic interventions and follow-up.

## References

1. Bird AC. Retinal photoreceptor dystrophies LI. Edward Jackson Memorial Lecture. *Am J Ophthalmol* 1995;119:543-62.
2. Langham ME, Kramer T. Decreased choroidal blood flow associated with retinitis pigmentosa. *Eye (Lond)* 1990;4 (Pt 2):374-81.
3. Falsini B, Anselmi GM, Marangoni D, D'Esposito F, Fadda A, Di Renzo A, *et al.* Subfoveal choroidal blood flow and central retinal function in retinitis pigmentosa. *Invest Ophthalmol Vis Sci* 2011;52:1064-9.
4. Ashton N. Central areolar choroidal sclerosis; a histo-pathological study. *Br J Ophthalmol* 1953;37:140-7.
5. Ferry AP, Llovera I, Shafer DM. Central areolar choroidal dystrophy. *Arch Ophthalmol* 1972;88:39-43.
6. Voo I, Glasgow BJ, Flannery J, Udar N, Small KW. North Carolina macular dystrophy: Clinicopathologic correlation. *Am J Ophthalmol* 2001;132:933-5.
7. Chhablani J, Kozak I, Jonnadula GB, Venkata A, Narayanan R, Pappuru RR, *et al.* Choroidal thickness in macular telangiectasia type 2. *Retina* 2014;34:1819-23.
8. Regatieri CV, Branchini L, Carmody J, Fujimoto JG, Duker JS. Choroidal thickness in patients with diabetic retinopathy analyzed by spectral-domain optical coherence tomography. *Retina* 2012;32:563-8.
9. Ayton LN, Guymer RH, Luu CD. Choroidal thickness profiles in retinitis pigmentosa. *Clin Experiment Ophthalmol* 2013;41:396-403.
10. Yeoh J, Rahman W, Chen F, Hooper C, Patel P, Tufail A, *et al.* Choroidal imaging in inherited retinal disease using the technique of enhanced depth imaging optical coherence tomography. *Graefes Arch Clin Exp Ophthalmol* 2010;248:1719-28.
11. Yamashita T, Yamashita T, Shirasawa M, Arimura N, Terasaki H, Sakamoto T. Repeatability and reproducibility of subfoveal choroidal thickness in normal eyes of Japanese using different SD-OCT devices. *Invest Ophthalmol Vis Sci* 2012;53:1102-7.
12. Barteselli G, Chhablani J, El-Emam S, Wang H, Chuang J, Kozak I, *et al.* Choroidal volume variations with age, axial length, and sex in healthy subjects: A three-dimensional analysis. *Ophthalmology* 2012;119:2572-8.

**Cite this article as:** Chhablani J, Nayaka A, Rani PK, Jalali S. Choroidal thickness profile in inherited retinal diseases in Indian subjects. *Indian J Ophthalmol* 2015;63:391-3.

**Source of Support:** Nil. **Conflict of Interest:** None declared.