

Thymosin β_4 expression in colorectal polyps and adenomas

Sonia Nemolato,^I Tiziana Cabras,^{II} Angelo Restivo,^{IV} Luigi Zorcolo,^{IV} Eliana Di Felice,^I Daniela Fanni,^I Clara Gerosa,^I Irene Messina,^{II} Massimo Castagnola,^{III} Gavino Faa,^I Giuseppe Casula^{IV}

^IUniversity of Cagliari, Department of Surgery, Section of Pathology, Cagliari/Italy. ^{II}University of Cagliari, Department of Life and Environmental Sciences, Cagliari/Italy. ^{III}Catholic University, Faculty of Medicine, Institute of Biochemistry and Clinical Biochemistry, Rome/Italy. ^{IV}University of Cagliari, Department of Surgical Sciences, Colorectal Surgery, Cagliari/Italy.

OBJECTIVE: Thymosin beta 4 (T β 4) is a ubiquitous peptide that plays pivotal roles in the cytoskeletal system and in cell differentiation. Recently, a role for T β 4 has been proposed in experimental and human carcinogenesis, including gastrointestinal cancer. This study was aimed at evaluating the relationship between T β 4 immunoreactivity and the initial steps of carcinogenesis.

METHODS: In total, 60 intestinal biopsies, including 10 hyperplastic polyps, 10 sessile serrated adenomas/polyps, 15 colorectal adenomas with low-grade dysplasia, 15 adenomas with high-grade dysplasia, 15 adenocarcinomas and 10 samples of normal colon mucosa, were analyzed for T β 4 expression by immunohistochemistry.

RESULTS: Weak cytoplasmic reactivity for T β 4 was detected in the normal colon mucosa. No reactivity for T β 4 was found in hyperplastic and sessile serrated polyps/adenomas. T β 4 expression was observed in 10/15 colorectal adenocarcinomas. In adenomas with low-grade dysplasia, T β 4 immunoreactivity was mainly detected in dysplastic glands but was absent in hyperplastic glands. T β 4 immunoreactivity was characterized by spot-like perinuclear staining. In high-grade dysplastic polyps, immunostaining for T β 4 appeared diffuse throughout the entire cytoplasm of dysplastic cells. Spot-like perinuclear reactivity was detected in adenocarcinoma tumor cells.

CONCLUSIONS: Our study shows for the first time that T β 4 is expressed during different steps of colon carcinogenesis. The shift of T β 4 immunolocalization from low-grade to high-grade dysplastic glands suggests a role for T β 4 in colorectal carcinogenesis. However, the real meaning of T β 4 reactivity in dysplastic intestinal epithelium remains unknown.

KEYWORDS: Hyperplastic Polyps; Colorectal Adenomas; Thymosin β_4 .

Nemolato S, Cabras T, Restivo A, Zorcolo L, Di Felice E, Fanni D, et al. Thymosin β_4 expression in colorectal polyps and adenomas. *Clinics*. 2013;68(9):1220-1224.

Received for publication on February 25, 2013; First review completed on March 19, 2013; Accepted for publication on April 24, 2013

E-mail: sonianemolato@libero.it

Tel.: 00390706092370

INTRODUCTION

Thymosin beta 4 (T β 4), a peptide named after its first detection in the calf thymus (1), is a member of the β -thymosins, a versatile actin-binding protein family (2). T β 4 has traditionally been associated with a role as a regulator of actin polymerization in living cells (3). T β 4 is thought to be involved in many critical biological processes, including angiogenesis (4), wound healing (5), the inflammatory response (6) and cell migration (7). T β 4 may also stimulate the AKT pathway, resulting in a strong anti-apoptotic effect on human cells (7), and it has recently been documented to

play an essential role in cardioprotection after myocardial infarction (8) and in the protection of gingival fibroblasts from apoptosis induced by TNF- α (9). Recently, T β 4 activity was implicated in experimental and human carcinogenesis. This concept is mainly based on the observation that T β 4 may facilitate tumor cell motility and induce intra- and peritumoral angiogenesis (10). T β 4 has been recently documented in breast cancer and in a few cases of colorectal cancer (11). Possible pro-metastatic (12) and pro-angiogenic activity has been hypothesized for T β 4 (13), which has encouraged the development of T β 4 inhibitors as anti-cancer drugs (14). Recently, T β 4 immunoreactivity was detected by our group in the vast majority of colon carcinomas, where it showed a patchy distribution and well-differentiated areas that were significantly more reactive than less-differentiated tumor zones. Moreover, the localization of T β 4 changed during cancer progression, moving from the cell membrane to the Golgi apparatus (15).

On the basis of these data, this study was aimed at analyzing the expression of T β 4 in the initial steps of

Copyright © 2013 CLINICS – This is an Open Access article distributed under the terms of the Creative Commons Attribution Non-Commercial License (<http://creativecommons.org/licenses/by-nc/3.0/>) which permits unrestricted non-commercial use, distribution, and reproduction in any medium, provided the original work is properly cited.

No potential conflict of interest was reported.

DOI: 10.6061/clinics/2013(09)08



colorectal carcinogenesis. We analyzed Tβ4 expression by immunohistochemistry in hyperplastic polyps and colorectal adenomas with different degrees of dysplasia to shed light on the relationship between Tβ4 expression and colon cancer insurgence and progression.

■ MATERIALS AND METHODS

The study included archival paraffin-embedded colorectal biopsies obtained from 75 patients who underwent colonoscopy and biopsy. The cohort included six groups: normal colon mucosa (10 samples), hyperplastic polyps (10 samples), sessile serrated adenomas/polyps (10 samples), adenomas with low-grade dysplasia (15 samples), adenomas with high-grade dysplasia (15 samples) and adenocarcinomas (15 samples). Dysplasia was graded according to the degree of nuclear atypia and glandular architectural changes (16).

Paraffin sections were immunostained with anti-Tβ4 antibodies using the labeled streptavidin-biotin complex system (LSAB2, Dako) in a Dako Autostainer (Dako-Cytomation, Carpinteria, CA, USA). Briefly, slides were deparaffinized and rehydrated, and endogenous peroxidase activity was quenched (30 min) by 0.3% hydrogen peroxide in methanol. The slides were then subjected to heat-induced antigen retrieval by steaming unstained sections in Target Retrieval Solution (Dako TRS pH 6.1) for 30 min. Next, the slides were incubated with 10% normal goat serum in phosphate-buffered saline (PBS) for 60 min to block non-specific binding, followed by incubation (60 min at room temperature) with a monoclonal anti-Thymosin Beta 4 antibody (Bachem-Peninsula Lab, San Carlos, CA, USA), diluted 1:100 in the blocking solution. Slides were extensively washed with PBS containing 0.01% Triton X-100 and incubated with a secondary reagent (En Vision kit) according to the manufacturer's (Dako, Glostrup, Denmark) instructions. Diaminobenzidine (DAB) was used as a chromogen. After additional washes, the color was developed using AEC reagent (Dako), and the sections were counterstained with Mayer's hematoxylin and mounted. Sections of reactive lymph nodes with Tβ4-immunoreactive histiocytes were utilized as positive controls. For negative controls, the same procedure was applied, omitting the primary antibody. All cases were independently analyzed by two pathologists specialized in gastrointestinal pathology (SN, GF).

■ RESULTS

In this study, Tβ4 expression was always restricted to the cytoplasm of normal and dysplastic cells. No nuclear reactivity was detected in intestinal cells. Four main patterns of immunostaining for Tβ4 were observed, as follows: a) granular cytoplasmic staining, localized to the entire cytoplasm or to the apical regions of the enterocytes and possibly representative of the localization of the peptide in vesicles; b) spot-like perinuclear immunostaining, possibly representative of Tβ4 localization in the trans-Golgi network, c) homogeneous cytoplasmic staining, probably marking the actin-binding activity of the peptide, and d) intraluminal granular reactivity. No significant differences regarding Tβ4 immunoreactivity were detected within the first five groups, whereas inter-individual differences were only found for the intensity of immunostaining. Marked

individual differences were observed in cases of colon cancer, in which Tβ4 was expressed in 10 of 15 cases.

Normal colon mucosa

All specimens of human colonic mucosa showed cytoplasmic expression of Tβ4. Immunoreactivity for Tβ4 was detected in the superficial enterocytes and in crypt cells. Immunoreactivity was consistently restricted to the cytoplasm and appeared as homogeneous staining. Tβ4 was also found in granular deposits in the intestinal lumen that were dispersed in the mucous secretions.

Hyperplastic polyps and sessile serrated polyps/adenomas

Hyperplastic glands and sessile serrated polyps/adenomas did not show any significant reactivity for Tβ4. Intense and granular cytoplasmic positivity was occasionally detected in scattered stromal mast cells (Figures 1A and 1B).

Adenomas with low-grade dysplasia

In adenomas with low-grade dysplasia, Tβ4 reactivity observed at low magnification appeared to be homogeneously present in all of the observed dysplastic glands (Figure 1C). No notable staining for Tβ4 was detected in hyperplastic gland cells. At higher magnification, three main patterns of reactivity were observed in dysplastic glands: i) a punctate granular pattern observed in the entire cytoplasm; ii) a band-like pattern occupying the apical zone of the proliferating enterocytes; and iii) spot-like perinuclear reactivity (Figure 1D).

Adenomas with high-grade dysplasia

When we studied Tβ4 expression in colon adenomas with high-grade dysplasia, we found significant differences from low-grade dysplastic adenomas. Immunoreactivity for Tβ4 appeared to be more diffuse throughout the cytoplasm of dysplastic cells (Figure 1E). In tubulo-villous adenomas, Tβ4 was mainly expressed in the cytoplasm of superficial dysplastic epithelial cells (Figure 1F).

Adenocarcinoma

Immunoreactivity for Tβ4 was detected in 10 out of 15 adenocarcinomas immunostained for the peptide. The most frequent immunohistochemical pattern was characterized by the accumulation of Tβ4 in the perinuclear area, giving rise to spot-like reactivity highly suggestive of localization to the trans-Golgi Network (Figure 1G). Granular discrete reactivity for Tβ4 was also detected in the stroma in close proximity to the glands with infiltrating tumors (Figure 1H).

■ DISCUSSION

This study comprehensively investigated the Tβ4 protein expression pattern in human colorectal polyps and adenomas, showing relevant changes in Tβ4 localization in enterocytes during different steps of colon carcinogenesis. In previous studies, Tβ4 was found to be expressed in cultured colon carcinoma cells (17). Subsequent data showed that Tβ4 overexpression was associated with a more malignant phenotype and with enhanced tumor cell invasion, which suggests that Tβ4 expression is associated with tumor aggressiveness and poor survival (18). A study investigating Tβ4 expression in a limited number of human

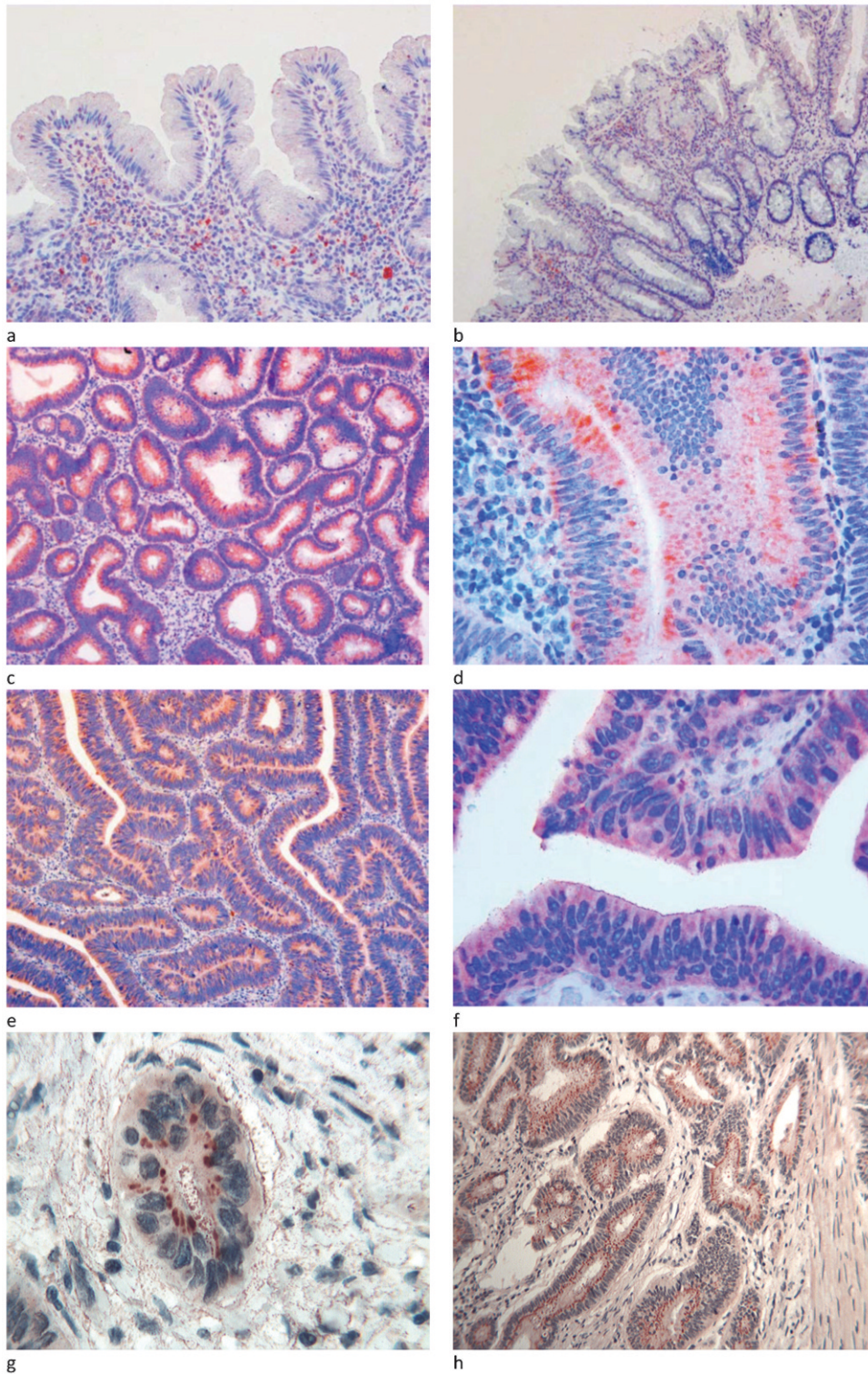


Figure 1 - Hyperplastic and serrated hyperplastic polyps: A), B) No immunoreactivity for Tβ₄ was observed in hyperplastic and serrated hyperplastic glands of the polyps analyzed. Scattered mast cells showed an intense and granular positivity for Tβ₄ (OM X250 and X 100). Adenoma with low-grade dysplasia: C) at low magnification, the diffuse cytoplasmic immunoreactivity for Tβ₄ was restricted to the dysplastic crypt epithelium (OM x100); D) at higher magnification, three main patterns of reactivity for Tβ₄ were observed in the dysplastic glands: perinuclear spots, cytoplasmic granules and homogeneous cytoplasmic immunostaining (OM x400); adenoma with high-grade dysplasia: E) at low magnification, intense cytoplasmic immunoreactivity for Tβ₄ was observed in the cytoplasm of dysplastic cells (OMx100); F) at higher magnification, diffuse and homogeneous Tβ₄ immunoreactivity was observed in the cytoplasm of dysplastic glands (OMx400); adenocarcinoma: G) at higher magnification, peri-nuclear spot-like reactivity for Tβ₄ was observed in the cytoplasm of the neoplastic nest (OMx400); H) perinuclear spot-like reactivity for Tβ₄ was observed in the cytoplasm of the infiltrating tumor glands. Fine granular immunoreactivity was detected in the stroma surrounding the infiltrating tumor glands (OMx250).



colon cancers reported highly variable immunostaining for Tβ4 in tumor cells and in endothelial and stromal cells (10). A recent study from our group showed strong Tβ4 cytoplasmic immunostaining in the tumor cells of the vast majority of colorectal adenocarcinomas (15). In this study, Tβ4 expression was found even in adenomas with low-grade dysplasia, representing the earliest stage of colorectal tumorigenesis. Further increases in Tβ4 expression paralleled the progression through distinct pathological stages, namely low-grade dysplasia and high-grade dysplasia. These findings clearly indicate that Tβ4 plays a role in colorectal carcinogenesis, starting from the early stages of adenomatous polyps and continuing through the progression towards colorectal cancer. It remains unclear whether Tβ4 staining could serve as a biomarker to distinguish colorectal adenomas that are more likely to progress to adenocarcinoma from Tβ4-negative polyps with no tendency toward cancer progression; long-term follow up and a large cohort of patients are required.

The absence of immunoreactivity for Tβ4 in sessile serrated polyps/adenomas is an interesting finding of our study. This finding suggests that Tβ4 could play a different role in the "serrated" pathway of colorectal neoplasia. From a practical point of view, the absence of immunoreactivity for Tβ4 in serrated polyps/adenomas might suggest the use of anti-Tβ4 antibodies in complex cases in which the differential diagnosis between low-grade adenoma and serrated polyp/adenoma is uncertain, based exclusively upon morphological criteria.

Colon cancer progression has also been associated with modifications in Tβ4 subcellular localization. In normal human colon mucosa, Tβ4 has a homogeneously diffuse staining pattern in the cytoplasm of superficial enterocytes and in the crypt epithelium. In hyperplastic polyps, we observed a complete disappearance of immunoreactivity for Tβ4. Interestingly, in low-grade dysplastic glands, we observed a preferential localization of Tβ4 to the trans-Golgi network, evidenced by perinuclear spot reactivity. The same immunostaining pattern for Tβ4 was previously reported in well-differentiated adenocarcinomas (15). In contrast, in high-grade adenomas, the pattern of Tβ4 immunolocalization changed to a cytoplasmic diffuse pattern. Although we were unable to attribute a certain function to Tβ4, particularly to its translocation to the Golgi apparatus and then back to the cytoplasm during colon carcinogenesis, we speculate that the diffuse cytoplasmic reactivity observed in normal mucosa could reflect the primary physiological role of Tβ4, i.e., the maintenance of actin cytoskeleton integrity, on which cell morphogenesis and motility depend (19). The translocation of Tβ4 from cytoplasmic vesicles to the trans-Golgi network may suggest a new function for this peptide in low-grade dysplastic cells; however, to the best of our knowledge, this function remains unclear. Translocation from the cell membrane to the trans-Golgi network has previously been reported in liver cells for ATP7B, a copper-transporting P-type ATPase. The localization of ATP7B in the Golgi apparatus reflects a synthetic role in the incorporation of copper atoms in cuproenzymes; under copper stress, ATP7B is relocated to the cell membrane and utilized in the excretion of excess copper (20). On the basis of these data, Tβ4 may play diverse roles in normal, dysplastic and tumor cells. Herein, we reported the preferential localization of Tβ4 in the Golgi apparatus in dysplastic and neoplastic cells, which may

suggest a role for Tβ4 in the secretory pathways of dysplastic enterocytes and in colon cancer cells. The absence of significant differences at the mRNA level between the normal colon mucosa and tumor tissues was previously reported by our group (15) and may suggest a deregulation of Tβ4 expression at the post-transcriptional level.

Recently, Tβ4 has been shown to be widely expressed in the gastrointestinal tract (21) and in the salivary glands (22) during human embryogenesis, whereas its expression is low or absent in many normal adult tissues. On the basis of the present data, Tβ4 could be added to the list of proteins involved in both the embryogenesis and carcinogenesis of the oral-gastrointestinal tract (23).

In summary, the present study demonstrated that Tβ4 is frequently expressed and usually deregulated in human colon adenomas and is preferentially localized in the trans-Golgi network in low-grade dysplasia, in the whole cytoplasm in high-grade dysplasia, and back to the Golgi apparatus in colon cancer. These findings suggest that Tβ4 translocation occurs during both the initial and the advanced stages of tumor progression in colorectal cancer. Identifying the molecular mechanism underlying this process is a major challenge for future research focusing on Tβ4 in human colon carcinogenesis. The well-known role of Tβ4 in the recruitment and stimulation of adult and progenitor cells to restore their embryonic pluripotency (19), together with its strong expression in all stages of colorectal carcinogenesis, leads us to hypothesize that Tβ4 may drive the development of colorectal adenocarcinoma during multistage carcinogenesis. Further studies at the molecular level are needed to validate these immunohistochemical results with other analytical methods.

■ ACKNOWLEDGMENTS

We want to thank Ms. Sandra Serra, Ms. Simonetta Paderi and Ms. Rossana Zedda for their technical assistance and Mr. Ignazio Ferru for his administrative support. This work was supported by Fondazione Banco di Sardegna. We gratefully acknowledge the Sardinia Regional Government for financial support (P.O.R. Sardegna F.S.E. Operational Programme of the Autonomous Region of Sardinia, European Social Fund 2007-2013 - Axis IV Human Resources, Objective I.3, Line of Activity I.3.1 "Avviso di chiamata per il finanziamento di Assegni di Ricerca").

■ AUTHOR CONTRIBUTIONS

Nemolato S, Fanni G, Cabras T and Restivo A designed the research and wrote the manuscript. Zorcolo L, Gerosa C and Danni F collected and analyzed the data. Di Felice E performed the immunohistochemical analysis. Faa G, Messina I, Castagnola M and Casula G supervised the final manuscript.

■ REFERENCES

1. Klein JJ, Goldstein AL, White A. Enhancement of *in vivo* incorporation of labeled precursors into Dann and total protein of mouse lymph nodes after administration of thymic extracts. *Proc Natl Acad Sci U S A*. 1965;53:812-7, <http://dx.doi.org/10.1073/pnas.53.4.812>.
2. Mannherz HG, Hannappel E. The β-thymosins: intracellular and extracellular activities of a versatile actin binding protein family. *Cell Motil Cytoskeleton*. 2009;66(10):839-51, <http://dx.doi.org/10.1002/cm.20371>.
3. Sanders MC, Goldstein AL, Wang YL. Thymosin beta 4 (Fx peptide) is a potent regulator of actin polymerization in living cells. *Proc Natl Acad Sci U S A*. 1992;89(10):4678-82, <http://dx.doi.org/10.1073/pnas.89.10.4678>.
4. Koutrafouris V, Leondiadis L, Avgoustakis K, Livianou E, Czarnecki J, Ithakissios DS, et al. Effect of thymosin peptides on the chick chorioallantoic membrane angiogenesis model. *Biochim Biophys Acta*. 2001;1568(1):60-6, [http://dx.doi.org/10.1016/S0304-4165\(01\)00200-8](http://dx.doi.org/10.1016/S0304-4165(01)00200-8).



5. Malinda KM, Sidhu GS, Mani H, Banaudha K, Maheshwari K, Goldstein AL, et al. Thymosin beta 4 accelerates wound healing. *J Invest Dermatol.* 1999;113(3):364-8, <http://dx.doi.org/10.1046/j.1523-1747.1999.00708.x>.
6. Badamchian M, Fagarasan MO, Danner RL, Suffredini AF, Damavandy H, Goldstein AL. Thymosin β4 reduces lethality and downmodulates inflammatory mediators in endotoxin induced septic shock. *Int. Int Immunopharmacol.* 2003;3(8):1225-33, [http://dx.doi.org/10.1016/S1567-5769\(03\)00024-9](http://dx.doi.org/10.1016/S1567-5769(03)00024-9).
7. Bock-Marquette I, Saxena A, White MD, DiMaio JM, Srivasta D. Thymosin beta 4 activates integrin-linked kinase and promotes cardiac cell migration, survival and cardiac repair. *Nature.* 2004;432(7016):466-72, <http://dx.doi.org/10.1038/nature03000>.
8. Srivastava D, Saxena A, Dimaio JM, Bock-Marquette I. Thymosin β4 is cardioprotective after myocardial infarction. *Ann N Y Acad Sci.* 2007;1112:161-70, <http://dx.doi.org/10.1196/annals.1415.048>.
9. Reti R, Kwon E, Qiu P, Wheeler M, Sosne G. Thymosin beta4 is cytoprotective in human gingival fibroblasts. *Eur J Oral Sci.* 2008;116(5):424-30.
10. Larsson L-I, Holck S. Localization of thymosin β-4 in tumours. *Ann N Y Acad Sci.* 2007;1112:317-25, <http://dx.doi.org/10.1196/annals.1415.005>.
11. Larsson L-I, Holck S. Occurrence of thymosin β4 in human breast cancer cells and in other cell types of the tumor microenvironment. *Human Pathol.* 2007;38(1):114-9, <http://dx.doi.org/10.1016/j.humpath.2006.06.025>.
12. Yamamoto T, Gotoh M, Kitajima M, Hirohashi S. Thymosin beta-4 is correlated with metastatic capacity in colorectal carcinomas. *Biochem Biophys Res Commun.* 1993;193(2):706-10, <http://dx.doi.org/10.1006/bbrc.1993.1682>.
13. Cha HJ, Jeong MJ, Kleinman HK. Role of thymosin β4 in tumor metastasis and angiogenesis. *J Natl Cancer Inst.* 2003;95(22):1674-80.
14. Goldstein AL. Thymosin β4: a new molecular target for antitumour strategies. *J Natl Cancer Inst.* 2003;95(22):1646-7.
15. Nemolato S, Restivo A, Cabras T, Coni P, Zorcolo L, Orrù G, et al. Thymosin β 4 in colorectal cancer is localized predominantly at the invasion front in tumor cells undergoing epithelial mesenchymal transition. *Cancer Biol Ther.* 2012;13(4):191-97.
16. European Colorectal Cancer Screening Guidelines Working Group, van Karsa L, Patnick J, Segnan N, Atkin W, Hallaron S, et al. European guidelines for quality assurance in colorectal screening and diagnosis: overview and introduction to the full supplement publication. *Endoscopy.* 2013;45(1):51-9.
17. Wang WS, Chen PM, Hsiao HL, Ju SY, Su Y. Overexpression of the thymosin beta-4 gene is associated with malignant progression of colon cancer cells. *Oncogene.* 2003;22(21):3297-306, <http://dx.doi.org/10.1038/sj.onc.1206404>.
18. Wang WS, Chen PM, Hsiao HL, Wang HS, Liang WY, Su Y. Overexpression of the thymosin beta-4 gene is associated with increased invasion of SW480 colon carcinoma cells and the distant metastasis of human colorectal cancer. *Oncogene.* 2004;23(39):6666-71, <http://dx.doi.org/10.1038/sj.onc.1207888>.
19. Smart N, Rossdeutsch A, Riley PR. Thymosin β4 and angiogenesis: modes of action and therapeutic potential. *Angiogenesis.* 2007;10(4):229-41, <http://dx.doi.org/10.1007/s10456-007-9077-x>.
20. Roelofsen H, Wolters H, Van Luyn MJ, Miura N, Kuipers F, Vonk RJ. Copper-induced apical trafficking of ATP7B in polarized hepatoma cells provide a mechanism for biliary copper excretion. *Gastroenterology.* 2000;119(3):782-93, <http://dx.doi.org/10.1053/gast.2000.17834>.
21. Portyanko A, Kovalev P, Gorgun J, Cherstvoy E. βIII-tubulin at the invasive margin of colorectal cancer: possible link to invasion. *Virchows Arch.* 2009;454(5):541-8, <http://dx.doi.org/10.1007/s00428-009-0764-4>.
22. Nemolato S, Cabras T, Cau F, Fanari MU, Fanni D, Manconi B, et al. Different thymosin Beta 4 immunoreactivity in foetal and adult gastrointestinal tract. *PLoS One.* 2010;5(2):e9111, <http://dx.doi.org/10.1371/journal.pone.0009111>.
23. Nemolato S, Messana I, Cabras T, Manconi B, Inzitari R, Fanali C, et al. Thymosin beta(4) and beta(10) levels in pre-term newborn oral cavity and foetal salivary glands evidence a switch of secretion during foetal development. *PLoS One.* 2009;4(4):e5109, <http://dx.doi.org/10.1371/journal.pone.0005109>.