

Single Case

Unhappy Triad: Infection with *Leptospira* spp. *Escherichia coli* and *Bacteroides uniformis* Associated with an Unusual Manifestation of Portal Vein Thrombosis

Sven Kalbitz^a Jörg Ermisch^a Jonathan M. Schmidt^{a, b} Ingo Wallstabe^b
Christoph Lübbert^{a, c, d}

^aDepartment of Infectious Diseases, Tropical Medicine, Nephrology and Rheumatology, St. Georg Hospital, Leipzig, Germany; ^bDepartment of Gastroenterology, Hepatology, Diabetology and Endocrinology, St. Georg Hospital, Leipzig, Germany; ^cDivision of Infectious Diseases and Tropical Medicine, Leipzig University Hospital, Leipzig, Germany; ^dInterdisciplinary Center for Infectious Diseases, Leipzig University Hospital, Leipzig, Germany

Keywords

Septic portal vein thrombosis · Pylephlebitis · Leptospirosis · Polymicrobial infection · Colonic diverticulitis · Anticoagulation · Case report

Abstract

Portal vein thrombosis (PVT) is a rare disease with an incidence of 0.7/100,000 inhabitants per year. Septic PVT (pylephlebitis) usually occurs secondary to infection in the anatomic region drained by the portal venous system. We report on a 76-year-old German male who was admitted with a history of recurrent fever and acute renal failure. Blood cultures taken on admission showed *Escherichia coli*, as well as *Bacteroides uniformis* after an extended incubation period of 90 h. In addition, infection with *Leptospira* spp. was diagnosed serologically. Computerized tomography of the abdomen revealed an extensive PVT along with signs of colonic diverticulitis. Symptoms resolved under prolonged antimicrobial therapy with beta-lactams and adequate heparinization. A myeloproliferative disorder could be excluded. There was no evidence of an underlying coagulation disorder. Imaging controls showed an almost complete resolution of the PVT after 6 months of anticoagulation therapy. To the best of our knowledge, this is the first report of such an “unhappy triad,” which includes atypical manifestations of leptospirosis and involvement of other intestinal bacteria.

© 2021 The Author(s).

Published by S. Karger AG, Basel

Correspondence to:
Christoph Lübbert, christoph.luebbert@medizin.uni-leipzig.de

Introduction

Portal vein thrombosis (PVT) is a rare disease with an incidence of 0.7/100,000 inhabitants per year [1] describing a thrombosis in the extrahepatic or intrahepatic part of the portal vein. Often chronic liver disease or malignancy of the liver itself is already present. However, inflammation or malignancy of neighboring organs can also cause PVT. Septic PVT (pyelephlebitis) usually occurs secondary to infection in the anatomic region drained by the portal venous system [2].

Leptospirosis is an important cause of sepsis, mainly in tropical areas, and pulmonary hemorrhage is the major cause of death [3]. Characteristically, infection with *Leptospira* spp. is associated with thrombocytopenia, platelet dysfunction, and multifactorial coagulopathy [4, 5]. In some cases, however, leptospirosis may also induce hypercoagulability with measurable increases in prothrombotic indicators such as fibrinogen, thrombin-antithrombin III complex, and prothrombin fragments [4, 5], leading to thromboembolic complications.

If PVT is diagnosed, a well-balanced interdisciplinary therapeutic decision is required, comprising radiological interventions for recanalization, solitary anticoagulation therapy, or surgical interventions (e.g., shunt placement or, as a last resort, liver transplantation). Treatment strategies must adequately take into account the etiology of PVT and the associated diseases of the individual patient.

Case Presentation

A 76-year-old German male presented to the emergency department with a high fever (39.1°C) in July 2020. Despite the diagnosis of acute renal failure at that time, the patient discharged himself against explicit medical advice. After temporary clinical improvement, but recurrent episodes of fever, the patient presented again to the emergency room after 12 days and was eventually admitted to the infectious diseases department. Laboratory results revealed acute renal failure (AKIN I, serum creatinine 178 µmol/L, glomerular filtration rate 32 mL/min/1.73 m²), signs of rhabdomyolysis (creatinine kinase 4.98 µmol/L × s), elevated liver transaminases (ALAT 0.94 µmol/L × s, ASAT 0.94 µmol/L × s), hyponatremia (serum sodium 128 mmol/L), signs of increased prothrombotic activity (fibrin monomers positive), and mild proteinuria (interstitial pattern, 166 mg/L), along with left-shifted leukocytosis (17.6 GPT/L, 79% neutrophils) and marked increase in C-reactive protein (178 mg/L).

Under the working diagnosis of a bacteremic urogenic infection, calculated antimicrobial therapy with intravenous cefotaxime (2 g TID) was administered. *Escherichia coli* was detected in the blood culture. Since the urine culture was negative and the fever persisted, abdominal imaging including contrast-enhanced computerized tomography was initiated, which revealed extensive PVT (shown in Fig. 1, 2) and signs of colonic diverticulitis (classification of diverticular diseases, Ia). The thrombosis prophylaxis with low-molecular-weight heparin was increased to a therapeutic dose. After an extended incubation interval of 90 h, *Bacteroides uniformis* was also detected in blood cultures. Antibiotic treatment was then escalated to intravenous meropenem (1 g TID), adding up to a total duration of the antimicrobial therapy of 21 days. Taking into account the symptom complex of fever, elevated liver transaminases, signs of rhabdomyolysis, increased prothrombotic activity, and acute renal failure as well as the anamnestic information that the patient had recently cleaned his flooded basement, a leptospiral serology (ELISA) was ordered, which revealed positive IgM antibodies and consecutive IgG seroconversion. Pathogen detection by molecular genetic methods as well as pathogen cultivation for *Leptospira* spp. was not successful. To rule out underlying malignancies, we additionally performed colonoscopy, a combined thoracal/abdominal

Fig. 1. Contrast-enhanced CT (coronal reconstruction) of the abdomen: arrows point toward the PVT (black arrow: main branch of the portal vein filled with contrast medium; white arrow: portal vein thrombus). PVT, portal vein thrombosis; CT, Computerized tomography.

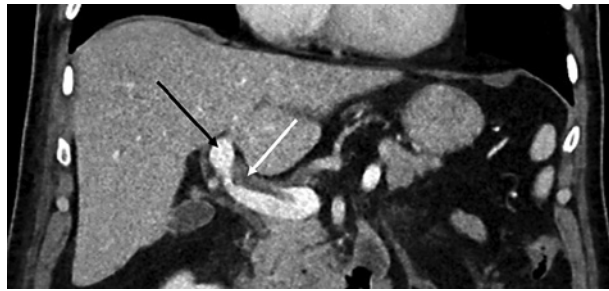
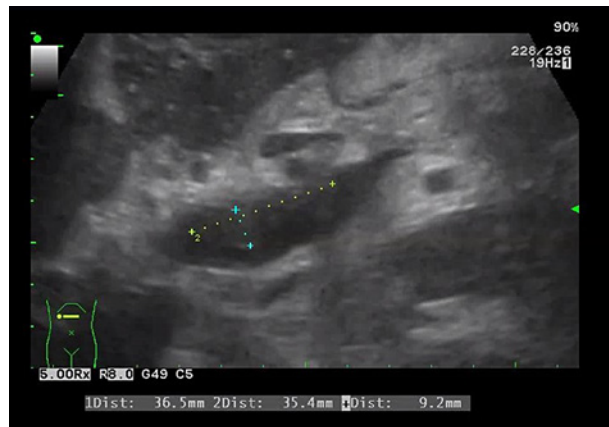

Fig. 2. Ultrasound image (B mode) of the PVT (extent of the thrombus: 36.5 × 35.4 mm). PVT, portal vein thrombosis.



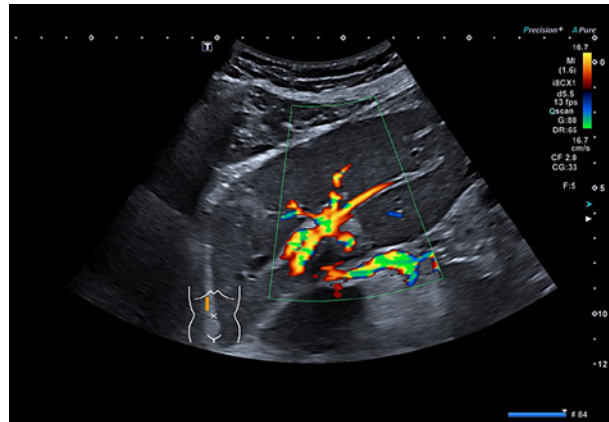
contrast-enhanced high-resolution computerized tomography-scan, bone marrow cytology and histology, serum electrophoresis, and immunofixation, which gave all inconspicuous findings. In the further course, hemorrhagic shock occurred, caused by Dieulafoy ulcer bleeding in the duodenum (Forrest Ib). The bleeding was stopped by endoscopic intervention with clip application and adrenalin injection, followed by rapid and adequate clinical improvement. Upon discharge from inpatient treatment, the laboratory values for serum creatinine, calculated glomerular filtration rate, creatine kinase, liver transaminases, blood cell count, and C-reactive protein had normalized.

After 3 months, the patient was seen in the hemostasis and thrombosis outpatient clinic. All global coagulation tests were normal, and there was no evidence of hereditary thrombophilia. After 6 months of therapeutic anticoagulation with low-molecular-weight heparin, the patient presented in our outpatient clinic for an ultrasound follow-up. The main thrombosis of the portal vein was no longer detectable, but the left branch of the portal vein still appeared to be thrombosed. Arterialization of the left lobe of the liver was demonstrated (shown in Fig. 3). Finally, the anticoagulation treatment could be terminated.

Discussion

Bacteroides spp. and *Escherichia coli* are the most common causative agents of septic PVT [2]. In the majority of cases, infectious affection of the portal vein system is a result of underlying colonic diverticulitis [6], as suggested in the patient presented here. Another common cause of PVT is myeloproliferative disorders, malignancies, and liver cirrhosis with abnormal coagulation parameters [7]. Gastrointestinal bleeding is a major complication of chronic PVT

Fig. 3. Duplex ultrasound image of the liver at 6-month follow-up, showing almost complete resolution of the PVT in the main branch with arterialization of the left liver lobe. PVT, portal vein thrombosis.



[8] but occurs rarely in acute septic PVT. The optimal anticoagulation in PVT remains controversial. The American College of Gastroenterology recommends anticoagulation with a low level of evidence for a period of 3 to 6 months [9]. In noncirrhotic patients with PVT, early anticoagulation resulted in complete recanalization of the portal vein in one-third of the patients [10].

Acute renal failure, rhabdomyolysis, and biphasic progression are classic complications of severe leptospirosis [11], but infection with *Leptospira* spp. accompanied by PVT has rarely been described [12]. However, activation of the coagulation system triggering the development and progression of thrombosis can be found in the literature [4]. To what extent *Leptospira* spp. may induce coagulopathies or hemorrhages by endothelial alterations cannot be answered conclusively. For both pathophysiological pathways, only observational case series and in vitro data exist so far [13].

In summary, we describe a case of acute leptospirosis complicated by septic PVT associated with coincident bacteremic infection with *Escherichia coli* and *Bacteroides uniformis*, most likely due to colonic diverticulitis. To the best of our knowledge, this is the first report of such an “unhappy triad.”

We acknowledge support from Leipzig University for Open Access Publishing.

Statement of Ethics

This study protocol was reviewed and the need for approval was waived by the Ethics Committee of the Saxonian Board of Physicians (Dresden, Germany). Written informed consent was obtained from the patient for publication of this case report and accompanying images.

Conflict of Interest Statement

The authors report no competing interests.

Funding Sources

This manuscript did not receive any funding.

Author Contributions

S.K., J.E., J.M.S., I.W., and C.L. cared for the patient. S.K. and C.L. drafted the manuscript. All the authors read and approved the final manuscript.

References

- 1 Rajani R, Björnsson E, Bergquist A, Danielsson A, Gustavsson A, Grip O, et al. The epidemiology and clinical features of portal vein thrombosis: a multicentre study. *Aliment Pharmacol Ther*. 2010;32:1154–62.
- 2 Plemmons RM, Dooley DP, Longfield RN. Septic thrombophlebitis of the portal vein (Pylephlebitis): diagnosis and management in the modern era. *Clin Infect Dis*. 1995;21:1114–20.
- 3 Bharti AR, Nally JE, Ricaldi JN, Matthias MA, Diaz MM, Lovett MA, et al., Peru-United States Leptospirosis Consortium. Leptospirosis: a zoonotic disease of global importance. *Lancet Infect Dis*. 2003;3:757–71.
- 4 Chierakul W, Tientadakul P, Suputtamongkol Y, Wuthiekanun V, Phimda K, Limpaboon R, et al. Activation of the coagulation cascade in patients with leptospirosis. *Clin Infect Dis*. 2008;46:254–60.
- 5 Medeiros Fda R, Spichler A, Athanzio DA. Leptospirosis-associated disturbances of blood vessels, lungs and hemostasis. *Acta Trop*. 2010;115:155–62.
- 6 Ames JT, Federle MP. Septic thrombophlebitis of the portal venous system: clinical and imaging findings in thirty-three patients. *Dig Dis Sci*. 2011;56:2179–84.
- 7 Manzano-Robleda Mdel C, Barranco-Fragoso B, Uribe M, Méndez-Sánchez N. Portal vein thrombosis: what is new? *Ann Hepatol*. 2015;14:20–7.
- 8 Basit SA, Stone CD, Gish R. Portal vein thrombosis. *Clin Liver Dis*. 2015;19:199–221.
- 9 Simonetto DA, Singal AK, Garcia-Tsao G, Caldwell SH, Ahn J, Kamath PS. ACG clinical guideline: disorders of the hepatic and mesenteric circulation. *Am J Gastroenterol*. 2020;115:18–40.
- 10 Plessier A, Darwish-Murad S, Hernandez-Guerra M, Consigny Y, Fabris F, Trebicka J, et al. Acute portal vein thrombosis unrelated to cirrhosis: a prospective multicenter follow-up study. *Hepatology*. 2010;51:210–8.
- 11 Cetin BD, Harmanakaya O, Hasman H, Gunduz A, Oktar M, Seber E, et al. Acute renal failure: a common manifestation of leptospirosis. *Ren Fail*. 2009;26:655–61.
- 12 Afzal I, Thaker R, Weissman S, Kothari M. Leptospirosis as an unusual culprit of acute pancreatitis and portal vein thrombosis in a New Yorker. *Clin Case Rep*. 2020;8:690–5.
- 13 Wagenaar JF, Goris MG, Partiningrum DL, Isbandrio B, Hartskeerl RA, Brandjes DP, et al. Coagulation disorders in patients with severe leptospirosis are associated with severe bleeding and mortality. *Trop Med Int Health*. 2010;15:152–9.