

# Role of Laparoscopic Distal Pancreatectomy for Solid Pseudopapillary Tumor

Julien Jarry, MD, Rodolphe Bodin, MD, Thierry Peycru, MD, Manuel Nunez, MD,  
Denis Collet, MD, PhD, Antonio Sa Cunha, MD, PhD

## ABSTRACT

**Background:** Since the first case report regarding laparoscopic distal pancreatectomy (DP) for solid pseudopapillary tumor (SPT), few additional articles have been published. The objective of this study was to evaluate the feasibility, safety, and long-term outcome of the laparoscopic DP based on a series of adult SPT patients.

**Methods:** In a single-center study, we screened all adult patients undergoing a laparoscopic DP for SPT. Preoperative, operative, and postoperative data were retrospectively analysed and compared to the results of open DP for SPT published in the medical literature.

**Results:** From April 2000 to June 2010, 5 adult female patients (median age 34 y) underwent a laparoscopic DP for an SPT. No conversion to open surgery was required. The median size of the tumor was 45 mm. The postoperative mortality rate was 0%, and serious complications (Dindo IV) occurred in 2 patients. The postoperative quality of life was not significantly altered by the laparoscopic procedure. At a median follow-up of 60 mo, all patients were alive and without evidence of local recurrence, distant metastasis, diabetes, or exocrine insufficiency.

**Conclusion:** Laparoscopy may offer an alternative to open surgery in the treatment of SPT of the distal pancreas in adult female patients. The laparoscopic procedure impacts neither the oncologic outcome nor the quality of life. However, due to the risk of postop-

erative complications, this procedure should be reserved for specialized centers.

**Key Words:** Pancreas, Solid and pseudopapillary tumor (SPT), Distal pancreatectomy (DP), Laparoscopy.

## INTRODUCTION

Laparoscopic resection of the pancreas was initially described in the medical literature in the early 1990s. The first laparoscopic pancreatoduodenectomy was performed in 1994, and the first distal pancreatectomy (DP) was performed in 1996.<sup>1,2</sup> Development of endoscopic instruments and advances in technique have made laparoscopic DP an effective option for the treatment of pancreatic disease. The laparoscopic approach is also particularly well adapted to DP, because it eliminates the need to perform an anastomosis. Although laparoscopic surgery for highly malignant pancreatic tumors is considered controversial, there are no current recommendations for low-grade malignant tumors, such as solid pseudopapillary tumors (SPTs). SPT is a rare clinical entity, representing 1% to 2% of all primary exocrine tumors of the pancreas. More than 80% of patients are female, and 85% are < 30 y old.<sup>3</sup> Only 8 case reports of pancreatic SPT operated under laparoscopy have been reported in the English medical literature, and of these, the majority were pediatric cases.<sup>4–11</sup> More recently, Cavallini et al.<sup>12</sup> published the first series of patients undergoing laparoscopic DP for SPT. They concluded that laparoscopic DP was a safe and feasible procedure for patients affected by pancreatic SPT. However, their population series included both adults and children, male and female. This large diversity makes it difficult to provide general recommendations, since some SPTs features differ according to sex and age.<sup>13,14</sup> Consequently, we decided to evaluate preoperative, operative, and postoperative results of laparoscopic DP in a homogeneous population of adult female patients. To the best of our knowledge and based on a review of the medical literature, this is the first study on this subject to date.

Department of Digestive Surgery, Robert Picqué Hospital, 351 route de Toulouse, 33140 Villenave d'Ormon, France (Drs. Jarry, Bodin, Peycru).

Reid Trainee Health Clinic, 1515 Truemper Road, Lackland AFB, TX 78236, USA (Dr Nunez).

Department of Digestive Surgery, Haut Leveque hospital, Avenue Magellan, 33600, Pessac France (Drs. Collet, Cunha).

The authors thank Mrs Antonia Giraud for her editorial work.

Address correspondence to: Julien Jarry, MD, Robert Picqué Hospital, 351 route de Toulouse, 33140 Villenave d'Ormon, France. Phone: (0033) 664352995, Fax: (0033) 472365489, E-mail: julienjarry@hotmail.com

DOI : 10.4293/108680812X13462882736970

© 2012 by JSLs, *Journal of the Society of Laparoendoscopic Surgeons*. Published by the Society of Laparoendoscopic Surgeons, Inc.

## MATERIALS AND METHODS

### Patient Selection

A retrospective chart review was done for all adult patients (age > 18 y) undergoing laparoscopic DP between April 2000 and June 2010 in the department of adult pancreatic surgery at Haut Leveque University Hospital in Bordeaux, France. Only patients with a definitive diagnosis of SPT were selected. No patient was excluded from the study. The preoperative assessment included a computed tomographic (CT) scan of the thorax, abdomen, and pelvis, a pancreatic magnetic resonance imaging (MRI), and an endoscopic ultrasound (EUS) with biopsy of the pancreatic mass for 1 patient. The preoperative anesthetic evaluation was done using the American Society of Anesthesiology guidelines, and the patient's consent was signed before surgery.

### Endpoint Assessment

Preoperative, operative, and postoperative data were prospectively collected and retrospectively analysed. These data were compared to the data of open DP for SPT published in the medical literature. Preoperative parameters included patient demographics (age, sex, body mass index, American Society of Anesthesiologists score) while operative parameters included total operating time, conversion necessity, blood loss, transfusion, and tumor characteristics (median size). The following postoperative data were collected.

**Overall morbidity:** Every medical and surgical complication occurring during the postoperative follow-up was recorded according to the classification of Dindo et al.<sup>15</sup>

**Splenic complications:** Splenic infarct, focal or massive, detected by color Doppler ultrasonography.

**Presence of pancreatic fistula:** According to the International Study Group on Pancreatic Fistula<sup>16</sup> this entity was deemed present if there was any measurable drainage from an operatively placed drain with amylase levels > 3 times the upper limit of normal serum levels. All patients below this range were considered to have no biochemical evidence of fistula.

**Severity of pancreatic fistula as defined by International Study Group on Pancreatic Fistula<sup>16</sup>:** Grade A fistulas: transient asymptomatic fistulas evident only by elevated drainage amylase levels. Grade B fistulas: symptomatic, clinically apparent fistulas that require diagnostic evaluation and therapeutic management. Grade C fistulas: se-

vere, clinically significant fistulas that require major intervention.

**Abscess:** culture-positive purulent drainage from an intra-abdominal fluid collection obtained either percutaneously or operatively; and/or radiographically confirmed fluid collection with systemic or localized signs of infection.

**Length of hospital stay (LHS):** days from the initial operation to hospital discharge.

**Completeness of resection:** An R0 resection was considered to have been performed if the primary tumor was removed with negative margins. Patients with microscopically positive margins or grossly positive margins were classified as having had an R1 or R2 resection, respectively.

**Quality of life:** assessed by recording the patient's SF-36 score both 1 mo prior to the operation and 1 mo postoperatively.<sup>17</sup> The questionnaire was completed by the patients themselves. A Mann-Whitney U test was carried out to compare pre- and postoperative SF-36 scores.

**Overall and disease-free survival:** Overall survival (OS) was defined as the delay between the date of surgery and the date of death, and disease-free survival (DFS) was defined as the delay between the date of surgery and the date of the first postoperative diagnosis of local recurrence. OS and DFS were estimated using the Kaplan-Meier method.

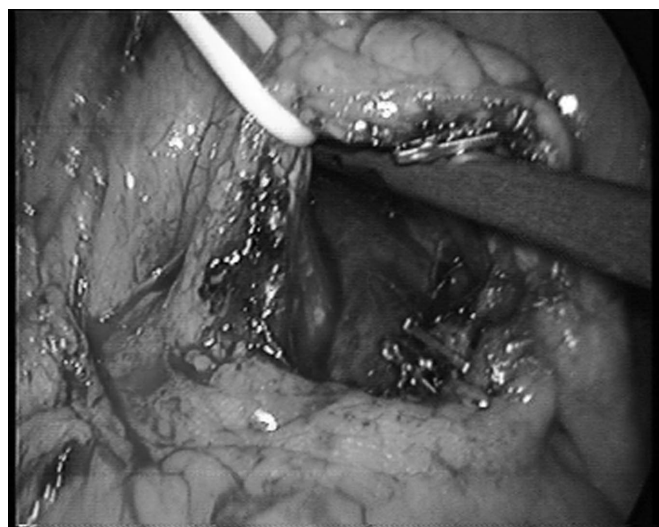
### Surgical Technique

All laparoscopic procedures were performed in a standardized fashion by a single surgeon. The patient was placed supine in a 30° reverse Trendelenburg position with the surgeon standing between the patient's legs. The laparoscopic monitor was to the left of the patient's head. A 4-port laparoscopic technique was used. A 10-mm camera port was placed at the umbilicus. Two additional working 5-mm ports, along with a 12-mm port for the linear stapling device, were placed in the xiphoid area and the right and left flanks, respectively. Laparoscopic distal pancreatectomy was performed with spleen preservation following Warshaw's technique (splenic vessel division). Electrocautery and LigaSure Atlas were used for dissection.<sup>18</sup> A wide window was made in the gastrocolic ligament. A forceps was used to raise the stomach from the epigastric trocar enabling good exposure of the body and tail of the pancreas. The inferior border of the gland was dissected and the tail detached from the retroperitoneum. This mobilization enabled visualization of the posterior wall of the gland and the splenic vessels which were

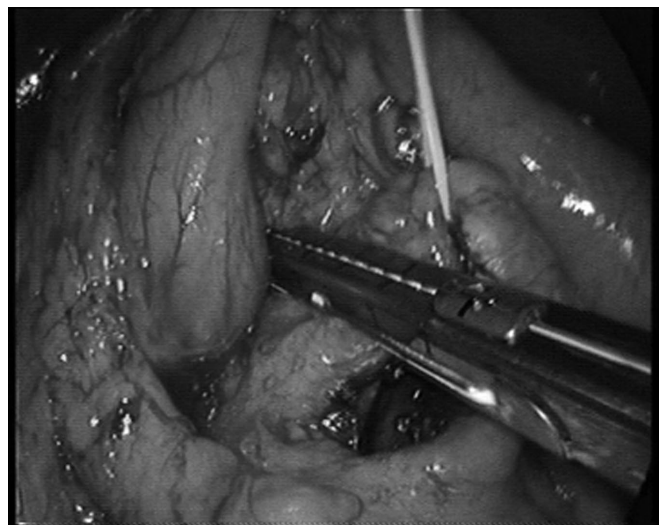
divided (**Figure 1**). The pancreatectomy was achieved by transection of the pancreatic body with an endoscopic linear 45-mm stapler (**Figure 2**). The dissected part of the pancreas was extracted in an endoscopic bag retrieval system through a Pfannenstiel incision. A drain was placed on the pancreatic stump and drawn out through the 12-mm port.

### Follow-up

After surgery, all patients underwent regular follow-up consultations at 4 mo, 6 mo, and annually thereafter. The



**Figure 1.** Operative view: The distal pancreas has been dissected off the splenic vessels, and the splenic vessels have been divided using a LigaSure Atlas and clips.



**Figure 2.** Operative view: The distal pancreas is transected with an endoscopic GIA stapler.

follow-ups included clinical examination and CT scan of the thorax and abdomen. All patients were present at the 1-y follow-up consultation. One patient was absent at all subsequent follow-ups.

## RESULTS

### Preoperative Data (Table 1)

Between April 1997 and June 2010, 75 patients underwent laparoscopic distal resection of the pancreas in our surgical department. Among them, 5 were operated on for a pancreatic SPT. Over the same period, we performed 86 open distal resections for various tumors of the pancreas. The 5 patients operated on for a pancreatic SPT were all Caucasian women with a median age of 34 y (range, 20 to 44). The median preoperative BMI was 20.4 kg/m<sup>2</sup> (range, 17 to 24). Using the American Society of Anaesthesiology (ASA) classification system, all the patients were classified as “ASA 1.” The diagnosis of SPT was made after initial assessment in 3 patients. The remaining 2 cases were initially misdiagnosed as mucinous cystadenoma, and the diagnosis of SPT was made only after histological analysis.

### Operative Data (Table 1)

Five laparoscopic DPs with Warshaw's procedure were performed. The spleen was conserved in 4 patients but had to be removed in 1 patient due to an iatrogenic injury during the laparoscopic procedure. The SPTs were located within the pancreatic body in 3 patients while the other 2 were located in the tail. Median tumor size was 45 mm (range, 22 to 80). No conversions were performed during the initial procedure. The median blood loss was 100 mL, and no blood transfusions were necessary during the 5 laparoscopic procedures. The median operative time was 230 min (range, 210 to 260) for the 5 laparoscopic procedures versus 215 min (range, 145 to 310;  $P = .129$ ) for the 86 patients undergoing a standard open DP in our institution.

### Postoperative Data (Table 1)

No case of perioperative mortality was recorded. Three postoperative complications occurred including 1 splenic ischemia (Dindo IV), 1 acute hemorrhage of the inferior pancreatic artery (Dindo IV), and 1 grade A pancreatic fistulae (Dindo I). Reoperation was required in 2 patients – the first after acute hemorrhage of the inferior pancreatic artery on postoperative day 2 (the patient underwent an emergency laparotomy to achieve hemostasis), the second case after

**Table 1.**  
Data of Adult Patients with Solid Pseudopapillary Tumor Operated Under Laparoscopy

	Patient 1	Patient 2	Patient 3	Patient 4	Patient 5
Age at Diagnosis (y)	20	34	34	25	44
Sex	Female	Female	Female	Female	Female
ASA <sup>a</sup>	1	1	1	1	1
BMI <sup>a</sup> (kg/m <sup>2</sup> )	20.3	24	17	21	20.4
Clinical Presentation at Diagnosis	Abdominal pain	Abdominal pain	Asymptomatic	Asymptomatic	Abdominal pain
Localization and Lesion Size (mm)	Body, 22	Body, 45	Body, 80	Tail, 50	Tail, 38
Number of Resected Lymph Node	3	1	8	5	3
Operative Time (min)	240	210	230	220	260
Morbidity DINDO Score	0	Fistula Grade A I	Splenic Infarction IV	Hemorrhage IV	0
LHS <sup>a</sup> (days)	7	20	30	10	16
Reoperation	No	No	Yes	Yes	No
Follow-up (months)	12	96	72	60	24

<sup>a</sup>BMI=body mass index; SP=splenopancreatectomy, LHS=length of hospital stay.


splenic ischemia, complicated by a splenic abscess (the patient underwent a laparotomy with splenectomy and peritoneal washout on postoperative day 22). Following laparoscopic DP, the median length of hospital stay was 16 d (range, 7 to 30) versus 17.7 d (range, 8 to 42) after a standard open DP ( $P = .402$ ).

Resection was classified as R0 in all the patients. An average number of 4 lymph nodes were resected with the pancreatic specimen. No lymph node metastases and no perineural invasions were found on histological analysis. None of the patients received adjuvant chemotherapy or radiotherapy. At a median follow-up of 60 mo (range, 12 to 108), all patients were alive without evidence of local recurrence, metastasis, diabetes, or exocrine insufficiency.

Comparison of the different pre- and postoperative SF 36 scores (**Figure 3**) did not reveal any significant difference in terms of physical functioning ( $P = .97$ ), general health perceptions ( $P = .06$ ), mental health ( $P = .37$ ), emotional role ( $P = .95$ ), physical role ( $P = .41$ ), social functioning ( $P = .93$ ), vitality ( $P = .91$ ), and bodily pain ( $P = .96$ ).

## DISCUSSION

SPTs are one of the most uncommon histotypes of all exocrine pancreatic neoplasms. They were first described by Frantz in 1959.<sup>19</sup> Since then, various names have been



**Figure 3.** Comparison of SF-36 Quality of Life Assessment pre-operatively and at 1 mo after surgery.

used to describe this unusual lesion, such as Frantz tumor, solid and cystic tumor of the pancreas, papillary cystic tumor, solid and papillary epithelial neoplasm, and Hamoudi's tumor. However, according to the World Health Organization classification of exocrine pancreatic tumors, the appropriate terminology for this tumor is SPT of the pancreas.<sup>20</sup>



Mao,<sup>3</sup> in a cumulative review of the literature, found that 90% of patients with SPT were females with a mean age of 23.9 y. In our group, 100% of the patients were female with a median age of 34 y, which is comparable to other findings reported in the United States, but older than several reported from Asia.<sup>21,22</sup>

Clinically, patients with pancreatic SPT may present with nonspecific symptoms, including vague abdominal pain, increasing abdominal girth, or a palpable mass, while 9% are described as asymptomatic.<sup>22</sup> In our series, 2 patients were asymptomatic with SPT discovered incidentally, and 3 patients presented with atypical abdominal pain ultimately leading to the diagnosis of SPT. This nonspecific presentation might delay diagnosis and lead to relatively larger tumor size upon first clinical evaluation, although tumor size has not been shown to be a predictor of resectability.<sup>22</sup> This was also demonstrated in our series, because SPT of up to 8cm could still be completely resected.

The differential diagnosis of pancreatic SPT includes any solid or cystic pancreatic disease entities. In our series, only 1 patient underwent an EUS with biopsy in the preoperative assessment. As a result, 2 SPTs were initially misdiagnosed as mucinous cystic tumors. This demonstrates the necessity to perform a systematic preoperative histologic diagnosis for all suspected SPTs.

Definitive treatment of pancreatic SPT is achieved by complete resection of the tumor, preserving as much pancreatic tissue as possible, with the surgical approach depending on both tumor location and size. The first surgical resection of a pancreatic SPT was performed by Grosfeld and described by Hamoudi in 1970.<sup>23</sup> Thirty-three years later, Carricaburu<sup>4</sup> reported the first case of laparoscopic SPT resection in a child. Since then, only a few similar case reports have been published.<sup>5–11</sup> The first series of SPT managed using laparoscopy was recently published by Cavallini et al.<sup>12</sup> but included a heterogeneous population of both adult and child, male and female patients. Based on a review of the medical literature, it has been demonstrated that SPTs in male patients have distinct patterns of onset and aggressiveness versus those in female patients and that SPTs in adults and children also differ with regard to clinical features.<sup>13,14</sup> The present study is the first to focus solely on adult female patients, the typical population that is affected by SPT. We find that laparoscopic DP is particularly suitable for our patients given their relatively young age. First, from an esthetic point of view the laparoscopic approach avoids abdominal incision with the exception of the Pfannenstiel incision. Second, it has

been documented that laparoscopy decreases the risk of long-term incisional hernia and postoperative adhesions associated with the open procedure.<sup>24,25</sup> This benefit disappears when patients require a laparotomy in the postoperative period due to complications from the initial procedure (as demonstrated by 2 of the 5 patients in our series). Some authors have also reported that laparoscopy decreases postoperative stress, analgesia requirements, and shortens hospital duration.<sup>26</sup> In our series, the median hospital length of stay was comparable to the series of open DP for SPT published in the medical literature (**Table 2**)<sup>27–34</sup> and also to open DP performed at our institution. However, 3 of our patients had complications delaying hospital discharge. Correcting for these complications, the hospital length of stay was only 7 d.

From an oncological point of view, the low-grade malignancy of SPT generally results in an excellent prognosis following complete surgical resection. Although SPTs may have malignant characteristics, they are generally not characteristic. Specifically, extrapancreatic or vascular invasion by the tumor, cellular pleomorphism, and elevated mitotic rates do not seem to have a significant impact on the oncologic behavior of SPTs. The analysis of multiple series of SPT operated on via open resection, including all type of pancreatic resections, demonstrates excellent outcomes, even in the presence of recurrent disease (**Table 2**).<sup>27–34</sup> In our group, all the patients were alive and free of recurrence or metastasis at a median follow-up of 60 mo. These results correspond theoretically to a 100% overall and disease-free survival at 1 y and 5 y. Thus, our oncologic results are comparable to those in the series of open resection. This demonstrates that laparoscopic resection of SPT does not impact oncologic outcomes. Furthermore, no lymph node metastases and no perineural invasions were found on histological analysis of the specimens in our series. This demonstrates that SPT rarely has lymph node metastases. Consequently, extensive lymphadenectomy is not necessary and makes laparoscopy even more appropriate.

Three complications occurred after the laparoscopic procedure. This overall morbidity rate (60%) is relatively high in comparison with open DP for pancreatic SPT as presented in **Table 2**,<sup>27–34</sup> but only 2 patients (40%) had serious complications requiring a relaparotomy (DINDO IV). One complication in our series was minor (pancreatic fistulas grade A). Such a result is not surprising, because SPT patients present with classic risk factors for postoperative pancreatic fistula including small duct size and soft gland texture. The 2 serious complications included 1

**Table 2.**  
Series of Open Surgery for Solid Pseudopapillary Tumor

Author	Year	N	Age (Median Years)	M/F <sup>a</sup>	LHS <sup>a</sup> (Median Days)	Morbidity (%)	Follow-up (Median)	Oncologic Outcome
Tipton <sup>27</sup>	2002	14	—	1/13	—	31	87 months	2 dead (14%); 3 recurrences (21%)
Ng <sup>22</sup>	2003	6	30	1/5	—	—	3.8 years	No death; No recurrence
Chen <sup>28</sup>	2005	21	27.3	0/21	—	—	36 months	No death; No recurrence
De Castro <sup>29</sup>	2007	12	21	0/12	9	1	3.8 years	No death; No recurrence
Goh <sup>21</sup>	2007	16	30		8	31	43 months	No death; No recurrence
Salvia <sup>30</sup>	2007	31	34	4/27	16.7	35	58.2 months	No death; No recurrence
Yang <sup>31</sup>	2008	26		4/22	17	26.9	32.5 months	No recurrence; 1 dead
Machado <sup>13</sup>	2008	34		6/27	11	62	84 months	2 recurrences; 1 death
Nakagohri <sup>32</sup>	2008	14	39	1/13	—	43	46 months	No death; No recurrence
Reddy <sup>33</sup>	2008	37	32	4/33	—	52	4.8 years	1 recurrence; 2 deaths
Matos <sup>34</sup>	2009	21	34	0/21	—	52	55 months	No death; No recurrence

<sup>a</sup>M/F=sex ratio male/female; LHS=Length of hospital stay.

splenic infarction and 1 hemorrhage of the inferior pancreatic artery. The splenic ischemia resulted from the division of the splenic vessels but not of the laparoscopic approach per se. The hemorrhage may be attributed to the use of a laparoscopic stapler resulting in inadequate hemostasis at the pancreatic incision site. Thus, the rate of relaparotomies decreased over time as the surgeons gained experience with the laparoscopic procedure. By 2011, it was only 5.6% in our institution. However given these issues, we recommend these laparoscopic approaches in specialized centers given their acknowledged expertise in handling these complications.

The comparison between the pre- and postoperative SF 36 score results did not reveal any significant differences based on the laparoscopic procedure used. It would have been particularly interesting to compare quality of life between our patients operated on with laparoscopy and other patients operated on with open laparotomy, but quality of life was not assessed in medical articles of open DP. Nonetheless, our results confirm that the quality of life of our patients was not significantly impacted by the laparoscopic DP.

## CONCLUSION

We conclude that laparoscopic DP offers an alternative to open surgery in the treatment of SPT of the distal pancreas in adult female patients without significantly impacting either the oncologic outcome or the quality of life of the patients.

## References:

1. Gagner M, Pomp A. Laparoscopic pylorus-preserving pancreatoduodenectomy. *Surg Endosc*. 1994;8:408–410.
2. Cuschieri A, Jakimowicz JJ, van Spreeuwel J. Laparoscopic distal 70% pancreatectomy and splenectomy for chronic pancreatitis. *Ann Surg*. 1996;223:280–285.
3. Mao C, Guvendi M, Domenico DR, Kim K, Thomford NR, Howard JM. Papillary cystic and solid tumors of the pancreas: a pancreatic embryonic tumor? Studies of three cases and cumulative review of the world's literature. *Surgery*. 1995;118:821–828.
4. Carricaburu E, Enezian G, Bonnard A, et al. Laparoscopic distal pancreatectomy for Frantz's tumor in a child. *Surg Endosc*. 2003;17(12):2028–2031.
5. Melotti G, Cavallini A, Butturini G, et al. Laparoscopic distal pancreatectomy in children: case report and review of the literature. *Ann Surg Oncol*. 2007;14(3):1065–1069.
6. Kang CM, Kim HG, Kim KS, Choi JS, Lee WJ, Kim BR. Laparoscopic distal pancreatectomy for solid pseudopapillary neoplasm of the pancreas - report of two cases. *Hepatogastroenterology*. 2007;54(76):1053–1056.
7. Uchida H, Goto C, Kishimoto H, et al. Laparoscopic spleen-preserving distal pancreatectomy for solid pseudopapillary tumor with conservation of splenic vessels in a child. *J Pediatr Surg*. 2010;45(7):1525–1529.
8. Sokolov YY, Stonogin SV, Donskoy DV, Povarnin OY, Vilesov AV. Laparoscopic pancreatic resections for solid pseudopapillary tumor in children. *Eur J Pediatr Surg*. 2009;19(6):399–401.

9. Kang CM, Yang WI, Lee YH, et al. A case of spleen-preserving laparoscopic distal pancreatectomy and concomitant cholecystectomy in male patient with solid pseudopapillary neoplasm of the pancreas and gallstone. *J Laparoendosc Adv Surg Tech A*. 2008;18(2):259–265.
10. Sasaki A, Nitta H, Nakajima J, et al. Laparoscopic spleen-preserving distal pancreatectomy with conservation of the splenic artery and vein: report of three cases. *Surg Today*. 2008;38:955–958.
11. Ntourakis D, Marzano E, De Blasi V, et al. Robotic left pancreatectomy for pancreatic solid pseudopapillary tumor. *Ann Surg Oncol*. 2011;18(3):642–643.
12. Cavallini A, Butturini G, Daskalaki D, et al. Laparoscopic pancreatectomy for solid pseudo-papillary tumors of the pancreas is a suitable technique: our experience with long-term follow-up and review of the literature. *Ann Surg Oncol*. 2011;18(2):352–357.
13. Machado MC, Machado MA, Bacchella T, et al. Solid pseudopapillary neoplasm of the pancreas: distinct patterns of onset, diagnosis, and prognosis for male versus female patients. *Surgery*. 2008;143:29–34.
14. Lee SE, Jang JY, Hwang DW, et al. Clinical features and outcome of solid pseudopapillary neoplasm: differences between adults and children. *Arch Surg*. 2008;143(12):1218–1221.
15. Dindo D, Demartines N, Clavien PA. Classification of surgical complications. A new proposal with evaluation in a cohort of 6336 patients and results of a survey. *Ann Surg*. 2004;240:205–212.
16. Bassi C, Dervenis C, Butturini G, et al. Postoperative pancreatic fistula: an international study group (ISGPF) definition. *Surgery*. 2005;138:8–13.
17. Ware JE Jr., Sherbourne CD. The MOS 36-item short-form health survey (SF-36). I. Conceptual framework and item selection. *Med Care*. 1992;30(6):473–83.
18. Warshaw AL. Conservation of the spleen with distal pancreatectomy. *Arch Surg*. 1988;123(5):550–553.
19. Frantz V. Tumours of the pancreas. Washington, DC: Armed Forces Institute of Pathology, 1959.
20. Kloppel G SE, Longnecker DS, Capella C, et al. Histological typing of tumours of the exocrine pancreas. World Health Organization International Histological Classification of Tumours. Berlin: Springer-Verlag, 1996.
21. Goh BK, Tan YM, Cheow PC, et al. Solid pseudopapillary neoplasms of the pancreas: an updated experience. *J Surg Oncol*. 2007;95:640–644.
22. Ng KH, Tan PH, Thng CH, et al. Solid pseudopapillary tumour of the pancreas. *ANZ J Surg*. 2003;73:410–415.
23. Hamoudi AB, Misugi K, Grosfeld JL, et al. Papillary epithelial neoplasm of pancreas in a child. Report of a case with electron microscopy. *Cancer*. 1970;26:1126–1131.
24. Andersen LP, Klein M, Gögenur I, et al. Incisional hernia after open versus laparoscopic sigmoid resection. *Surg Endosc*. 2008;22(9):2026–2029.
25. Trastulli S, Ciocchi R, Listori C, et al. Laparoscopic vs open resection for rectal cancer: a meta-analysis of randomized clinical trials. *Colorectal Dis*. 2012;14(6):277–296.
26. DiNorcia J, Schrope BA, Lee MK, et al. Laparoscopic distal pancreatectomy offers shorter hospital stays with fewer complications. *J Gastrointest Surg*. 2010;14(11):1804–1812.
27. Tipton SG, Smyrk TC, Sarr MG, et al. Malignant potential of solid pseudopapillary neoplasm of the pancreas. *Br J Surg*. 2006;93:733.
28. Chen X, Zhou GW, Zhou HJ, Peng CH, Li HW. Diagnosis and treatment of solid-pseudopapillary tumors of the pancreas. *Hepatobiliary Pancreat Dis Int*. 2005;4(3):456–459.
29. De Castro SM, Singhal D, Aronson DC, et al. Management of solid-pseudopapillary neoplasms of the pancreas: a comparison with standard pancreatic neoplasms. *World J Surg*. 2007 May; 31(5):1130–1135.
30. Salvia R, Bassi C, Festa L, et al. Clinical and biological behavior of pancreatic solid pseudopapillary tumors: report on 31 consecutive patients. *J Surg Oncol*. 2007;95:304–310.
31. Yang F, Jin C, Long J, et al. Solid pseudopapillary tumor of the pancreas: a case series of 26 consecutive patients. *Am J Surg*. 2009;198:210–215.
32. Nakagohri T, Kinoshita T, Konishi M, et al. Surgical outcome of solid pseudopapillary tumor of the pancreas. *J Hepatobiliary Pancreat Surg*. 2008;15:318–321.
33. Reddy S, Cameron JL, Scudiere J, et al. Surgical management of solid-pseudopapillary neoplasms of the pancreas (Franz or Hamoudi tumors): a large single-institutional series. *J Am Coll Surg*. 2009 May;208(5):950–957.
34. Matos JM, Grützmann R, Agaram NP, et al. Solid pseudopapillary neoplasms of the pancreas: a multi-institutional study of 21 patients. *J Surg Res*. 2009 Nov;157(1):e137–e142.