

Acute Benefits After Liposomal Bupivacaine Abdominal Wall Blockade for Living Liver Donation: A Retrospective Review

Adam W. Amundson, MD; David A. Olsen, MD; Hugh M. Smith, MD, PhD; Laurence C. Torsher, MD; David P. Martin, MD, PhD; Julie K. Heimbach, MD; and James Y. Findlay, MB, ChB

Abstract

Objective: To investigate whether the addition of liposomal bupivacaine abdominal wall blocks to a multimodal analgesic regimen improves postoperative numeric rating scale pain scores and reduces opioid consumption in patients undergoing living liver donation.

Patients and Methods: We conducted a single-center, retrospective review of patients who underwent living liver donation from January 1, 2011, through February 19, 2016, and received multimodal analgesia with (block group) or without (control group) abdominal wall blockade. The block solution consisted of liposomal bupivacaine (266 mg) mixed with 30 mL of 0.25% bupivacaine. Both groups received intrathecal hydromorphone. Main outcome measures were pain scores, opioid requirements, time to full diet, and bowel activity.

Results: Postoperative day 0 pain scores were significantly better in the block group (n=29) than in the control group (n=48) (2.4 vs 3.5; $P=.002$) but were not significantly different on subsequent days. Opioid requirements were significantly decreased for the block group in the postanesthesia care unit (0 vs 9 mg oral morphine equivalents; $P=.002$) and on postoperative day 0 (7 vs 18 mg oral morphine equivalents; $P=.004$). Median (interquartile range) time to full diet was 23 hours (14-30 hours) in the block group and 38 hours (24-53 hours) in the control group ($P=.001$); time to bowel activity was also shorter in the block group (45 hours [38-73 hours] vs 67 hours [51-77 hours]; $P=.01$).

Conclusion: Abdominal wall blockade with liposomal bupivacaine after donor hepatectomy provides an effective method of postoperative pain control and decreases time to full diet and bowel activity.

© 2018 THE AUTHORS. Published by Elsevier Inc on behalf of Mayo Foundation for Medical Education and Research. This is an open access article under the CC BY-NC-ND license (<http://creativecommons.org/licenses/by-nc-nd/4.0/>) ■ *Mayo Clin Proc Inn Qual Out* 2018;2(2):186-193

From the Department of Anesthesiology and Perioperative Medicine (A.W.A., D.A.O., H.M.S., L.C.T., D.P.M., J.Y.F.) and Division of Transplantation Surgery (J.K.H.), Mayo Clinic, Rochester, MN.

The critical shortage of deceased donor liver allografts and the increased morbidity and mortality that patients experience while awaiting transplant have led to the use of living donor liver transplant.^{1,2} Because donor hepatectomy involves major upper abdominal surgery in healthy donors, analgesia is important for mitigating postoperative morbidity and is a primary concern for patients considering living donation.³ Although epidural analgesia has historically been the standard of postoperative pain control, recent studies have found that postoperative coagulopathy may put patients at risk for neuraxial hematoma.^{1,4} Accordingly, alternative analgesic methods that avoid this risk

have been used in the search for safe but effective pain management.^{4,5}

Abdominal wall blockade involves depositing local anesthetic into the fascial plane superficial to the transversus abdominis muscle to anesthetize the distal branches of the anterior rami of the lower thoracic and upper lumbar nerve roots.⁶ Although single-injection transversus abdominis plane (TAP) blocks can provide excellent analgesia for major abdominal surgery, their primary shortcomings include limitations in dermatomal spread and short duration, with comprehensive analgesia rarely extending beyond 12 hours.^{6,7} To extend analgesia duration, some investigators have placed TAP catheters to facilitate infusion

of local anesthetic.^{4,5} To date, however, this technique has been limited by high failure rates of secondary analgesia.⁸

The novel, long-acting, encapsulated local anesthetic liposomal bupivacaine has been reported to produce detectable serum bupivacaine concentrations for up to 96 hours.⁹ Therefore, liposomal bupivacaine may extend the analgesia of abdominal wall blockade and improve postoperative pain control for living liver donation patients. Recently, Mayo Clinic added a multi-injection abdominal wall technique (specifically, lateral TAP and multi-injection subcostal TAP) with a liposomal bupivacaine mixture to our practice. This regional approach targets broader dermatomal innervation of the abdominal wall and may improve both coverage and duration of blockade.

We hypothesized that abdominal wall blockade for living liver donation patients would improve postoperative pain scores and reduce opioid consumption.

PATIENTS AND METHODS

After receiving Mayo Clinic Institutional Review Board approval, we searched the institutional liver transplant database to identify all patients undergoing living liver donation at Mayo Clinic, Rochester, Minnesota, from January 1, 2011, through February 19, 2016. Living donor hepatectomy patients aged 18 to 60 years were included. Exclusion criteria were chronic pain syndromes (fibromyalgia, complex regional pain syndromes) and chronic opioid use (daily opioid consumption of >15 mg/d oral morphine equivalents [OME] for more than 1 month before liver donation).

American Society of Anesthesiologists (ASA) status, body mass index (calculated as the weight in kilograms divided by the height in meters squared), sex, and age were recorded for all patients. Patients were then screened for eligibility into 2 groups based on anesthetic intervention: use of abdominal wall blocks (block group) or no use of abdominal wall blocks (control group). The primary outcome measure was postoperative numeric rating scale (NRS) pain scores (0 = no pain to 10 = worst pain) on postoperative days (PODs) 0 and 1. Secondary outcomes included NRS pain scores in the postanesthesia care unit (PACU) and on

PODs 2, 3, and 4; opioid consumption in the PACU and on PODs 0, 1, 2, 3, and 4; treatment for nausea and vomiting on PODs 0, 1, 2, 3, and 4; time to ingestion of clear fluids and a full diet; time to bowel activity; and hospital length of stay. Data were extracted from the electronic medical record using institutional perioperative database software by electronic query and via manual retrieval from the electronic medical and anesthesia records.

Multimodal Analgesia and Perioperative Protocol

Mayo Clinic's multimodal analgesic clinical pathway for living liver donation consists of preoperative oral medications, perioperative systemic opioids and nonopioid medicines, and a preoperative intrathecal opioid. On arrival at the preoperative area, the patient is administered 800 mg of oral gabapentin. The patient is then transferred to the operating room suite, where a hydromorphone (100-150 μ g) spinal is aseptically administered using primarily a 25-gauge Whitacre needle. General anesthesia is maintained with volatile anesthesia, intravenous (IV) opioids (fentanyl, <500 μ g), nonopioid adjuvants (ketorolac, 15 mg IV, +/- ketamine, 10 mg IV), and aggressive antiemetic prophylaxis (granisetron, 0.1 mg IV, or ondansetron, 4 mg IV, +/- scopolamine transdermal patch, 1.5 mg, applied for 24-72 hours +/- droperidol, 0.625 mg IV).

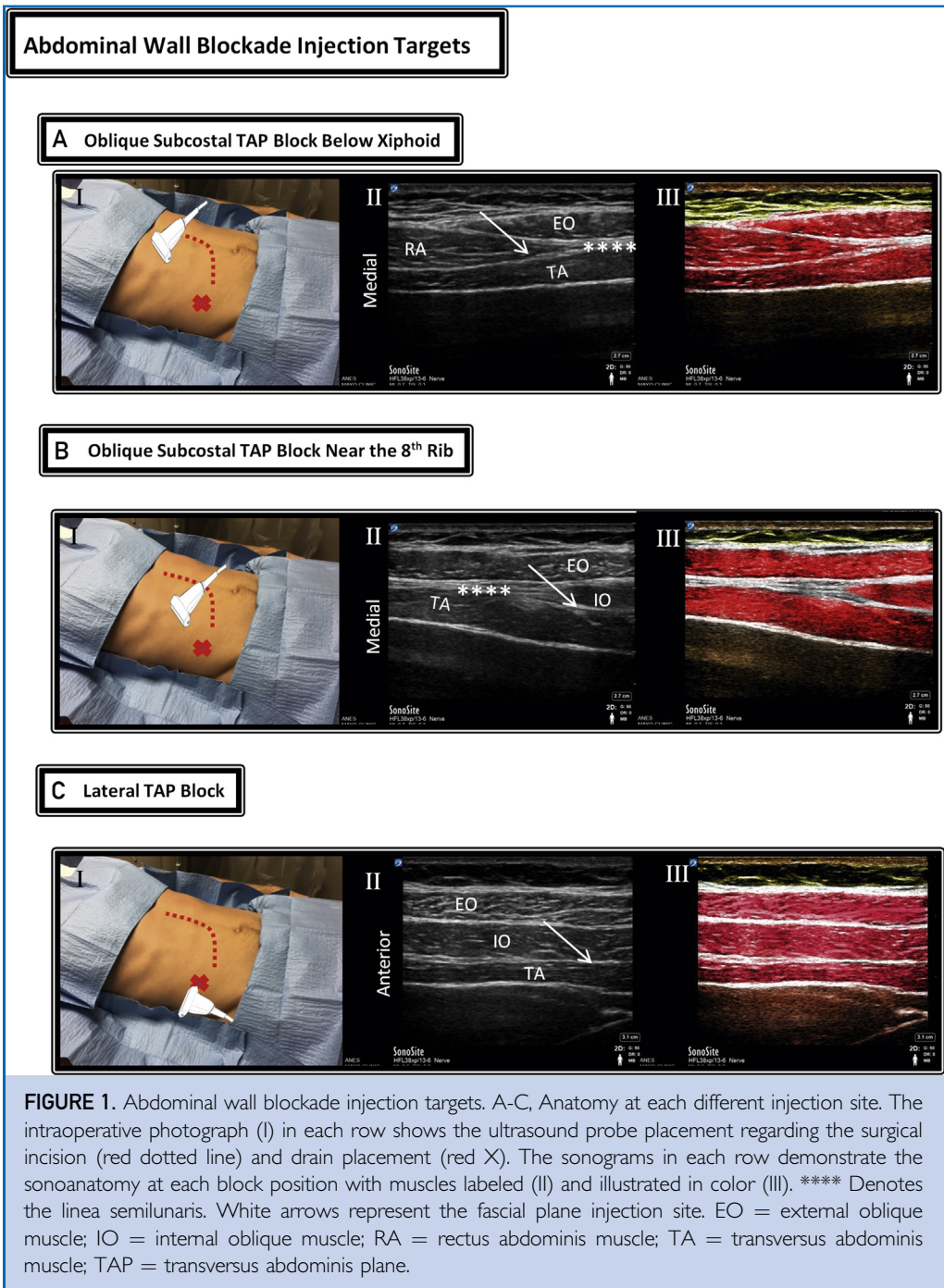
The regional anesthesia technique, when performed, was after wound closure. All the patients were extubated and transported to the PACU, where they were assessed for postoperative pain control and anesthetic recovery. On PACU departure they are transferred to the intensive care unit and monitored for 24 hours.

Surgical Technique

The surgical incision for living liver donation involves a primary right subcostal incision with a midline extension to the xiphoid. All the patients underwent a right or left hepatectomy with incidental cholecystectomy.

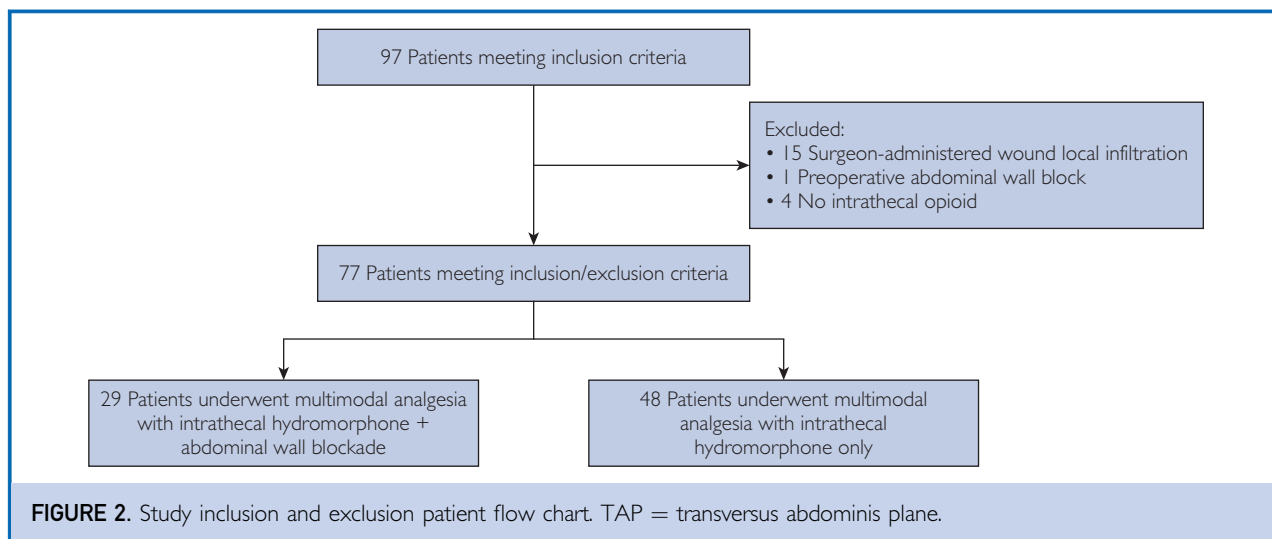
Abdominal Wall Injection Technique

All ultrasound-guided abdominal wall blocks were placed under general anesthesia at the end of surgery, with patients in a supine position and with the sterile field intact. The block solution consisted of 20 mL (266 mg) of



liposomal bupivacaine mixed with 30 mL of 0.25% (75 mg) plain bupivacaine to a total of 50 mL. A linear HFL38 13-6 MHz ultrasound transducer (M-Turbo or X-Porte; SonoSite Inc) and a 21-gauge 4-inch Stimuplex needle (B. Braun Medical Inc) or a 20-gauge 4-inch Ultrplex 360° nonstimulating echogenic

needle (B. Braun Medical Inc) were used in the blocks. The technique consisted of 5 distinct injections (10 mL at each site): bilateral oblique subcostal TAP blocks just below the xiphoid (one between the rectus muscle and the transversus abdominis muscle) (Figure 1, A), bilateral subcostal TAP blocks near the 8th



rib (between the internal oblique and transversus abdominis muscles) (Figure 1, B), and a lateral TAP block on the right side (Figure 1, C).

Statistical Analyses

Data are reported using median (interquartile range [IQR]) for continuous variables and frequency (percentage) for categorical variables. Daily pain scores were averaged for each patient across all available NRS pain scores in each period and are reported as the median (IQR) average pain score for the groups. Opioid use was converted to OME using standard institutional tables and is reported as median (IQR). Timing of diet, elimination, and hospital length of stay are similarly reported as median (IQR). Data were compared between groups using a rank sum test for continuous variables and a 2-tailed Fisher exact test for categorical variables. Two-sided tests were performed, with $P < .05$ denoting statistical significance. Data analyses were performed using both JMP Pro version 10.0.0 (SAS Institute Inc) and Stata version 9.3 (StataCorp LLC).

RESULTS

During the study period, 97 persons were living liver donors and met the inclusion criteria (Figure 2). Of those patients, 1 was excluded because the TAP block was placed preoperatively, 4 were excluded because they did not receive an intrathecal opioid, and 15 were excluded because of surgeon-administered abdominal wound infiltration with local

anesthetic under direct visualization. A total of 77 patients were analyzed, with 29 in the block group and 48 in the control group. The median age of participants was within 2 years, and body mass index was within 1 kg/m² between the groups (Table 1). The block group had a slightly higher percentage of ASA I patients (79% vs 69% in the control group); given the rigorous

TABLE 1. Patient and Procedural Characteristics^a

Characteristic	Control group (n=48)	Abdominal wall block group (n=29)	P value ^b
Age (y), median (IQR)	37 (28-49)	35 (29-49)	.60
Sex (No. [%])			
Male	25 (52)	16 (55)	.64
Female	23 (48)	13 (45)	
Body mass index (kg/m ²), median (IQR)	26 (24-28)	25 (23-27)	.15
ASA status (No. [%])			
I	33 (69)	23 (79)	.43
II	15 (31)	6 (21)	
Hepatectomy site (No. [%])			
Right	40 (83)	24 (83)	>.99
Left	8 (17)	5 (17)	
Duration of surgery (min), median (IQR)	193 (172-217)	187 (170-213)	.65
Duration of anesthesia (min), median (IQR)	282 (260-307)	303 (279-322)	.07
Intraoperative OME (mg), median (IQR)	25 (10-30)	18 (13-30)	.95

^aASA = American Society of Anesthesiologists; IQR = interquartile range; OME = oral morphine equivalents.

^bContinuous variables use the rank sum test for comparison. Categorical variables use the 2-tailed Fisher exact test for comparison.

TABLE 2. Pain Scores

Postoperative day	Numeric rating scale score ^a		P value
	Control group (n=48)	Abdominal wall block group (n=29)	
0	3.5 (2.4-4.9)	2.4 (0.8-3.3)	.002 ^b
1	3.6 (3.0-4.9)	3.4 (2.4-4.6)	.41
2	3.8 (2.8-5.3)	4.5 (3.2-5.1)	.18
3	3.7 (2.9-5.0)	4.4 (3.2-4.9)	.31
4 ^c	3.8 (3.0-5.3)	3.2 (2.7-5.2)	.41

^aData are presented as median (interquartile range). The rank sum test was used for comparison.
^bStatistically significant.
^cData were missing for 3 patients (1 control and 2 abdominal wall blocks) on postoperative day 4.

selection criteria for liver donation, there were no ASA III patients in either group. There were no differences between groups in the median (IQR) duration of surgery (block group: 187 minutes [170-213 minutes]; control group: 193 minutes [172-217 minutes]) or anesthetic time (block group: 303 minutes [279-322 minutes]; control group: 282 minutes [260-307 minutes]). Similar percentages of patients underwent left or right hepatectomy in each group. No demographic data were statistically significantly different between the groups (Table 1).

Pain Scores and Opioid Consumption

Median (IQR) average pain scores on POD 0 were significantly better in the block group vs the control group (2.4 [0.8-3.3] vs 3.5 [2.4-4.9]; $P=.002$), but differences between the groups did not reach statistical significance on subsequent days (Table 2). Furthermore, median (IQR) opioid requirements in the PACU were significantly lower for the block group vs

the control group (0 mg OME [0-10 mg OME] vs 9 mg OME [1-25 mg OME]; $P=.002$) and also on POD 0 (7 mg OME [0-15 mg OME] vs 18 mg OME [5-36 mg OME]; $P=.004$), but no difference was seen on subsequent days (Table 3).

Diet, Bowel Recovery, and Other Secondary Outcomes

Median (IQR) time to full diet was significantly shorter in the block group vs the control group (23 hours [14-30 hours] vs 38 hours [24-53 hours]; $P=.001$) (Table 4). Median (IQR) time to first bowel movement or flatus was also significantly decreased (45 hours [38-73 hours] vs 67 hours [51-77 hours]; $P=.01$). Median (IQR) hospital length of stay was not significantly different between the groups (block group: 5.8 days [5.4-6.4 days]; control group: 6.4 days [5.4-7.4 days]; $P=.08$). No differences were detected in the incidence of postoperative nausea or vomiting requiring treatment between the groups

TABLE 3. Opioid Use^{a,b}

Pain assessment time	Opioid use (mg OME)		P value
	Control group (n=48)	Abdominal wall block group (n=29)	
PACU	9 (1-25)	0 (0-10)	.002 ^c
POD 0	18 (5-36)	7 (0-15)	.004 ^c
POD 1	45 (29-75)	50 (11-78)	.46
POD 2	38 (11-67)	30 (4-55)	.44
POD 3	23 (8-53)	15 (0-53)	.22
POD 4	15 (0-45)	4 (0-26)	.26
PODs 0-4	172 (86-289)	120 (41-241)	.06

^aOME = oral morphine equivalents; PACU = postanesthesia care unit; POD = postoperative day.
^bData are presented as median (interquartile range). The rank sum test was used for comparison.
^cStatistically significant.

during all periods. No patients required pain consultations.

Two patients in the control group returned to the operating room within 30 days, one for retrieval of a broken abdominal drain on POD 9 and one for evacuation of a hematoma and to achieve hemostasis on POD 1. Two patients were readmitted within 30 days (one for a bile leak and one for a surgical site infection), both from the control group. Two patients required endoscopy with stent placement for bile leak, one from each group. No complications associated with abdominal wall blockade or intrathecal injection were noted.

DISCUSSION

This study reports improved initial postoperative analgesia using multi-injection liposomal bupivacaine abdominal wall blocks in conjunction with the established multimodal analgesic regimen for living liver donation. Furthermore, the addition of abdominal wall blocks in this group showed improved time to solid food intake and bowel activity, both indicators of enhanced recovery and improved patient satisfaction and outcomes.¹⁰

Providing optimal and safe postoperative pain control for living hepatic donors is desirable for several reasons.¹¹ First, according to the American Transplant Foundation,¹² postoperative pain is a primary concern in persons considering liver donation. Second, the current demand for liver transplants is much greater than the available organ supply; thus, provision of safe and comfortable perioperative experiences influences living donor availability.¹³ Finally, postoperative pain has been found to be a major cause of perioperative morbidity and mortality and is, thus, of special consideration in otherwise healthy donor patients.¹⁴

With that in mind, every pain management technique for major abdominal surgery has its own set of risks and benefits. Although epidural placement provides excellent pain control for living liver donation, several studies have reported that postoperative coagulopathy places patients at risk for epidural hematoma. One study found that prothrombin times increased by 50% on POD 1, and another study found that one-third of patients had an international normalized ratio of 1.5 or higher over the same postoperative period during which

TABLE 4. Secondary Outcomes: Diet and Elimination, PONV, and PACU and Hospital LOS^a

Outcome	Control group (n=48)	Abdominal wall block group (n=29)	P value ^b
Diet and elimination, median (IQR) ^c			
Time to clear fluids (h) ^d	4.8 (2.9-12.6)	2.8 (1.7-7.1)	.05
Time to solids (h)	38 (24-53)	23 (14-30)	.001 ^e
Time to first BM (h)	67 (51-77)	45 (38-73)	.01 ^e
LOS, median (IQR)			
PACU (min)	101 (75-120)	87 (67-108)	.05
Hospital (d)	6.4 (5.4-7.4)	5.8 (5.4-6.4)	.08
PONV requiring treatment (No. [%])			
In PACU	3 (6.3)	2 (6.9)	>.99
POD 0, after PACU	29 (60.4)	13 (44.8)	.24
POD 1	23 (47.9)	10 (34.5)	.34
POD 2	25 (52.1)	15 (51.7)	>.99
POD 3	23 (47.9)	16 (55.2)	.64
POD 4	16 (33.3)	11 (37.9)	.81

^aBM = bowel movement or flatus; IQR = interquartile range; LOS = length of stay; PACU = postanesthesia care unit; POD = postoperative day; PONV = postoperative nausea or vomiting.

^bComparison is rank sum for continuous variables and 2-tailed Fisher exact test for categorical variables.

^cTime since the end of surgery.

^dData were missing for 4 patients (2 control and 2 abdominal wall block) in time to clear fluids.

^eStatistically significant.

epidural analgesia is typically required.^{1,15} Despite recent literature contradicting this concern by reporting a prothrombic state via thromboelastometry after major hepatic resection, many anesthesia providers are still reluctant to place an epidural catheter.¹⁶

Individual abdominal wall blocks (lateral TAP, subcostal TAP, or rectus sheath blocks) have each been associated with improved pain control in isolation; however, their limited duration, visceral pain sparing, and inconsistent dermatomal coverage has led to inferior analgesia compared with an epidural technique.¹⁷ For example, a lateral TAP block consistently provides coverage to the T10-T12 dermatomes but inconsistently anesthetizes the T9 and L1 dermatomal regions.⁶ Støving et al¹⁷ performed sensory mapping after a lateral TAP block in healthy volunteers and found a highly variable pattern of dermatomal blockade. Furthermore, single-injection subcostal TAP blocks have been found to consistently block T7-T9 dermatomes and inconsistently block T6 and T10.⁴ Rozen et al¹⁸ also reported that a rectus sheath block, performed at the lateral edge, missed 11% of the terminal anterior cutaneous branches. On the basis of these investigations,

a multi-injection technique to provide more consistent incisional blockade from T6 to T12 was adapted into clinical practice to overlap local anesthetic spread in the TAP.¹⁹

Although the pharmaceutical manufacturer's published data regarding liposomal bupivacaine indicates detectable serum levels 96 hours after administration,⁹ head-to-head trials examining the duration of analgesia in liposomal and free bupivacaine have had conflicting results.^{20,21} The limited analgesic clinical benefit observed in the present study, although still potentially longer than published results for abdominal wall blockade with plain bupivacaine, remains considerably shorter than advertised data. However, it is possible that a dilution effect, in combining 75 mg of plain bupivacaine (added to improve onset time of block) with 266 mg of liposomal bupivacaine, also contributed to the shorter clinical effect of the regional technique. Furthermore, there has been hesitation among some organizations to adapt the routine use of liposomal bupivacaine for postoperative pain control given the added cost of this product over plain bupivacaine without concrete data showing a clear advantage.

This retrospective study has several strengths. The surgical procedure was performed at a large academic liver transplant center with consistent and uniform surgical techniques among surgeons. Furthermore, the surgical and anesthesia teams have worked collaboratively during the past 20 years to standardize the analgesic pathway for liver donation patients. This is also an ideal study population because of the homogeneity of good health among patients secondary to rigorous donor screening and selection criteria. Abdominal wall blockade is also easy to learn and perform using ultrasound guidance. Compared with catheter placement, it allows for less medical intervention, avoids dislodgement, and decreases the workload of placement and catheter management. The abdominal wall blocks also do not significantly extend the total length of the surgical procedure (Table 1) because they are placed after the incision is closed in the operating room and during patient emergence from anesthesia. Although only a few centers perform living liver donation, the application of this block technique could be easily

transferred and applied to other major abdominal surgeries.

The main limitation of this study is the nonrandomized retrospective design, which lacks blinding to patients and providers. Statistically significant outcomes could also have been the result of a bias associated with implementation of a new technique into a surgical practice or changes in downstream care. The small sample size also means insufficient power to interpret data where no significant differences were detected (ie, hospital length of stay); therefore, the data presented are hypothesis generating and should be replicated with a large randomized controlled trial. Furthermore, near the end of the study period, the surgical incision technique changed slightly for 5 patients, who received a laparoscopic-assisted hepatectomy. These patients had an approximately 12-cm midline incision, a supraumbilical 10-mm trocar, and two 5-mm trocars in the right side of the abdomen. Despite the change, subset analysis excluding these 5 patients still found a significant difference in median (IQR) pain scores on POD 0 (block group: 2.5 [1-3.6]; control group: 3.5 [2.4-4.9]; $P=.009$) and in median (IQR) total OME consumption in the PACU (block group: 0 mg OME [0-14 mg OME]; control group: 8 mg OME [1-25 mg OME]; $P=.009$) and on POD 0 (block group: 7 mg OME [0-15 mg OME]; control group: 18 mg OME [5-36 mg OME]; $P=.01$).

CONCLUSION

In summary, the addition of a multi-injection abdominal wall blockade to a comprehensive multimodal clinical pathway for living liver donation improves postoperative pain control and decreases time to full diet and bowel activity. Prospective, blinded, randomized clinical trials evaluating abdominal wall blockade with liposomal bupivacaine compared with free bupivacaine are needed to determine the utility of encapsulated bupivacaine with abdominal wall blocks.

ACKNOWLEDGMENTS

We thank Darrell R. Schroeder, MS, statistician, and Alberto Marquez, RRT, Anesthesia Clinical

Research Unit data acquisition expert, for their help with data extraction and analysis.

Abbreviations and Acronyms: **ASA** = American Society of Anesthesiologists; **IQR** = interquartile range; **IV** = intravenous; **NRS** = numeric rating scale; **OME** = oral morphine equivalents; **PACU** = postanesthesia care unit; **POD** = postoperative day; **TAP** = transversus abdominis plane

Grant Support: This research was funded by Mayo Foundation for Medical Education and Research and did not receive any specific grants from funding agencies in the public, commercial, or not-for-profit sectors.

Potential Competing Interests: The authors report no competing interests.

Correspondence: Address to Adam W. Amundson, MD, Department of Anesthesiology and Perioperative Medicine, Mayo Clinic, 200 First St SW, Rochester, MN 55905 (Amundson.Adam@mayo.edu).

REFERENCES

1. Siniscalchi A, Begliomini B, De Pietri L, et al. Increased prothrombin time and platelet counts in living donor right hepatectomy: implications for epidural anesthesia. *Liver Transpl*. 2004;10(9):1144-1149.
2. Bachir NM, Larson AM. Adult liver transplantation in the United States. *Am J Med Sci*. 2012;343(6):462-469.
3. Hwang GS, McCluskey SA. Anesthesia and outcome after partial hepatectomy for adult-to-adult donor transplantation. *Curr Opin Organ Transplant*. 2010;15(3):377-382.
4. Maeda A, Shibata SC, Wada H, et al. The efficacy of continuous subcostal transversus abdominis plane block for analgesia after living liver donation: a retrospective study [published correction appears in *J Anesth*. 2016;30(3):546]. *J Anesth*. 2016;30(1):39-46.
5. Khan J, Katz J, Montbriand J, et al. Surgically placed abdominal wall catheters on postoperative analgesia and outcomes after living liver donation. *Liver Transpl*. 2015;21(4):478-486.
6. Chin KJ, McDonnell JG, Carvalho B, Sharkey A, Pawa A, Gadsden J. Essentials of our current understanding: abdominal wall blocks. *Reg Anesth Pain Med*. 2017;42(2):133-183.
7. Bhattacharjee S, Ray M, Ghose T, Maitra S, Layek A. Analgesic efficacy of transversus abdominis plane block in providing effective perioperative analgesia in patients undergoing total abdominal hysterectomy: a randomized controlled trial. *J Anaesthesiol Clin Pharmacol*. 2014;30(3):391-396.
8. Niraj G, Kelkar A, Jeyapalan I, et al. Comparison of analgesic efficacy of subcostal transversus abdominis plane blocks with epidural analgesia following upper abdominal surgery. *Anaesthesia*. 2011;66(6):465-471.
9. Bramlett K, Onel E, Viscusi ER, Jones K. A randomized, double-blind, dose-ranging study comparing wound infiltration of DepoFoam bupivacaine, an extended-release liposomal bupivacaine, to bupivacaine HCl for postsurgical analgesia in total knee arthroplasty. *Knee*. 2012;19(5):530-536.
10. Jones C, Kelliher L, Dickinson M, et al. Randomized clinical trial on enhanced recovery versus standard care following open liver resection. *Br J Surg*. 2013;100(8):1015-1024.
11. Darwish Murad S, Fidler JL, Poterucha JJ, et al. Long-term clinical and radiological follow-up of living liver donors. *Liver Transpl*. 2016;22(7):934-942.
12. Barriers for approaching living donors. American Transplant Foundation website. <http://www.americantransplantfoundation.org/programs/mentorship-program-2/mentor/living-donor-connectors/barriers-for-approaching-living-donors/>. Published April 23, 2018.
13. Mandell MS, Smith AR, Dew MA, et al. Early postoperative pain and its predictors in the Adult to Adult Living Donor Liver Transplantation Cohort Study. *Transplantation*. 2016;100(11):2362-2371.
14. Popping DM, Elia N, Van Aken HK, et al. Impact of epidural analgesia on mortality and morbidity after surgery: systematic review and meta-analysis of randomized controlled trials. *Ann Surg*. 2014;259(6):1056-1067.
15. Hase T, Takita K, Hashimoto T, Morimoto Y. Coagulation profiles following donor hepatectomy and implications for the risk of epidural hematoma associated with epidural anesthesia [Japanese]. *Masui*. 2011;60(7):840-845.
16. Mallett SV, Sugavanam A, Krzanicki DA, et al. Alterations in coagulation following major liver resection. *Anaesthesia*. 2016;71(6):657-668.
17. Støving K, Rothe C, Rosenstock CV, Aasvang EK, Lundström LH, Lange KH. Cutaneous sensory block area, muscle-relaxing effect, and block duration of the transversus abdominis plane block: a randomized, blinded, and placebo-controlled study in healthy volunteers. *Reg Anesth Pain Med*. 2015;40(4):355-362.
18. Rozen WM, Ashton MW, Kiiil BJ, et al. Avoiding denervation of rectus abdominis in DIEP flap harvest II: an intraoperative assessment of the nerves to rectus. *Plast Reconstr Surg*. 2008;122(5):1321-1325.
19. Ladak A, Tubbs RS, Spinner RJ. Mapping sensory nerve communications between peripheral nerve territories. *Clin Anat*. 2014;27(5):681-690.
20. Amundson AW, Johnson RL, Abdel MP, et al. A three-arm randomized clinical trial comparing continuous femoral plus single-injection sciatic peripheral nerve blocks versus peritubular injection with ropivacaine or liposomal bupivacaine for patients undergoing total knee arthroplasty. *Anesthesiology*. 2017;126(6):1139-1150.
21. Schroer WC, Diesfeld PG, LeMarr AR, Morton DJ, Reedy ME. Does extended-release liposomal bupivacaine better control pain than bupivacaine after total knee arthroplasty (TKA)? a prospective, randomized clinical trial. *J Arthroplasty*. 2015;30(9 suppl):64-67.