

Severe infolding of fenestrated-branched endovascular stent graft

Aleem K. Mirza, MD, Giuliano A. Sandri, MD, Emanuel R. Tenorio, MD, PhD, Jussi M. Kärkkäinen, MD, PhD, and Gustavo S. Oderich, MD, Rochester, Minn

ABSTRACT

Infolding of a fenestrated-branched stent graft is an infrequent complication due to excessive oversizing. We report the case of an 89-year-old man who underwent a four-vessel fenestrated-branched endovascular aortic repair for a pararenal aortic aneurysm. Computed tomography angiography revealed severe infolding across the mesenteric-renal vessels. The patient was treated by angioplasty and placement of Palmaz stent. Cone-beam computed tomography confirmed patent visceral vessels with resolution of the infolding. This case illustrates an uncommon complication that can be prevented by modifications in the stent design and by immediate assessment using intraoperative cone-beam computed tomography. (*J Vasc Surg Cases and Innovative Techniques* 2018;4:240-3.)

Keywords: Infolding; Cone-beam computed tomography (CBCT); Fenestrated-branched endovascular stent graft

Endovascular repair of complex aortic aneurysms is increasing in frequency with wider application of fenestrated and branched stent graft technology.¹⁻³ For patients with juxtarenal or pararenal aortic aneurysms, stents are often designed with a supraceliac sealing zone using three or four fenestrations. The presence of a narrowing segment at the level of the renal arteries may result in excessive oversizing if the device is planned to the sealing zone at the level of the superior mesenteric artery (SMA) and celiac axis. Problems associated with excessive oversizing include difficult device rotation, lack of space to facilitate branch catheterization, and rarely infolding. This report illustrates a patient who had an unrecognized stent graft infolding at the time of initial stent graft implantation. The technique of endovascular treatment of fenestrated stent graft infolding is described. The patient was informed and consented to the writing of this report.

CASE REPORT

The patient is an 89-year-old man with an enlarging 6.1-cm pararenal abdominal aortic aneurysm with a penetrating aortic ulcer adjacent to the left renal artery. Computed tomography angiography revealed a suitable sealing zone of 27 mm in diameter at the level of the suprarenal aorta, with narrowing of the aortic diameter to 20 mm below the lowest renal artery. His cardiovascular risk factors included hypertension,

hyperlipidemia, coronary artery disease, and remote smoking history. The patient had a paternal family history of abdominal aortic aneurysm.

A fenestrated-branched stent graft was designed with a double scallop for the celiac axis and three fenestrations for the SMA and both main renal arteries. The stent graft sealing stents were sized to 32 mm, with stent graft taper to 22 mm starting below the level of the lowest fenestration. Using bilateral percutaneous femoral approach and a preloaded renal guidewire system, the fenestrated repair was deployed without complications. The SMA and both renal arteries were aligned using iCAST covered stents (Atrium Medical, Hudson, NH), which were flared to 10 mm. Completion angiography revealed widely patent celiac axis, SMA, and bilateral renal arteries with no evidence of endoleak. The patient recovered without complications and underwent routine predismittal computed tomography angiography (CTA) on postoperative day 1. CTA revealed severe infolding of the proximal aortic sealing stent, starting at the level of celiac axis scallop and extending distally across the SMA and renal fenestrations (Fig 1). The infolded stent graft had no apposition to the posterior aortic wall, resulting in a large type IA endoleak.

TECHNIQUE

The patient was treated for the stent graft infolding under general endotracheal anesthesia using bilateral percutaneous transfemoral approach in a hybrid endovascular operating room with cone-beam computed tomography (CBCT) capability. A 20F Gore DrySeal sheath (W. L. Gore & Associates, Flagstaff, Ariz) was advanced through the left femoral approach and a 14F Cook Check-Flo sheath (Cook Medical, Bloomington, Ind) through the right femoral approach. The SMA and bilateral renal arteries were selectively catheterized using separate 7F hydrophilic sheaths and Rosen guidewires (Cook Medical). Angioplasty balloons (10 mm × 2 cm) were positioned into each of the three fenestrations for kissing balloon inflation. First, a 49-mm × 10-cm Palmaz

From the Division of Vascular and Endovascular Surgery, Mayo Clinic.

Author conflict of interest: none.

Correspondence: Gustavo S. Oderich, MD, Gonda Vascular Center, Mayo Clinic, 200 First St SW, Rochester, MN 55902 (e-mail: oderich.gustavo@mayo.edu).

The editors and reviewers of this article have no relevant financial relationships to disclose per the Journal policy that requires reviewers to decline review of any manuscript for which they may have a conflict of interest.

2468-4287

© 2018 The Authors. Published by Elsevier Inc. on behalf of Society for Vascular Surgery. This is an open access article under the CC BY-NC-ND license (<http://creativecommons.org/licenses/by-nc-nd/4.0/>).

<https://doi.org/10.1016/j.jvscit.2018.05.001>

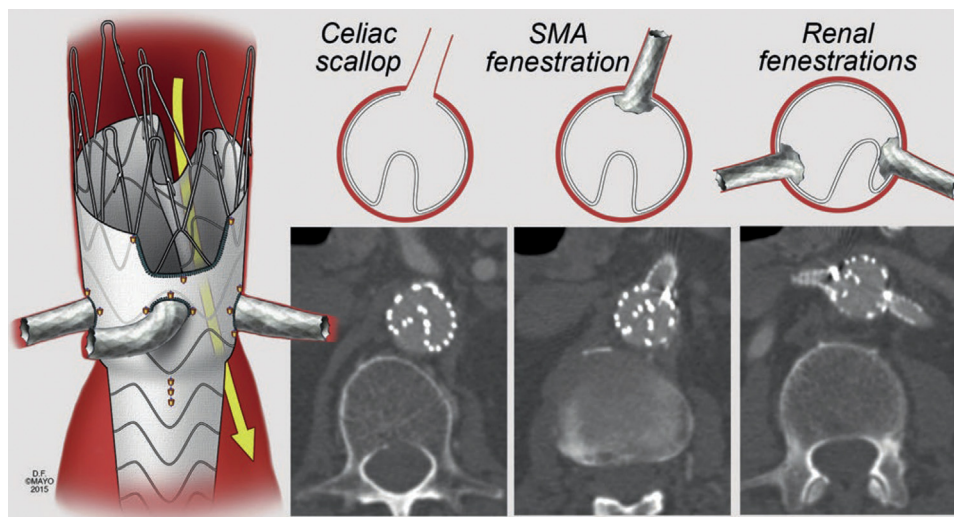


Fig 1. Infolding of fenestrated stent graft due to excessive oversizing caused a type I endoleak. SMA, Superior mesenteric artery. (Reproduced by permission of Mayo Foundation for Medical Education and Research. All rights reserved.)

stent (Cordis Endovascular, Milpitas, Calif) was positioned and deployed just proximal to the SMA fenestration and across the celiac axis scallop to expand the proximal sealing stent. The Palmaz stent was postdilated to 25 mm through the left femoral approach to re-expand the top sealing stent of the fenestrated aortic stent graft. Once the sealing stent was fully expanded, the balloon was used to dilate the segment across the SMA and renal arteries with concomitant balloon inflation of all three fenestrated stents. The aortic balloon was deflated first, followed by angioplasty of the SMA and renal stents. Completion angiography revealed a widely patent celiac axis, SMA, and bilateral renal arteries with no evidence of endoleak. Intravascular ultrasound was performed and demonstrated a completely expanded stent graft. CBCT confirmed that all stents were fully expanded with no residual infolding (Fig 2). The patient tolerated the procedure well and was discharged on postoperative day 2 with a normal serum creatinine concentration of 0.9 mg/dL and no complications. CTA at 1 year showed a widely patent stent graft with small type II endoleak.

DISCUSSION

Fenestrated and branched endografts have broadened the indications of endovascular aortic repair to patients with complex aneurysms involving the renal and mesenteric arteries.^{4,5} In most centers with larger experience, fenestrated stent grafts have evolved from two fenestrations to three or four fenestrations based on suprarenal sealing zones. This change in design paradigm has occurred because of risk of progression of aortic disease, which may compromise sealing zone in patients treated by two fenestrations. Despite the increasing complexity in design, outcomes with three or four fenestrations

have been satisfactory, with no change in technical success, mortality, and major adverse events.¹⁻³

Type IA endoleaks after fenestrated endovascular aneurysm repair are infrequent, particularly if suprarenal sealing zone is used.^{2,4,6} O'Callaghan et al⁷ reported a large experience with 924 patients, of whom 26 (2.8%) had type IA endoleak after fenestrated repair. In that study, use of more fenestrations was associated with significant decline in the rate of type IA endoleak. Once a type IA endoleak is present, treatment is recommended, but options may be limited to stent graft explantation or redo fenestrated-branched repair if there is progression of disease compromising seal.^{8,9} In the U.S. Zenith Fenestrated Study, one patient (1.5%) developed a late type IA endoleak treated by coil embolization at 3 years of follow-up.¹⁰

Fenestrated stent graft infolding is a rare complication with no previous reports in the literature. This may be due to excessive stent graft oversizing, which can occur if there is a narrower aortic segment below the sealing zone. Fenestrated stent grafts have been traditionally designed with a tapered segment below the lowest renal fenestration so that the fenestrations are as close as possible to the target vessel. In patients with juxtarenal aneurysms, the infrarenal aorta may be excessively narrow compared with the sealing zone at the level of the SMA and suprarenal aorta (Fig 3). This may be a cause of infolding, which can be prevented by designing the fenestrated endograft with a tapered segment across the fenestrations to better match the aortic diameter.

Treatment of infolding requires dilation of the aortic endograft, which has to be done with caution to avoid uncontrolled aortic disruption. For this reason, we elected to start the revision by expanding the proximal sealing stent with a Palmaz stent graft, ensuring at least

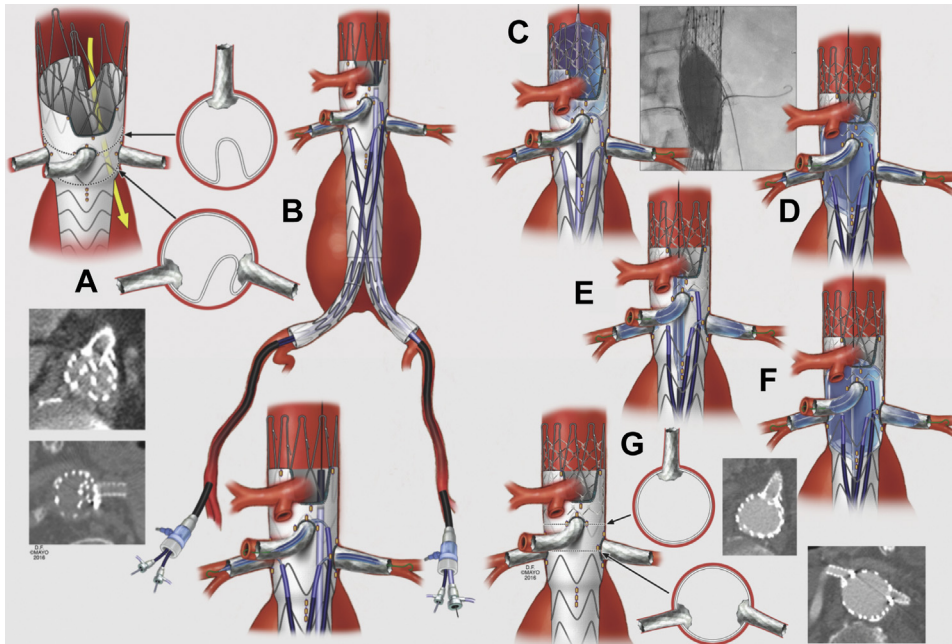


Fig 2. Infolded aortic stent across the fenestrated segment (**A**) requires protection of each of the side stents by sheath and balloon (**B**). Placement of a Palmaz stent in the proximal sealing stent (**C**) followed by dilation of the visceral segment of the graft (**D**), balloon dilation of each side stent (**E**), and the aorta (**F**) allows complete expansion of the aortic graft (**G**). (Reproduced by permission of Mayo Foundation for Medical Education and Research. All rights reserved.)

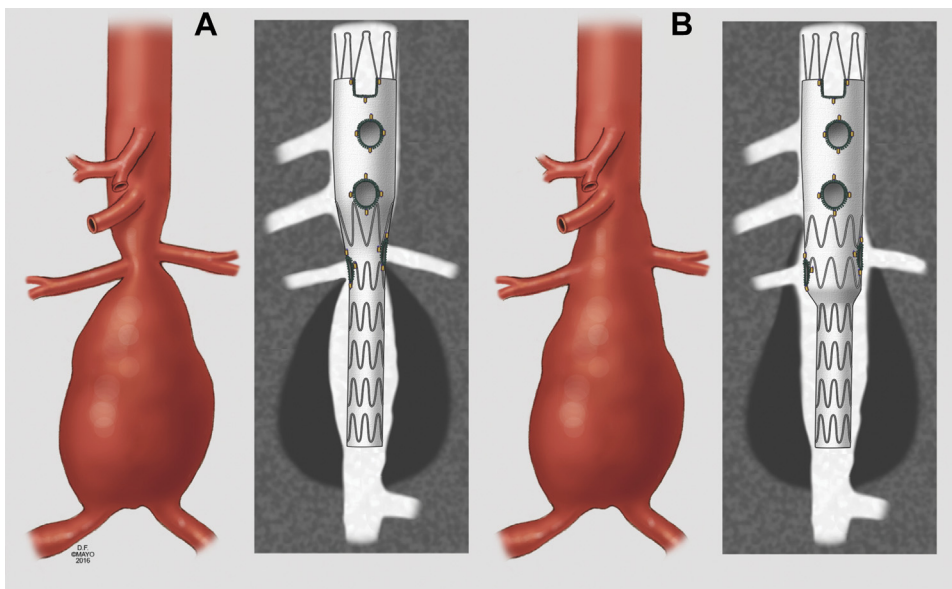


Fig 3. Fenestrations have been based on wider graft diameters to promote apposition between the graft fabric and the aortic wall. Some designs may start the tapered segment in the superior mesenteric artery (SMA), ending below the renal arteries (**A**), or use the traditional design of rapid tapering below the renals (**B**). The design illustrated in (**A**) could have avoided the infolded aortic stent in this case. (Reproduced by permission of Mayo Foundation for Medical Education and Research. All rights reserved.)

expansion of the proximal stent and resolution of the type IA endoleak. Once the stent was expanded, the renal and mesenteric segments were dilated with balloon protection of the visceral vessels to prevent side

branch stent compression or occlusion. Our report also illustrates the utility of performing immediate assessment with CBCT, which was not done at the time of the initial implant. Intraoperative assessment with

CBCT ensures immediate identification of stent kink, compression or infolding, and endoleaks and may decrease the rate of avoidable reinterventions as illustrated by this case.^{11,12}

CONCLUSIONS

This case illustrates a technique for repair of fenestrated stent graft infolding with a Palmaz stent while preventing side stent compression. It also highlights the role of CBCT in ensuring aortic and visceral stent graft patency.

REFERENCES

1. Verhoeven EL, Katsargyris A, Oikonomou K, Kouvelos G, Renner H, Ritter W. Fenestrated endovascular aortic aneurysm repair as a first line treatment option to treat short necked, juxtarenal, and suprarenal aneurysms. *Eur J Vasc Endovasc* 2016;51:775-81.
2. Kitagawa A, Greenberg RK, Eagleton MJ, Mastracci TM. Zenith p-branch standard fenestrated endovascular graft for juxtarenal abdominal aortic aneurysms. *J Vasc Surg* 2013;58:291-300.
3. Starnes BW, Tatum B. Early report from an investigator-initiated investigational device exemption clinical trial on physician-modified endovascular grafts. *J Vasc Surg* 2013;58:311-7.
4. Mastracci TM, Eagleton MJ, Kuramochi Y, Bathurst S, Wolski K. Twelve-year results of fenestrated endografts for juxtarenal and group IV thoracoabdominal aneurysms. *J Vasc Surg* 2015;61:355-64.
5. Oderich GS, Ribeiro M, Hofer J, Wigham J, Cha S, Chini J, et al. Prospective, nonrandomized study to evaluate endovascular repair of pararenal and thoracoabdominal aortic aneurysms using fenestrated-branched endografts based on supraceliac sealing zones. *J Vasc Surg* 2017;65:1249-59.e10.
6. Starnes BW, Heneghan RE, Tatum B. Midterm results from a physician-sponsored investigational device exemption clinical trial evaluating physician-modified endovascular grafts for the treatment of juxtarenal aortic aneurysms. *J Vasc Surg* 2017;65:294-302.
7. O'Callaghan A, Greenberg RK, Eagleton MJ, Bena J, Mastracci TM. Type Ia endoleaks after fenestrated and branched endografts may lead to component instability and increased aortic mortality. *J Vasc Surg* 2015;61:908-14.
8. Cox DE, Jacobs DL, Motaganahalli RL, Wittgen CM, Peterson CJ. Outcomes of endovascular AAA repair in patients with hostile neck anatomy using adjunctive balloon-expandable stents. *Vasc Endovascular Surg* 2006;40:35-40.
9. Dias NV, Resch T, Malina M, Lindblad B, Ivancev K. Intra-operative proximal endoleaks during AAA stent-graft repair: evaluation of risk factors and treatment with Palmaz stents. *J Endovasc Ther* 2001;8:268-73.
10. Oderich GS, Greenberg RK, Farber M, Lyden S, Sanchez L, Fairman R, et al. Results of the United States multicenter prospective study evaluating the Zenith fenestrated endovascular graft for treatment of juxtarenal abdominal aortic aneurysms. *J Vasc Surg* 2014;60:1420-8.e1-e5.
11. Tornqvist P, Dias N, Sonesson B, Kristmundsson T, Resch T. Intra-operative cone beam computed tomography can help avoid reinterventions and reduce CT follow up after infrarenal EVAR. *Eur J Vasc Endovasc Surg* 2015;49:390-5.
12. Schulz CJ, Schmitt M, Bockler D, Geisbusch P. Intraoperative contrast-enhanced cone beam computed tomography to assess technical success during endovascular aneurysm repair. *J Vasc Surg* 2016;64:577-84.

Submitted Mar 16, 2018; accepted May 5, 2018.