

Received: 2015.05.15
Accepted: 2015.06.29
Published: 2015.10.02

Bilateral Pneumothoraces Following BiV ICD Placement: A Case of Buffalo Chest Syndrome

Authors' Contribution:
Study Design A
Data Collection B
Statistical Analysis C
Data Interpretation D
Manuscript Preparation E
Literature Search F
Funds Collection G

ACDEF 1 **Aniket S. Rali**
DE 2 **Harish Manyam**

1 Department of Internal Medicine, University Hospitals Case Medical Center, Cleveland, OH, U.S.A.

2 Department of Electrophysiology, Harrington Heart and Vascular Institute, Cleveland, OH, U.S.A.

Corresponding Author: Aniket Rali, e-mail: aniket.rali@uhospitals.org
Conflict of interest: None declared

Patient: Female, 73
Final Diagnosis: Buffalo chest syndrome
Symptoms: —
Medication: —
Clinical Procedure: Bi-ventricular ICD
Specialty: Cardiology

Objective: Rare disease

Background: Contralateral pneumothorax following device implantation on the left side has been reported in a few cases. The majority of contralateral pneumothoraces showed evidence of atrial perforation on computed tomography (CT), echocardiography, or chest x-rays and required lead revision. To the best of our knowledge there is only 1 other reported case of contralateral pneumothorax without evidence of macro-displacement of the atrial lead. In that case the patient experienced a right-sided pneumothorax on day 1 after undergoing repositioning of the atrial lead.

Case Report: The current case is unique on several accounts, including timing of the contralateral pneumothorax and no evidence of associated atrial lead perforation on device interrogation or CT imaging. Furthermore, the appearance of contralateral pneumothorax within 8 hours of clamping of the ipsilateral chest tube argues in favor of a pleuro-pleural fistula.

Conclusions: The term 'buffalo chest' refers to a single pleural space, with no anatomical separation of the 2 hemithoraces, as seen in an American buffalo or bison. We believe this to be a case of buffalo chest syndrome.

MeSH Keywords: Bison • Cardiac Electrophysiology • Cardiac Resynchronization Therapy Devices • Pneumothorax, Artificial

Abbreviations: CT – computed tomography; EF – ejection fraction; NYHA – New York Heart Association, ICD – implantable cardioverter defibrillator

Full-text PDF: <http://www.amjcaserep.com/abstract/index/idArt/894671>



Background

Contralateral pneumothorax following device implantation on the left side has been reported in a few cases. Most contralateral pneumothoraces showed evidence of atrial perforation on CT, echocardiography, or chest x-rays and required lead revision [1]. To the best of our knowledge, there is only 1 other reported case of contralateral pneumothorax without evidence of macro-displacement of the atrial lead [2]. In that case the patient had loss of atrial lead capture at high output, which required repositioning of the atrial lead. Our case is unique on several accounts, including timing of the contralateral pneumothorax, normal device parameters, and no evidence of associated atrial lead perforation on imaging.

Case Report

A 73-year-old woman with non-ischemic cardiomyopathy (EF of 30–35%), NYHA class 3, and left bundle branch block underwent implantation of a biventricular implantable cardioverter defibrillator (BiV-ICD) with a screw-in atrial lead. The device was implanted through the left axillary approach and during implantation the patient experienced severe nausea and emesis with gross intra-procedural movement. This made

obtaining access difficult and required multiple attempts before access was secured.

The patient had intra-procedural hypotension and hypoxemia. Hypotension somewhat resolved with intravenous fluids but fluoroscopy was concerning for a left-sided pneumothorax. A post-procedure chest x-ray confirmed a moderate-size left pneumothorax. The cardiothoracic surgery team was consulted for an emergent chest tube placement. The patient's dyspnea improved after chest tube placement. A repeat chest x-ray 48 hours later confirmed resolution of left-sided pneumothorax and the chest tube was transitioned to a water-seal.

The patient continued to have severe nausea and vomiting, which was managed with ondansetron. On day 3 of hospitalization the patient had another episode of hypotension. At that time, a follow-up chest x-ray (Figure 1), taken 8 hours after clamping of the ipsilateral (left sided) chest tube, demonstrated a moderate right-sided hydropneumothorax and recurrent left-sided apical pneumothorax. At that time a right-sided chest tube was placed by cardiothoracic surgery and the previously placed left-sided tube was unclamped. The device was checked again and normal parameters were seen (atrial threshold 0.5 @ 0.4 mV, atrial lead impedance 762 ohms, and atrial sensing 1 V; unipolar atrial lead testing without change in atrial lead threshold). CT imaging (Figure 2) confirmed that the placement of the BiV-ICD leads ended within the right atria,

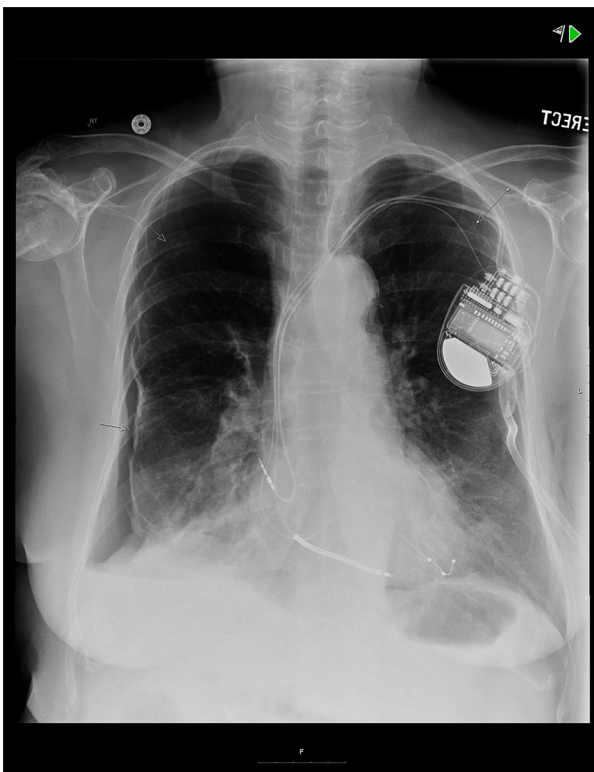


Figure 1. Chest x-ray performed on post-procedure day 3 confirming bilateral pneumothoraces. Left-sided chest tube in place.

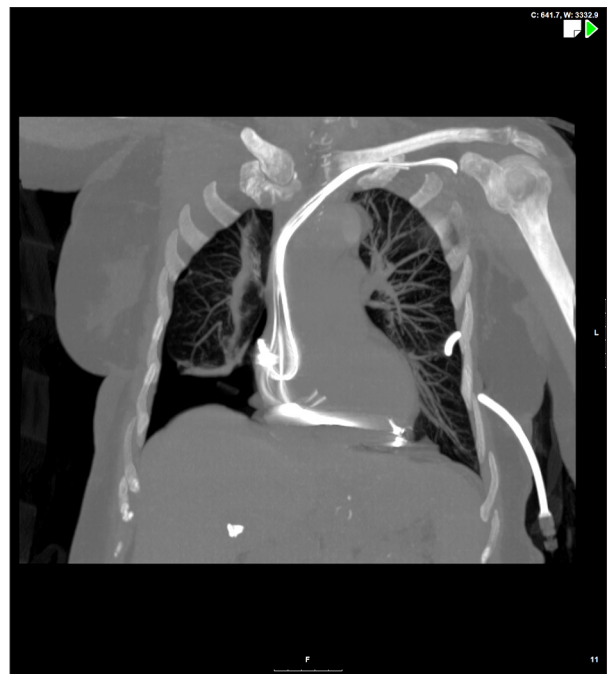

Figure 2. CT chest performed on post-procedure day 3 confirming no atrial lead perforation. Lead shadow/artifact remains within the right atrium, further suggesting that the actual lead is within the chamber.

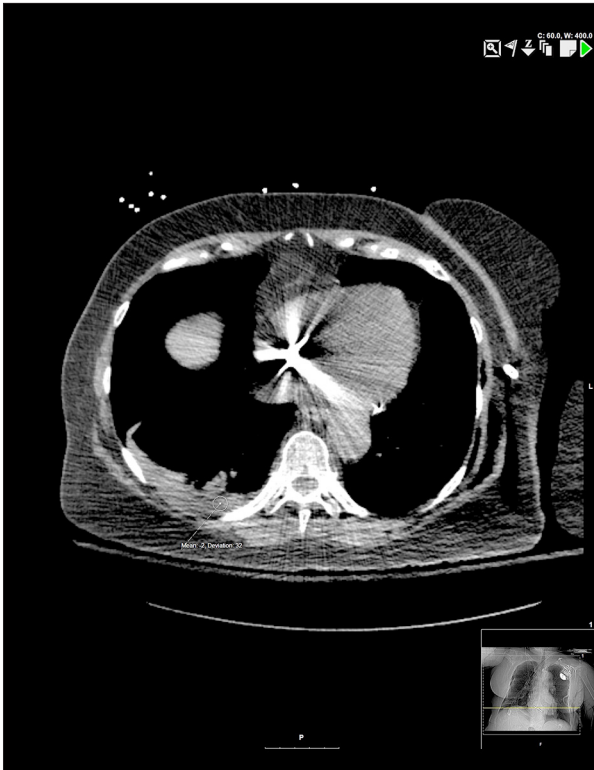


Figure 3. CT chest showing right pleural fluid with Hounsfield units measuring between 0–10.

right ventricle, and a branch of the coronary sinus, without any myocardial perforation.

Hounsfield units of the pleural fluid at right lung base were between 0–10, which would be most consistent with non-hemorrhagic fluid (Figure 3). Furthermore, there was no evidence of air or fluid within the pericardial cavity (Figure 4). Repeat chest x-ray confirmed resolution of bilateral pneumothorax within hours of right-sided chest tube placement. On day 4 of hospitalization both chest tubes were transitioned to water-seal without recurrence of pneumothorax and subsequent removal of tubes prior to discharge.

A follow-up chest x-ray after chest tube removal showed a small left-sided apical pneumothorax. The patient recovered well and was sent home without supplemental oxygen. Repeat imaging a week later showed resolution of the left-sided apical pneumothorax.

Discussion

This case is unique in that the patient developed bilateral pneumothoraces and, more importantly, the contralateral pneumothorax occurred several days after the procedure. Left-sided (ipsilateral) pneumothorax is a known complication

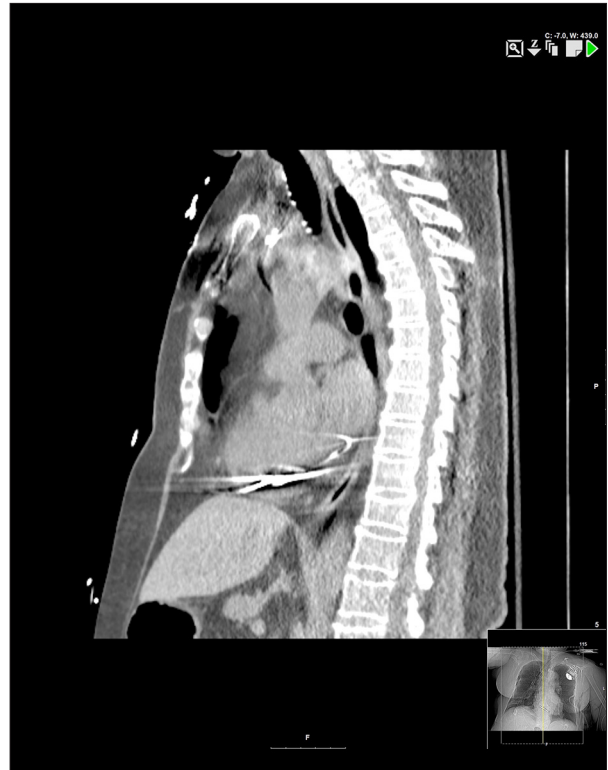

Figure 4. Sagittal view of CT chest confirming absence of fluid or air in the pericardial space.

of the left subclavian approach. Possible explanations for contralateral pneumothorax include a ruptured bulla (in the setting of nausea and vomiting), atrial lead micro-perforation, or a traumatic pleural puncture either leading to or in the presence of a buffalo chest.

The term ‘buffalo chest’ refers to a single pleural space, with no anatomical separation of the 2 hemithoraces, as seen in an American buffalo or bison. This feature of its anatomy proved to be a disadvantage for the animal because a single arrow to the thorax often led to bilateral tension pneumothoraces and was fatal. In humans, the pleural cavities are separated, but a pleuro-pleural communication may result from intrathoracic procedures, leading to ‘iatrogenic buffalo chest.’ In our patient with a buffalo chest, the right and left pneumothoraces were located at different areas within a single pleural cavity. For this very reason, absence of a right-sided pneumothorax immediately following the procedure does not rule out a buffalo chest. Delay in appearance of contralateral pneumothorax in a patient with buffalo chest was also noted in the case reported by Atkinson et al. [3].

Ruptured bulla was ruled out by CT. Atrial lead perforation was ruled out by device interrogation and CT. We accept that this could still be a micro-perforation, although there was still capture through the lead on unipolar testing, making it less likely.

More likely, we believe this to be a case of buffalo chest syndrome. The appearance of the bilateral pneumothoraces immediately after clamping of the left-sided chest tube argues in favor of buffalo chest physiology. One definitive way of confirming this would be resolution of right-sided pneumothorax with unclamping of the left-sided chest tube. However, buffalo chest syndrome was not in the differential diagnosis at the time of this acute clinical event. Furthermore, given the magnitude of right-sided hydropneumothorax and patient's symptoms, placement of a right-sided chest tube was pursued in an emergent manner.

Conclusions

Contralateral pneumothorax caused by atrial lead perforation is a known complication of electrophysiology procedures. To the best of our knowledge, there is only 1 reported case of contralateral pneumothorax, in the absence of macro-lead perforation [2]. Buffalo chest syndrome is another rare etiology

References:

1. Srivathsan K, Byrne RA, Appleton CP, Scott LRP: Pneumopericardium and pneumothorax contralateral to venous access site after permanent pacemaker implantation. *Europace*, 2003; 5: 361–63
2. Petteimerides V, Jenkins N: Contralateral pneumothorax following repositioning of an atrial lead. *Europace*, 2011; 4: 606
3. Hartin DJ, Kendall R, Boyle AA, Atkinson PRT: Case of the month: buffalo chest: a case of bilateral pneumothoraces due to pleuropleural communication. *Emerg Med J*, 2006; 23: 483–86

of bilateral pneumothoraces, as we believe was the case with our patient. The appearance of bilateral pneumothoraces hours after clamping of the left-sided chest tube, normal device parameters, and negative imaging for macro-lead perforation all point towards buffalo chest physiology as the likely cause here. We accept that micro-perforation of the atrial lead remains a less likely possibility. It is our hope that our case report shall help readers consider buffalo chest syndrome among differential diagnoses during similar unusual clinical presentations.

Acknowledgements

We appreciate the guidance of Drs. Jay Gollamudi and Robert Gilkeson, with the Department of Radiology at University Hospitals Case Medical Center, in interpreting images reported here.

Conflict of interests

No conflict of interests exists in reporting this case for either of the 2 authors.