

Single Case

Improvement of Psoriasis, Psoriatic Arthritis, and Alopecia Universalis during Treatment with Tofacitinib: A Case Report

Tanja Todberg^{a, b} Nikolai Dyrberg Loft^{a, b} Claus Zachariae^{a, b}

^aDepartment of Dermatology and Allergy, Herlev and Gentofte Hospital, University of Copenhagen, Hellerup, Denmark; ^bCopenhagen Research Group for Inflammatory Skin (CORGIS), Hellerup, Denmark

Keywords

Alopecia areata · Alopecia universalis · Psoriasis · Psoriatic arthritis · Psoriasis treatment

Abstract

Alopecia areata (AA) is the most common immune-mediated hair loss disorder with a life-time prevalence of 2%. The pathogenesis of AA is not completely understood, but interferon gamma (INF- γ) and Janus kinases (JAK) may play a key role. Here, we present a case involving a male patient with psoriasis and psoriatic arthritis, who exhibited a rapid hair loss, diagnosed as AA, during ciclosporin treatment. As ciclosporin was unable to control his psoriasis, the treatment was changed to methotrexate injections, but the hair loss progressed into alopecia universalis. During treatment with the oral JAK inhibitor tofacitinib, the patient presented an almost complete hair remission on the scalp and partly on the eyebrows, eyelashes, beard, and chest. Furthermore, the patient experienced no joint complaints and his psoriasis was improved. Based on these findings, JAK inhibitors may be an optional treatment in complicated cases involving both rheumatological and dermatological diseases.

© 2020 The Author(s)
Published by S. Karger AG, Basel

Introduction

Alopecia areata (AA) is an immune-mediated hair loss disorder with a life-time prevalence of 2% [1]. AA is a predominantly type 1-driven inflammation with interferon-gamma stimulating Janus kinase (JAK) leading to activation of the JAK STAT pathway [2]. Likewise, type 1 inflammation is important in the initiation of psoriasis and psoriatic arthritis, but Th17 cytokines have been shown to play a dominant role in the chronic phase of psoriasis [3].

Tofacitinib, a selective JAK inhibitor suppressing preferentially JAK1 and JAK3, is approved for psoriatic arthritis, rheumatoid arthritis, and ulcerative colitis, but has also been shown effective in several other dermatological diseases [2].

Here, we present a case including a patient with psoriasis, psoriatic arthritis, and AA who achieved improvement in all diseases after treatment with tofacitinib.

Case Report

A 49-year-old man with a history of psoriatic arthritis had been seen at our department for several years for treatment of severe psoriasis. Due to gastrointestinal side effects of orally administered methotrexate 15 mg per week, his psoriasis was treated with ciclosporin 100 mg twice daily from January 2014 until January 2018 with efficient results. Since 2003 he had been treated with salazopyrine 1 g twice daily for psoriatic arthritis and had no joint complaints.

At the end of 2015, the patient exhibited a rapid hair loss located on the scalp and AA was diagnosed. This progressed into alopecia totalis over 3 years. From October 2017 to February 2018, his AA was treated with diphencyprone (DCP), initially 2% down-titrated to 0.001% twice monthly; however, the effect was discrete with only minor hair regrowth in the occipital area.

In January 2018, his psoriasis could no longer be controlled with ciclosporin, and subcutaneous methotrexate 15 mg per week was initiated. After 3 months, the hair loss progressed and involved the scalp, eyebrows, eyelashes, beard, and chest and he was diagnosed with alopecia universalis (AU) (Fig. 1a, b, Fig. 2a, b). Additionally, he had no improvement in psoriasis, and in May 2018 tofacitinib 5 mg twice daily was initiated as a potential treatment for psoriasis, psoriatic arthritis, and AU. After 3 months of treatment, a moderate remission in hair regrowth was observed, the psoriasis had almost cleared and the patient had no joint complaints, thus treatment with salazopyrine was paused.

In January 2019, an impressive hair regrowth was seen on the scalp, beard, eyebrows, and a partly remission of the eyelashes (Fig. 1c, d). Furthermore, the patient had no relapse in psoriatic arthritis and only minor psoriatic plaques were seen (Fig. 2c, d).

Discussion

This is a rather unusual case, as AA development occurred while the patient was treated with ciclosporin, which has shown to be effective in up to 57% of patients with AA [4].

Treatment of AA is challenging, with first-line treatment including DCP and topical steroids. In a systematic review and meta-analysis, methotrexate was found to be effective for the treatment of AA, especially when given in combination with topical steroids [5]. However, methotrexate is not well tolerated in all patients, and as seen in the current case, not always

with acceptable effect on AA/AU. Among other systemic treatments for AA, JAK inhibitors have been described as a new promising therapy. In a recent clinical trial, almost 40% of patients with AA experienced complete regrowth after treatment with tofacitinib [6].

To the best of our knowledge, this is the first case report describing a patient with multiple diseases including psoriasis, psoriatic arthritis, and AU who is successfully treated with tofacitinib.

Oral JAK inhibitors have similar safety profiles as other immunosuppressive drugs, and could be considered in cases with refractory concomitant diseases where JAK inhibitors can be effective for both dermatological and rheumatological conditions.

Statement of Ethics

The research was conducted ethically in accordance with the World Medical Association Declaration of Helsinki. The subject has given his written informed consent to publish his case (including the images).

Conflict of Interest Statement

Dr. Todberg has served as investigator for Novartis and LEO Pharma. Dr. Loft has been an honorary speaker for Eli Lilly. Dr. Zachariae has consulting relationships and/or is an investigator and/or received grants or honoraria from Eli Lilly and Company, Janssen Cilag, Novartis Pharmaceutical Corp., AbbVie, Takeda, Amgen, MSD, LEO Pharmaceuticals, Boehringer-Ingelheim, Almirall, and Regeneron.

Funding Sources

No funding was received.

Author Contributions

C.Z. was the physician who had several consultations with the patient. C.Z., N.D.L., and T.T contributed to the preparation of the manuscript.

References

- 1 Gilhar A, Etzioni A, Paus R. Alopecia areata. *N Engl J Med*. 2012 Apr;366(16):1515–25.
- 2 Damsky W, King BA. JAK inhibitors in dermatology: the promise of a new drug class. *J Am Acad Dermatol*. 2017 Apr;76(4):736–44.
- 3 Conrad C, Gilliet M. Psoriasis: from pathogenesis to targeted therapies. *Clin Rev Allergy Immunol*. 2018 Feb;54(1):102–13.
- 4 Kassira S, Korta DZ, Chapman LW, Dann F. Review of treatment for alopecia totalis and alopecia universalis. *Int J Dermatol*. 2017 Aug;56(8):801–10.
- 5 Phan K, Ramachandran V, Sebaratnam DF. Methotrexate for alopecia areata: A systematic review and meta-analysis. *J Am Acad Dermatol*. 2019 Jan;80(1):120–27e2.
- 6 Serdaroglu S, Engin B, Çelik U, Erkan E, Aşkın Ö, Oba Ç, et al. Clinical experiences on alopecia areata treatment with tofacitinib: A study of 63 patients. *Dermatol Ther (Heidelb)*. 2019 May;32(3):e12844.

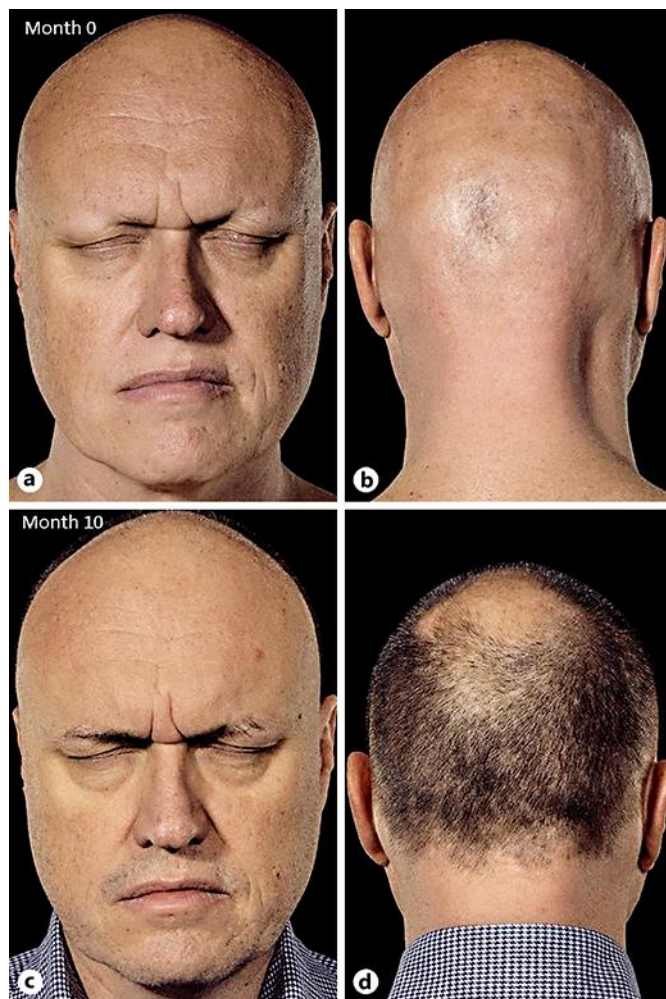


Fig. 1. **a** View of the face at baseline. **b** View of the cranium at baseline. **c** View of the face after 10 months of treatment with tofacitinib. **d** View of the cranium after 10 months of treatment with tofacitinib.

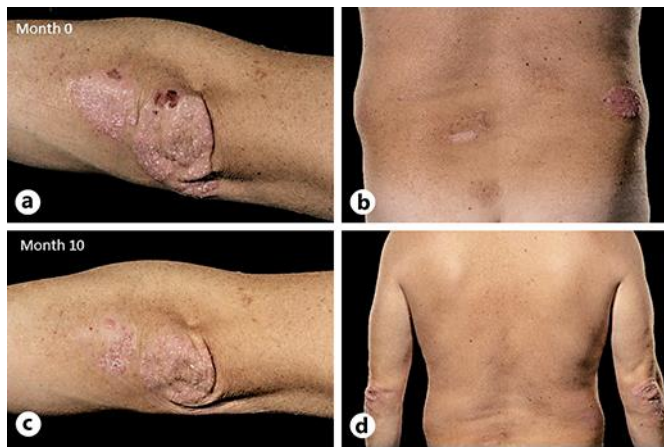


Fig. 2. **a** View of the elbow at baseline. **b** View of the back at baseline. **c** View of the elbow after 10 months of treatment with tofacitinib. **d** View of the back after 10 months of treatment with tofacitinib.