

Available online at www.sciencedirect.com

ScienceDirect

Biomedical Journal

journal homepage: www.elsevier.com/locate/bj

Highlights

Sweet dreams: How mini-invasive surgery tackles obstructive sleep apnea

Sophia Julia Häfner

University of Copenhagen, BRIC Biotech Research & Innovation Centre, Anders Lund Group, Ole Maaløes Vej 5, 2200, Copenhagen, Denmark

ARTICLE INFO

Article history:

Available online 20 May 2019

Keywords:

Obstructive sleep apnea
Automated hematology
Tyrosine phosphorylation

ABSTRACT

In this issue of the *Biomedical Journal* we uncover how the discovery of tyrosine phosphorylation thirty years ago led to the recent development of potent cancer drugs. Furthermore we learn about the state of the art of surgery for obstructive sleep apnea and how modern automated hematology could be used to detect various pathologies. Finally we discuss the risk factors for hospital-acquired *Clostridium difficile* infection and how to minimize ultrasonic motor-induced magnetic resonance imaging artifacts.

Spotlight on review

Sweet dreams: how mini-invasive surgery tackles obstructive sleep apnea

“He who sleeps does not sin”, claims a medieval mock syllogism, yet more dangers than one could expect linger in Morpheus' arms. Proof that the bed is not necessarily a safe harbor is the panel of sleep disordered breathing (SDB) syndromes, ranging from simple snoring to obstructive sleep apnea (OSA), which consists in the complete or partial obstruction of the airways during sleep [1]. It is normal for the overall muscle tone of the body to decrease during sleep, however, in some cases this can lead to the collapse of the soft tissues that compose the throat and airways. As a consequence, breathing is repeatedly reduced or paused for up to 40 s, causing depletion in blood oxygen saturation

{Rochester:MkNi0iPx}. OAS can be transient in the context of upper respiratory infections causing the swelling of various tissues in the throat, or chronic. The latter is most common in middle-aged overweight individuals and twice as frequent in males (2–4%) than females. Many factors can contribute to the development of the syndrome, including craniofacial abnormalities and excessive bulk of soft tissue but also problems with the neurologic control of the upper airway musculature [2].

The severity of the possible health repercussions of chronic OAS is commonly underestimated. OAS leads to serious daytime sleepiness, which impacts on working abilities, accidents due to lack of attention and a reduction of overall life quality, but increases also the risk for inner ear diseases as well as for hypertension and cardiovascular diseases, including myocardial infarction [1] and eventually even for dementia [3].

E-mail address: sophia.hafner@bric.ku.dk.

Peer review under responsibility of Chang Gung University.

<https://doi.org/10.1016/j.bj.2019.04.005>

2319-4170/© 2019 Chang Gung University. Publishing services by Elsevier B.V. This is an open access article under the CC BY-NC-ND license (<http://creativecommons.org/licenses/by-nc-nd/4.0/>).

Continuous positive airway pressure (CPAP) is the standard first line of treatment for OAS [4]. Patients wear a facemask by night through which a ventilator continuously applies light air pressure to keep the airways open. Other than the inevitable discomfort generated by the device, CPAP is not always efficient, leaving usually only surgery as an alternative treatment [4]. Given the multifactorial etiology of OAS and the complex architecture of the human airways, this comprises in reality a multitude of possible interventions that have to be carefully selected, eventually combined and ultimately backed up with additional treatment methods in order to provide a long-term cure.

On these grounds, Li et al. update us in their comprehensive review article on the current state of the art in decision-making between CPAP and surgery but also surgery procedure types and finally stress the importance of post-operative integrated treatment [5]. Concerning the decision-making between CPAP and surgery, the authors emphasize on the importance of distinguishing obstruction from collapse, as the first one evinces clear anatomical deformities that can be corrected surgically, while collapse mostly indicates neurological issues rather palliated by CPAP, without omitting all the exceptions and hybrid conditions.

Subsequently, the review takes the reader through the many different types of surgery, clearly stating for which precise pathological background they are the most appropriate. It becomes clear that over the recent years, much effort towards mini-invasiveness has been made as to preserve pharyngeal function. Intra-pharyngeal surgery for example has transited from blunt excision to a differential treatment of each tissue, such as ablation of adipose tissue, muscle suspension and mucosa preservation. Other recently developed techniques comprise mini-invasive septoturbinoplasty (MIST) as a form of nasal surgery and the use of the suspension technique as a way to minimize soft palate excision during uvulopalatopharyngoplasty.

Ultimately, the outcomes of the surgery are significantly enhanced by postoperative integrated treatment, such as the re-education and strengthening of the muscles and respiration training via oropharyngeal myofunctional therapy, positional therapy as to favor lateral sleep, weight loss and cognitive behavior therapy meant to re-acquire a healthy circadian rhythm.

All in all, it is very clear that OSA is a complex condition whose many forms and origins necessitate a thorough and precise preliminary analysis and a tailored strategy both for surgical correction and additional measures in order to maximize the benefit of the latter [Fig. 1].

Spotlight on original articles

Automated hematology has more than one string to its bow

Although modern automated hematology analyzers are nowadays part and parcel of any hematology laboratory, they are mainly used only for cell counts and differential leukocyte analysis, despite the fact that most machines allow for the acquisition of way more parameters. Habit,

lack of information about the full potential of the devices and skewed trust between well-trained hematologists and machines might be at fault [6]. Among the available additional features are for example is the reticulocyte hemoglobin content (CHr), a good indicator for iron deficiency. As for leukocytes, a multitude of characteristics such as electrical impedance, radiofrequency conductivity, volume, conductivity and scatter (VCS) of up to 10^5 cells in a few seconds can be obtained [6]. Various combinations have already been suggested to serve the detection of viral, bacterial and parasitic infections, sepsis, or malignant hematological conditions [7,8]. Patients with acute lymphocytic leukemia (ALL) or chronic lymphocytic leukemia (CLL) for instance were shown to display distinct characteristic VCS profiles [9].

In the present issue, Gaspar et al. propose to further exploit the technology's potential and investigate if the obtained data on leukocyte size and structure could be used to tell reactive from neoplastic cellular proliferations, focusing on chronic myeloid leukemia (CML) [10]. CML accounts for 15–25% of all adult leukemias and is characterized by an abnormal proliferation of mature granulocytes and their precursors as well as by the fusion gene BCR-ABL1 [11]. As mentioned in our editorial about the history of tyrosine kinases, the first targeted tyrosine-kinase inhibitor that succeeded as an FDA-approved drug was imatinib in 2001 for the treatment of CML and has since then massively improved therapy and patient life quality [12].

The study consists in the comparison of complete blood counts and VCS data from newly diagnosed CML patients, CML patients under imatinib treatment, patients with high neutrophil counts, pregnant women and healthy controls. Compared to the benign controls, untreated CML patients exhibited indeed significantly higher mean neutrophil and monocyte volumes (MNV, MMV), higher mean lymphocyte scatter (MLS) as well as higher standard deviations of mean neutrophil volume and conductivity (MNV-SD, MNC-SD). Without the input of total leucocyte counts, untreated CML could be distinguished from benign neutrophilia notably via the combination of MNV and MNC-SD. Upon treatment by imatinib on the other hand, these values and several other parameters seemed to normalize, which suggests that monitoring their evolution in the course of therapy could serve as an indicator for treatment efficiency. Moreover, the combined analysis of the VCS data by two algorithmic approaches managed to discriminate untreated CML cases against all other groups.

As the authors point out, rather than supplanting an expert opinion in the case of a specific diagnostic conjecture, this type of analysis and many similar ones could be integrated without any extra cost or need for time and more samples into global routine automated health check-ups. Any detected anomaly would generate an immediate “electronic warning flag”, subsequently prompting the medical personnel to issue further appropriate tests. Furthermore, aside from the diagnostic value, this would allow for a statistically valuable collection of standardized data on a multitude of conditions, which could in turn help to gain biological insights into both pathogenesis and treatment time course.

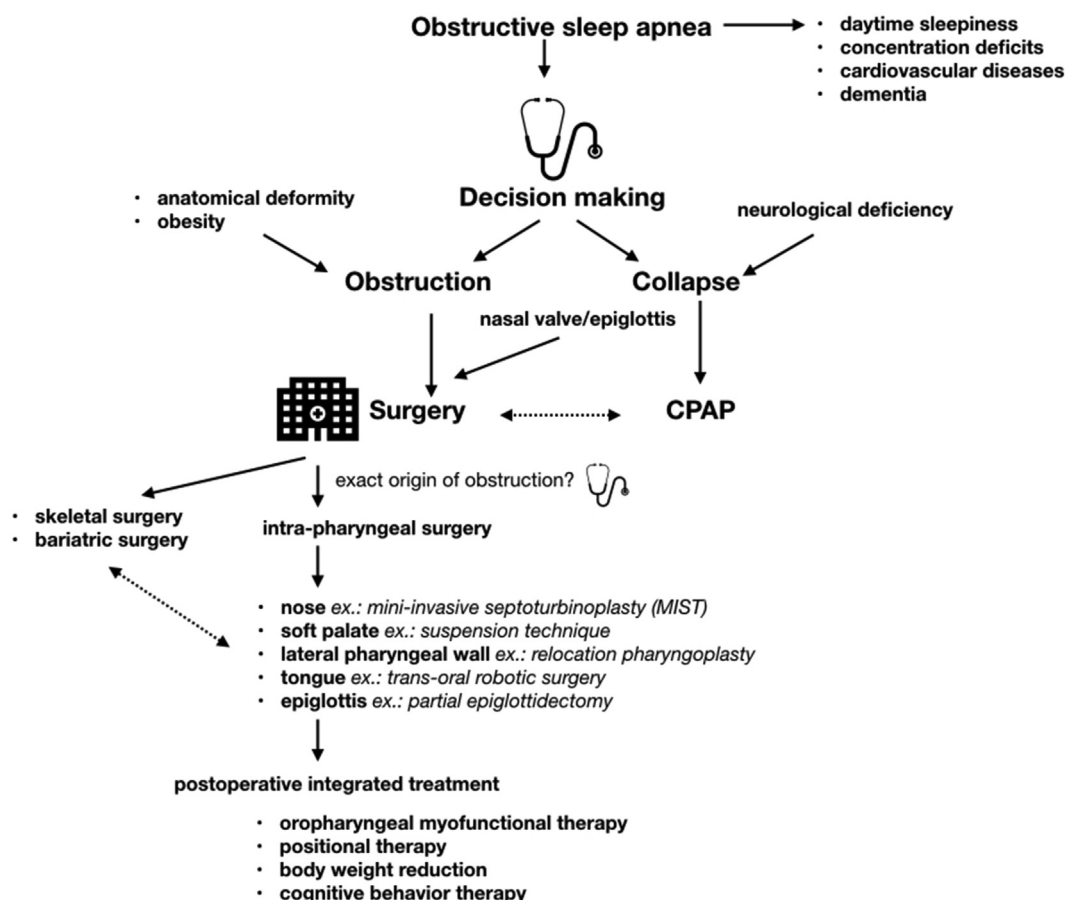


Fig. 1 The complex task of treating obstructive sleep apnea (OSA). OSA is a multifactorial disease with severe possible consequences on health and life quality. Treatment success depends heavily on the precise identification of the anatomical origin of the problem, the tailored choice of intervention and the thorough backing-up of surgery by postoperative integrated treatments. At the surgery level, the recent trend is towards minimal invasiveness and a maximal preservation of pharyngeal function.

Also in this issue

News and perspectives

30 years of tyrosine phosphorylation

At the occasion of the bestowal of the prestigious 2018 Tang Prize in Biopharmaceutical Science to Tony Hunter, Brian Druker and John Mendelsohn “for the discovery of protein tyrosine phosphorylation and tyrosine kinases as oncogenes, leading to successful targeted cancer therapies”, Jau-Song Yu takes us in his editorial onto a captivating travel through 30 years of history of tyrosine phosphorylation [13].

The story starts with the discovery of tyrosine phosphorylation by Tony Hunter's lab in 1979 and the ensuing realization that it is key to major transmembrane signal transmission mechanisms frequently hijacked by tumors [14]. Immediately flagging them as potential anti-cancer targets, research subsequently focused on small molecule inhibitors of oncogenic tyrosine kinases (TK), but the path from bench to bedside proved to be long. Brian Druker's team

was the first to succeed with the approval of imatinib for the treatment of chronic myelogenous leukemia (CML) in 2001 [15]. In parallel, John Mendelsohn and his colleagues worked on the development of antibodies to block the tyrosine kinase signaling, an equally long but fruitful trail that led to the release of cetuximab for cancer colon therapy in 2004 [16]. The search for specific TK inhibitors continues undamped, presently striving to integrate multi-omics and the concept of personalized medicine in order to optimize the patient's treatment response.

Original articles

Risks and outcomes of *Clostridium difficile* infection in a hospital setting

C. difficile is a bad competitor - as long as a healthy microbiotum is in place, the pathogen is usually kept in check [17]. However, once the latter is disrupted, as a consequence of lifestyle or medical treatment, *C. difficile* can cause persistent disease ranging from mild diarrhea to life-threatening pseudomembranous colitis [18]. Thereby it has successfully

acquired the infamous title of number one hospital acquired infection (12,1%) and the global incidence of *C. difficile* infection (CDI) is on the rise [19]. Facing the frequency of infection relapse, fecal microbiota transplantation might be sometimes the last hope for cure [20]. In their study, Lee et al. aim to identify risk factors for CDI, the associated mortality rate and to put forward possible prevention methods [21]. They observe that underlying peptic ulcer disease and previous use of gastric acid inhibitors or third generation cephalosporins for at least 3 days significantly correlate with CDI. Mortality was only linked to overall Charlson scores however. The authors strongly recommend to base CDI treatment rather on Charlson scores than CDI-specific parameters, as underlying diseases play an equally important role in the treatment outcome.

Mean platelet volume measurements could improve the early diagnosis of acute coronary syndrome

Acute coronary syndrome (ACS) reflects the reduction in blood flow in the coronary arteries usually after atheroma rupture or erosion resulting in the formation of a thrombus [22]. The direct consequence being malfunction and/or necrosis of the heart muscle, every minute counts in making the correct diagnosis and starting treatment [23]. Currently, electrocardiogram (ECG) characteristics and cardiac Troponin I and T are the main, yet not foolproof, diagnostic checkpoints. Consequently, additional biomarkers that are fast and easy to obtain would be beneficial in order to avoid both under- and misdiagnoses. ACS is a consequence of atherothrombosis and the latter involves the activation of platelets, which in turn correlates with an increase in mean platelet volume (MPV) and immature platelet fraction (IPF). Here, Huang et al. interrogate the diagnostic value of these two parameters in confirming ACS [24]. Indeed, according to a retrospect study, both are higher in ACS patients and MPV could be used as an independent predictor of ACS diagnosis.

Description and trouble-shooting of ultrasonic motor-induced artifacts in magnetic resonance imaging

Combining magnetic resonance imaging (MRI) with robot-assisted interventions should improve accuracy, stability and sampling reproducibility targeting during surgery [25]. However, the synergy is challenged by inherent features of the robot, such as actuators and sensors, which tend to interfere with the MRI instrument [26]. Ultrasonic motors (USMs) are nonmagnetic devices optimized for the use in surgical robots [27,28], yet some limitations due to various image artifacts still remain [29]. In the present article, Shokrollahi et al. aim at identifying the type and origin of USM-caused MRI image artifacts and the means to minimize them [30]. The authors observe signal voids, pileups, geometric distortions as well as zipper and motion artifacts. Aligning the motor shaft with the bore axis, decreasing slice thickness, augmenting bandwidth and ultra-short echo time sequences partially corrected several artifacts.

Advanced ankylosing spondylitis patients display imbalanced loss of trunk muscle strength

Ankylosing spondylitis (AS) is an incurable auto-inflammatory systemic rheumatic disease with strong genetic association,

notably the HLA-B27 genotype [31], mainly affecting the joints of the spine and affecting up to 1,8% of the population. Progressing disease can lead to the ossification of the vertebrae and the fusion of the spine, severely impacting quality of life. Decrease of muscle mass and strength are other disease manifestations but also therapeutic targets.

Wang et al. search to characterize the trunk isometric strength and the ratio of flexor and extensor strength at varying trunk postures in AS patients at different disease stages [32]. Patients of the most advanced AS stages displayed lowest isometric trunk muscle strength as well as greater loss in extensor than flexor muscle strength. Consequently, the authors recommend a strengthening program focusing on the extensor muscles.

General endotracheal anesthesia is suitable for ERCP-assisted biliary stone removal

Endoscopic retrograde cholangiopancreatography (ERCP) is an invasive procedure combining upper gastrointestinal endoscopy and X-rays to treat narrowed or blocked bile and pancreatic ducts, for instance because of gallstones [33]. Liang et al. investigate here via a retrospective study the safety, rate of success and possible complications of performing ERCP-assisted biliary stone extraction either with conscious, local sedation (NS) or under general endotracheal anesthesia (GET) [34]. According to their results, the GET group had a higher success rate of complete stone extraction with smaller required rates of contrast injection but a slightly higher risk to develop pneumonia due to the tracheal intubation after the procedure. Preventive strategies could further lower the risk of the latter.

Conflicts of interest

The author declares no conflict of interests.

REFERENCES

- [1] Maspero C, Giannini L, Galbiati G, Rosso G, Farronato G. Obstructive sleep apnea syndrome: a literature review. *Minerva Stomatol* 2015;64:97–109.
- [2] Semelka M, Wilson J, Floyd R. Diagnosis and treatment of obstructive sleep apnea in adults. *Am Fam Phys* 2016;94:355–60.
- [3] Shastri A, Bangar S, Holmes J. Obstructive sleep apnoea and dementia: is there a link? *Int J Geriatr Psychiatry* 2016;31:400–5.
- [4] Lin HC, Weaver EM, Lin HS, Friedman M. Multilevel obstructive sleep apnea surgery. *Adv Otorhinolaryngol* 2017;80:109–15.
- [5] Li HY, Lee LA, Hsin LJ, Fang TJ, Lin WN, Chen HC, et al. Intraparyngeal surgery with integrated treatment for obstructive sleep apnea. *Biomed J* 2019;42:84–92.
- [6] Chhabra G. Automated hematology analyzers: recent trends and applications. *J Lab Phys* 2018;10:15–6.
- [7] Purohit AHL, Kumar P, Sharma S, Kapil A, Gupta A, Mukhopadhyay AK. Volume, conductivity, and scatter parameters as diagnostic aid to bacterial sepsis: a tertiary care experience. *Indian J Pathol Microbiol* 2015;58:459–63.

- [8] Sharma P, Bhargava M, Sukhachev D, Datta S, Wattal C. LH750 hematology analyzers to identify malaria and dengue and distinguish them from other febrile illnesses. *Int J Lab Hematol* 2014;36:45–55.
- [9] Choccalingam C. Volume, conductance, and scatter parameters of neoplastic and nonneoplastic lymphocytes using Coulter LH780. *J Lab Phys* 2018;10:85–8.
- [10] Gaspar BL, Sharma P, Varma N, Sukhachev D, Bihana I, Naseem S, et al. Unique characteristics of leukocyte volume, conductivity and scatter in chronic myeloid leukemia. *Biomed J* 2019;42:93–8.
- [11] Kaleem B, Shahab S, Ahmed N, Shamsi TS. Chronic myeloid leukemia—prognostic value of mutations. *Asian Pac J Cancer Prev* 2015;16:7415–23.
- [12] Priyanka A, Pophali MMP. The role of new tyrosine kinase inhibitors in chronic myeloid leukemia. *Cancer J* 2016;22:40–50.
- [13] Yu JS. From discovery of tyrosine phosphorylation to targeted cancer therapies: the 2018 Tang prize in biopharmaceutical science. *Biomed J* 2019;42:80–3.
- [14] Hunter T. The genesis of tyrosine phosphorylation. *Cold Spring Harb Perspect Biol* 2014;6:a020644–4.
- [15] Druker BJ. Imatinib: a viewpoint by brian. *J Druker Drugs* 2001;61:1775–6.
- [16] Mendelsohn J. EGF receptors as a target for cancer therapy. *Trans Am Clin Climatol Assoc* 2004;115:249–53. Discussion 253–4.
- [17] Crobach MJT, Vernon JJ, Loo VG, Kong LY, Péchiné S, Wilcox MH, et al. Understanding *Clostridium difficile* colonization. *Clin Microbiol Rev* 2018;31:e00021–17.
- [18] Kristin E, Burke JTL. *Clostridium difficile* infection: a worldwide disease. *Gut Liver* 2014;8:1–6.
- [19] Monegro AF, Regunath H. Hospital acquired infections. Treasure Island (FL): StatPearls Publishing; 2019.
- [20] Heath RD, Cockerell C, Mankoo R, Ibdah JA, Tahan V. Fecal microbiota transplantation and its potential therapeutic uses in gastrointestinal disorders. *North Clin Istanbul* 2018;5:79–88.
- [21] Lee HY, Hsiao HL, Chia CY, Cheng CW, Tsai TC, Deng ST, et al. Risk factors and outcomes of *Clostridium difficile* infection in hospitalized patients. *Biomed J* 2019;42:99–106.
- [22] Pagidipati NJ, Peterson ED. Acute coronary syndromes in women and men. *Nat Rev Cardiol* 2016;13:471–80.
- [23] Switaj TL, Christensen SR, Brewer DM. Acute coronary syndrome: current treatment. *Am Fam Phys* 2017;95:232–40.
- [24] Huang HL, Chen CH, Kung CT, Li YC, Sung PH, You HL, et al. Clinical utility of mean platelet volume and immature platelet fraction in acute coronary syndrome. *Biomed J* 2019;42:107–15.
- [25] Kettenbach J, Kronreif G, Melzer A, Fichtinger G, Stoianovici D, Cleary K. Ultrasound-, CT- and MR-guided robot-assisted interventions. *Image processing in radiology*, vol. 69. Berlin, Heidelberg: Springer; 2008. p. 393–409.
- [26] Macura KJ, Stoianovici D. Advancements in magnetic resonance-guided robotic interventions in the prostate. *Top Magn Reson Imag* 2008;19:297–304.
- [27] Tavallaei MA, Johnson PM, Liu J, Drangova M. Design and evaluation of an MRI-compatible linear motion stage. *Med Phys* 2016;43:62–71.
- [28] Nofiele J, Yuan Q, Kazem M, Tatebe K, Torres Q, Sawant A, et al. An MRI-compatible platform for one-dimensional motion management studies in MRI. *Magn Reson Med* 2016;76:702–12.
- [29] Shokrollahi P, Drake JM, Goldenberg AA. Ultrasonic motor-induced geometric distortions in magnetic resonance images. *Med Biol Eng Comput* 2018;56:61–70.
- [30] Shokrollahi P, Drake JM, Goldenberg AA. A study on observed ultrasonic motor-induced magnetic resonance imaging (MRI) artifacts. *Biomed J* 2019;42:116–23.
- [31] Hanson A, Brown MA. Genetics and the causes of ankylosing spondylitis. *Rheum Dis Clin* 2017;43:401–14.
- [32] Wang CM, Hong WH, Ho HH, Chen JY, Tsai YL, Pei YC. Features of trunk muscle weakness in patients with ankylosing spondylitis: a cross-sectional study. *Biomed J* 2019;42:124–30.
- [33] Yuen N, O'Shaughnessy P, Thomson A. New classification system for indications for endoscopic retrograde cholangiopancreatography predicts diagnoses and adverse events. *Scand J Gastroenterol* 2017;52:1457–65.
- [34] Liang CM, Kuo CM, Lu LS, Wu CK, Tsai CE, Kuo MT, et al. A comparison between non-sedation and general endotracheal anesthesia for retrograde endoscopic common bile duct stone removal: a tertiary center experience. *Biomed J* 2019;42:131–6.