



Case report

Laparoscopic relief of reduction en-masse in an inguinal hernia: A case report

Bahador Oshidari^a, Manoochehr Ebrahimian^{a,*}, Mobin Nakhaei^a, Negin Ghayebi^b^a Department of General Surgery, Loghman Hakim Hospital, Shahid Beheshti University of Medical Sciences, Tehran, Iran^b School of Medicine, Shahid Beheshti University of Medical Sciences, Tehran, Iran

ARTICLE INFO

Keywords:

Inguinal hernia
 Reduction en-masse
 Laparoscopy
 Transabdominal preperitoneal
 Hernioplasty
 Case report

ABSTRACT

Introduction and importance: Reduction en-masse is an extremely rare condition that usually develops in prolonged hernias. Spontaneous or iatrogenic reduction of this type of hernia may lead to disastrous consequences such as obstruction, gangrene, or peritonitis. According to the reports so far, surgical management is the only choice for this condition.

Presentation of case: In this paper, we report a 48-year-old man who presented with vague abdominal pain and a history of inguinal hernia for years and had reduced his hernia five days earlier. Computed tomography (CT) and ultrasonography confirmed the diagnosis, and the patient was taken to the operating room to relieve the bowel loop utilizing laparoscopy.

Conclusion: Laparoscopic relief could be an effective tool in diagnosis and surgery of reduction en-masse. Transabdominal preperitoneal repair is the best choice due to its capability to explore the intraabdominal organs and its low risk of recurrence.

1. Introduction

The reduction en-masse of inguinal hernia is a highly rare condition in which an incarcerated or strangulated hernia returns to the inguinal canal with the surrounding peritoneum without any actual relief. “en-masse” meaning altogether, was first described by Barthélemy Saviard, a French surgeon, in 1702. In 1965, Mings et al. reviewed over 200 cases of en-masse hernia. Since then, a few cases have been reported.

Reduction en-masse causes the intestinal loop to remain in a strangulated or incarcerated condition inside the abdominal cavity, finally leading to obstruction, ischemia, gangrene, or peritonitis. Therefore, it can be a fatal condition if not diagnosed and treated correctly [1].

Thus early diagnosis and proper management of this condition are essential steps to prevent further catastrophic ischemia and complications. This work has been reported based on SCARE 2020 guidelines [2].

2. Presentation of case

A 48-year-old man with vague periumbilical pain that had started three days earlier, presented to the emergency department. He was a non-smoker, and had no underlying disease other than left inguinal

hernia. He mentioned that he had noticed a bulging in the groin two years earlier; but had not sought any medical attention. The patient stated that the bulging had reduced spontaneously but got stuck about five days before the visit to the hospital; however, he pushed it inside by force. After that, the patient developed abdominal pain, especially around the belly button, and the pain increased and caused his visit to the hospital. The patient did not report nausea or vomiting, but his defecation was markedly reduced. Abdominal tenderness was not present, based on physical examination. He was of medium size with a normal Body Mass Index (BMI = 23.6 kg/m²). Also, digital rectal examination showed an empty vault without any signs of mucosal sloughing. Laboratory data showed an increased white blood count (12.3 × 10³ units/mm³) with neutrophil dominancy. Hemoglobin level was normal, and arterial blood gas did not indicate any abnormality.

Radiologic studies were performed, and multiple air-fluid levels were found in small bowels in upright abdominal radiogram (Fig. 1). In addition, ultrasonography showed a round hypo-echoic lesion in the left lower quadrant of the abdomen that did not have vascular flow, suggesting an entrapped small bowel loop (Fig. 2). Based on the above findings, we decided to perform a CT scan. In the abdominopelvic CT with intravenous and oral contrast, we found a high-grade small bowel

* Corresponding author at: Department of General Surgery, Loghman Hakim Hospital, Shahid Beheshti University of Medical Sciences, Tehran, Iran.

E-mail addresses: dr.bahador.oshidari@sbmu.ac.ir (B. Oshidari), manoochehrehbrahimian@sbmu.ac.ir (M. Ebrahimian).

obstruction due to a closed loop with a diameter of 44 mm around the left internal inguinal canal (Fig. 3).

Finally, after 6 h, the patient was taken to the operating theatre with the possible diagnosis of intra-abdominal incarcerated hernia, so-called “Reduction en-masse”.

First, exploratory laparoscopy was performed to evaluate the intra-abdominal organs. After a precise exploration, a ball-like mass consisting of a jejunal loop was found near the left internal inguinal canal (Indirect Hernia). The mass was wrapped with peritoneal layers, and the reduction en-masse diagnosis was confirmed clinically. All the bowel loops proximal to the transition zone were dilated. With the aid of electrocautery, the surrounding peritoneum was incised, and the incarcerated closed loop was liberated (Fig. 4). The involved loop had a slightly bluish color, but its peristaltic movement suggested a viable bowel loop. In the next step, a 10 × 7 cm polypropylene mesh was placed on the internal ring and covered by adjacent peritoneum (TAPP).

The insufflated gas was drained, the ports were removed, and the patient returned to the surgery ward.

On the first day, the oral regimen started and the patient was discharged two days later, after which no complications or problems were reported.

3. Discussion

Reduction en-masse of inguinal hernia is a rare entity in which has been reported about 200 cases so far. After Mings et al. [1], who reviewed over 200 cases in 1965, more than fifteen cases reported until today [3]. Due to the lack of cases, it is not possible to estimate the exact prevalence of the disease, but it seems that it occurs in 1 in 13,000 hernias [1,3].

Described by Saviard in 1702, reduction en-masse is a condition in which incarcerated or strangulated inguinal hernia does not reduce properly into the abdominal cavity, and the inguinal mass with all of its surrounding envelopments reduces inappropriately into the preperitoneal space [1]. The leading cause of this entity is not understood well until now [1,3,4], but logically, prolonged asymptomatic incarceration develops fibrotic changes in both bowel and sac tissue, and the trapped bowel cannot move freely inside the sac. Finally, these fibrotic changes may occur at the neck of the sac, but the neck is not tight enough to develop ischemia. Fibrotic changes continue until the neck becomes

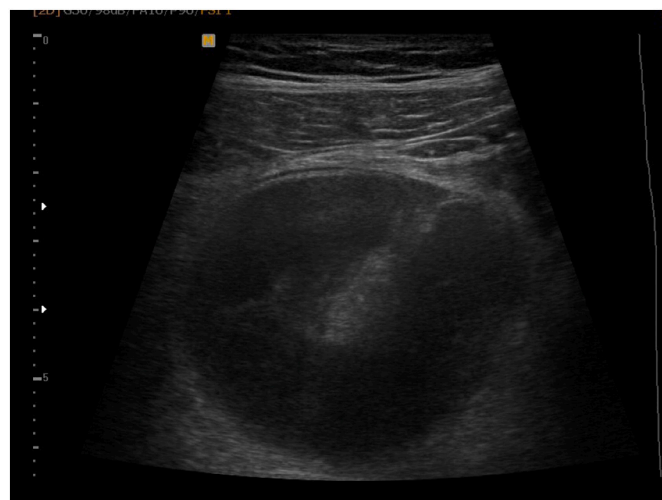

Fig. 2. Transabdominal ultrasonography shows a ball-like loop of small intestine.

more tighter and the ischemic process begins.

Typically the patients develop abdominal pain regardless of a successful reduction [3]. Reduction may be done spontaneously or with the aid of a physician. It is reported that about 60% of cases are iatrogenic or by forcible taxis by the patient; while spontaneous reduction en-masse occurs in 35% of cases [4]. Our reported case intended to reduce his hernia forcibly.

The mainstay of diagnosis is accurate history taking and physical examination. Small bowel obstruction signs and symptoms usually occur in typical cases. Although no specific sign is described for this problem, Barker and Smiddy in 1970 stated that traction of the testicles could lead to iliac fossa pain. It should be noted that this sign is not a famous sign between clinicians, and we didn't check this sign in our case [5].

Several studies used CT to confirm diagnosis [4–9] and it seems that CT findings such as ball-like bowel loop adjacent to the inguinal canal can lead to the correct diagnosis even without knowing the clinical information [10]. In almost every reported case, authors used CT for the diagnosis. Although non-contrast CT is fast and can be interpreted by

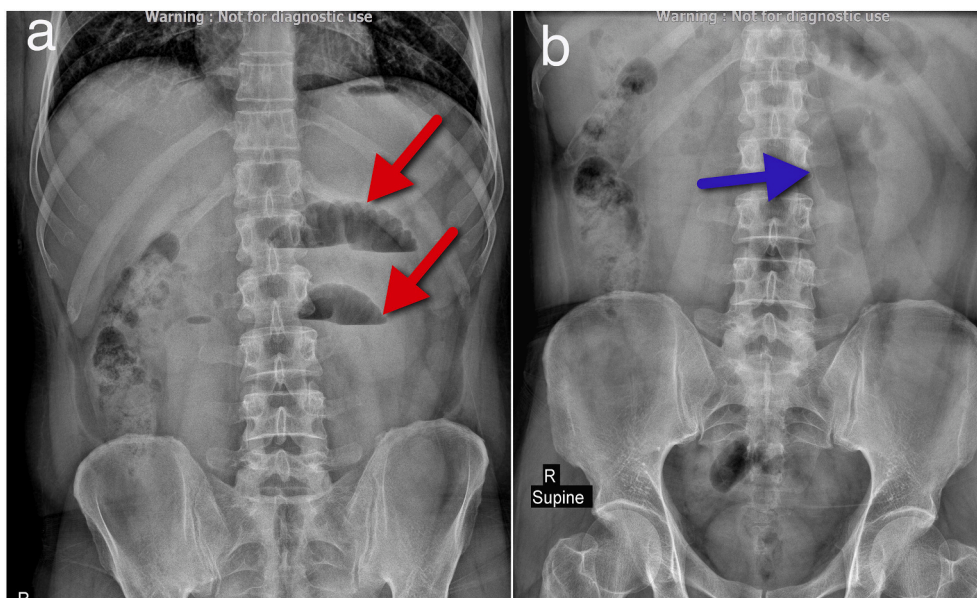


Fig. 1. Plain abdominal radiographs. a) multiple air-fluid levels is shown (red arrows) in upright x-ray. b) small bowel loop with a “stack of coins” sign is indicated (blue arrow). (For interpretation of the references to color in this figure legend, the reader is referred to the web version of this article.)

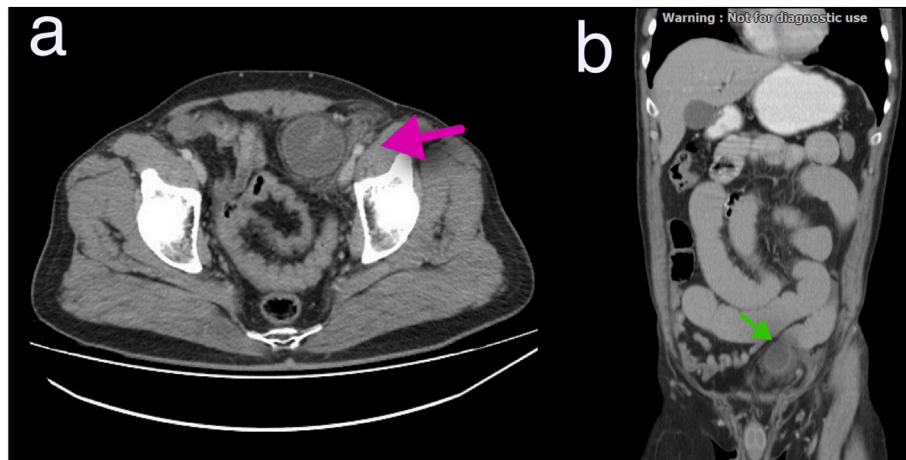


Fig. 3. CT images of the patient. a) a ball-like loop of jejunum (pink arrow) in the left lower quadrant is seen in axial view. b) coronal views shows the same features. (For interpretation of the references to color in this figure legend, the reader is referred to the web version of this article.)

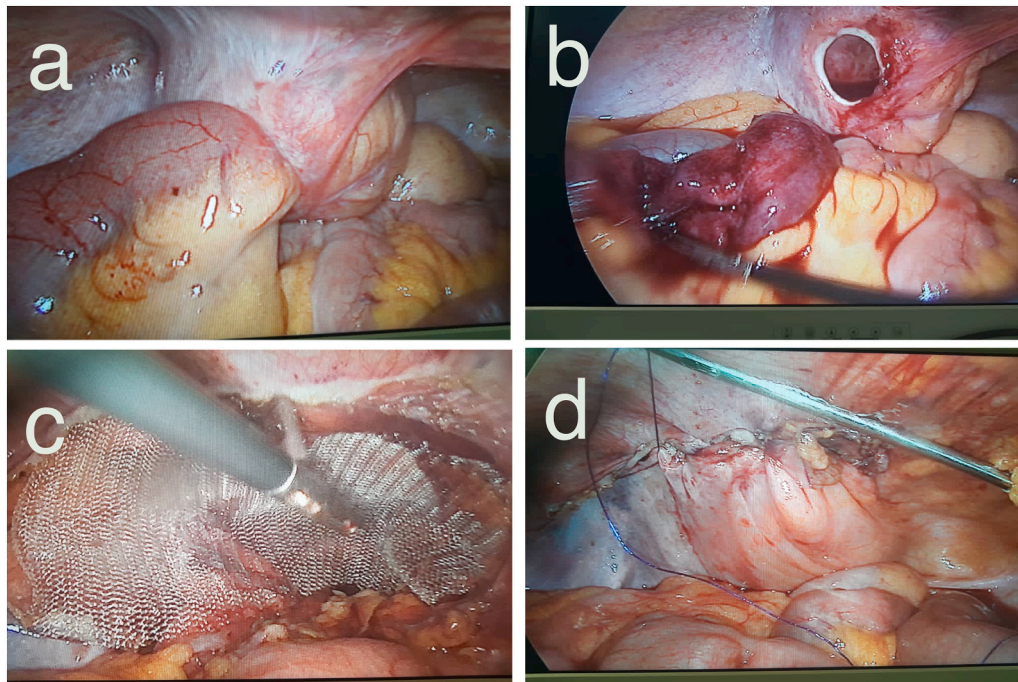


Fig. 4. Images of the surgery. a) ball-like structure containing jejunum loops. b) Relieved bowel loop with a bluish color near the fibrotic sac's neck. c) a polypropylene mesh placed on the internal ring. d) adjacent peritoneum covers the mess with continuous running sutures (TAPP).

surgeons, there are some disadvantages like irradiation and dissatisfaction of patients. On the other hand, there is not much information about ultrasonography findings. In our case, we performed transabdominal ultrasonography, which showed a hypoechoic ball-like mass in the left lower quadrant. This finding accompanied by clinical information may be helpful to confirm the diagnosis, but further studies are required to prove the usability of ultrasound in this matter.

Surgical management is the only option for the treatment of reduction en-masse. Traditionally, inguinal incisions and midline incisions are used to evaluate and treat this condition [1]. The surgeon needs to liberate the trapped bowel, evaluate the involved loop's viability, and decide based on the situation. If the bowel loop is viable, the only step is to repair the hernia. Still, in a situation in which the viability of the bowel is not acceptable, the involved bowel must be resected. However, in cases that develop peritonitis or gangrenous bowel, synthetic mesh may act as a biofilm and cause further infections. Given that there is a

lack of data about the repair of laparoscopic inguinal hernia without mesh, it is better to convert to laparotomy in these cases. Laparoscopy is a valuable tool in diagnosing and treating the disease because in suspicious cases, it helps the surgeon to explore the abdominal cavity and even can be used as a safe method to relieve the entrapped bowel. Several laparoscopic approaches have been reported so far [6–10], and all the studies stated that Transabdominal Preperitoneal (TAPP) repair is the best choice of laparoscopic hernia repair in this context. In fact, other approaches like Totally Extraperitoneal (TEP) are not possible because in these cases, we need to evaluate precisely the whole abdomen. On the other hand, Open Intraoperative Onlay Mesh (IPOM) is associated with a higher recurrence rate [11]. However, laparotomy seems more feasible in emergent circumstances, especially when the patient develops abdominal signs of peritonitis. Also, there are some known contraindications for laparoscopic surgery. Conditions like coagulopathy, chronic obstructive pulmonary disease (COPD), and heart

failure with reduced ejection fraction (HFrEF) are known contraindications [12]. Therefore, in cases in which dilated bowel loops or intra-abdominal adhesions may disturb the surgeons' vision, it is better to convert to laparotomy.

4. Conclusion

Reduction en masse should be considered when abdominal pain lingers after a forceful reduction of inguinal hernia, especially in chronic cases. The use of ultrasonography and CT can help the clinician to diagnose the disease earlier. The laparoscopic approach could be an appropriate diagnostic and therapeutic choice for the management of this disease.

Sources of funding

The authors did not receive any financial support for this report.

Ethical approval

This article does not contain any studies with human participants or animals performed by any of the authors.

Consent

Written informed consent was obtained from the patient for publication of this case report and accompanying images. A copy of the written consent is available for review by the Editor-in-Chief of the journal on request.

Registration of research studies

Not applicable.

Provenance and peer review

Not commissioned, externally peer-reviewed.

Guarantor

Dr. Manoochehr Ebrahimian.

CRedit authorship contribution statement

BO: Study design and Operation. MN: Case presentation. ME: Data gathering. NG: Writing manuscript.

All authors read and approved the final manuscript.

Declaration of competing interest

The authors declared no potential conflict of interests with respect to the research, authorship, and/or publication of this article.

Acknowledgments

I wish to extend my special thanks to Dr. Mohammad Ali Moradi who helped us as an assistant in the surgery.

References

- [1] H. Mings, J.D. Olson, Reduction en masse of groin herniae, *Arch. Surg.* 90 (5) (1965) 764–769.
- [2] R.A. Agha, T. Franchi, C. Sohrabi, G. Mathew, A. Kerwan, A. Thoma, et al., The SCARE 2020 guideline: updating consensus surgical CAse REport (SCARE) guidelines, *Int. J. Surg.* 84 (2020) 226–230.
- [3] M.R. Sahoo, A. Kumar, Laparoscopic management of reduction-en-masse, *Case Rep.* (2012) 1–3, <https://doi.org/10.1136/bcr-2012-007919>.
- [4] C.-C. Wu, J.-C. Kang, Y.-M. Huang, Laparoscopic transabdominal preperitoneal hernioplasty for reduction en masse of an incarcerated inguinal hernia: a case report, *J. Gastrointest. Surg.* 16 (7) (2012) 1433–1435.
- [5] D. Watkin, Groin hernias in the adult presenting as emergencies, in: *Abdominal Wall Hernias*, Springer, 2001, pp. 560–568.
- [6] T. Arima, K. Muroya, K. Kawamoto, Y. Koba, T. Omura, Laparoscopic relief of reduction en masse followed by elective preperitoneal inguinal hernia repair with modified Kugel™ patch, *Int. J. Surg. Case Rep.* 50 (2018) 97–99.
- [7] Y. Cao, A. Kohga, A. Kawabe, K. Yajima, T. Okumura, K. Yamashita, et al., Case of reduction en masse who presented with no symptoms, *Asian J. Endosc. Surg.* 12 (2) (2019) 207–210.
- [8] A. Hoshino, Y. Kawachi, S. Takamatsu, H. Nagano, S. Ohtsukasa, S. Kato, et al., Reduction en masse can be treated using pure laparoscopic transabdominal preperitoneal hernioplasty following early CT diagnosis: report of a case, *J. Surg. Case Rep.* (5) (2015), rjv055.
- [9] Y. Kaiwa, K. Namiki, H. Matsumoto, Laparoscopic relief of reduction en masse of incarcerated inguinal hernia, *Surg. Endosc.* 17 (2) (2002) 352.
- [10] M. Kitami, T. Yamada, T. Ishii, M. Tsuboi, T. Hakamatsuka, K. Takase, et al., CT findings of “reduction en masse” of an inguinal hernia, *Eur. J. Radiol. Extra.* 67 (3) (2008), e111–e4.
- [11] E. Phillips, M. Arregui, B. Carroll, J. Corbitt, W. Crafton, M. Fallas, et al., Incidence of complications following laparoscopic hernioplasty, *Surg. Endosc.* 9 (1) (1995) 16–21.
- [12] S.P. Bowers, J.G. Hunter, Contraindications to laparoscopy, in: *The Sages Manual*, Springer, 2006, pp. 25–32.