

Analysis of a Refractory Case of Pediatric Meningitis Caused by *Klebsiella pneumoniae* Co-Resistant to Carbapenems and Polymyxins

Xu Huang¹, Mingxiao Han², Fei Jin³, Zhichen Zhu², Haifang Zhang²

¹Department of Clinical Laboratory, Children's Hospital of Nanjing Medical University, Nanjing, People's Republic of China; ²Department of Clinical Laboratory, The Second Affiliated Hospital of Soochow University, Suzhou, People's Republic of China; ³Department of Laboratory, The First Affiliated Hospital of Nanjing Medical University, Nanjing, People's Republic of China

Correspondence: Haifang Zhang, The Second Affiliated Hospital of Soochow University, 1055 Sanxiang Road, Suzhou, Jiangsu, People's Republic of China, Tel +86 512 67783550; +86 18896808917, Email haifangzhang@suda.edu.cn

Abstract: We report our clinical exploration experience treating a 6-year-old girl with a postoperative central nervous system (CNS) infection of prolonged invasion with *Klebsiella pneumoniae* (*K. pneumoniae*) co-resistant to carbapenems and polymyxin B. Although rational antibiotic therapy and effective source control measures were applied, the infection was not controlled eventually. To understand the mechanism of infection, whole-genome sequencing (WGS) was used to explore the resistance mechanism, and the susceptibility test was used to observe the efficacy of ceftazidime–avibactam (CAZ-AVI) in vitro. It is currently uncertain whether CAZ-AVI could be used as a salvage therapy for pediatric CNS infection. Therefore, we hope to share this case to seek medical help worldwide to treat pediatric CNS infection.

Keywords: central nervous system, co-resistant to carbapenems and polymyxin B, *Klebsiella pneumoniae*, whole-genome sequencing, ceftazidime–avibactam

Introduction

Pediatric CNS infection caused by *K. pneumoniae* co-resistant to carbapenems and polymyxin B remains challenging to treat. In many previous cases, a combination of intravenous (IV) and intraventricular (IVT) polymyxin B achieved good therapeutic prognosis in CNS infection.^{1,2} Moreover, the novel β -lactam- β -lactamase inhibitor (β L- β LI) agents are becoming the last saving straw with the advent of polymyxin B-resistant isolates. CAZ-AVI as a potential alternative agent has attracted more and more attention in recent years. Avibactam is a β -lactamase inhibitor that exhibits activity against most KPC.³ The clinical usage experience of CAZ-AVI is very limited due to the lack of scientific guidelines and pediatric reference data in CNS infection. Herein, we report a refractory case of pediatric post neurosurgical meningitis caused by co-resistant to carbapenems and polymyxin B *K. pneumoniae*. Ethical approval of this study was obtained from the ethics committee of Children's Hospital of Nanjing Medical University, and we obtained the consent from patient's parents for the publication of this case.

Case Presentation

A 6-year-old girl developed meningitis 1 week after intracranial injury surgery. She was transferred to the surgical intensive care unit (SICU) of Children's Hospital of Nanjing Medical University (Nanjing, China) due to a persistent high fever. Upon arrival at the hospital, the patient was initially treated empirically for 3 days with meropenem (0.88 g IV q8 hours) plus vancomycin (0.22 g IV q6 hours). Three days later, the cerebrospinal fluid (CSF) culture results showed multidrug-resistant (MDR) *K. pneumoniae*. The antimicrobial susceptibility assay did not provide the sensitive or resistant data for polymyxin and tigecycline due to the limitations of the clinical laboratory. Even though the antimicrobial therapy was changed to meropenem (0.85 g IV q8 hours) plus polymyxin B (24 mg IV q12 hours) and polymyxin B (2 mg IVT qd) for nearly 3 weeks, the severe intracranial infection had not been controlled and the re-cultures of CSF showed the growth of MDR *K. pneumoniae*. On day 22, the CSF was sent to the First

Affiliated Hospital of Nanjing Medical University (Nanjing, China) for further analysis of antimicrobial susceptibility, and the results showed that the MDR *K. pneumoniae* isolate named 20JS63 was only sensitive to tigecycline (≤ 1 mg/L), but resistant to meropenem (≥ 128 mg/L), imipenem (≥ 128 mg/L), even colistin (≥ 64 mg/L). Thus, the clinicians switched the therapy to meropenem (0.85 g IV q8 hours) plus tigecycline (25 mg IV q12 hours) and added meropenem (5 mg IVT qd) plus tigecycline (4 mg IVT qd) the next day. Accompanied by the insignificant therapeutic effect of dual therapy, the patient manifested a persistent high fever up to 40.3°C and a severe CNS infection. Overall, inflammatory markers (PCT, CRP, WBC count and neutrophilic granulocyte percentage (NEUT%) in his peripheral blood) also peaked during this time (Figure 1). On day 37, polymyxin B was added at a dose of 25 mg IV q12 hours to triple therapy based on dual therapy. Because the local pus in the patient's skull was thick and difficult to drain, the ventricles were irrigated with tigecycline (50 mg qd) and continuous bilateral ventricles drainage to maintain the stability of the brain environment. On day 50, meropenem was replaced with aztreonam (0.65 g IV q8 hours) because long-term use of meropenem leads to changes in cell membrane protein and diminishes the antimicrobial effect. The patient's temperature was maintained under continuous ventricular irrigation and drainage, but she had not achieved a clinical or microbiological cure. On day 69, her parents chose to discontinue treatment and the patient was discharged after the consultation with the parents.

To increase the valuable clinical experience and explore the possibility of anti-infective therapy, we carried out further research on the isolate 20JS63. The entire genomic DNA of the *K. pneumoniae* 20JS63 was sequenced and deposited in the GenBank database under accession number JAKEDZ000000000. This *K. pneumoniae* 20JS63 belonged to sequence type 11 (ST11), which harboured antibiotic resistance genes including *kpc-2*, *CTX-M-65*, *SHV-11*, *TEM-1B*, *rmtB*, *qnrS1*, *tetA*, and *dfpA14*. Circos (the version number: 0.69) was used to make a circular map of the bacterial genome so that the drug resistance genes can be visualized on the bacterial genome (Figure 2A). In addition, this strain contained virulence genes, including *lutA* and *rmpA*. Noteworthy, the isolate possessed a mutated *pmrB* gene, which encoded the PmrB protein in PmrAB two-component

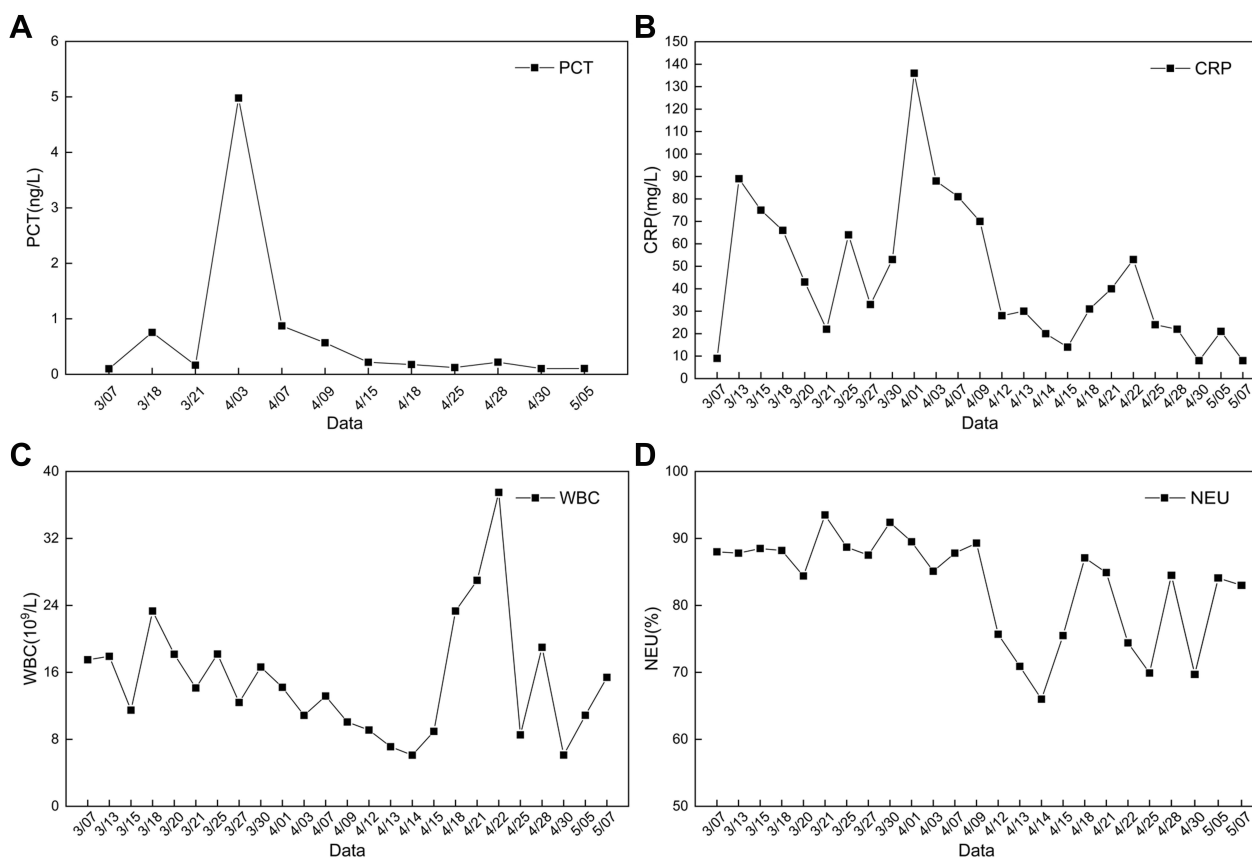


Figure 1 Clinical course of the patient. **(A)** PCT in the peripheral blood. **(B)** CRP in the peripheral blood. **(C)** White blood cell (WBC) count in the peripheral blood. **(D)** Neutrophil percentage (NEUT%) in the peripheral blood.

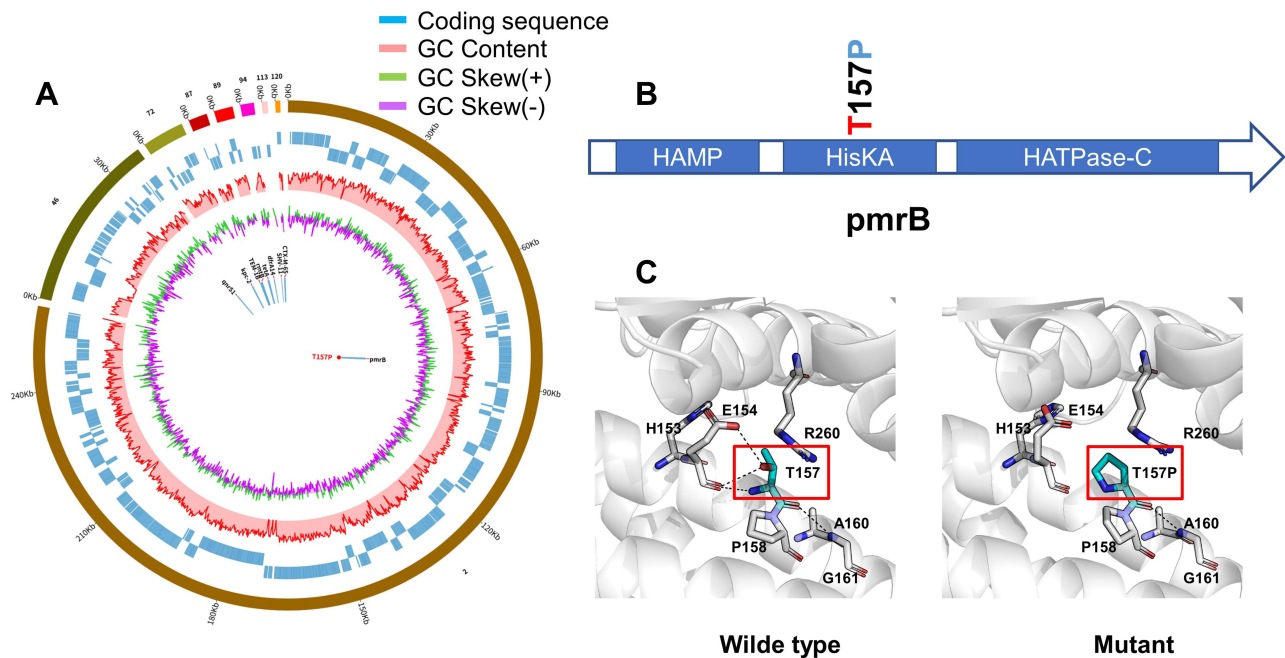


Figure 2 Mechanisms of resistance. **(A)** Genomic map of *K. pneumoniae* 20J563 harbored antibiotic resistance genes including *kpc-2*, *CTX-M-65*, *SHV-11*, *TEM-1B*, *rmtB*, *qnrS1*, *tetA*, and *dfrA14*. **(B)** Position of mutation in *pmrB* gene conferring colistin resistance. **(C)** Interatomic interaction between residue at the 157 (red mark) position and neighbor residue of both wild- and mutant-type PmrB protein.

system. The mutant *pmrB* gene detected in this isolate differed from the wild type featured a single threonine to proline amino acid substitution at position 157 (Figure 2B). DynaMut web server (<http://biosig.unimelb.edu.au/dynamut/>) was used to analyze the effect of mutation on structure of mutated PmrB protein (Figure 2C). This genetic alteration is known to be responsible for acquired polymyxin B resistance in *K. pneumoniae*. CAZ-AVI was launched on 21 May 2019 in China after the hospitalization period of this patient (7 March to 14 May 2019). The E-test of CAZ-AVI was performed after the case, and the result showed that this isolate was sensitive to ceftazidime–avibactam (≤ 0.125 mg/L) in vitro.

Discussion

Healthcare-associated ventriculitis and meningitis are evolving occurrence due to the increasing rates of neurosurgery procedures. MDR *K. pneumoniae* intracranial infection associated with high morbidity and mortality needs more comprehensive therapeutic approaches to improve clinical prognosis.⁴ Although clinicians had integrated IV and IVT antibiotic administration plus strengthened thorough ventricular irrigation, the prognosis of this patient is still poor. The reasons may be aggressive infection source, limited treatment choice or the host itself.

This isolate is polymyxin B-resistant *kpc-2*-producing *K. pneumoniae*. It is worth mentioning that the isolate possessed a mutated *pmrB* gene that differed from the wild type featured a single threonine to proline amino acid substitution at position 157. This genetic alteration responsible for acquired polymyxin B resistance can be traced back to a multi-laboratory collaborative study in 2014.⁵ In addition, this isolate belongs to ST11 harboured virulence-related determinants (*lutA* and *rmpA*). A series of studies clarified that ST11-hv-carbapenem-resistant *Klebsiella pneumoniae* (CRKP) could cause higher mortality of infected patients in China.^{6–9} So we speculate that this isolate is closely related to our patient's severe infection symptoms and long-term incurable outcome.

Pediatric post-neurosurgical meningitis caused by co-resistant carbapenems and polymyxins *K. pneumoniae* is rare worldwide. This 6-year-old child patient with a CNS infection provides a massive challenge for clinical treatment. We encountered the following difficulties during the treatment of such a case. Firstly, there are no pediatric guidelines for the treatment of *K. pneumoniae* co-resistant carbapenems and polymyxins. Although the Infectious Diseases Society of America (IDSA) Standards and Practice Guidelines Committee issued a guideline named 2017 Infectious Diseases Society of America's Clinical

Practice Guidelines for Healthcare-Associated Ventriculitis and Meningitis, the guideline does not cover the therapy of polymyxin B-resistant CRKP in children.¹⁰ In this case, the pediatric patient was threatened by the embarrassing situation with no cure, and clinicians had no choice but to treat this patient empirically with dual and triple therapy. At this stage, there is an urgent need to optimize and update the pediatric guidelines for the absence of the treatment against polymyxin B-resistant CRKP. In the course of the case, clinicians used polymyxin B as a conventional lifesaver against superbugs at first, but the emergence of polymyxin B resistance prompted clinicians to use tigecycline as a last therapeutic option. Unfortunately, the source of infection in this pediatric patient was not eradicated, and the treatment was finally abandoned.

Therapeutic paradigms for refractory carbapenem-resistant Enterobacteriaceae (CRE) have revolutionized in recent years with the advent of novel β -lactam- β -lactamase Inhibitor (β L- β LI) agents, including ceftazidime-avibactam, meropenem-vaborbactam and imipenem/cilastatin-relebactam).³ However, the clinical trials evaluating safety of meropenem-vaborbactam and imipenem-relebactam in children are still underway.³ Furthermore, CAZ-AVI was approved by the FDA in March 2019 for children ages ≥ 3 months without guidance on CNS infection.¹¹ The treatment of children with polymyxin B-resistant CRKP in CNS infection is very challenging. Given the dearth of pediatric data, therapeutic programs require expert discussion and an individualized solution often based on adult data. It has been reported that the clinical success rate of CAZ-AVI therapy against co-resistant to carbapenems and polymyxin B *Enterobacteriales* in adults is 82.7% higher than other antimicrobial agents.¹² A study in vitro pointed out CAZ-AVI combined with polymyxin B could strengthen the efficacy of polymyxin B and prevent the regrowth of polymyxin B-heteroresistant KPC-Kp.¹³ Aside from an inability to cure the patient, can ceftazidime-avibactam be used to treat pediatric meningitis caused by *K. pneumoniae* co-resistant to carbapenems and polymyxins? Apparently, the clinical efficacy of this novel antibiotic in the pediatric patient has yet to be uncertain due to the limitations of pediatric-specific pharmacokinetic and pharmacodynamic (PK-PD) data and pediatric clinical experience in pediatric CNS infection.

Conclusion

In summary, this case illustrates some of the challenges faced by the pediatric meningitis caused by co-resistant to carbapenems and polymyxins *K. pneumoniae*. CAZ-AVI as a novel β L- β LI agent could become an alternative protocol if other therapeutic options have been exhausted. The treatment failure may be attributed to the host. However, there are still many objective limitations, such as the lack of relevant pediatric guidelines, the blank of drug susceptibility tests for polymyxin B and tigecycline in conventional laboratories, and the lag in the time of ceftazidime approval in China. Thus, we hope to exchange treatment experience for this pediatric CNS infection and seek more treatment possibilities by sharing this case.

Data Sharing Statement

The whole-genome sequence of *K. pneumoniae* 20JS63 was deposited in the GeneBank database (<https://www.ncbi.nlm.nih.gov/genbank/>) under accession number JAKEDZ000000000.

Funding

This study was supported by the National Natural Science Foundation of China (82172332), the Science and Technology Development Fund of Nanjing Medical University (No. NMUB2018082), Gusu health youth talent of Suzhou (GSWS2019039, GSWS2020030), the Science and Technology Program of Suzhou (SKY2021007) and Discipline Construction of The Second Affiliated Hospital of Soochow University (XKTJ-TD202001).

Disclosure

The authors report no conflict of interest in this work.

References

1. Xing H, Cheng C, Zhang Y, et al. Successful treatment with intrathecal and intravenous polymyxin b-based combination against MDR *Acinetobacter baumannii* meningitis in pediatric patient: a case report. *Front Pediatr*. 2021;9:564991. doi:10.3389/fped.2021.564991
2. Abdallah M, Alsaleh H, Baradwan A, et al. Intraventricular tigecycline as a last resort therapy in a patient with difficult-to-treat healthcare-associated *Acinetobacter baumannii* ventriculitis: a case report. *SN Compr Clin Med*. 2020;1–5. doi:10.1007/s42399-020-00433-7

3. Chiotos K, Hayes M, Gerber JS, Tamma PD. Treatment of carbapenem-resistant Enterobacteriaceae infections in children. *J Pediatric Infect Dis Soc.* 2020;9(1):56–66. doi:10.1093/jpids/piz085
4. Pandey S, Li L, Deng XY, Cui DM, Gao L. Outcome following the treatment of ventriculitis caused by multi/extensive drug resistance gram negative bacilli; *Acinetobacter baumannii* and *Klebsiella pneumoniae*. *Front Neurol.* 2018;9:1174. doi:10.3389/fneur.2018.01174
5. Jayol A, Poirel L, Brink A, Villegas MV, Yilmaz M, Nordmann P. Resistance to colistin associated with a single amino acid change in protein PmrB among *Klebsiella pneumoniae* isolates of worldwide origin. *Antimicrob Agents Chemother.* 2014;58(8):4762–4766. doi:10.1128/AAC.00084-14
6. Jin X, Chen Q, Shen F, et al. Resistance evolution of hypervirulent carbapenem-resistant *Klebsiella pneumoniae* ST11 during treatment with tigecycline and polymyxin. *Emerg Microbes Infect.* 2021;10(1):1129–1136. doi:10.1080/22221751.2021.1937327
7. Sary A. Zygomycosis and aspergillosis. *Zigomicosis y aspergilosis. Monografias de Dermatologia.* 1995;8(4):291–306. Spanish.
8. Xie M, Yang X, Xu Q, et al. Clinical evolution of ST11 carbapenem resistant and hypervirulent *Klebsiella pneumoniae*. *Commun Biol.* 2021;4(1):650. doi:10.1038/s42003-021-02148-4
9. Ahmadi M, Ranjbar R, Behzadi P, Mohammadian T. Virulence factors, antibiotic resistance patterns, and molecular types of clinical isolates of *Klebsiella pneumoniae*. *Expert Rev Anti Infect Ther.* 2022;20(3):463–472. doi:10.1080/14787210.2022.1990040
10. Tunkel AR, Hasbun R, Bhimraj A, et al. 2017 Infectious Diseases Society of America's Clinical Practice Guidelines for healthcare-associated ventriculitis and meningitis. *Clin Infect Dis.* 2017;64(6):34–65. doi:10.1093/cid/ciw861
11. US Food and Drug Administration. Ceftazidime-avibactam prescribing information. Available from: https://www.accessdata.fda.gov/drugsatfda_docs/label/2019/206494s005_s006lbl.pdf. Accessed October 3, 2019.
12. Guimarães T, Nouér Simone A, Martins Roberta CR, et al. Ceftazidime-avibactam as salvage therapy for infections caused by enterobacteriales coresistant to carbapenems and polymyxins. *Antimicrob Agents Chemother.* 2019;63(10):e00528–19. doi:10.1128/AAC.00528-19
13. Ma X, He Y, Yu X, et al. Ceftazidime/avibactam improves the antibacterial efficacy of polymyxin B against polymyxin B heteroresistant KPC-2-producing *Klebsiella pneumoniae* and hinders emergence of resistant subpopulation in vitro. *Front Microbiol.* 2019;10:2029. doi:10.3389/fmicb.2019.02029

Infection and Drug Resistance

Dovepress

Publish your work in this journal

Infection and Drug Resistance is an international, peer-reviewed open-access journal that focuses on the optimal treatment of infection (bacterial, fungal and viral) and the development and institution of preventive strategies to minimize the development and spread of resistance. The journal is specifically concerned with the epidemiology of antibiotic resistance and the mechanisms of resistance development and diffusion in both hospitals and the community. The manuscript management system is completely online and includes a very quick and fair peer-review system, which is all easy to use. Visit <http://www.dovepress.com/testimonials.php> to read real quotes from published authors.

Submit your manuscript here: <https://www.dovepress.com/infection-and-drug-resistance-journal>