

# Closed Extension-Block Pinning for Management of Mallet Fracture – A Case Report Based Description

Sharat Agarwal<sup>1\*</sup>, Nasim Mohammad Akhtar<sup>1</sup>

## Abstract

**Introduction:** Close reduction by extension-block K-wire fixation for acute mallet fracture is based on two sound orthopedic principles – stable arc splinting and early protected motion. Distal interphalangeal joint splinting is still the technique commonly used for mallet fractures with significant morbidity and only moderate functional outcome.

**Case Report:** We have demonstrated here Ishiguro's technique in a partially treated 2 weeks old mallet fracture with the flexion deformity at distal interphalangeal (DIP) joint after proper preoperative assessment. Peroperatively, proper anatomical localization of mallet fragment was done under fluoroscopy. Reduction of the avulsion fracture was done by extension block K-wire and intra-articular K-wire was inserted subsequently to hold the reduction in place and DIP joint in extension. Later on K-wires were removed at the end of 6 weeks follow up. Patient was subjected to the physiotherapy during the course of the treatment. Excellent functional outcome was noted at the end of three months.

**Conclusion:** Closed Extension block pinning can give acceptable functional outcome even in delayed mallet finger injuries. Full range of movement at the affected joint is an important pre-requisite for the same.

**Keywords:** Mallet finger, Mallet fracture, Extension block method.

## Introduction

Disruption of the extensor tendon mechanism of the distal phalanx resulting in an extensor lag of the distal interphalangeal joint is commonly referred to as a 'baseball or mallet finger deformity'. The underlying mechanism of injury is axial loading of the distal phalanx. There are three types of mallet finger injuries namely the rupture of the extensor tendon, avulsion of the extensor tendon at its attachment to the bone and the avulsion fracture of dorsal base of the distal phalanx, which is typically known as "mallet fracture"[1]. Mallet injury with or without a bony defect is traditionally

treated with an immobilization splint in extension for eight weeks, followed by night splinting for an additional month. If the splint is removed and the distal interphalangeal (DIP) joint of the finger goes into flexion, "the eight weeks" splinting in extension must start again [2]. It has been found that this management protocol puts undue demand on patient compliance. Cochrane review published online in 2008 found that the most important factor in the success of splint treatment is that of patient compliance [3]. On the other hand, open repair is technically difficult and demanding. Close reduction by extension-block K-wire pinning technique described by Ishiguro for the management of "Mallet fractures[4, 5]" is technically simple with good clinical outcome.

## Case History

A 29 year old male presented to us with pain and flexion deformity of the DIP joint of the middle finger. There was history of injury to left middle finger while playing

<sup>1</sup>North Eastern Indira Gandhi Regional Institute of Health & Medical Sciences, Shillong, Mawdiangdiang-793012. India

### Address of Correspondence

Dr. Sharat Agarwal

<sup>1</sup>North Eastern Indira Gandhi Regional Institute of Health & Medical Sciences, Shillong, Mawdiangdiang-793012. India

Email: [drsharat88@yahoo.com](mailto:drsharat88@yahoo.com)

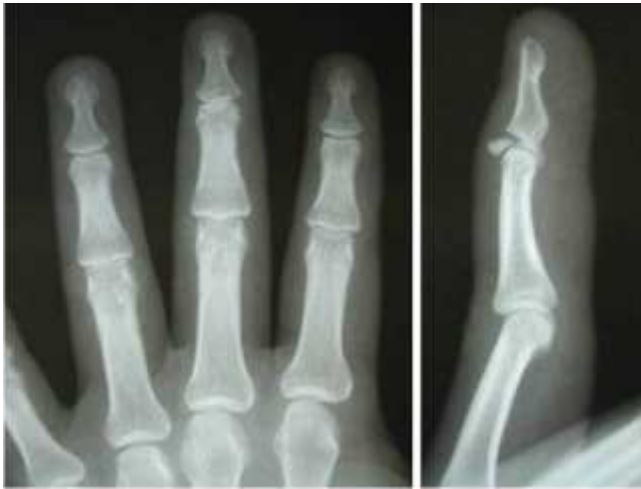

Figure 1: Antero-posterior and lateral radiographs of (L) middle finger showing mallet fracture with dorsally displaced intra-articular fracture fragment from the base of the distal phalanx involving about 50 % of the articular surface without comminution and volar subluxation of the distal phalanx.

cricket 2 weeks back. There was no history of open injury. Patient had initially taken treatment at primary health centre, where a finger splint was advised for 2 weeks. Subsequently, patient was subjected to physiotherapy with mobilization of the distal interphalangeal joint. On local examination there was swelling with associated tenderness on the dorsal aspect and flexion deformity of 20 degrees at distal interphalangeal (DIP) joint of (L) middle finger. Further flexion to 90 degrees was possible. There was no restriction of passive extension. Antero-posterior and lateral radiographs of (L) middle finger showed dorsally displaced intra-articular fracture fragment from the base of the distal phalanx involving about 50 % of the articular surface without comminution and volar subluxation of the distal phalanx (Fig. 1). Patient was planned for close reduction by extension-block K (Kirschner)-wire along with trans-articular K-wire pinning of the DIP joint. Patient was operated under digital block anesthesia on a radiolucent operating table in supine position with intraoperative C-arm image intensifier control. Being a closed procedure, no tourniquet was used. With the DIP joint held in maximum flexion, a 1.5 mm K-wire introduced just behind the fracture fragment and driven proximally into the head of the middle phalanx at an angle so that it should not slip while insertion and it should get purchase in the head of the middle phalanx and leaving ample room for another transarticular K-wire. The

fracture was reduced by the pressure of the proximal end of the distal phalanx indirectly i.e. on the already inserted K-wire levering the fracture fragment into its original position as the DIP joint is brought into full extension. Reduction was confirmed with C-arm image intensifier. Another 1.5 mm K-wire was then advanced through the distal phalanx across the DIP joint in extension into the head of the middle phalanx to maintain the reduction. Again, the reduction was confirmed with the use of C-arm image intensifier. K-wires were bent and left protruding outside the skin to facilitate removal later (Fig. 2). Pin tract dressing was done following full aseptic technique. The PIP (proximal interphalangeal) joint remained free and its mobilization was started from day one postoperatively. The wires were removed as an OPD procedure after 6 weeks and active mobilization of the DIP joint was started. Night splinting of the finger with DIP joint in extension was continued for another 2 weeks. Subsequently passive mobilization was started after the end of 8 weeks postoperatively. There was no pain or extensor lag with full flexion of the DIP joint at the end of 3 months follow up. Radiologically, no joint space narrowing or joint incongruity was evident (Fig. 3). This evaluation of the outcome was done on the basis of Crawford criteria [6], which evaluates the results as- Excellent- Full DIP joint extension, full flexion, no pain

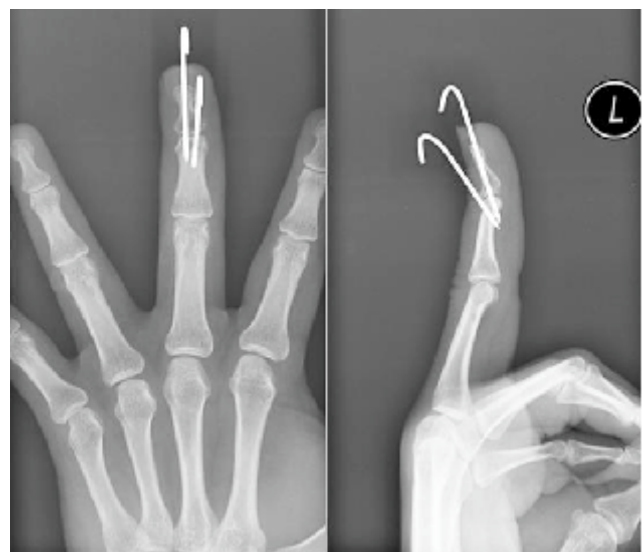


Figure 2: Post-operative antero-posterior and lateral radiographs showing in-situ extension-block and trans-articular K-wires. DIP joint is in slight extension. Extension-block K-wire is radial-ward and trans-articular K-wire is ulnar-ward. Position of K-wires was dictated by position of the mallet fragment as seen during intraoperative fluoroscopy.

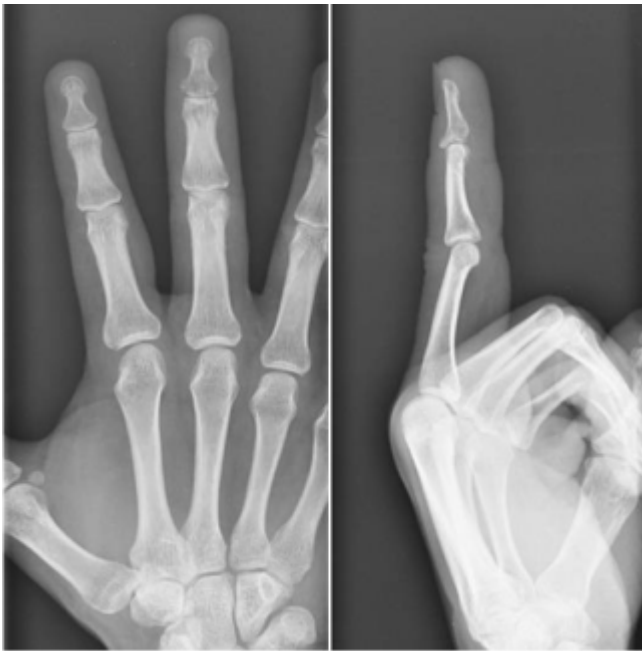

Figure 3: Antero-posterior and lateral radiographs at 3 months follow up. No extensor lag present. Joint space is congruous with no joint space narrowing.

Good- 0-10 degrees of extension deficit, full flexion, no pain; Fair- 10-25 degrees of extension deficit, any flexion loss, no pain; Poor- More than 25 degrees of extension deficit or persistent pain. In this case the result was “excellent” as per Crawford's criteria, and patient had full DIP joint extension, full flexion, no pain with no medio-lateral instability.

### Discussion

The dorsal intra-articular avulsion fracture of the base of the distal phalanx or the bony mallet finger, constitutes about 5 – 10 % of mallet finger injuries [7, 8]. The management of these injuries is dependent on the size of the avulsed intra-articular fragment and congruency of the DIP joint. The management of acute mallet fingers with extensor tendon rupture or a small fracture fragment involving less than one-third of the articular surface of the distal phalanx is usually done by continuous distal interphalangeal joint volar splinting in extension with molded polythene (Stack) or aluminum splint for 6 to 8 weeks. Night splinting usually is recommended for an additional 2 to 6 weeks. Commonly volar splints are used but dorsal splints can also be used. However, care must be taken when applying them to prevent maceration and ulceration of the skin [9]. Conservative treatment has been advocated by Wehbe and Schneider, regardless of the size of bony

fragment or extent of fracture displacement or subluxation of the DIP joint. Good patient compliance and regular follow-ups are essential [10]. Skin slough, tape allergy, transverse nail plate grooves, splint-related pain, and tender dorsal prominence can complicate conservative treatment [11, 12]. However, the management of mallet fractures involving more than one-third of the articular surface has been found to be more controversial. Wehbe and Schneider [10] observed 33% complication rate in open-surgically managed group as compared to 9% in conservatively managed group. The later group showed poor patient's compliance as a major problem. Percutaneous pinning procedures have decreased the complications associated with open surgery. Most authors agree for operative management for mallet fracture involving more than one-third of the articular surface. But, open reduction is fraught with many complications, like scar formation, nail deformity, prominent dorsal bump, osteomyelitis, non-union or avascular necrosis of the fragment, or recurrent mallet or residual finger flexion deformity etc. In 1988, Ishiguro et al introduced a new method for close pinning by extension block for effective reduction of mallet fragment and simultaneously decreasing the complications of open surgery [5, 13]. Other authors also confirmed the effectiveness of this technique [14, 15]. Ishiguro et al observed that the trans-articular K-wire should be introduced from the radial or ulnar side to prevent the pin penetrating the fracture surface which may lead to loss of reduction or interfere with fracture healing [13]. In our case, intraoperative fluoroscopy revealed that the mallet fragment was slightly radialwards, so the extension-block K-wire was placed on the radial side, and the transarticular K-wire was placed slightly towards ulnar side to attain good reduction and to prevent transarticular pin coursing through fracture line (Fig. 2). Understandably, pin-tract infection is one of the potential complications of this technique, so due pin-tract care is imperative. Removal of the callus in chronic mallet fractures for correct anatomical reduction is not possible by percutaneous techniques. However, percutaneous procedures have been found to be associated with the technical difficulty in accessing the DIP joint correctly, achieving reduction of the small articular fragment and potential chances of injury to the tenuous soft tissue envelope [10, 13].

Extension block pinning technique is a minimally invasive method of managing mallet fractures with low morbidity and good functional outcome. This technique when properly applied has been found to produce satisfactory functional results with good fracture union. No issue related to patient compliance was noted. Good pin-tract care is mandatory in these cases. Thus to conclude, Ishiguro's extension-block K-wire fixation technique is a novel method for the management of "Mallet fractures" and should be considered for such cases.

### Conclusion

This case report based review on the technique of the management of Mallet Fracture using Closed Extension block method has been presented to highlight the efficacy and easiness to perform this procedure, requiring attention to only few technical details with good functional outcome.

### Clinical Message

Closed Extension block pinning method can be successfully used with good functional outcome for the management of Mallet fracture with less than 1/3rd of the distal phalanx involvement, presenting even as late as 2 weeks since injury. Although, more number of cases may be required to highlight the issue of the outcome, one key factor for a good outcome can be the availability of full passive range of motion at the DIP joint in the cases which are presenting late to the treating surgeon especially in developing countries

Conflict of Interest: Nil  
Source of Support: None

### References

1. Doyle JR. *Extensor tendon acute injuries*. In: Green DP, Hotchkiss RN, Pederson WC, eds. *Operative hand surgery*. 4th ed. New York: Churchill Livingstone, 1999; 1950-1987.
2. Perron AD, Brady WJ, Keats TE, et al. *Orthopedic pitfalls in the emergency department: closed tendon injuries of the hand*. *Am J Emerg Med* 2001; 19: 76-80.
3. Handoll HH, Vaghela MV. *Interventions for treating mallet finger injuries*. *Cochrane Database Syst Rev*. 2004;(3):CD004574.
4. Pegoli L, Toh K, Arai A, Fukuda S, Nishikawa S, Vallejo IG. *The Ishiguro extension block technique for the treatment of mallet finger fracture: indications and clinical results*. *J Hand Surg* 2003; 28B: 15-17.
5. Ishiguro T. *A new Method of closed reduction for mallet fracture using extension-block Kirschner wire*. *Cent Jpn J Orthop Trauma Surg* 1988; 6: 413-5.
6. Crawford GP. *The moulded polythene splint for the mallet finger deformities*. *J Hand Surg Am*. 1984; 9(2): 231-237.
7. Darder-Prats A, Fernandez-Garcia E, Fernandez-Gabarda R: *Treatment of mallet finger fractures by the extension-block K-wire technique*. *J Hand Surg [Br]* 1998; 23(6): 802-805
8. Doyle JR: *Extensor Tendons: Acute Injuries*. In: Green DP (Ed.) *Operative Hand Surgery*. New York: Churchill Livingstone, 1988; 3: 2045-71.
9. James H. Calandruccio, Mark T. Jobe. *The Hand – Fractures, Dislocations, and Ligamentous Injuries*. In: *Campbell's Operative Orthopaedics*, 11th ed., Philadelphia, Mosby Elsevier; 2008. p.3966-3967.
10. Wehbe MA, Schneider LH. *Mallet fractures*. *J Bone Joint Surg Am*. 1984; 66(5): 658-669.
11. Bendre AA, Hartigan BJ, Kalainov DM. *Mallet finger*. *J Am Acad Orthop Surg*. 2005; 13(5):336-344.
12. Stern PJ, Kastrup JJ. *Complications and prognosis of treatment of mallet finger*. *J Hand Surg Am*. 1988; 13(3): 329-334.
13. Ishiguro T, Itoh Y, Yabe Y, Hashizume N. *Extension block with Kirschner wire for fracture dislocation of the distal interphalangeal joint*. *Tech Hand Up Extrem Surg*. 1997; 1(2): 95-102.
14. Inoue G. *Closed reduction of mallet fractures using extension-block Kirschner wire*. *J Orthop Trauma*. 1992; 6(4): 413-415.
15. Darder-Prats A, Fernández-García E, Fernández-Gabarda R, Darder-García A. *Treatment of mallet finger fractures by the extension-block K-wire technique*. *J Hand Surg Br*. 1998; 23(6): 802-805.

### How to Cite this Article:

Sharat A, Akhtar NM. Closed Extension-Block Pinning for Management of Mallet Fracture – A Case Report Based Description. *J Orthopaedic Case Reports* 2012 July-Sep;2(3): 17-20