

Delayed intracerebellar hemorrhage secondary to lumboperitoneal shunt insertion

Uygur Er, Çetin Akyol¹, Murad Bavbek¹

Department of Neurosurgery, School of Medicine, Düzce University, Düzce, ¹Neurosurgery Clinic, Dışkapı Yıldırım Beyazıt Education and Research Hospital, Ankara, Turkey

ABSTRACT

Aim of this paper is to present and discuss a case of a delayed cerebellar parenchymal hemorrhage developing after L/P shunt placement with a NPH patient. A hypertensive patient admitted to our clinic with a diagnosis of NPH. The patient was placed a pressure adjustable L/P shunt without any surgical complication. He was discharged with an uneventful period. The patient was admitted to the emergency clinic of our hospital with a 1.5 × 1.5 cm diameter hematoma at the left cerebellar hemisphere on 2 days after his discharge. CSF drainage by an L/P shunt can generate intracerebellar hemorrhages especially in hypertensive patients.

Key words: Hydrocephalus, intracerebellar hemorrhage, lumboperitoneal shunt

Introduction

Lumbar CSF drainage has been used in some diagnostic and therapeutic indications with well documented complications including overdrainage, pneumocephalus, brain collapse that resulted in neurological deterioration.^[1] Developing acute subdural hematoma (ASH) after lumboperitoneal (L/P) shunt placement in patients with normal pressure hydrocephalus (NPH) is a well-known clinical entity despite its low incidence.^[1,2] Some parenchymal hemorrhages also can be seen after ventriculoperitoneal (V/P) shunt insertion.^[3,4] Both clinical entities can be explained by several well-established theories.^[2,4] To the best of our knowledge, there are hardly ever cases in the literature that developing delayed parenchymal hematoma after L/P shunt placement in a patient with NPH, and there is no intracerebellar one among them. It is presented and discussed in this paper that a case of a delayed cerebellar parenchymal hemorrhage developing after L/P shunt placement with a NPH patient.

Case Report

A 67-year-old man admitted to our clinic with a 4-month

history of headache, difficulty in walking, urinary incontinence and mild close memory deficit. The patient was suffered from hypertension approximately for 30 years. He was treated by multiple antihypertensive agents such as angiotensine-converting enzyme (ACE) inhibitors, β -blockers and calcium channel blockers. His hypertension has been within normal limits (145-170/80-90 mmHg) for a long time. He was never treated by antiaggregant or anticoagulant agents regularly to liquefy the blood viscosity. Neurological examination revealed a gait pattern with wide based, short shuffling steps and unsteadiness on turning. Bradykinesia and slowness of thought were also detected. A magnetic resonance imaging (MRI) revealed hydrocephalic dilatations of the lateral, the third and the fourth ventricles [Figure 1]. Neither white matter nor cortical abnormalities such as infarcts or atrophy were detected on the CT scan. There was no compression of cortical sulci either. During lumbar puncture (LP), opening pressure (OP) of the cerebrospinal fluid (CSF) was 170 mmH₂O which was diminished to 120 mmH₂O.

Under the light of these findings, the patient was diagnosed as NPH. It was thought that he had a high clinical response to lumbar evacuating, he is considered as a candidate of L/P shunt inserting in the surgical council of our clinic.

The patient was placed a pressure adjustable L/P shunt (Sophysa, D'Orsei-France) via L₄-L₅ interspinous space without any surgical complication. An LP shunt was preferred instead of a VP one. Because the LP shunt is considered to have less complications compared to VP one. At the same time the application of an LP shunt is easier and total operating time is less than a VP shunt. Jia L *et al.* stated that a LP shunting is minimally invasive and effective in treating communicating hydrocephalus, with fewer complications. The effectiveness

Access this article online

Quick Response Code:



Website:

www.asianjns.org

DOI:

10.4103/1793-5482.145068

Address for correspondence:

Prof. Uygur Er, Söğütözü C., 4th Sk., No: 22/7, 06510, Ankara, Turkey. E-mail: uygurer@gmail.com

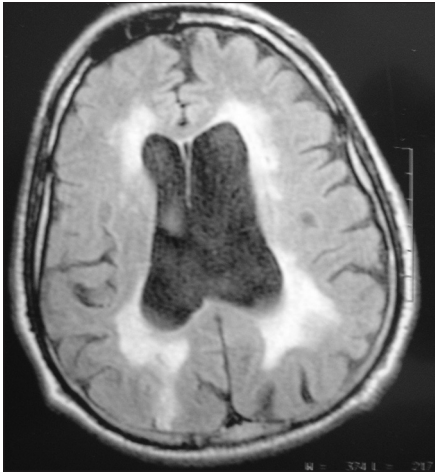


Figure 1: Hydrocephalus is seen on the preoperative axial MRI

of shunting was 91.40% and the probability of shunt-tube obstruction, which occurs predominantly in the abdominal end, was only 5.85%, far lower than that of VP shunt.^[5] At the same time complications of a VP shunt are more severe than a LP shunt, because they invade the brain and due to the need for general anesthesia and longer hospitalization.^[6] He was discharged at the second postoperative day with an uneventful period and with normal arterial blood pressure levels (TA: 160/85 mmHg).

The patient was admitted to the emergency clinic of our hospital with severe headache, nausea and vomiting 2 days after his discharge. His blood pressure was within normal limits for his age group (TA: 170/90 mmHg). Neurological examination was within normal limits. A computerized tomographic (CT) scan revealed a 1.5 × 1.5 cm diameter hematoma at the left cerebellar hemisphere [Figure 2]. His hydrocephalus was resolved. The pressure interval of the pump was adjusted to 120 mmH₂O and checked. The patient was hospitalized at intensive care unit of our clinic again and observed closely. After an uneventful period and stabilization his blood pressure he was discharged without any complication.

Discussion

L/P shunts have long been employed in the treatment of NPH.^[7] Various complications related to L/P shunts have been reported in the literature.^[1,2,8] Complications associated overdrainage of the CSF have very important and life-threatening consequences. Acute or chronic subdural hematomas, hypotensive attacks and severe headache can be seen after shunt placement despite a properly functioning shunt. These complications can also be observed after a V/P shunt operation more severely.^[4] Postoperative intracerebral hemorrhages were not even mentioned in several large series of shunting operations.^[9] Mechanism of the development of an intracerebral hematoma (ICH) can be explained by multiple

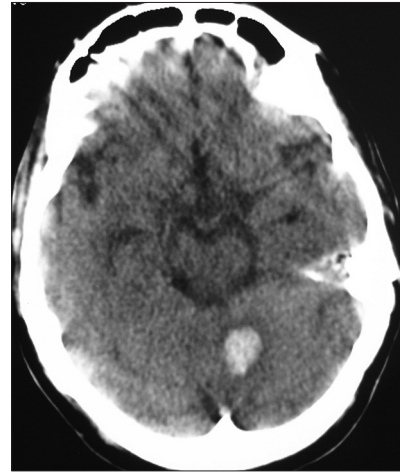


Figure 2: Postoperative fourth day CT scan revealed a left cerebellar hematoma

attempts at perforation of the ventricles, puncture of the choroids plexus or improper placement of the tubing within the parenchyma.^[3,4] These events are clearly recognizable after a V/P shunting. But a delayed intracerebellar hemorrhage (ICEH) after an L/P shunt operation should be explained by the mechanism other than direct mechanical hazards. Trauma shortly after the shunt placement has been reported in the literature.^[3] Lumbar CSF drainage may result in a reduction of CSF volume with the related lowering in intracranial pressure (ICP), which eventually increased the transmural pressure gradient of the vessels, leading to a secondary wall stress rupture.^[10] Overdrainage of the CSF during the operation may be the leading cause in our patient. Placement of pressure-adjustable type shunt can avoid overdrainage after the operation. Hypertensive patients like our patient have the greater risk of wall rupture because of the fragility of the arterioles even using a pressure-adjustable system. These type of ruptures generally occurred in the perforating arterial territories as basal ganglia and periventricular regions. Spontaneous hypertensive cerebellar hemorrhage is also considered for this patient's condition because of his hypertensive disease. But underlying hypertension of this patient has been controlled well for a long time by effective medical treatment. During the hospitalization period his blood pressure never raised-up above normal limits. His arterial tension was also measured as normal at the second admission. Beside these measurements, clinic status of the patient and hemorrhage pattern on the CT of the second admission did not suggestive for the hypertensive hemorrhage. Because its sizes were too small to be a hypertensive hematoma and the patient's condition was not worse clinically.

There is a strong preponderance for the supratentorial space.^[1] Advanced age of the patient may be the other important contributing factor in our patient' ICEH. The widespread and prolonged degeneration of the arterioles of the patients could be made vulnerable of any region of the brain. Moreover, the

ICEH of our patient might be developed independently because of his hypertension or precipitated by CSF evacuation. At the same time, some minor abnormalities like amyloid angiopathy should be kept in mind as an independent causative.

Conclusions

It should be kept in mind though that CSF overdrainage by an L/P shunt can either cause or trigger ICEHs especially in hypertensive and elderly patients.

References

1. Ruiz-Sandoval JL, Campos A, Romero-Vargas S, Jimenez-Rodriguez MI, Chiquete E. Multiple simultaneous intracerebral hemorrhages following accidental massive lumbar cerebrospinal fluid drainage: Case report and literature review. *Neurol India* 2006;54:421-4.
2. Kamiryo T, Hamada J, Fuwa I, Ushio Y. Acute subdural hematoma after lumboperitoneal shunt placement in patients with normal pressure hydrocephalus. Four case reports. *Neurol Med Chir (Tokyo)* 2003;43:197-200.
3. Alcazar R, Alfaro R, Tamarit M, Gomez-Angulo JC, Ortega JM, Aragonés P, *et al.* Delayed intracerebral hemorrhage after ventriculoperitoneal shunt insertion. Case report and literature review. *Neurocirugia* 2007;18:128-33.
4. Savitz MH, Bobroff LM. Low incidence of delayed intracerebellar hemorrhage secondary to ventriculoperitoneal shunt insertion. *J Neurosurg* 1991;91:32-4.
5. Jia L, Zhao ZX, You C, Liu JG, Huang SQ, He M, *et al.* Minimally invasive treatment of communicating hydrocephalus using a percutaneous lumboperitoneal shunt. *J Zhejiang Univ Sci B* 2011;12:293-7.
6. Barcia-Mariño C, González-Bonet LG, Salvador-Gozalbo L, Goig-Revert F, Rodríguez-Mena R. Lumboperitoneal shunt in an outpatient setting for the treatment of chronic hydrocephalus in adults. A study and follow-up of 30 cases. *Rev Neurol* 2009;49:300-6.
7. Karabatsou K, Quigley G, Buxton N, Foy P, Mallucci C. Lumboperitoneal shunts: Are the complications acceptable? *Acta Neurochir (Wien)* 2004;146:1193-7.
8. Liao YJ, Dillon WP, Chin CT, McDermott MW, Horton JC. Intracranial hypotension caused by leakage of cerebrospinal fluid from the thecal sac after lumboperitoneal shunt placement. *J Neurosurg* 2007;107:173-7.
9. Snow RB, Zimmerman RD, Devinsky O. Delayed intracerebral hemorrhage after ventriculoperitoneal shunting. *Neurosurgery* 1986;19:305-7.
10. Bloch J, Regli R. Brain stem and cerebellar dysfunction after lumbar spinal fluid drainage: Case report. *J Neurol Neurosurg Psychiatry* 2003;74:992-4.

How to cite this article: Er U, Akyol Ç, Bavbek M. Delayed intracerebellar hemorrhage secondary to lumboperitoneal shunt insertion. *Asian J Neurosurg* 2016;11:447.

Source of Support: Nil, **Conflict of Interest:** None declared.