

Ultrasound-guided core needle biopsy for differential diagnosis of thyroid nodules: A systematic review and meta-analysis

NA LIU¹, ZHAOWEI MENG¹, QIANG JIA¹, XIANGHUI HE², WEIJUN TIAN², JIAN TAN¹, YUJIE ZHANG³, XUE LI¹, TIANPENG HU¹, PINGPING ZHOU¹, SEN WANG¹ and ARUN UPADHYAYA¹

Departments of ¹Nuclear Medicine, ²General Surgery and ³Pathology, Tianjin Medical University General Hospital, Tianjin 300052, P.R. China

Received May 5, 2016; Accepted March 10, 2017

DOI: 10.3892/mco.2017.1246

Abstract. Ultrasound-guided core needle biopsy (US-CNB) of thyroid nodules is a relatively new technique used in surgical workup. However, no systematic review of this method has yet been performed. In the present meta-analysis, literature databases consisting of Cochrane Library, Medline, Embase, Scopus and Google Scholar were searched. Following eligibility assessments of the studies, quality appraisals were performed on the included studies using the Quality Assessment Tool for Diagnostic Accuracy Studies-2 method. The data were systematically analyzed by using Review Manager (version 5.3) and Meta-Disc (version 1.4). Eight investigations were included, and the study qualities were good. There were 1,621 nodules included in the final meta-analysis. The summary estimated that US-CNB had a sensitivity of 0.96 [95% confidence interval (CI)=0.94-0.97] and a specificity of 0.96 (95% CI=0.94-0.97). Positive and negative likelihood ratios, and the diagnostic odds ratio of US-CNB were 18.20 (95% CI=2.21-156.41), 0.08 (95% CI=0.02-0.27) and 250.60 (95% CI=19.11-3286.76), respectively. The area under the summary receiver operating characteristic curve was 0.979. Therefore, US-CNB may be considered as a reliable method in the assessment of thyroid nodules, and has an acceptable risk of complications.

Introduction

Thyroid nodules are one of the most common thyroid disorders. Ultrasound-guided fine needle aspiration (US-FNA) has been accepted as the gold standard for the differential diagnosis of thyroid nodules (1). However, there are certain limitations of US-FNA, including indeterminate results, which

range in frequency from 10-33% (2,3). The recommended clinical management for indeterminate aspirates is repeated US-FNA. However, a repeated US-FNA still has 38-48% indeterminate rate (4,5). Otherwise, diagnostic surgery may be performed, which eventually will increase medical costs and suffering of patients (1). Ultrasound-guided core needle biopsy (US-CNB) presents a useful alternative method to obtain tissue from thyroid nodules for diagnosis. Previous studies have demonstrated that US-CNB was a useful alternative for the management of thyroid nodules with indeterminate FNA results (4,6). However, US-CNB is not commonly used in the routine evaluation of thyroid nodules as a first-line method, and the major reason may be that US-CNB is proposed to increase the risk of bleeding and discomfort of patients (7,8).

The purpose of the current meta-analysis was to evaluate US-CNB in the diagnosis of the thyroid nodules with suspicious US findings.

Data collection methods

Literature search. Literature databases consisted of the Cochrane Library, Medline, Embase, Scopus and Google Scholar. The search terms used were core needle biopsy/coarse needle biopsy/core biopsy/CNB; thyroid nodules; thyroid cancer; head and neck tumors; neck masses. Articles were selected with publication dates up to July 29, 2015.

Eligibility. Initially, the titles and abstracts of studies were independently reviewed for eligibility by two investigators. Discrepancies were resolved by a third evaluator or by consensus following a re-evaluation. There were no restrictions on study design, language or time period. The initial screening process produced a set of potentially eligible studies. Full reprints of all these potential studies were obtained and subjected to a more rigorous screen to produce a final set of eligible studies. Prospective and retrospective observational studies were considered eligible if they contained accuracy data for the diagnosis of thyroid nodules.

Inclusion and exclusion criteria. Studies were finally included if they contained extractable data on the diagnosis of thyroid nodules. The main exclusion criteria were: i) articles not within the field of interest in this review, ii) nodules had selection bias,

Correspondence to: Dr Zhaowei Meng, Department of Nuclear Medicine, Tianjin Medical University General Hospital, 154 Anshan Road, Heping, Tianjin 300052, P.R. China
E-mail: jamesmencius@163.com

Key words: ultrasound-guided core needle biopsy, ultrasound-guided fine needle aspiration, thyroid nodule, thyroid cancer, meta-analysis

iii) diagnostic values such as sensitivity and specificity for malignancy were not studied with respect to thyroid nodules and iv) US-FNA has been performed but the outcomes were indeterminate or failed.

Quality assessment. Quality appraisals of retrieved full-text articles were graded independently by two investigators for quality and applicability according to the Quality Assessment Tool for Diagnostic Accuracy Studies-2 (QUADAS-2) method. This widely used tool consisted of 11 items: Representative spectrum (item 1), reference standard (item 2), acceptable delay between tests (item 3), partial verification bias (item 4), differential verification bias (item 5), incorporation bias (item 6), reference standard results blinded (item 7), index text results blinded (item 8), relevant clinical information (item 9), uninterpretable results reported (item 10) and withdrawals explained (item 11). Disagreements were resolved by a third evaluator or by consensus following a re-evaluation of the references.

Outcome analysis. The primary outcomes were the number of nodules that were true positive (TP), true negative (TN), false positive (FP) or false negative (FN). Subsequently, sensitivity, specificity, positive likelihood ratio (LR), negative LR, diagnostic odds ratio (DOR) and the area under the summary receiver operating characteristic curve (AUC) were evaluated. The biopsy results of US-CNB were grouped into six categories according to the Bethesda system (9), which was originally used for the analysis of US-FNA cytology: i) non-diagnostic, ii) benign, iii) atypical follicular lesion of undetermined significance (AUS/FLUS), iv) follicular neoplasm or suspected follicular lesion (FN/SFN), v) suspicious for cancer and vi) malignant lesions.

For malignant nodules, the final diagnoses were based on histological findings following surgical resection. For benign nodules, the final diagnoses were based on histological findings following surgical resection or a stable and uneventful follow-up. In the current meta-analysis, inconclusive results including non-diagnostic findings, AUS/FLUS and SFN/FN were excluded.

Statistical analysis. The results of US-CNB were assessed using values for TP, TN, FP and FN. Diagnostic parameters were calculated as followed: Sensitivity = $TP/(TP + FN)$, specificity = $TN/(TN + FP)$, positivity LR = $sensitivity/(1-specificity)$, negative LR = $(1-sensitivity)/specificity$ and DOR = $(TP/FP)/(FN/TN)$. Pooled estimates for sensitivity, specificity, positive LR, negative LR and DOR with the corresponding 95% confidence intervals (CIs) were used to examine the diagnostic ability of US-CNB for differentiating benign from malignant thyroid nodules. The pooled estimates were derived using the fixed-effects model (Mantel-Haenszel method) if significant heterogeneity was not present. In case of heterogeneity, the random-effects model (DerSimonian-Laird method) was applied. Summary receiver operating characteristic (SROC) curves were constructed using the Moses-Shapiro-Littenberg (inverse variance) method. Heterogeneity was explored via the Cochran Q test, and a P-value of <0.01 indicated the presence of heterogeneity. Inconsistency was calculated by I^2 to describe the percentage of variability due to heterogeneity,

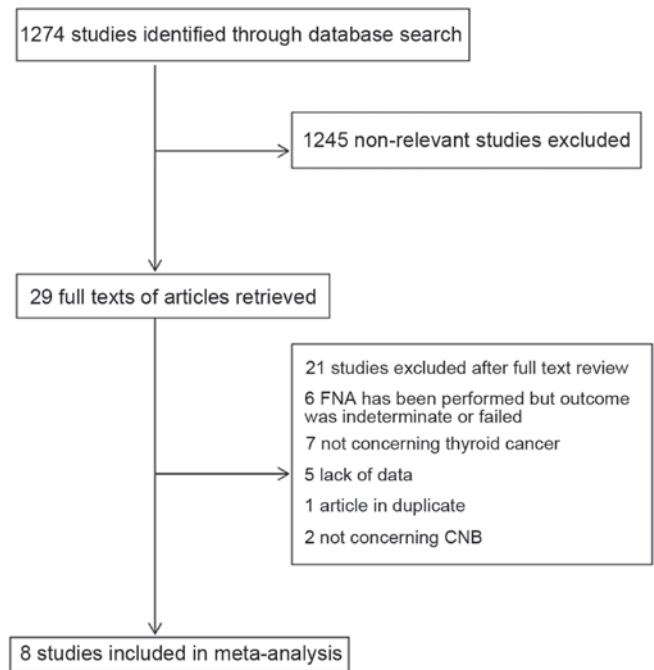


Figure 1. Flow chart diagram of the study selection process. CNB, core-needle biopsy.

rather than sampling errors. An I^2 value $>50\%$ was considered indicative of substantial heterogeneity (10). Data were analyzed using Review Manager software (RevMan version 5.3, Copenhagen: The Nordic Cochrane Centre, The Cochrane Collaboration, 2014) and Meta-Disc software (version 1.4) (11). $P < 0.05$ was considered to indicate a statistically significant difference.

Results

Study retrieval. Initially, 1,274 studies were identified. Following title and abstract scrutiny, 1,245 irrelevant studies were removed. From the 29 obtained potentially eligible articles, 8 papers were finally included (Fig. 1) (7,8,12-17). There was 1 prospective study and 7 retrospective studies, and the parameters of the investigations are provided in Table I.

Study quality. A summary of the QUADAS-2 quality assessment is presented in Fig. 2. Nodules with at least one of the following malignancy-suspicious US findings were subjected to US-CNB: Calcification, hypoechogenicity, irregular margin, vascularity, and taller than wide (item 1). The gold standard was surgical pathology (item 2). No studies specifically mentioned the time between US-CNB and histological evaluation, except for that by Paja *et al* (14), which clearly stated that the interval between US-CNB and surgery was less than 12 months in all cases (item 3). Although this may lead to timing bias, in the majority of institutions, the interval between US-CNB and histological evaluation was likely to be short. All cases were evaluated against a reference standard. The majority of studies were based only on histologically verified samples, which may lead to partial verification bias (item 4). In addition, 2 studies used histological confirmation and clinical follow-up as reference standards (item 5). The index test was independent of

Table I. Basic characteristics of studies included in this meta-analysis

First author (year)	Design	No. of nodules	Inadequate samples (%)	No. of cases including follow-up	Finally included	Male/female	Age, years (range)	(Refs.)
Chen (2015)	Retrospective	365	63 (17.3)	89	89	286/79	58 (14-85)	(12)
Harvey (2005)	Retrospective	79	10 (12.7)	69	69	NK	NK	(13)
Karstrup (2001)	Retrospective	77	9 (11.7)	41	36	13/64	51 (33-81)	(7)
Paja (2015)	Retrospective	3,517	364 (10.3)	676	522	NK	NK	(14)
Renshaw (2007)	Retrospective	377	67 (17.8)	62	55	76/301	52 (14-86)	(8)
Sung (2012)	Retrospective	555	82 (14.8)	555	473	85/453	44.32±11.86	(15)
Trimboli (2014)	Prospective	31	1 (3.2)	31	30	NK	NK	(16)
Zhang (2014)	Retrospective	369	22 (6.0)	369	347	101/254	47.7±11.8 (14-78)	(17)

NK, not known.

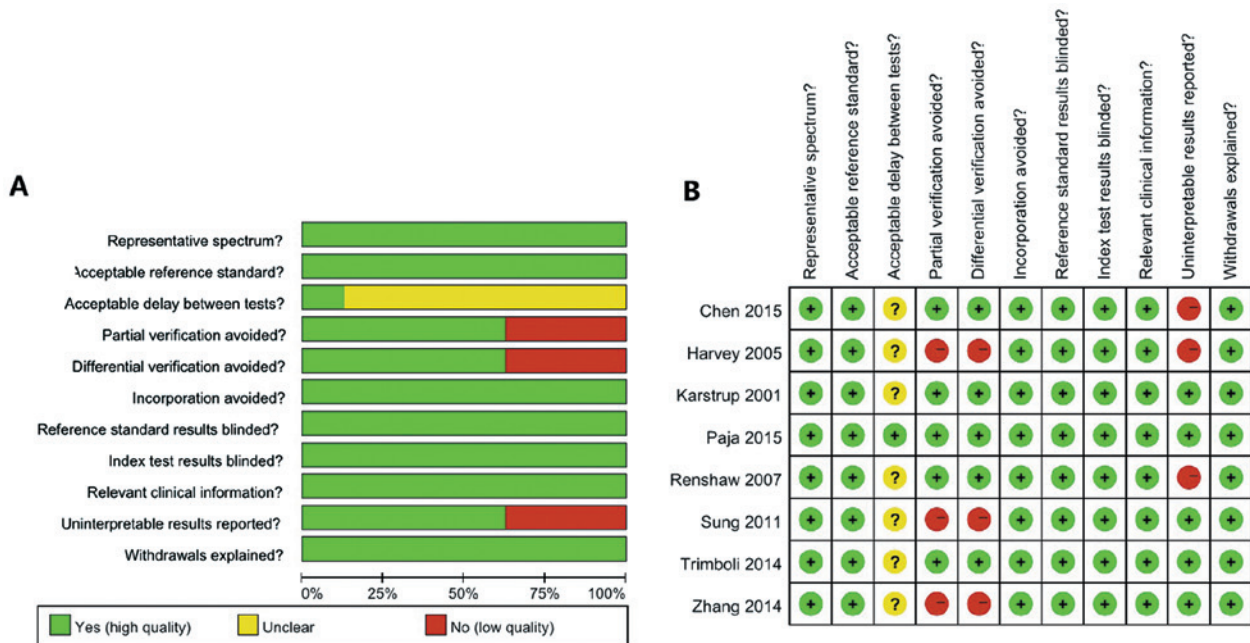


Figure 2. Evaluation of study quality. (A) Risk of bias graph and (B) risk of bias summary. A green circle indicates a low risk of bias; a yellow circle indicates an unclear risk of bias; and a red circle indicates a high risk of bias.

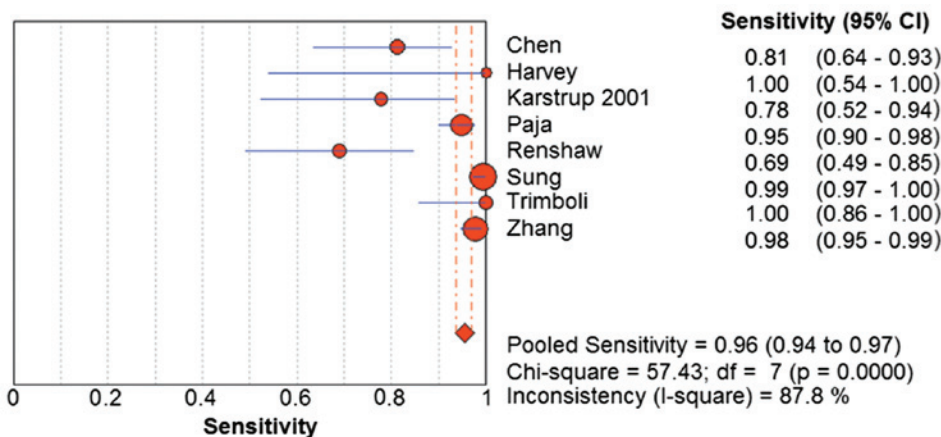


Figure 3. Pooled diagnostic sensitivity of ultrasound-guided core needle biopsy. CI, confidence interval; df, degrees of freedom.

Table II. Performance of the included studies.

First author (year)	TP	FP	FN	TN	Total	Sensitivity (%)	Specificity (%)	Accuracy (%)	Positive predictive value (%)	Final diagnosis	(Refs.)
Chen (2015)	26	4	6	53	89	81.3	93	88.8	86.7	Surgical resection	(12)
Harvey (2005)	6	7	0	56	69	100	88.9	89.9	46.2	Surgical resection and clinical follow-up	(13)
Karstrup (2001)	14	1	4	17	36	77.8	94.4	86.1	93.3	Surgical resection	(7)
Paja (2015)	145	3	8	366	522	94.8	99.2	97.9	98	Surgical resection	(14)
Renshaw (2007)	20	17	9	9	55	69.0	34.6	52.7	54.1	Surgical resection	(8)
Sung (2012)	276	2	2	193	473	99.3	99.0	99.2	99.3	Surgical resection and clinical follow-up	(15)
Trimboli (2014)	24	0	0	6	30	100.0	100.0	100.0	100.0	Surgical resection	(16)
Zhang (2014)	211	2	5	129	347	97.7	98.5	98.0	99.1	Surgical resection and clinical follow-up	(17)

TP, true positive; FP, false positive; FN, false negative; TN, true negative.

the reference test (item 6). It was usual practice for the reference standard to be evaluated with knowledge of the index test results (item 7), and the index test was always interpreted without knowledge of the reference standard (item 8), thus, there was potential for the knowledge of the US-CNB diagnosis to influence the histological diagnosis. The majority of the studies were retrospective, and clinical data were available at the time of diagnosis by the index test (item 9). Three studies included non-diagnostic findings, AUS/FLU and SFN/FN (item 10), and the withdrawals were explained (item 11).

Diagnostic analysis. In the 8 studies included in this meta-analysis, there were a total of 5,370 nodules, including 618 indeterminate nodules. The rate of indeterminate results ranged from 0-17.8%, and the pooled rate of indeterminate results was 11.5%. In 5,370 nodules, 1,738 nodules were followed-up, but 117 of these nodules were indeterminate, so 1,621 nodules were finally included in this meta-analysis (Table I).

The compilations of sensitivity, specificity, accuracy and positive predictive value of US-CNB for thyroid cancer are displayed in Table II. The sensitivity for malignancy ranged from 0.69-1, the specificity for malignancy ranged from 0.35-1, and the accuracy ranged from 0.53-1. The random-effects model was used for determining the pooled diagnostic sensitivity, as homogeneity tests of sensitivity revealed that $Q=57.43$ ($P<0.01$) and $I^2=87.8\%$. The pooled sensitivity for malignancy was 0.96 (95% CI=0.94-0.97) (Fig. 3). Similarly, the random-effects model was used for determining the pooled diagnostic specificity, as homogeneity tests of sensitivity showed $Q=107.35$ ($P<0.01$) and $I^2=93.5\%$. The pooled specificity was 0.96 (95% CI=0.94-0.97) (Fig. 4).

The positive LR was 18.20 (95% CI=2.21-156.41; $Q=284.00$; $P<0.01$) and $I^2=97.5\%$ (Fig. 5). The negative LR was 0.08 (95% CI=0.02-0.27; $Q=87.41$; $P<0.01$) and $I^2=92.0\%$ (Fig. 6). The DOR was 250.60 (95% CI=19.11-3286.76) ($Q=120.83$; $P<0.01$) and $I^2=94.2\%$ (Fig. 7). The AUC was 0.979 (standard error=0.018) (Fig. 8).

Complications of US-CNB. In total, 73 hematomas and 1 recurrent nerve lesion were reported from a total of 5,370 nodules (Table III). The overall risk of the hematoma was 1.3%.

Discussion

Thyroid nodules are very common, and their prevalence has dramatically increased in recent years (18,19). Although the risk of malignancy is fairly low, it must be considered (1,20,21). The early detection and distinction between benign or malignant thyroid nodules is particularly important to guide clinical treatment and select operative methods. At present, ultrasound is widely used in the initial differentiation. Several ultrasound features, such as irregular, taller than wide dimensions, microcalcifications and hypoechogenicity have been considered to be malignant signs (22). However, none of these characteristics appears sufficient to diagnose malignancy individually, and in numerous cases ambiguous features result in uncertain ultrasonic diagnosis. Therefore, US-FNA and cytopathology is now considered as the gold standard to identify thyroid nodules with suspiciously concerning clinical and/or

Table III. Complications in the included studies

First author (year)	Needle gauge passes	Total	Complications	(Refs.)
Chen (2015)	NK	365	1 hematoma	(12)
Harvey (2005)	18	79	1 hematoma	(13)
Karstrup (2001)	18	77	3 hematomas	(7)
Paja (2015)	18	3,517	56 hematomas, 1 recurrent nerve lesion following a direct puncture of the nerve	(14)
Renshaw (2007)	18, 20, 21	377	1 hematoma	(8)
Sung (2012)	18	555	11 hematomas ^a	(15)
Trimboli (2014)	21	31	None	(16)
Zhang (2014)	18	369	None	(17)

^aIncluded ultrasound-guided fine needle aspiration and ultrasound-guided core needle biopsy NK, not known.

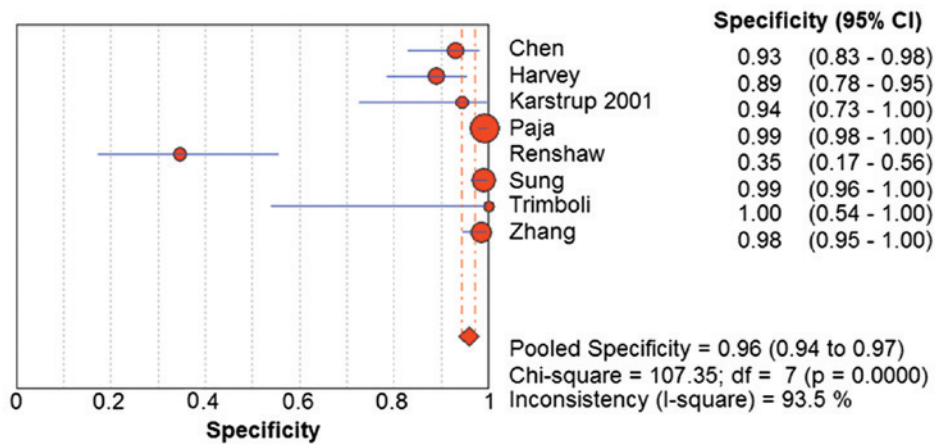


Figure 4. Pooled diagnostic specificity of ultrasound-guided core needle biopsy. CI, confidence interval; df, degrees of freedom.

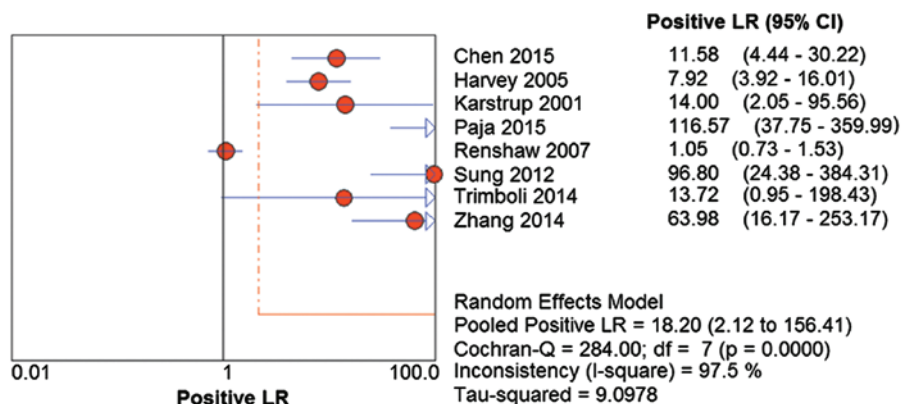


Figure 5. Pooled positive LR of ultrasound-guided core needle biopsy. LR, likelihood ratio; CI, confidence interval; df, degrees of freedom.

sonographic features. Nevertheless, US-FNA has been limited by the rate of indeterminate results (including non-diagnostic AUS/FLUS and FN/SFN findings) to a certain extent. It has been reported that indeterminate rate of the US-FNA was between 10.9-33% (2,3,23-25). The malignancy rate of the

surgical follow-up in AUS/FLUS ranged from 6-48% (26) and in FN/SFN between 10 and 30% (27,28).

US-CNB has been revealed to be useful in combination with US-FNA or following insufficient, non-diagnostic or atypia of uncertain significance results in US-FNA (5,6,29,30).

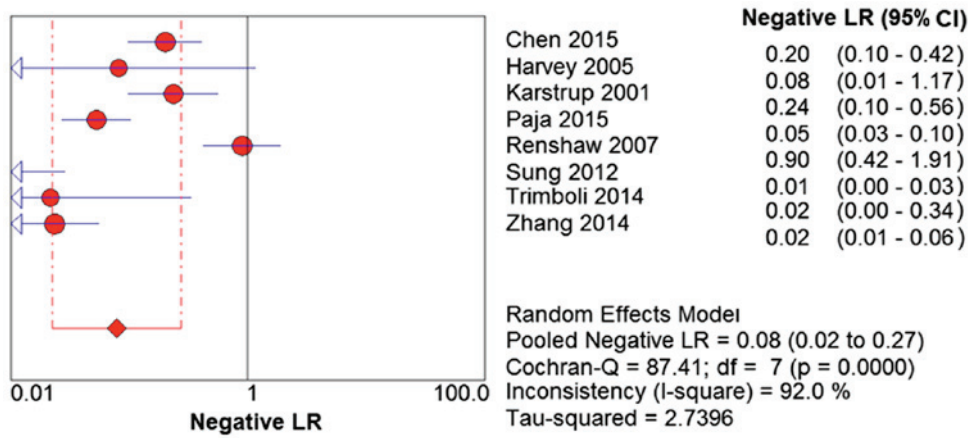


Figure 6. Pooled negative LR of ultrasound-guided core needle biopsy. LR, likelihood ratio; CI, confidence interval; df, degrees of freedom.

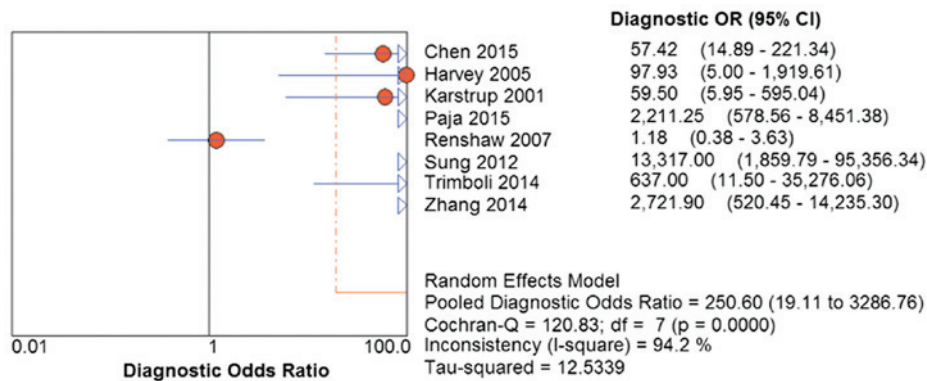


Figure 7. Pooled diagnostic OR of ultrasound-guided core needle biopsy. OR, odds ratio; CI, confidence interval; df, degrees of freedom.

However, few reports have been conducted to evaluate the usefulness of US-CNB as a routine diagnostic procedure for thyroid nodules. In a prior meta-analysis, Li *et al* (31) evaluated US-FNA and US-CNB in diagnosing thyroid nodule malignancy. This recently published review included 5 studies and elucidated a US-FNA sensitivity of 68% and a specificity of 93% for detecting thyroid cancer, and US-CNB was able to detect thyroid malignancy with a sensitivity of 83% and a specificity of 94%. The number of studies included in the above meta-analysis was smaller than that in the current study. To the best of our knowledge, the present study is the only dedicated meta-analysis and literature review of US-CNB for thyroid nodules. The present meta-analysis included 1,621 nodules from 8 studies. The results revealed that US-CNB for thyroid nodules was a useful technique with high pooled sensitivity (96%) and high pooled specificity (96%), confirming that US-CNB was an effective method for identifying malignancy in thyroid nodules. With increased evidence inclusion in the current analysis, markedly higher diagnostic capabilities of US-CNB than the findings from Li *et al* (31) were identified.

Higher economical cost, concerns about potential complications, technical requirements and time consumption may limit the use of US-CNB. It may be considered that US-CNB has the potential to increase patient discomfort and enhance complications. However, prior investigations revealed that compared with US-FNA, US-CNB did not increase the patient

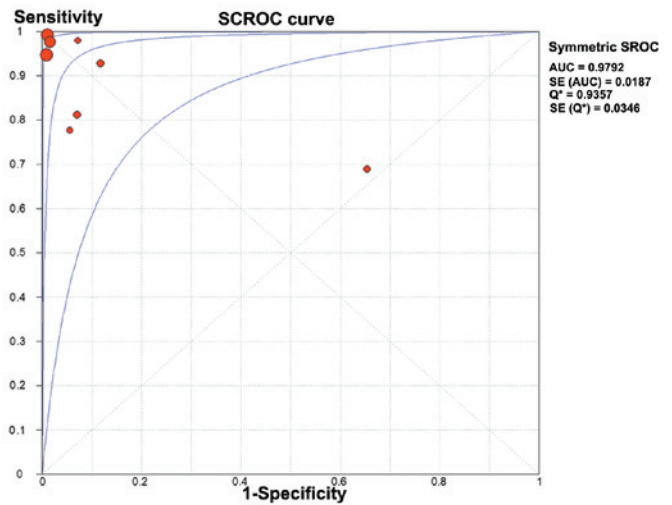


Figure 8. SROC curve for ultrasound-guided core needle biopsy. SROC plot for assessing accuracy with corresponding curves indicative of upper and lower bounds of 95% confidence interval. SROC, summary receiver operating characteristic; AUC, area under curve; SE, standard error; Q², summary measure of accuracy derived from the SROC curve.

discomfort significantly (5-8,15,29,30,32-36). In the present meta-analysis, the reported complications are compiled in Table III. The most common was post-biopsy hematoma (7,8,12-15), but the majority of patients did not require

treatment for this complication. Only one patient suffered from recurrent nerve damage following a direct puncture of the nerve, which finally caused permanent dysphonia. However, this type of complication was also reported with US-FNA (37). Furthermore, Bergeron *et al* (38) reported an iatrogenic arteriovenous fistula formation following US-CNB, eventually causing tinnitus. In order to minimize such critical complications, US-CNB must be performed with experienced radiologists with dedicated training, who are familiar with the radiological features of important anatomical structures in the cervical region. Compared with US-FNA, US-CNB appears to depend more on the experience and skill of the operator and cytology interpretation. In addition, the cost of US-CNB requires consideration. Trimboli *et al* (39) reported that US-CNB cost 1,000 Euros per patient, and this price was much higher than the cost of US-FNA (about 150 Euros). Although US-CNB is more expensive, considering the collective cost of repeat US-FNA and diagnostic surgery, and the associated patient suffering due to surgery, the cost of US-CNB is reasonable.

The current meta-analysis had several potential sources of bias and limitations. Firstly, 7 of the 8 included studies were retrospective. Retrospective studies frequently tend to include post-surgical cases with positive results, and in this way positive rate will be much higher than the negative rate. Three retrospective and one prospective study included in this meta-analysis avoided this problem in that they included all cases within a specified period of time and used clinical follow-up to verify cases with a negative US-CNB. Second, the heterogeneity of the included studies was also a matter of concern. The degree of heterogeneity in the present study was relatively high. It was considered that variance across the included studies was attributed to heterogeneity. The potential confounding variances included, for example: The choice of the nodules, the shape and size of the nodules and the experience of the operator. In addition, baseline differences among the patients in the included studies and in the study qualities may also contribute to heterogeneity. Third, publication bias was another concern, as studies that reported significance were more likely to be published than those reporting non-significant results. Fourth, although the current study provided evidence suggesting that US-CNB had high sensitivity and specificity for the detection of malignancy nodules in thyroid, it was also based on a relatively small number of studies.

In conclusion, the present meta-analysis suggests that US-CNB is a safe, reliable, and accurate method to assess thyroid nodules. It has high sensitivity and specificity, and has low risk of complications for the diagnosis of malignant thyroid nodules, which may avoid repeat US-FNA and diagnostic surgery.

Acknowledgements

The present study was supported by the National Key Clinical Specialty Project (awarded to the Departments of Nuclear Medicine and Radiology); The Tianjin Medical University General Hospital New Century Excellent Talent Program; Young and Middle-aged Innovative Talent Training Program from Tianjin Education Committee; and Talent Fostering Program (the 131 Project) from Tianjin Education Committee,

Tianjin Human Resources and Social Security Bureau (awarded to Dr Zhaowei Meng); The China National Natural Science Foundation (grant no. 81571709) Key Project of Tianjin Science and Technology Committee Foundation grant (awarded to Dr Zhaowei Meng). The funders had no role in study design, data collection and analysis, decision to publish, or preparation of the manuscript.

References

1. American Thyroid Association (ATA) Guidelines Taskforce on Thyroid Nodules and Differentiated Thyroid Cancer; Cooper DS, Doherty GM, Haugen BR, Kloos RT, Lee SL, Mandel SJ, Mazzaferri EL, McIver B, Pacini F, *et al*: Revised American thyroid association management guidelines for patients with thyroid nodules and differentiated thyroid cancer. *Thyroid* 19: 1167-1214, 2009.
2. Nayar R and Ivanovic M: The indeterminate thyroid fine-needle aspiration: Experience from an academic center using terminology similar to that proposed in the 2007 national cancer institute thyroid fine needle aspiration state of the science conference. *Cancer* 117: 195-202, 2009.
3. Degirmenci B, Haktanir A, Albayrak R, Acar M, Sahin DA, Sahin O, Yucel A and Caliskan G: Sonographically guided fine-needle biopsy of thyroid nodules: The effects of nodule characteristics, sampling technique, and needle size on the adequacy of cytological material. *Clin Radiol* 62: 798-803, 2007.
4. Lee SH, Kim MH, Bae JS, Lim DJ, Jung SL and Jung CK: Clinical outcomes in patients with non-diagnostic thyroid fine needle aspiration cytology: Usefulness of the thyroid core needle biopsy. *Ann Surg Oncol* 21: 1870-1877, 2014.
5. Park KT, Ahn SH, Mo JH, Park YJ, Park DJ, Choi SI and Park SY: Role of core needle biopsy and ultrasonographic finding in management of indeterminate thyroid nodules. *Head Neck* 33: 160-165, 2011.
6. Na DG, Kim JH, Sung JY, Baek JH, Jung KC, Lee H and Yoo H: Core-needle biopsy is more useful than repeat fine-needle aspiration in thyroid nodules read as nondiagnostic or atypia of undetermined significance by the Bethesda system for reporting thyroid cytopathology. *Thyroid* 22: 468-475, 2012.
7. Karstrup S, Balslev E, Juul N, Eskildsen PC and Baumbach L: US-guided fine needle aspiration versus coarse needle biopsy of thyroid nodules. *Eur J Ultrasound* 13: 1-5, 2001.
8. Renshaw AA and Pinnar N: Comparison of thyroid fine-needle aspiration and core needle biopsy. *Am J Clin Pathol* 128: 370-374, 2007.
9. Cibas ES and Ali SZ: NCI Thyroid FNA State of the Science Conference: The Bethesda system for reporting thyroid cytopathology. *Am J Clin Pathol* 132: 658-665, 2009.
10. Higgins JP, Thompson SG, Deeks JJ and Altman DG: Measuring inconsistency in meta-analyses. *BMJ* 327: 557-560, 2003.
11. Zamora J, Abraira V, Muriel A, Khan K and Coomarasamy A: Meta-DiSc: A software for meta-analysis of test accuracy data. *BMC Med Res Methodol* 6: 31, 2006.
12. Chen BT, Jain AB, Dagus A, Chu P, Vora L, Maghami E and Salehian B: Comparison of the efficacy and safety of ultrasound-guided core needle biopsy versus fine-needle aspiration for evaluating thyroid nodules. *Endocr Pract* 21: 128-135, 2015.
13. Harvey JN, Parker D, De P, Shrimali RK and Otter M: Sonographically guided core biopsy in the assessment of thyroid nodules. *J Clin Ultrasound* 33: 57-62, 2005.
14. Paja M, Del Cura JL, Zabala R, Corta I, Lizarraga A, Oleaga A, Expósito A, Gutiérrez MT, Ugalde A and López JI: Ultrasound-guided core-needle biopsy in thyroid nodules. A study of 676 consecutive cases with surgical correlation. *Eur Radiol* 26: 1-8, 2016.
15. Sung JY, Na DG, Kim KS, Yoo H, Lee H, Kim JH and Baek JH: Diagnostic accuracy of fine-needle aspiration versus core-needle biopsy for the diagnosis of thyroid malignancy in a clinical cohort. *Eur Radiol* 22: 1564-1572, 2012.
16. Trimboli P, Nasrollah N, Guidobaldi L, Taccogna S, Ciciarella Modica DD, Amendola S, Romanelli F, Lenzi A, Nigri G, Centanni M, *et al*: The use of core needle biopsy as first-line in diagnosis of thyroid nodules reduces false negative and inconclusive data reported by fine-needle aspiration. *World J Surg Oncol* 12: 61, 2014.

17. Zhang M, Zhang Y, Fu S, Lv F and Tang J: Thyroid nodules with suspicious ultrasound findings: The role of ultrasound-guided core needle biopsy. *Clin Imaging* 38: 434-438, 2014.
18. Davies L and Welch HG: Current thyroid cancer trends in the United States. *JAMA Otolaryngol Head Neck Surg* 140: 317-322, 2014.
19. Tunbridge WM, Evered DC, Hall R, Appleton D, Brewis M, Clark F, Evans JG, Young E, Bird T and Smith PA: The spectrum of thyroid disease in a community: The Whickham survey. *Clin Endocrinol (Oxf)* 7: 481-493, 1977.
20. Pacini F, Schlumberger M, Dralle H, Elisei R, Smit JW and Wiersinga W; European Thyroid Cancer Taskforce: European consensus for the management of patients with differentiated thyroid carcinoma of the follicular epithelium. *Eur J Endocrinol* 154: 787-803, 2006.
21. Rago T, Santini F, Scutari M, Pinchera A and Vitti P: Elastography: New developments in ultrasound for predicting malignancy in thyroid nodules. *J Clin Endocrinol Metab* 92: 2917-2922, 2007.
22. Frates MC, Benson CB, Charboneau JW, Cibas ES, Clark OH, Coleman BG, Cronan JJ, Doubilet PM, Evans DB, Goellner JR, *et al*: Management of thyroid nodules detected at US: Society of Radiologists in Ultrasound consensus conference statement. *Radiology* 237: 794-800, 2005.
23. Yassa L, Cibas ES, Benson CB, Frates MC, Doubilet PM, Gawande AA, Moore FD Jr, Kim BW, Nosé V, Marqusee E, *et al*: Long-term assessment of a multidisciplinary approach to thyroid nodule diagnostic evaluation. *Cancer* 111: 508-516, 2007.
24. Yang J, Schnadig V, Logrono R and Wasserman PG: Fine-needle aspiration of thyroid nodules: A study of 4703 patients with histologic and clinical correlations. *Cancer* 111: 306-315, 2007.
25. Gharib H, Papini E, Paschke R, Duick DS, Valcavi R, Hegedüs L and Vitti P; AACE/AME/ETA Task Force on Thyroid Nodules: American Association of Clinical Endocrinologists, Associazione Medici Endocrinologi, and European Thyroid Association medical guidelines for clinical practice for the diagnosis and management of thyroid nodules. *J Endocrinol Invest* 33 (5 Suppl): S1-S50, 2010.
26. Otori NP and Schoedel KE: Variability in the atypia of undetermined significance/follicular lesion of undetermined significance diagnosis in the Bethesda System for Reporting Thyroid Cytopathology: Sources and recommendations. *Acta Cytol* 55: 492-498, 2011.
27. Cibas ES and Ali SZ: The Bethesda system for reporting thyroid cytopathology. *Thyroid* 19: 1159-1165, 2009.
28. Deandrea M, Ragazzoni F, Motta M, Torchio B, Mormile A, Garino F, Magliona G, Gamarra E, Ramunni MJ, Garberoglio R and Limone PP: Diagnostic value of a cytomorphological subclassification of follicular patterned thyroid lesions: A study of 927 consecutive cases with histological correlation. *Thyroid* 20: 1077-1083, 2010.
29. Yeon JS, Baek JH, Lim HK, Ha EJ, Kim JK, Song DE, Kim TY and Lee JH: Thyroid nodules with initially nondiagnostic cytologic results: The role of core-needle biopsy. *Radiology* 268: 274-280, 2013.
30. Choi SH, Baek JH, Lee JH, Choi YJ, Hong MJ, Song DE, Kim JK, Yoon JH and Kim WB: Thyroid nodules with initially non-diagnostic, fine-needle aspiration results: Comparison of core-needle biopsy and repeated fine-needle aspiration. *Eur Radiol* 24: 2819-2826, 2014.
31. Li L, Chen BD, Zhu HF, Wu S, Wei D, Zhang JQ and Yu L: Comparison of pre-operation diagnosis of thyroid cancer with fine needle aspiration and core-needle biopsy: A meta-analysis. *Asian Pac J Cancer Prev* 15: 7187-7193, 2014.
32. Khoo TK, Baker CH, Hallanger-Johnson J, Tom AM, Grant CS, Reading CC, Sebo TJ and Morris JC III: Comparison of ultrasound-guided fine-needle aspiration biopsy with core-needle biopsy in the evaluation of thyroid nodules. *Endocr Pract* 14: 426-431, 2008.
33. Strauss EB, Iovino A and Upender S: Simultaneous fine-needle aspiration and core biopsy of thyroid nodules and other superficial head and neck masses using sonographic guidance. *AJR Am J Roentgenol* 190: 1697-1699, 2008.
34. Hahn SY, Shin JH, Han BK, Ko EY and Ko ES: Ultrasonography-guided core needle biopsy for the thyroid nodule: Does the procedure hold any benefit for the diagnosis when fine-needle aspiration cytology analysis shows inconclusive results? *Br J Radiol* 86: 20130007, 2013.
35. Ha EJ, Baek JH, Lee JH, Kim JK, Kim JK, Lim HK, Song DE, Sung TY, Kim TY, Kim WB and Shong YK: Core needle biopsy can minimise the non-diagnostic results and need for diagnostic surgery in patients with calcified thyroid nodules. *Eur Radiol* 24: 1403-1409, 2014.
36. Nasrollah N, Trimboli P, Rossi F, Amendola S, Guidobaldi L, Ventura C, Maglio R, Nigri G, Romanelli F, Valabrega S and Crescenzi A: Patient's comfort with and tolerability of thyroid core needle biopsy. *Endocrine* 45: 79-83, 2014.
37. Polyzos SA and Anastasilakis AD: Clinical complications following thyroid fine-needle biopsy: A systematic review. *Clin Endocrinol (Oxf)* 71: 157-165, 2009.
38. Bergeron M and Beaudoin D: Simple core-needle biopsy for thyroid nodule, complicated tinnitus. *Eur Thyroid J* 3: 130-133, 2014.
39. Trimboli P and Crescenzi A: Thyroid core needle biopsy: Taking stock of the situation. *Endocrine* 48: 779-785, 2015.