





# Hemiparesis Caused by Cerebral Venous Sinus Thrombosis during the Postpartum Period: A Case Report; Negelle Arsi General Hospital and Medical College, Ethiopia

Zerihun Bogale <sup>1</sup>, Gemechu Geleto <sup>2</sup>, Dawit Yosef <sup>1</sup>, Abdella Amano Abdo <sup>3</sup>

<sup>1</sup>Internal Medicine Department, Negelle Arsi General Hospital and Medical College, Negelle Arsi, Oromia, Ethiopia; <sup>2</sup>Radiology Department, Negelle Arsi General Hospital and Medical College, Negelle Arsi, Oromia, Ethiopia; <sup>3</sup>Research and Community Service Office, Negelle Arsi General Hospital and Medical College, Negelle Arsi, Oromia, Ethiopia

Correspondence: Zerihun Bogale, Tel +251-913-83-31-57, Email zerihunmed@gmail.com

**Background:** Although rare, cerebral venous sinus thrombosis (CVT) can result in significant neurological complications, particularly after childbirth. Early diagnosis poses a challenge due to symptom overlap with other conditions. Limited publications and underdiagnosis of CVT are prevalent in developing nations, notably in Ethiopia.

**Case:** A 29-year-old mother, having given birth four times, presented to the emergency department in her second month postpartum with complaints of persistent headaches and blurred vision over three weeks. Additionally, she reported sudden weakness on her right side for one day. Despite previous treatments for migraine headaches, she was diagnosed with CVT after magnetic resonance imaging/venography revealed blockage in the right anastomotic vein and the posterior segment of the superior sagittal sinus. Treatment commenced with the anticoagulant enoxaparin. During hospitalization, she experienced one episode of generalized seizures, leading to transfer to the intensive care unit where phenytoin was added. Subsequent diagnosis of papilledema occurred. After a 16-day hospital stay, she was discharged with warfarin, phenytoin, and acetazolamide. Oral anticoagulation and other medications ceased after six months of treatment, considering the postpartum period as a temporary risk factor for CVT. The patient currently maintains good health and has resumed normal activities.

**Conclusion:** Maintaining a high index of suspicion for CVT during the postpartum period and promptly conducting imaging scans are crucial for early diagnosis. This approach can halt neurological decline and facilitate immediate recovery through early therapeutic interventions.

**Keywords:** Ethiopia, Negelle Arsi, headache, postpartum period, cerebral venous thrombosis

## Introduction

Cerebral venous thrombosis (CVT), which involves the clotting of veins and sinuses within the brain, is an uncommon form of cerebrovascular disorder. It primarily impacts young women, affecting around five individuals per million and representing only 0.5% of all strokes.<sup>1-3</sup> The annual incidence of CVT falls between 0.22 and 1.57 cases per 100,000 individuals in the broader population.<sup>4-7</sup>

Risk factors for CVT include conditions that lead to increased blood clotting, such as inherited prothrombotic disorders, autoimmune diseases, the use of oral contraceptives or hormonal replacement therapy, pregnancy or the postpartum period, cancer, infections, or chronic inflammatory conditions.<sup>3</sup> CVT is more commonly observed in female patients, likely due to the presence of gender-specific risk factors for clotting disorders, such as pregnancy and the use of oral contraceptives.<sup>8</sup>

The pathophysiology of CVT results from a complex interplay among genetic predisposition, hypercoagulable conditions, venous stasis, endothelial damage, changes in blood composition, and inflammatory responses. These factors

collectively contribute to the formation of blood clots within the brain's veins. CVT can stem from systemic or localized disruptions in prothrombotic and thrombolytic functions, leading to the development and dissemination of blood clots within the cerebral dural sinuses or veins. Consequently, venous blood is redirected into narrower vessels and capillaries, causing increased pressure within the venous and capillary systems.<sup>1,2,4,9</sup>

CVT can manifest with a diverse range of symptoms and onset patterns, often resembling various other conditions, which poses a diagnostic challenge for clinicians. Headache, seizures, focal neurological deficits, altered consciousness, and papilledema are among the most frequently observed symptoms and signs. These symptoms may occur individually or in combination with others.<sup>1,8,10–12</sup>

Several conditions can mimic the symptoms of CVT, highlighting the critical need for precise diagnosis. These conditions include migraine headaches, ischemic stroke, subarachnoid hemorrhage, infections such as meningitis or encephalitis, space-occupying lesions like intracranial tumors, posterior reversible encephalopathy syndrome, and idiopathic intracranial hypertension.<sup>1,3,13,14</sup>

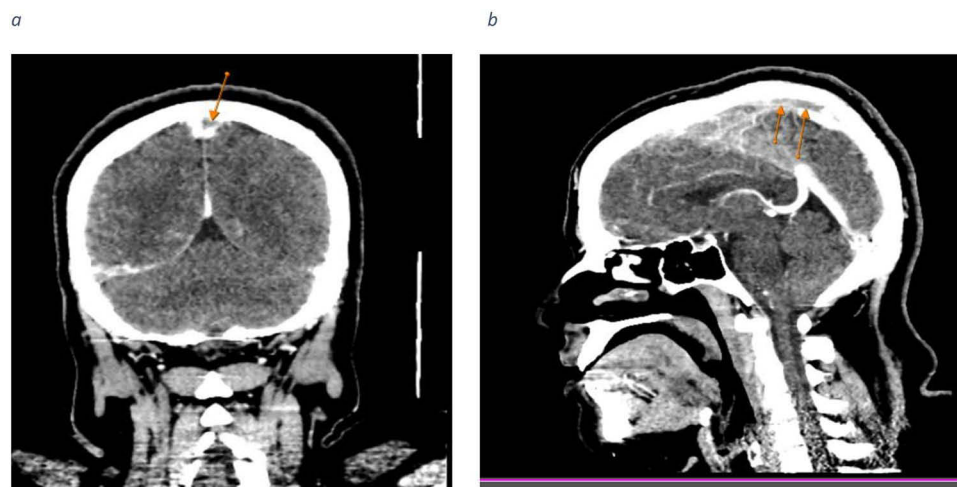
Diagnosing CVT poses challenges; nevertheless, the introduction of magnetic resonance imaging (MRI) has improved diagnostic capabilities,<sup>15</sup> magnetic resonance venography (MRV), computed tomography venography (CTV), and magnetic resonance angiography (MRA) are imaging methods utilized to verify the existence and pinpoint the location of thrombosed sinuses in CVT. As such, these imaging techniques play a crucial role in confirming the diagnosis of the condition.<sup>8</sup>

The long-term prognosis CVT depends on factors like clot severity, promptness of diagnosis and treatment, and patient health. Mortality rates, ranging from 4% to 15%, are affected by age, existing conditions, and intracranial bleeding. Recurrence is rare but possible, especially in those with prothrombotic conditions.<sup>1,2,4</sup>

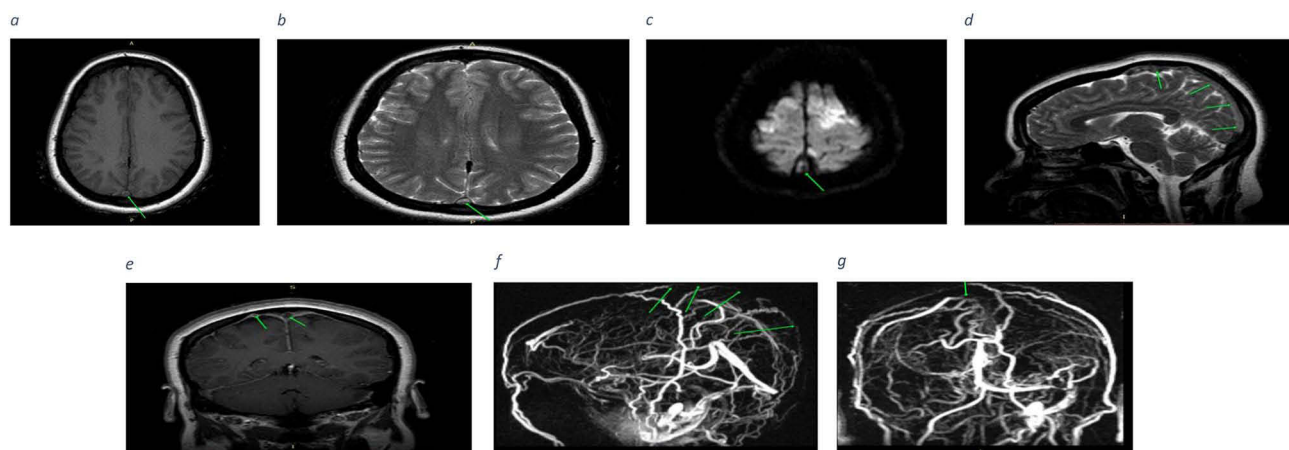
Timely diagnosis and treatment are crucial as they can potentially save a patient's life and prevent long-term disabilities. In this case study, we illustrate the significance of early detection and appropriate intervention by presenting a patient who initially presented with symptoms of hemiparesis, seizures, and papilledema, which were initially misattributed to migraine headaches. These complications were later identified as consequences of CVT, underscoring the importance of timely diagnosis and therapeutic measures in managing the condition.

## Case Presentation

This case involves a 29-year-old mother who has given birth four times, currently in her second month postpartum, presenting to the emergency department with complaints of headaches and blurred vision persisting for three weeks. She also reported experiencing right-sided body weakness for one day. Despite being treated twice before for migraine headaches, a diagnosis of CVT was eventually made. There is no personal or family history of thromboembolism. Upon examination, her blood pressure was 100/60 mmHg, and all other vital signs were within normal limits. She was fully conscious, with a Glasgow Coma Scale (GCS) score of 15/15. Motor strength was 4/5 in the right upper extremity, 4+ in the right lower extremity, and 5/5 in the left upper and lower extremities. Meningeal signs were absent. Laboratory tests including complete blood count, random blood sugar, organ function tests, and viral markers were all normal. A contrast-enhanced head computed tomography (CT) scan revealed a filling defect along the superior sagittal sinus, resembling a delta sign, as well as a tubular filling defect along the posterior aspect of the superior sagittal sinus (Figure 1a and b). Enoxaparin treatment was started, and the patient was admitted to the medical ward. On the admission day, the patient experienced a single episode of generalized tonic-clonic seizure and was subsequently moved to the intensive care unit, where phenytoin was initiated. Magnetic resonance imaging (MRI) with MRV conducted on the second day of admission revealed a focal filling defect in the right anastomotic vein and the posterior segment of the superior sagittal sinus (Figure 2a–g). The patient underwent an ophthalmologic assessment, which revealed a diagnosis of papilledema. Treatment with acetazolamide was initiated accordingly. She remained in the intensive care unit for 5 days and subsequently spent 11 days in the medical ward. After a total of 16 days of hospitalization, the patient's condition improved with the combination of phenytoin, acetazolamide, and warfarin. Considering the postpartum period as a temporary risk factor for CVT, oral anticoagulation and other medications were ceased after six months of treatment. The patient is presently in good health, indicating an absence of weakness, headaches, or any lingering symptoms previously experienced.



**Figure 1** (a) Coronal contrast-enhanced CT scan of the brain reveals a filling defect along the superior sagittal sinus, presenting as a delta sign (indicated by an arrow). (b) Sagittal contrast-enhanced CT scan of the brain displays a tubular filling defect along the posterior aspect of the superior sagittal sinus (highlighted by an arrow).



**Figure 2** (a) Axial T1WI-SE brain MRI shows slightly high signal intensity of superior sagittal sinus posteriorly (arrow) compared to cerebral white matter. (b) and (c) Axial T2-weighted and Diffusion-weighted Imaging (DWI) Brain MRI depicting high signal intensity along the posterior aspect of the superior sagittal sinus (indicated by arrows) respectively. (d) and (e) Sagittal T2-weighted spin echo (T2WI- SE) and coronal T1-weighted spin echo (T1WI-SE) brain MRI demonstrating hyperintensity along the posterior aspect of the superior sagittal sinus and the right vein of Trolard (superior anastomotic vein) respectively. (f) and (g) The MRV reveals a focal absence of blood flow (filling defect) along the posterior portion of the superior sagittal sinus and the right vein of Trolard (superior anastomotic vein).

## Discussion

Cerebral venous thrombosis (CVT) is a relatively rare and frequently misdiagnosed condition, impacting about five individuals per million and making up roughly 0.5% of all stroke cases.<sup>1,2</sup>

Typical risk factors for CVT encompass acquired hypercoagulability, hereditary thrombophilia, and conditions leading to increased blood viscosity, such as hyperhomocysteinemia, antiphospholipid antibody syndrome, Behcet's disease, and various hematological disorders.<sup>3</sup> In female patients, the primary risk factors for CVT include pregnancy/postpartum, oral contraceptive use, and the utilization of fertility drugs.<sup>3,11,15</sup>

The diagnosis of CVT presents challenges due to its infrequency and diverse clinical manifestations, often leading to confusion with other typical postpartum issues. A delayed diagnosis is linked with substantial morbidity and mortality.<sup>1</sup> Headache is the predominant symptom of CVT, observed in over 80% of cases.<sup>1,15–17</sup> Other symptoms include focal neurological deficits, papilledema, visual impairments, and seizures followed by postictal confusion.<sup>8,18</sup>

If there is suspicion of CVT, immediate imaging modalities, particularly MRV or CTV, should be conducted. The transverse sinus is the most frequent site of thrombosis formation, followed by the sigmoid sinus.<sup>15,19,20</sup>

Anticoagulation, primarily with low molecular weight heparin (LMWH) instead of unfractionated heparin (UFH), is the primary treatment approach recommended for acute CVT. This is typically followed by oral anticoagulation therapy.<sup>20</sup>

In this report, we highlight a case that has frequently been misdiagnosed or overlooked as evidenced by - limited available case reports or studies in Africa, specifically in Ethiopia.

## Conclusion

We present an uncommon instance of CVT accompanied by hemiparesis and seizures in a patient during the postpartum phase, initially mistaken for a migraine headache. This underscores the importance of considering a wide range of possibilities in the differential diagnosis of headache in postpartum patients. Early detection and treatment are crucial in averting complications and mortality.

## Abbreviations

CVT, cerebral venous sinus thrombosis; CTV, computed tomography venography; GCS, Glasgow Coma Scale; LMWH, low molecular weight heparin; MRI, magnetic resonance imaging; MRA, magnetic resonance angiography; MRV, magnetic resonance venography; UFH, unfractionated heparin.

## Ethics Approval and Consent to Participate

The publication of a single case report does not necessitate ethics approval according to the policies of the authors' institution.

## Consent for Publication

The patient provided written informed consent for the publication of this case report and accompanying images.

## Acknowledgments

The authors express their gratitude to the patient and their family for granting permission to share this case with fellow colleagues.

## Author Contributions

All authors made a significant contribution to the work reported, whether that is in the conception, study design, execution, acquisition of data, analysis and interpretation, or in all these areas; took part in drafting, revising or critically reviewing the article; gave final approval of the version to be published; have agreed on the journal to which the article has been submitted; and agree to be accountable for all aspects of the work.

## Funding

No funding was received from any organization or individuals.

## Disclosure

The authors declare that they have no competing interests in this work.

---

## References

1. Bousser MG, Ferro JM. Cerebral venous thrombosis: an update. *Lancet Neurol.* 2007;6(2):162–170. doi:10.1016/S1474-4422(07)70029-7
2. Coutinho JM, Zuurbier SM, Stam J. Declining mortality in cerebral venous thrombosis: a systematic review. *Stroke.* 2014;45(5):1338–1341. doi:10.1161/STROKEAHA.113.004666
3. Stam J. Thrombosis of the cerebral veins and sinuses. *N Engl J Med.* 2005;352(17):1791–1798. doi:10.1056/NEJMr042354
4. Ferro JM, Canhao P, Stam J, Bousser MG, Barinagarrementeria F, Investigators I. Prognosis of cerebral vein and dural sinus thrombosis: results of the International Study on Cerebral Vein and Dural Sinus Thrombosis (ISCVT). *Stroke.* 2004;35(3):664–670. doi:10.1161/01.STR.0000117571.76197.26

5. Coutinho JM, Zuurbier SM, Aramideh M, Stam J. The incidence of cerebral venous thrombosis: a cross-sectional study. *Stroke*. 2012;43(12):3375–3377. doi:10.1161/STROKEAHA.112.671453
6. Ruuskanen JO, Kytö V, Posti JP, Rautava P, Sipilä JOT. Cerebral venous thrombosis: Finnish nationwide trends. *Stroke*. 2021;52(1):335–338. doi:10.1161/STROKEAHA.120.031026
7. Devasagayam S, Wyatt B, Leyden J, Kleinig T. Cerebral venous sinus thrombosis incidence is higher than previously thought: a retrospective population-based study. *Stroke*. 2016;47(9):2180–2182. doi:10.1161/STROKEAHA.116.013617
8. Chen YC, Chang CW, Wu HC, Chen CM, Chang CH, Chang KH. Clinical characteristics and prognostic factors of non-infectious cerebral venous sinus thrombosis. *J Clin Med*. 2022;11(20):1.
9. Schaller B, Graf R. Cerebral venous infarction: the pathophysiological concept. *Cerebrovasc Dis*. 2004;18(3):179–188. doi:10.1159/000079939
10. Wang Y, Shen X, Wang P, Fang Q. Clinical characteristics of cerebral venous sinus thrombosis patients with new-onset of headache. *BMC Neurol*. 2023;23(1):56. doi:10.1186/s12883-023-03098-6
11. Song SY, Lan D, Wu XQ, Meng R. The clinical characteristic, diagnosis, treatment, and prognosis of cerebral cortical vein thrombosis: a systematic review of 325 cases. *J Thromb Thrombolysis*. 2021;51(3):734–740. doi:10.1007/s11239-020-02229-x
12. Liberman AL, Gialdini G, Bakradze E, Chatterjee A, Kamel H, Merkler AE. Misdiagnosis of cerebral vein thrombosis in the emergency department. *Stroke*. 2018;49(6):1504–1506. doi:10.1161/STROKEAHA.118.021058
13. Coutinho JM, Ferro JM, Canhao P, et al. Cerebral venous and sinus thrombosis in women. *Stroke*. 2009;40(7):2356–2361. doi:10.1161/STROKEAHA.108.543884
14. Saposnik G, Barinagarrementeria F, Brown RD Jr, et al. Diagnosis and management of cerebral venous thrombosis: a statement for healthcare professionals from the American Heart Association/American Stroke Association. *Stroke*. 2011;42(4):1158–1192. doi:10.1161/STR.0b013e31820a8364
15. Alet M, Ciardi C, Aleman A, et al. Cerebral venous thrombosis in Argentina: clinical presentation, predisposing factors, outcomes and literature review. *J Stroke Cerebrovasc Dis*. 2020;29(10):105145. doi:10.1016/j.jstrokecerebrovasdis.2020.105145
16. Mehndiratta MM, Garg S, Gurnani M. Cerebral venous thrombosis—clinical presentations. *J Pak Med Assoc*. 2006;56(11):513–516.
17. Gazioglu S, Dinc G. Cerebral venous sinus thrombosis in pregnancy and puerperium. *Acta Neurol Belg*. 2021;121(4):967–972. doi:10.1007/s13760-020-01459-3
18. Ferro JM, Canhao P. Cerebral venous sinus thrombosis: update on diagnosis and management. *Curr Cardiol Rep*. 2014;16(9):523. doi:10.1007/s11886-014-0523-2
19. Goyal G, Charan A, Clinical Presentation SR. Neuroimaging findings, and predictors of brain parenchymal lesions in cerebral vein and dural sinus thrombosis: a retrospective study. *Ann Indian Acad Neurol*. 2018;21(3):203–208. doi:10.4103/aian.AIAN\_470\_17
20. Ferro JM, Bousser MG, Canhao P, et al. European Stroke Organization guideline for the diagnosis and treatment of cerebral venous thrombosis - endorsed by the European Academy of Neurology. *Eur J Neurol*. 2017;24(10):1203–1213. doi:10.1111/ene.13381

## Publish your work in this journal

The International Medical Case Reports Journal is an international, peer-reviewed open-access journal publishing original case reports from all medical specialties. Previously unpublished medical posters are also accepted relating to any area of clinical or preclinical science. Submissions should not normally exceed 2,000 words or 4 published pages including figures, diagrams and references. The manuscript management system is completely online and includes a very quick and fair peer-review system, which is all easy to use. Visit <http://www.dovepress.com/testimonials.php> to read real quotes from published authors.

Submit your manuscript here: <https://www.dovepress.com/international-medical-case-reports-journal-journal>