

## Case Report

# Neutropenic Enterocolitis in the Treatment of Solid Tumors: A Case Report and Review of the Literature

Sara Cherri<sup>a</sup> Tiziana Prochilo<sup>a</sup> Luigina Rota<sup>a</sup> Stefano Mutti<sup>b</sup>  
Marco Garatti<sup>b</sup> Barbara Liserre<sup>c</sup> Alberto Zaniboni<sup>a</sup>

<sup>a</sup>Department of Oncology, Fondazione Poliambulanza, Brescia, Italy; <sup>b</sup>Department of Surgery, Fondazione Poliambulanza, Brescia, Italy; <sup>c</sup>Department of Pathology, Fondazione Poliambulanza, Brescia, Italy

## Keywords

Neutropenic enterocolitis · Typhlitis · Colitis · Docetaxel

## Abstract

Neutropenic enterocolitis is a clinical condition characterized by inflammation of the colic mucosa, usually the caecum, associated with bowel wall thickening in patients with compromised immune system due to chemotherapy treatments. It can occur as well in other clinical conditions that lead to immunosuppression. Clinically, patients present with abdominal pain, fever, and neutropenia on blood tests. A number of major and minor criteria have been suggested for the clinical diagnosis of typhlitis. The most sensitive radiological investigation is represented by a computed tomography scan. There are no guidelines for treatment, but some factors may lead the clinician to medical treatments or prompt surgery as the best choice in that particular patient. The most implicated chemotherapeutic regimens are those based on taxanes. Here, we present a clinical case of a young patient with breast cancer and a review of the state of the art of knowledge regarding neutropenic enterocolitis in adult patients undergoing chemotherapy for the treatment of solid tumors.

© 2020 The Author(s).  
Published by S. Karger AG, Basel

## Introduction

Neutropenic enterocolitis (or typhlitis) is a severe complication that can occur in immunosuppressed patients, characterized by transmural inflammation of the caecum (for this reason, it is also defined as typhlitis), but it can also occur in other portions of the colon [1,

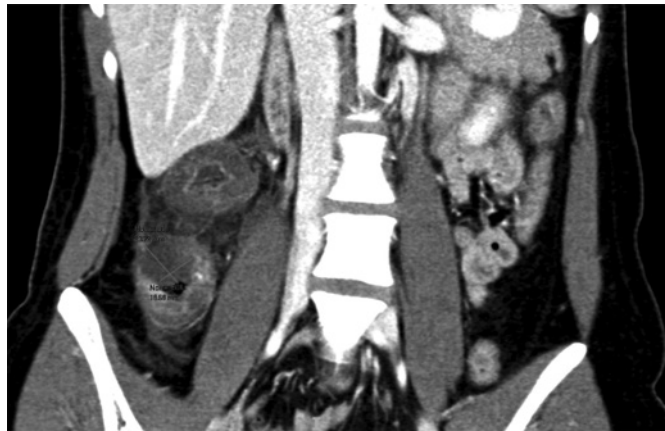Sara Cherri, MD  
Department of Clinical Oncology  
Fondazione Poliambulanza, Bissolati Street 57  
IT-25124 Brescia (Italy)  
sara.m.cherri@gmail.com

2]. Classically, the inflammation of the caecum is associated with involvement of the right colon. The pathogenesis is not fully known; it may be multifactorial: destruction of the intestinal mucosal barrier and migration of bacteria from the intestine to the bloodstream [3]. The caecum is the portion most affected, probably due to the low blood flow. There is a large amount of literature on typhlitis during intensive chemotherapy treatments in hematological patients; in fact, the first case of typhlitis was described in a leukemic pediatric patient. However, recently, there has been more interest in this complication also as regards the treatment of solid tumors in adults, since the use of combined and aggressive chemotherapy regimens has increased [4, 5]; most of the cases are treated with taxane-based chemotherapy. Cases of neutropenic enterocolitis have been reported in the literature during other chemotherapy treatments as well [6–11].

The exact incidence of typhlitis is not known. The percentages reported in the literature vary from 2.8 to 5% of patients admitted for acute abdomen during chemotherapy treatments [12, 13]. This percentage, however, concerns both hematological and oncological patients. It is not known what is the exact incidence of typhlitis in the treatment of solid tumors, but it seems that the most involved chemotherapy drugs are taxanes, both in monotherapy and in combined regimens [14–19].

The clinical presentation is characterized by abdominal pain, neutropenia, and fever, although some patients may not present all of these symptoms [20]. Differential diagnosis involves the exclusion of *Clostridium difficile* infection, appendicitis, and colitis due to chemotherapy regimens [21–23]. Computed tomography (CT) scan provides a radiological diagnosis, although abdominal ultrasound can be a valuable first aid as well [24, 25]. The proper diagnosis can only be achieved based on histological tissue, which, however, is not always feasible in living patients. In fact, a possible discrepancy between radiological and histological diagnosis is reported in the literature [26]. Some criteria have been suggested to facilitate the clinical diagnosis of typhlitis. In particular, there are major criteria (neutropenia, fever, and wall thickening >4 mm detected by ultrasonography or CT) and minor criteria (nonspecific symptoms, such as abdominal pain, diarrhea, and melena) [27].

In the literature, it can be seen that this effect tends to occur early, about 1 week after the chemotherapy treatment and classically, although not necessarily, at the first administration of the treatment [15, 28]. The risk of serious complications is high as well as mortality. Furthermore, there is a risk of recurrence in patients treated conservatively [13]. The treatment options are, in fact, both conservative and surgical. In the literature on guidelines to the best treatment, there are some suggestions to identify patients at higher risk of perforation and who may need an early surgery [29–31]. As far as medical treatment is concerned, therapy consists of the use of broad-spectrum antibiotics, hydration, bowel rest, transfusion of concentrated red blood cells in case of severe anemia, platelets in case of relevant thrombocytopenia, and, if needed, insertion of gastric nose tube and parenteral nutrition [32, 33]. Clinical improvement of pain symptoms should be obtained with resolution of fever and with the increase in the absolute value of neutrophils. If the fever does not disappear after 48 h from the start of antibiotic therapy, the addition of an intravenous anti-fungal agent should be evaluated, as a fungal co-infection is possible in 20% of cases (classically *Candida albicans*) [34]. It appears that some pathogens, like *Clostridium septicum*, are associated with an increased risk of complications [22]. On the other hand, there are no recommendations on the use of granulocyte colony stimulating factor (G-CSF), which could even be harmful in some cases [22, 35]. Once the fever has resolved and the neutrophil count has increased, complications and the risk of perforation are not avoided yet [36]. In the absence of clinical benefit and in the presence of hemodynamic changes, the patient should be rapidly discussed with the surgeon for re-evaluation and possible surgery [21, 37, 38]. It has been reported that the presence of neutropenia should not be



**Fig. 1.** CT scan image.

considered as a contraindication to surgery [39]. The mortality rate is high (32–50%), although it has been improving in recent years thanks to more efficient medical treatments [13].

### Case Report

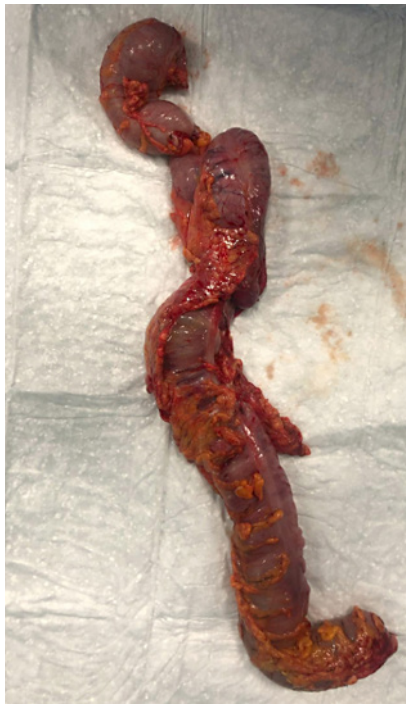A 22-year-old woman came to our attention when she was sent to us by the sinologist for the appearance, during breastfeeding, of a right breast lump. She underwent biopsy, which was positive for infiltrating ductal carcinoma with estrogen 5%, progesterone 70%, GATA3, GCDP15 (focal), E-cadherin, basal markers 8CK5/6, EGFR, and focally p63, negative for Her2, chromogranin, and synaptophysin. The proliferation rate (ki67) was 95%.

A positron emission tomography (PET) scan was performed and showed intense accumulation of the metabolic tracer by the known lesion occupying the right mammary gland, multiple lymphadenopathies in the right axillary site (the largest having a maximum diameter of about 21 mm), and, of lesser intensity, a lymphadenopathy along the right internal breast chain. Furthermore, metabolic accumulation was detected at a pulmonary nodule located in the basal segment of the right lower lobe, 16 × 12 mm in size, strongly suspected of being a malignancy.

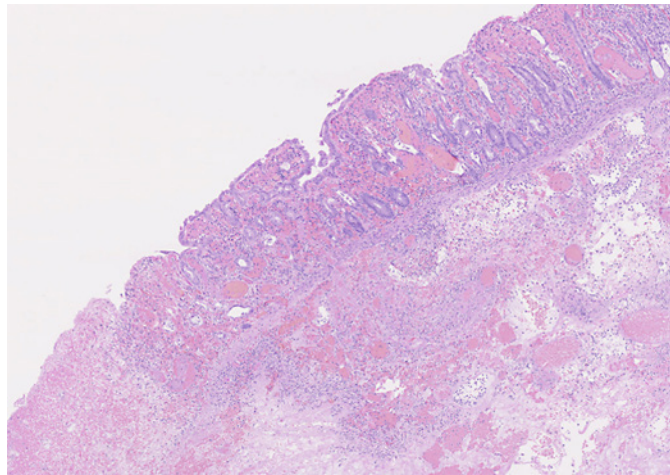
The patient had no comorbidity and was in excellent condition, according to her young age. She had a term pregnancy 2 years before and she was still breastfeeding her child at the time of the diagnosis. No other causes for hospitalization and no family history of cancer were reported. She had normal body mass index, no history of smoking, nor alcohol habits. She had a good blood exam and a normal cardiac ultrasound; so, she was started on a regimen with docetaxel 75 mg/m<sup>2</sup>, doxorubicin 50 mg/m<sup>2</sup>, and cyclophosphamide 600 mg/m<sup>2</sup> (TAC regimen) with GCSF support (pegfilgrastim 24 h after chemotherapy).

On the seventh day, the patient came to the oncology ward for abdominal pain that she scored as 8 (VAS scale), obstinate constipation since the day of therapy, and fever. She was found to be neutropenic (neutrophil count 500/mm<sup>3</sup>) despite the use of GCSF support after chemotherapy. A CT scan showed severe thickening of the ascending colon, part of the caecum and of the proximal transverse colon; the distal transverse colon was normal. The pathological thickness was measured as 15 mm with diffuse hyperemia of the mucosa and marked hypodensity of the submucosa (Fig. 1).

Neutropenic enterocolitis (typhlitis) was diagnosed, and we aimed to manage the case with medical treatment which consisted of empiric broad-spectrum antibiotic therapy (piper-



2



3

**Fig. 2.** Image of the resected colon.**Fig. 3.** Image of the pathological anatomy.

acillin/tazobactam and amikacin), GCSF (filgrastim 30 one administration per day that was continued for 2 days until neutrophil count was  $>1,000/\text{mm}^3$ ), hydration, bowel rest, and parenteral nutrition.

After 2 days from hospitalization and antibiotic therapy, the neutrophilic count was normal, the fever was gone, but the abdominal pain was getting worse. So, she underwent a second CT scan which reported an increased circumferential thickness of the transverse colon (16 vs. 14 mm) involving almost the entire transverse colon. A surgical evaluation indicated the need for surgery; so, the patient underwent a right hemicolectomy with resection of the caecum and right and transverse colon till the splenic flexure with lateral ileostomy (Fig. 2).

The histological examination showed widespread full-thickness necrotic phenomena with the presence of granulocytic infiltrate involving all the colic wall with extension to the pericolic adipose tissue and to the visceral peritoneum (Fig. 3).

## Discussion

In our clinical case, the patient developed neutropenic enterocolitis despite the prophylaxis with GCSF. The possibility of neutropenic enteritis has been reported in the literature in spite of prophylaxis with growth factors in chemotherapy combination regimens, such as TAC regimen (docetaxel, adriamycin, cyclophosphamide). Interestingly, in a retrospective study published by Singh et al. [15], 85% of patients who had died of typhlitis had multi-drug chemotherapy; in those regimens, typhlitis had occurred despite the use of GCSF; doxorubicin was the most common docetaxel-associated drug; typhlitis had never occurred in patients treated with docetaxel in monotherapy with GCSF support [6]. These factors can identify some treatment regimens associated with a major risk of typhlitis, but it is not possible to predict the individual risk of the patient. In our case, the patient was young and without any comorbidity.

We aimed to treat the patient with conservative treatment, but, regardless of the quick diagnosis and the rapid start of broad-spectrum empirical antibiotic therapy, the patient did not improve clinically, and surgery was required. In the literature, there is no consensus on the best management of typhlitis, but it is a shared opinion that in case of absence of clinical improvement and at the first signs of hemodynamic alteration or organ failure, surgery must be considered as the safest choice. Neutropenia in these patients should not discourage the clinician from surgery [11].

Our patient underwent a colic resection and was discharged with complete recovery. There are no recommendations in the literature about the safeness of further chemotherapy in patients who had a previous neutropenic enterocolitis. What we know is that there is a risk of a second gastrointestinal event. In our case, we have chosen to restart chemotherapy when the general conditions were fully recovered, omitting docetaxel. The patient received doxorubicin + cyclophosphamide followed by weekly paclitaxel without presenting further complications.

### Conclusion

Several chemotherapy regimens used to treat solid tumors are linked to a typhlitis risk. Docetaxel is the most frequently implicated drug, even when used in monotherapy. The incidence of typhlitis is estimated around 5% of patients hospitalized for febrile neutropenia. The risk of mortality is high, although it has been decreasing in recent years thanks to the improvement of supportive medical therapy. Despite the absence and infeasibility of prospective studies, due to the low incidence of this side effect, the current literature presents very useful elements that can guide physicians towards a fast diagnosis and the best therapeutic approach.

### Statement of Ethics

The description of cases is retrospective and the people involved maintained completely anonymous. The patient included in this case report had provided written informed consent to publish the images, and the authors have no ethical conflicts to disclose.

### Disclosure Statement

The authors have no conflicts of interest to declare.

### Funding Sources

The authors received no financial support for the research, authorship, and/or publication of this article.

### Author Contributions

The corresponding author wrote the manuscript, all the co-authors contributed to collect the relevant references and reviewed the manuscript. All the authors approved the final version.



## References

- 1 Ramsingh J, Bolln C, Hodnett R, Al-Ani A. Neutropenic enterocolitis affecting the transverse colon: an unusual complication of chemotherapy. *BMJ Case Rep*. 2014 May 2;2014. pii: bcr2014204035.
- 2 Mehdi I, Al Bahrani B. Chemotherapy-induced neutropenic necrotizing enterocolitis: a review. *J Pak Med Assoc*. 2012 Jul;62(7):718–23.
- 3 Qasim A, Nahas J. *Neutropenic enterocolitis (typhlitis)*. StatPearls. Treasure Island (FL): StatPearls Publishing; 2019.
- 4 Bremer CT, Monahan BP. Necrotizing enterocolitis in neutropenia and chemotherapy: a clinical update and old lessons relearned. *Curr Gastroenterol Rep*. 2006 Aug;8(4):333–41.
- 5 Oehadian A, Fadjari TH. Neutropenic enterocolitis in breast cancer patient after taxane-containing chemotherapy. *Acta Med Indones*. 2008 Jan;40(1):29–33.
- 6 Buchinger K, Stahel R, Niggemeier V, Gubler C, Franzen D. Pemetrexed-induced neutropenic enteritis and severe cutaneous hyperpigmentation in a patient with malignant pleural mesothelioma. *Lung Cancer*. 2013 Jun;80(3):347–9.
- 7 Baandrup L, Hauggaard A, Winberg BH, Holm B. Neutropenic enterocolitis during first-line chemotherapy with carboplatin and etoposide in small cell lung cancer. *Acta Oncol*. 2011 Apr;50(3):465–7.
- 8 Shvartsbeyn M, Edelman MJ. Pemetrexed-induced typhlitis in non-small cell lung cancer. *J Thorac Oncol*. 2008 Oct;3(10):1188–90.
- 9 Hayes D Jr, Leonardo JM. Neutropenic enterocolitis in a woman treated with 5-fluorouracil and leucovorin for colon carcinoma. *N C Med J*. 2002 May-Jun;63(3):132–4.
- 10 Ferrazzì E, Toso S, Zanotti M, Giuliano G. Typhlitis (neutropenic enterocolitis) after a single dose of vinorelbine. *Cancer Chemother Pharmacol*. 2001 Mar;47(3):277–9.
- 11 Kronawitter U, Kemeny NE, Blumgart L. Neutropenic enterocolitis in a patient with colorectal carcinoma: unusual course after treatment with 5-fluorouracil and leucovorin – a case report. *Cancer*. 1997 Aug;80(4):656–60.
- 12 Abu-Sbeih H, Ali FS, Chen E, Mallepally N, Luo W, Lu Y, et al. Neutropenic enterocolitis: clinical features and outcomes. *Dis Colon Rectum*. 2019 Dec 13;63(3):381–8.
- 13 Xia R, Zhang X. Neutropenic enterocolitis: A clinico-pathological review. *World J Gastrointest Pathophysiol*. 2019 Oct;10(3):36–41.
- 14 Chen E, Abu-Sbeih H, Thirumurthi S, Mallepally N, Khurana S, Wei D, et al. Clinical characteristics of colitis induced by taxane-based chemotherapy. *Ann Gastroenterol*. 2020 Jan-Feb;33(1):59–67.
- 15 Singh P, Nayernama A, Christopher Jones S, Amiri Kordestani L, Fedenko K, Prowell T, et al. Fatal neutropenic enterocolitis associated with docetaxel use: A review of cases reported to the United States Food and Drug Administration Adverse Event Reporting System. *J Oncol Pharm Pract*. 2019 Oct 8;1078155219879494.
- 16 Gadducci A, Gargini A, Palla E, Fanucchi A, Genazzani AR. Neutropenic enterocolitis in an advanced epithelial ovarian cancer patient treated with paclitaxel/platinum-based chemotherapy: a case report and review of the literature. *Anticancer Res*. 2005 May-Jun;25(3c):2509–13.
- 17 Furonaka M, Miyazaki M, Nakajima M, Hirata S, Fujitaka K, Kondo K, et al. Neutropenic enterocolitis in lung cancer: a report of two cases and a review of the literature. *Intern Med*. 2005 May;44(5):467–70.
- 18 D’Amato G, Rocha Lima C, Mahany JJ, Muro-Cacho C, Haura EB. Neutropenic enterocolitis (typhlitis) associated with docetaxel therapy in a patient with non-small-cell lung cancer: case report and review of literature. *Lung Cancer*. 2004 Jun;44(3):381–90.
- 19 Ibrahim NK, Sahin AA, Dubrow RA, Lynch PM, Boehnke-Michaud L, Valero V, et al. Colitis associated with docetaxel-based chemotherapy in patients with metastatic breast cancer. *Lancet*. 2000 Jan 22;355(9200):281–3.
- 20 Chow EJ, Bishop KD. Painless neutropenic enterocolitis in a patient undergoing chemotherapy. *Curr Oncol*. 2016 Oct;23(5):e514–6.
- 21 Lebon D, Biard L, Buyse S, Schnell D, Lengliné E, Roussel C, et al. Gastrointestinal emergencies in critically ill cancer patients. *J Crit Care*. 2017 Aug;40:69–75.
- 22 Neshar L, Rolston KV. Neutropenic enterocolitis, a growing concern in the era of widespread use of aggressive chemotherapy. *Clin Infect Dis*. 2013 Mar;56(5):711–7.
- 23 Carrion AF, Hosein PJ, Cooper EM, Lopes G, Pelaez L, Rocha-Lima CM. Severe colitis associated with docetaxel use: A report of four cases. *World J Gastrointest Oncol*. 2010 Oct 15;2(10):390–4.
- 24 Kirkpatrick ID, Greenberg HM. Gastrointestinal complications in the neutropenic patient: characterization and differentiation with abdominal CT. *Radiology*. 2003 Mar;226(3):668–74.
- 25 Tamburrini S, Setola FR, Belfiore MP, Saturnino PP, Della Casa MG, Sarti G, et al. Ultrasound diagnosis of typhlitis. *J Ultrasound*. 2019 Mar;22(1):103–6.
- 26 Sachak T, Arnold MA, Naini BV, Graham RP, Shah SS, Cruise M, et al. Neutropenic enterocolitis: new insights into a deadly entity. *Am J Surg Pathol*. 2015 Dec;39(12):1635–42.
- 27 Gorschlüter M, Mey U, Strehl J, Ziske C, Schepke M, Schmidt-Wolf IG, et al. Neutropenic enterocolitis in adults: systematic analysis of evidence quality. *Eur J Haematol*. 2005;75(1):1–13.
- 28 Shakir FTZ, Sultan R, Siddiqui R, Shah MZ, Javed A, Coll J. Adult necrotising enterocolitis in a breast cancer patient after first cycle of adjuvant chemotherapy. *J Coll Physicians Surg Pak*. 2019 Oct;29(10):1006–8.

- 29 Machado NO. Neutropenic enterocolitis: A continuing medical and surgical challenge. *N Am J Med Sci*. 2010 Jul;2(7):293–00.
- 30 Rodrigues FG, Dasilva G, Wexner SD. Neutropenic enterocolitis. *World J Gastroenterol*. 2017 Jan 7;23(1):42–7.
- 31 Kouroussis C, Samonis G, Androulakis N, Souglakos J, Voloudaki A, Dimopoulos MA, et al. Successful conservative treatment of neutropenic enterocolitis complicating taxane-based chemotherapy: a report of five cases. *Am J Clin Oncol*. 2000 Jun;23(3):309–13.
- 32 Freifeld AG, Bow EJ, Sepkowitz KA, Boeckh MJ, Ito JI, Mullen CA, et al., Infectious Diseases Society of America. Clinical practice guideline for the use of antimicrobial agents in neutropenic patients with cancer: 2010 update by the Infectious Diseases Society of America. *Clin Infect Dis*. 2011 Feb;52(4):e56–93.
- 33 Principe DR, Koch RM, Bergsten TM, Rubin J. Chemotherapy-associated neutropenic enterocolitis of the transverse colon post right hemicolectomy. *Oxf Med Case Reports*. 2019 Dec 19;2019(11):omz140.
- 34 Duceau B, Picard M, Pirracchio R, Wanquet A, Pène F, Merceron S, et al. Neutropenic enterocolitis in critically ill patients: Spectrum of the disease and risk of invasive fungal disease. *Crit Care Med*. 2019 May;47(5):668–76.
- 35 Smith TJ, Khatcheressian J, Lyman GH, Ozer H, Armitage JO, Balducci L, et al. 2006 update of recommendations for the use of white blood cell growth factors: an evidence-based clinical practice guideline. *J Clin Oncol*. 2006 Jul;24(19):3187–205.
- 36 Rolston KV. Neutropenic enterocolitis associated with docetaxel therapy in a patient with breast cancer. *Clin Adv Hematol Oncol*. 2009 Aug;7(8):527–8.
- 37 Vergara-Fernández O, Trejo-Avila M, Solórzano-Vicuña D, Santes O, Salgado-Nesme N. Factors associated with emergent colectomy in patients with neutropenic enterocolitis. *Langenbecks Arch Surg*. 2019 May;404(3):327–34.
- 38 Bagnoli P, Castagna L, Cozzaglio L, Rossetti C, Quagliuolo V, Zago M, et al. Neutropenic enterocolitis: is there a right timing for surgery? Assessment of a clinical case. *Tumori*. 2007 Nov-Dec;93(6):608–10.
- 39 Saillard C, Zafrani L, Darmon M, Bisbal M, Chow-Chine L, Sannini A, et al. The prognostic impact of abdominal surgery in cancer patients with neutropenic enterocolitis: A systematic review and meta-analysis, on behalf the Groupe de Recherche en Réanimation Respiratoire du patient d’Onco-Hématologie (GRRR-OH). *Ann Intensive Care*. 2018 Apr;8(1):47.