

## Retrospective Study

## Risk factors for intraocular metastasis of primary liver cancer in diabetic patients: Alpha-fetoprotein and cancer antigen 125

Kang Yu, Jing Tang, Jie-Li Wu, Biao Li, Shi-Nan Wu, Meng-Yao Zhang, Qiu-Yu Li, Li-Juan Zhang, Yi-Cong Pan, Qian-Min Ge, Hui-Ye Shu, Yi Shao

**ORCID number:** Kang Yu 0000-0001-7457-8516; Jing Tang 0000-0003-3560-1941; Jie-Li Wu 0000-0001-9206-0534; Biao Li 0000-0002-7123-0321; Shi-Nan Wu 0000-0002-6992-9059; Meng-Yao Zhang 0000-0001-7105-0804; Qiu-Yu Li 0000-0002-9639-3931; Li-Juan Zhang 0000-0002-8348-8392; Yi-Cong Pan 0000-0003-2018-1307; Qian-Min Ge 0000-0001-5403-3295; Hui-Ye Shu 0000-0003-1569-3746; Yi Shao 0000-0003-1571-2433.

**Author contributions:** Shao Y obtained funding support; Yu K, Tang J and Shao Y contributed to study design; Yu K, Tang J, Shao Y and Zhang MY contributed to data collection; Wu JL and Zhang LJ performed data interpretation; Yu K, Tang J, Wu JL, Li B, Pan YC and Ge QM performed the statistical analysis; Yu K, Tang J, Wu SN, Li QY and Shu HY conducted the literature search; Yu K and Shao Y prepared the manuscript.

**Supported by** The National Natural Science Foundation of China, No. 81400372 and 81660158; the Key Research and Development Plan of Jiangxi Province, No. 20181BBG70004; the Young Scientists Fund of Jiangxi Province, No. 20161ACB21017 and 20151BAB215016; the Science and Technology Plan Project of Jiangxi

Kang Yu, Biao Li, Shi-Nan Wu, Meng-Yao Zhang, Qiu-Yu Li, Li-Juan Zhang, Yi-Cong Pan, Qian-Min Ge, Hui-Ye Shu, Yi Shao, Department of Ophthalmology, The First Affiliated Hospital of Nanchang University, Nanchang 330006, Jiangxi Province, China

**Jing Tang**, Department of Oncology, The Affiliated Zhuzhou Hospital Xiangya Medical College, Central South University, Zhuzhou 412000, Hunan Province, China

**Jie-Li Wu**, Department of Ophthalmology, Xiang'an Hospital of Xiamen University, Xiamen 361102, Fujian Province, China

**Corresponding author:** Yi Shao, MD, PhD, Director, Doctor, Department of Ophthalmology, The First Affiliated Hospital of Nanchang University, No. 17 Yongwaizheng Street, Donghu District, Nanchang 330006, Jiangxi Province, China. [freebee99@163.com](mailto:freebee99@163.com)

## Abstract

## BACKGROUND

In rare instances, primary liver cancer can be associated with intraocular metastasis (IOM).

## AIM

To investigate the correlation between a diverse range of clinical characteristics and IOM in diabetic patients with primary liver cancer, and to determine potential risk factors in predicting IOM.

## METHODS

We recruited a total of 722 diabetic patients with primary liver cancer. The differences between the IOM and non-intraocular metastasis (NIOM) groups in these patients were assessed using the chi-squared test and Student's *t*-test. Binary logistic regression analysis was subsequently used to determine risk factors. Finally, the diagnostic value of IOM in this cohort with primary liver cancer was analyzed by receiver operating characteristic (ROC) curve analysis.

## RESULTS

In all, 13 patients had IOM. There were no remarkable intergroup differences with respect to age, sex, histopathological sub-types, or blood biochemical parameters. However, the IOM group had significantly higher alpha-fetoprotein (AFP) and cancer antigen 125 (CA125) values than the NIOM group. Binary logistic

Province, No. 20151BBG70223; and the Distinguished Young Scientists Fund of Jiangxi Province, No. 20192BCBL23020.

#### Institutional review board

**statement:** This study was reviewed and approved by the Medical Ethics Committee of the First Affiliated Hospital of Nanchang University.

#### Informed consent statement:

Informed consent was obtained from the patients included in this study.

**Conflict-of-interest statement:** This was not an industry supported study. The authors report no conflicts of interest in this work.

**Data sharing statement:** The datasets generated during and/or analyzed during the current study are available from the corresponding author on reasonable request.

**Open-Access:** This article is an open-access article that was selected by an in-house editor and fully peer-reviewed by external reviewers. It is distributed in accordance with the Creative Commons Attribution NonCommercial (CC BY-NC 4.0) license, which permits others to distribute, remix, adapt, build upon this work non-commercially, and license their derivative works on different terms, provided the original work is properly cited and the use is non-commercial. See: <http://creativecommons.org/licenses/by-nc/4.0/>

**Manuscript source:** Unsolicited manuscript

**Specialty type:** Endocrinology and metabolism

**Country/Territory of origin:** China

#### Peer-review report's scientific quality classification

Grade A (Excellent): 0  
Grade B (Very good): B  
Grade C (Good): C, C  
Grade D (Fair): 0  
Grade E (Poor): 0

regression identified AFP and CA125 to be significant risk factors for IOM in diabetic patients with primary liver cancer. ROC curve analysis showed that the area under the curve values for AFP and CA125 were 0.727 and 0.796, with the cut-off values of 994.20 ng/mL and 120.23 U/mL, respectively. The sensitivity and specificity for AFP were 92.3% and 59.9%, while those for CA125 were 84.6% and 70.1%, respectively.

#### CONCLUSION

Elevated AFP and CA125 represent significant risk factors for IOM in diabetic patients with primary liver cancer.

**Key Words:** Primary liver cancer; Intraocular metastasis; Diabetes; Alpha-fetoprotein; Cancer antigen 125; Risk factors

©The Author(s) 2021. Published by Baishideng Publishing Group Inc. All rights reserved.

**Core Tip:** This is a retrospective study designed to evaluate the risk factors for ocular metastasis in patients with diabetic primary liver cancer. Elevated alpha-fetoprotein (AFP) and cancer antigen 125 (CA125) represent significant risk factors for intraocular metastasis (IOM) in diabetic patients with primary liver cancer. Notably, the combination of AFP and CA125 is more reliable for differentiation between IOM and non-intraocular metastasis in diabetic patients with primary liver cancer.

**Citation:** Yu K, Tang J, Wu JL, Li B, Wu SN, Zhang MY, Li QY, Zhang LJ, Pan YC, Ge QM, Shu HY, Shao Y. Risk factors for intraocular metastasis of primary liver cancer in diabetic patients: Alpha-fetoprotein and cancer antigen 125. *World J Diabetes* 2021; 12(2): 158-169

**URL:** <https://www.wjgnet.com/1948-9358/full/v12/i2/158.htm>

**DOI:** <https://dx.doi.org/10.4239/wjd.v12.i2.158>

## INTRODUCTION

Primary liver carcinoma is among the most frequent causes of cancer-related deaths worldwide and shows increasing rates of incidence and mortality. In China, primary liver carcinoma is the fourth most common malignant tumor and the third major cause of tumor-associated deaths, and therefore a significant public health threat. This disease has a relatively high incidence among the middle aged (45-64 years old) and elderly population (> 65 years old). Of the various types of primary liver cancers, hepatocellular carcinoma (HCC) and intrahepatic cholangiocarcinoma (ICC) are the most common, accounting for approximately 70% and 15% of all diagnosed cases, respectively<sup>[1]</sup>. The main risk factors of HCC involve hepatitis B virus (HBV) or hepatitis C virus (HCV) infection, alcoholic liver diseases, and nonalcoholic fatty liver disease. Chronic HBV and HCV infection regulate the pathogeny of HCC in low- and middle-income countries; furthermore, aflatoxin exposure leads to HCC progression in Africa and East Asia<sup>[2]</sup>. The most reliable approach to minimize HCC risk is to prevent the potential hepatopathy by means such as hepatitis B vaccination. Less common causes of HCC involve hereditary hemochromatosis, alpha1-antitrypsin deficiency, autoimmune hepatitis, some types of porphyria, and Wilson's disease<sup>[3]</sup>. In recent years, it was found that diabetes and cancer are related diseases that may co-exist in the same individual<sup>[4]</sup>. An increasing body of significant evidence suggests that patients with diabetes have a greater risk of developing certain cancers, especially primary hepatic cancer<sup>[5]</sup>.

Our previous study showed that carbohydrate antigen 125, calcium, and hemoglobin can be predictive clinical indicators for ocular metastasis in male liver cancer patients<sup>[6]</sup>. However, things may be different when it comes to diabetic patients with primary liver cancer.

The most common mode of ICC dissemination is intrahepatic, involving the venous system<sup>[7]</sup>. A variety of signaling pathways dominate the expression of metastasis-associated genes in primary liver carcinoma<sup>[8]</sup>. Overexpression of vascular endothelial cell growth factor and epidermal growth factor receptor are associated with

**Received:** October 8, 2020

**Peer-review started:** October 8, 2020

**First decision:** November 18, 2020

**Revised:** November 26, 2020

**Accepted:** December 11, 2020

**Article in press:** December 11, 2020

**Published online:** February 15, 2021

**P-Reviewer:** Nakajima K,  
Papazafropoulou A

**S-Editor:** Chen XF

**L-Editor:** Webster JR

**P-Editor:** Ma YJ



intrahepatic metastases and perineural, lymph-vascular aggression, respectively, in ICC<sup>[7]</sup>.

Hepatocellular carcinoma, the major form of primary liver cancer, is specifically widespread in Southeast Asia involving areas of China. Extrahepatic metastases (EHM) of HCC are commonly observed in sites such as the lung, lymph nodes, bone and adrenal gland<sup>[9]</sup>.

Although primary liver carcinoma metastasis to the eye is rare, intraocular metastasis (IOM) is closely associated with primary liver carcinoma. The detection, diagnosis, and management of IOM in the early stages are extremely important for good outcomes. IOM is more common in middle-aged patients; the average age of subjects in different series being around 60 years<sup>[10]</sup>. The overall prognosis of IOM is poor, with proptosis and diplopia being the most frequent presenting features, per a previous report<sup>[10]</sup>. The treatment for IOM aims at reducing the chance of visual impairment and improving the quality of life of patients. Radiotherapy is the main choice of treatment, as it can effectively control regional progression of the cancer and preserve vision. Metastasis to the choroid of HCC can be treated with focal plaque brachytherapy, with conservation of vision<sup>[11]</sup>. It is noteworthy that the clinical significance and underlying laboratorial value of diagnosing IOM has increased in the past few years owing to the expanding role of chemotherapy and radiation in the treatment of metastatic disease<sup>[12]</sup>. Because the eye provides a distinct opportunity for the imagery and identification of even a micro focus of neoplasm, treatment can be designed without delay and the effect observed immediately.

Imaging plays a crucial role in the diagnosis of primary liver carcinoma. The diagnostic criteria for HCC are mainly based on the visualization of neoangiogenesis<sup>[13]</sup>. The prompt detection of IOM may significantly influence the choice of treatment for primary liver carcinoma. Consequently, there is an urgent need to identify the potential risk factors of IOM in patients with primary liver carcinoma and determine clinically meaningful predictors.

Therefore, the aim of this retrospective research was to detect the potential risk factors for IOM by investigating a range of clinicopathological parameters and biomarkers in diabetic patients with primary liver carcinoma.

## MATERIALS AND METHODS

### Study design

This retrospective study was performed between January 1998 and May 2015, and involved a series of 722 consecutive middle-age and elderly diabetic patients diagnosed with primary liver cancer. All the patients were treated at the Endocrinology Department of the First Affiliated Hospital of Nanchang University. The diagnosis in all cases with primary liver cancer was confirmed by histopathological analysis of specimens obtained through needle biopsy or radical nephrectomy. The diagnosis of IOM was confirmed using computed tomography or magnetic resonance imaging. Patients with primary intraocular carcinoma and those with secondary liver carcinoma were excluded from the study. The experimental design was explained to each patient and written informed consent was obtained.

### Data collection

For each diabetic participant, we retrospectively recorded a range of demographic and clinical characteristics, including sex, age at the time of diagnosis of the primary tumor, histopathological tumor sub-type, sites of metastases, and treatments received. We also retrospectively recorded the plasma levels of several tumor biomarkers including alpha-fetoprotein (AFP), carcinoembryonic antigen (CEA), cancer antigen 125 (CA125), cancer antigen 199 (CA199), cancer antigen 153 (CA153), cancer antigen 724 (CA724), ferritin (FER), and alkaline phosphatase (ALP), and the serum levels of total cholesterol (TC), triglycerides (TG), high density lipoprotein (HDL), low density lipoprotein (LDL), apolipoprotein A1 (ApoA1), apolipoprotein B (ApoB), lipoprotein A [Lp(a)], calcium and hemoglobin (Hb). We subsequently analyzed the incidence of IOM, and investigated data for the potential correlation between clinical parameters and IOM.

### Statistical analysis

The chi-squared test and Student's *t*-test were applied to determine differences in clinical characteristics between the IOM and non-intraocular metastasis (NIOM) groups. Subsequently, binary logistic regression analysis was conducted to confirm

potential risk factors of IOM. In addition, receiver operating characteristic curves were plotted, and area under the curve (AUC) values were used to evaluate the accuracy in predicting IOM. *P* values less than 0.05 were considered statistically significant. SPSS17.0 software (SPSS; IBM Corp, United States) or Excel 2016 software (Excel; Microsoft Corp, United States) were used for all statistical analyses in this study.

## RESULTS

### *Demographics and clinical characteristics*

Overall, 722 diabetic patients with primary liver cancer were recruited into this study. The demographic data are shown in Table 1 and Figure 1. The majority of patients were male ( $n = 619$ , 85.7%). Of the 722 patients, 13 were diagnosed with IOM. The mean age of patients in the IOM and NIOM groups was  $53.62 \pm 8.61$  years and  $58.66 \pm 9.66$  years, respectively. There were no significant intergroup differences in terms of age, sex, and histopathological sub-type ( $P > 0.05$ ). However, treatment received was significantly different between the two groups ( $P < 0.05$ ).

### *Clinical features as risk factors for IOM*

Our analysis showed that the levels of AFP and levels of CA125 were significantly higher ( $P < 0.05$ ) in the IOM group than in the NIOM group. There were no significant intergroup differences in the levels of CEA, CA199, CA153, CA724, FER, ALP, TC, TG, HDL, LDL, ApoA1, ApoB, Lp(a), calcium or Hb (Table 2). Furthermore, binary logistic regression analysis showed that AFP and CA125 levels were independent risk factors for IOM. The value of AFP was 1.001 (1.000-1.001) and that of CA125 was 1.001 (1.000-1.002), both of which were statistically significant ( $P < 0.05$ ) (Table 3).

### *Cut-off value, AUC, sensitivity and specificity values for AFP and CA125 in the prediction of IOM*

The AUC value for AFP was 0.727, and the associated sensitivity and specificity values for predicting IOM were 92.3% and 59.9%, respectively. The AUC value for CA125 was 0.796, and the associated sensitivity and specificity values for predicting IOM were 84.6% and 70.1%, respectively. These data are based on cut-off values of 994.20 ng/mL and 120.23 U/mL for AFP and CA125, respectively. We also found that the combination of AFP and CA125 data exhibited higher AUC (0.860) and specificity (89.3%) values. All results were statistically significant ( $P < 0.05$ ) (Figures 2-4, Table 4).

## DISCUSSION

Primary liver cancer is a major cause of tumor-associated mortality worldwide with increasing incidence. Although several treatment options such as ablation, surgical resection, and liver transplantation are available for primary liver cancer, the treatment is still complicated, because considerations involve not only the cancer pathology and liver anatomy but also the hepatic function and the general condition of patients. Moreover, distant metastasis is the main characteristic of malignancy. In China, many patients suffer from primary liver cancer, with some patients, especially in the middle and elderly age groups, having already developed regional or distant metastases at diagnosis. Hence, providing optimal treatment is challenging. While IOM of primary liver cancer is relatively uncommon, it is a predictor of unfavorable prognosis. Therefore, confirmation of cancer with IOM in the early stage is critical.

To date, carcinoma-related IOM has been reported in patients with rectal cancer<sup>[14]</sup>, lung cancer<sup>[15]</sup>, breast cancer<sup>[16]</sup>, esophageal carcinoma<sup>[17]</sup>, thyroid cancer<sup>[18]</sup>, gastric carcinoma<sup>[19]</sup>, renal cancer<sup>[20]</sup>, and choriocarcinoma<sup>[21]</sup> (Table 5).

Previous studies<sup>[22-29]</sup> on the risk factors for local or distant metastases of primary liver cancer are shown in Table 6. The potential of tumor markers to predict metastases of carcinoma and address the limitations of imaging examinations is indicated (Figure 5)<sup>[30-32]</sup>. The content of serological tumor markers also changed when different tumors had IOM. Serological detection and imaging detection have different advantages, and the combination of the two can more accurately determine the occurrence and stage of tumors (Table 6).

Tumor markers can be detected in blood, cerebrospinal fluid, or serous fluid, and tumor-marker evaluation has been used in tumor screening as well as for prognostic analysis. As one of the earliest discovered protein tumor markers, AFP has found

**Table 1 Clinical features of diabetic patients with primary liver cancer**

Patient characteristics	IOM group (%)	NIOM group (%)	Total numbers of patients (%)	P value
Age (yr) <sup>1</sup>	53.62 ± 8.61	58.66 ± 9.66		0.062
< 65	11 (84.6)	520 (73.3)	531 (73.5)	
≥ 65	2 (15.4)	189 (26.7)	191 (26.5)	
Gender <sup>2</sup>				0.777
Men	12 (92.3)	607 (85.6)	619 (85.7)	
Women	1 (7.7)	102 (14.4)	103 (14.3)	
Treatment <sup>2</sup>				0.015
Surgical resection	2 (15.4)	45 (6.3)	47 (6.5)	
Chemotherapy	5 (38.5)	102 (14.4)	107 (14.8)	
Other treatments	6 (46.2)	562 (79.3)	568 (78.7)	
Histopathological type <sup>2</sup>				0.317
HCC	0	122 (17.2)	122 (16.9)	
ICC	0	28 (3.9)	28 (3.9)	
cHCC-ICC	0	2 (0.3)	2 (0.3)	
Unclear	13 (100)	557 (78.6)	570 (78.9)	
HbA1c	6.04 ± 0.54	6.23 ± 0.67	-	0.892

<sup>1</sup>Indicates Student's *t*-test was used.

<sup>2</sup>Indicates Chi-squared test was used. *P* < 0.05 represents statistical significance. IOM: Intraocular metastasis; NIOM: Non-intraocular metastasis; HCC: Hepatocellular carcinoma; ICC: Intrahepatic cholangiocarcinoma; cHCC-ICC: Combined hepatocellular carcinoma and intrahepatic cholangiocarcinoma.

considerable experimental and clinical acceptance and application. AFP is a 67-kDa glycoprotein produced in the early fetal stage by the liver, or later by various carcinomas such as HCC and hepatoblastoma and ovarian and testicular non-spermatogonial germ cells<sup>[33]</sup>. In the sera of normal healthy individuals, the concentrations of AFP are < 20 ng/mL. In patients with HCC, increased AFP levels could be prognostic indicators in the case of large tumors, advanced cancer stage, EHM, portal vein thrombosis, and recurrence after liver transplantation resulting in poor prognosis. Although its application in HCC screening and diagnosis is debatable, AFP levels have been used to guide therapeutic decision-making in HCC and manage the overall treatment in recent years<sup>[34]</sup>. Additionally, AFP is now considered a significant marker of postoperative HCC relapse and metastasis. Increased AFP level plays a crucial role in accelerating tumor growth and distant metastasis of HCC cells by increasing the expression of metastasis-associated proteins. The molecular mechanism by which AFP accelerates metastasis of HCC cells is by activating the phosphatidylinositol 3-kinase/protein kinase B signaling pathway to stimulate expression of metastasis-related factors such as CXC motif chemokine receptor 4. Liu *et al*<sup>[35]</sup> found that AFP levels ≥ 20000 ng/mL confirm HCC with portal vein tumor thrombosis (PVTT), thereby providing significant guidance for clinical practice. Our results indicated that elevated AFP is a risk factor for IOM in diabetic patients with primary liver cancer, because patients with AFP levels > 994.20 ng/mL were prone to IOM.

CA125, also known as mucin 16, is a large transmembrane glycoprotein, the largest of the class of membrane-associated mucins to which it belongs<sup>[36]</sup>. In addition, a previous study indicated that CA125 was overexpressed in 80% of cases with epithelial ovarian cancer<sup>[37]</sup>. CA125 is a useful tumor marker for early diagnosis and monitoring of the reaction to chemotherapy in epithelial ovarian cancer, and routine testing of CA125 levels after initial therapy can help detect cancer recurrence several months before laboratorial evidence or clinical signs of the disease. Since it was introduced in 1983, CA125 has been used worldwide in the management of patients with ovarian cancer. Yuan *et al*<sup>[38]</sup> reported that CA125 promotes ovarian cancer cell invasion through the Wnt signaling pathway, and presented a cut-off value of 82.9 U/mL, which was likely to indicate metastasis of ovarian cancer. Furthermore, CA125 has also



**Table 2 Differences in the concentration of various tumor biomarkers between patients with and without intraocular metastasis**

Clinical features	IOM group	NIOM group	t	P value
AFP	1030.37 ± 342.38	526.37 ± 587.16	-5.17	< 0.001
CEA	6.54 ± 14.75	389.37 ± 10012.62	0.138	0.89
CA125	419.78 ± 356.43	148.03 ± 305.88	-3.165	0.002
CA199	200.35 ± 329.82	314.22 ± 4482.59	0.092	0.927
CA153	19.81 ± 15.06	20.32 ± 23.28	0.078	0.938
CA724	6.68 ± 8.44	6.91 ± 12.32	0.066	0.947
FER	198.23 ± 52.50	259.43 ± 224.57	0.981	0.327
ALP	192.54 ± 94.07	174.15 ± 171.39	-0.386	0.7
TC	4.75 ± 1.20	5.14 ± 8.62	0.161	0.872
TG	1.44 ± 0.81	1.37 ± 1.03	-0.257	0.797
HDL	1.30 ± 0.64	1.50 ± 1.17	0.602	0.548
LDL	2.52 ± 1.16	2.58 ± 1.43	0.144	0.885
ApoA1	1.65 ± 0.45	1.57 ± 0.87	-0.331	0.741
ApoB	0.77 ± 0.32	1.10 ± 0.82	1.426	0.154
Lp(a)	181.92 ± 219.72	221.66 ± 240.54	0.591	0.555
Ca	14.56 ± 44.90	2.14 ± 0.27	-0.997	0.338
Hb	114.69 ± 43.54	117.19 ± 22.31	0.207	0.84

$P < 0.05$  represents statistical significance. IOM: Intraocular metastasis; NIOM: Non-intraocular metastasis; AFP: Alpha-fetoprotein; CEA: Carcinoembryonic antigen; CA: Cancer antigen; FER: Ferritin; ALP: Alkaline phosphatase; TC: Total cholesterol; TG: Triglyceride; HDL: High density lipoprotein; LDL: Low density lipoprotein; ApoA1: Apolipoprotein A1; ApoB: Apolipoprotein B; Lp(a): Lipoprotein A; Ca: Calcium; Hb: Hemoglobin.

**Table 3 The binary logistic regression results**

Factors	B	OR	OR (95%CI)	P value
AFP	0.001	1.001	1.000-1.001	0.01
CA125	0.001	1.001	1.000-1.002	0.036

$P < 0.05$  represents statistical significance. B: Coefficient of regression; OR: Odds ratio; CI: Confidence interval; AFP: Alpha-fetoprotein; CA125: Cancer antigen 125.

**Table 4 The receiver operating characteristic results of risk factors for predicting intraocular metastasis in diabetic liver cancer patients**

	Cut-off value	Sensitivity (%)	Specificity (%)	AUC	95%CI	P value
AFP	994.20	0.923	0.599	0.727	0.627-0.827	0.005
CA125	120.23	0.846	0.701	0.796	0.678-0.915	< 0.001
AFP + CA125		0.769	0.893	0.860	0.745-0.975	< 0.001

$P < 0.05$  represents statistical significance. AUC: Area under the curve; CI: Confidence interval; AFP: Alpha-fetoprotein; CA125: Cancer antigen 125.

been tested in the sera of patients with primary liver cancer. Li *et al*<sup>[39]</sup> analyzed the medical records of 60 patients (30 patients with HCC and 30 with ICC) and found that joint detection of CA125, AFP, CA199, and CEA was of great importance in the diagnosis of ICC. In another study, Liu *et al*<sup>[35]</sup> reported that AFP levels > 32.91 ng/mL and CA125 levels > 113.65 U/mL can detect HCC with PVT. Our results demonstrate that CA125 is a risk factor for IOM in primary liver cancer, with a cut-off value of

**Table 5 Studies on the intraocular metastasis from different cancers**

Ref.	Diseases with IOM
Tei <i>et al</i> <sup>[14]</sup> , 2014	Rectal cancer
Shah <i>et al</i> <sup>[15]</sup> , 2014	Lung cancer
Levison <i>et al</i> <sup>[16]</sup> , 2018	Breast cancer
Chang <i>et al</i> <sup>[17]</sup> , 2018	Esophageal carcinoma
Fountas <i>et al</i> <sup>[18]</sup> , 2017	Thyroid cancer
Wu <i>et al</i> <sup>[19]</sup> , 2019	Gastric carcinoma
Essadi <i>et al</i> <sup>[20]</sup> , 2017	Renal cancer
Hazan <i>et al</i> <sup>[21]</sup> , 2014	Choriocarcinoma

IOM: Intraocular metastasis.

**Table 6 The risk factors for metastases from primary liver cancer**

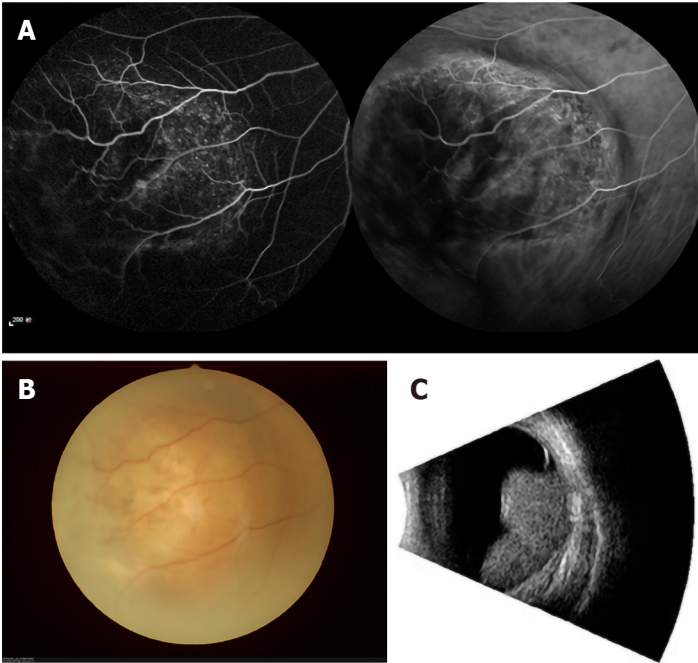
Ref.	Histopathological type	Metastatic sites	Risk factor
Lin <i>et al</i> <sup>[22]</sup> , 2003	HCC	Lung	Tumor size
Ogawa <i>et al</i> <sup>[23]</sup> , 2004	HCC	Distant metastasis	CD44v3
Xiang <i>et al</i> <sup>[24]</sup> , 2009	HCC	Bone	CXCR4
Lin <i>et al</i> <sup>[25]</sup> , 2010	HCC	Vessel	Aurora B
Kwak <i>et al</i> <sup>[26]</sup> , 2012	HCC	Peritoneum	HCC rupture
Morimoto <i>et al</i> <sup>[27]</sup> , 2014	HCC	EHM	Platelet, DCP
Chen <i>et al</i> <sup>[28]</sup> , 2015	Small HCC	IHM and EHM	VEGF
Lee <i>et al</i> <sup>[29]</sup> , 2019	HCC	EHM	AFP

HCC: Hepatocellular carcinoma; EHM: Extrahepatic metastasis; IHM: Intrahepatic metastasis; CD44v3: CD44 variant exon 3; CXCR4: CXC motif chemokine receptor 4; DCP: Des-γ-carboxyprothrombin; VEGF: Vascular endothelial growth factor; AFP: Alpha-fetoprotein.

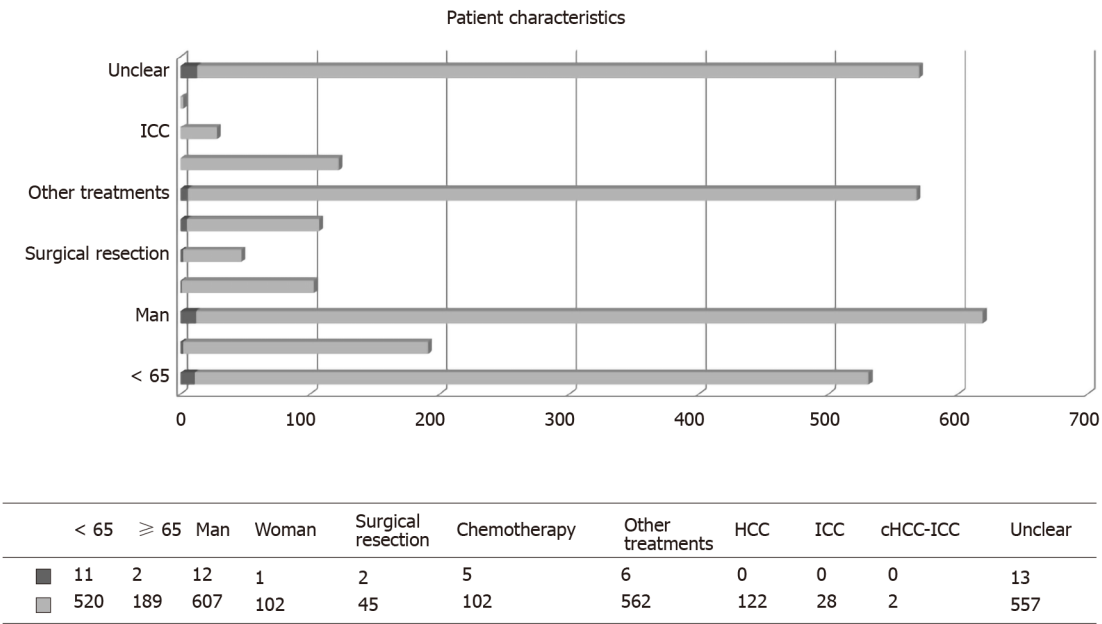
120.23 U/mL. In addition, diabetes is often accompanied by various secondary diseases. Although cancer is generally considered a genetically controlled disease. Related studies have shown that the metabolic characteristics of various cancers are consistent with the metabolic changes in diabetic patients<sup>[40]</sup>. Furthermore, data analysis has also shown that the probability of diabetic patients suffering from HCC is 2-3 times that of patients without diabetes<sup>[41]</sup>. To date, there is no direct evidence that diabetic patients are more likely to develop eye metastases from liver cancer. However, some studies have shown that diabetes is significantly related to eye diseases such as retina diseases and liver diseases such as cirrhosis<sup>[42,43]</sup>. Combined with the data from our research, we speculate that diabetic patients are relatively more likely to develop liver cancer ocular metastasis. However, this requires further clinical data to confirm. Thus, diabetic patients with primary liver cancer whose CA125 levels were > 120.23 U/mL were more prone to IOM.

A combination of AFP and CA125 levels showed higher specificity than either level alone in predicting IOM in diabetic patients with primary liver cancer. In addition, AUC results showed higher accuracy of combined AFP and CA125 than either level alone in differentiating between patients with IOM and NIOM. Overall, combined AFP and CA125 levels appeared to be more useful in predicting IOM than either level alone.

Our study has some limitations. First, it was a retrospective study with insufficient data in the IOM group, which may have affected the overall analysis. Second, owing to the long period of time, some patient data, such as for prognosis, were either unknown or missing. Third, the number of cases with IOM was very low, so it is necessary to further expand the sample size in future studies to obtain more accurate results. In addition, all patients were from the same hospital, which may have led to inherent



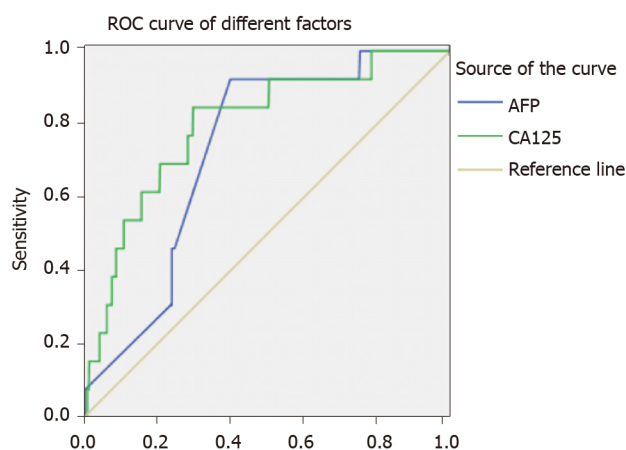
**Figure 1** Example of patients with intraocular metastasis seen on fluorescence fundus angiography, fundus camera and eye B ultrasound, respectively. A: Fluorescence fundus angiography; B: Fundus camera; C: Eye B ultrasound.



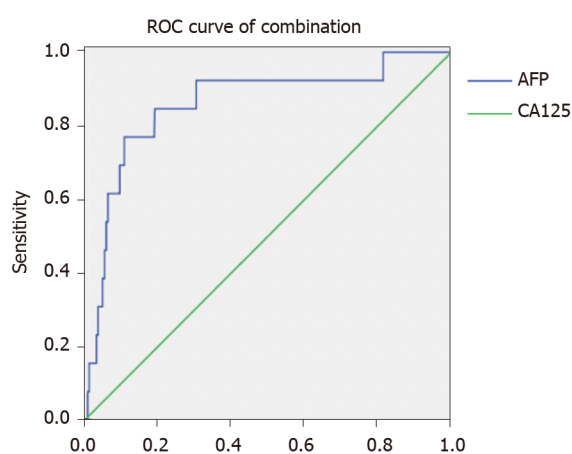
**Figure 2** Clinical features of patients with and without intraocular metastasis. Blue represents age, sex, treatments, and histopathological type in the intraocular metastasis group; red represents age, sex, treatment, and histopathological type in the non-intraocular metastasis group. “Unclear” means that the histopathological type is unclear. HCC: Hepatocellular carcinoma; ICC: Intrahepatic cholangiocarcinoma; cHCC-ICC: Combined hepatocellular carcinoma and intrahepatic cholangiocarcinoma.

confounding factors. Furthermore, we only found altered serum concentrations of AFP and CA125 in diabetic patients with IOM of primary liver cancer. Therefore, how these two factors change remains unclear. Finally, in the basic clinical characteristics of diabetic patients, statistics on body mass index (BMI), smoking history and other clinical complications are not performed, which may cause errors in the statistical results. Pairing the patient’s BMI with diabetes, smoking history, and other clinical complications will make the results more accurate and more convincing. We will further study their potential relationships in future experiments.





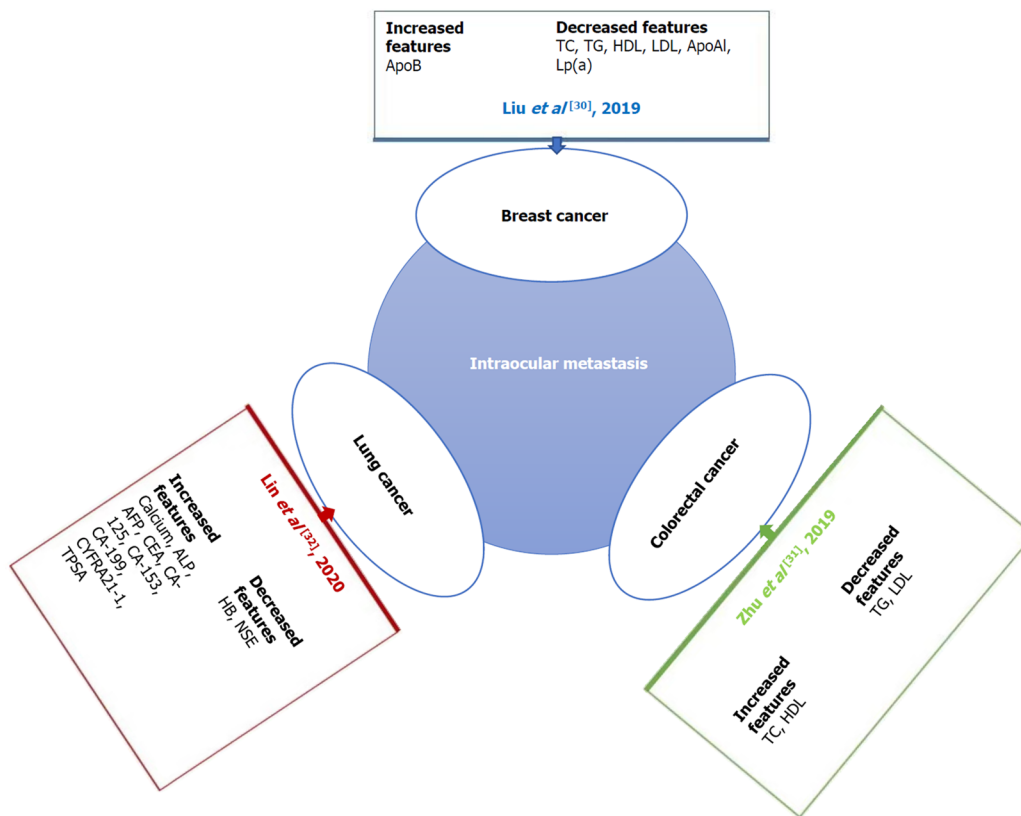
**Figure 3** The receiver operating characteristic curves of risk factors for detecting intraocular metastasis in primary liver cancer. ROC: Receiver operating characteristic; AFP: Alpha-fetoprotein; CA125: Cancer antigen 125.



**Figure 4** The receiver operating characteristic curves of the combination of alpha-fetoprotein and cancer antigen 125. ROC: Receiver operating characteristic; AFP: Alpha-fetoprotein; CA125: Cancer antigen 125.

## CONCLUSION

In conclusion, based on this retrospective study of 722 diabetic patients with primary liver cancer, serum concentrations of AFP and CA125 were independent risk factors for IOM. Moreover, the combined levels of AFP with CA125 most likely have higher accuracy than either level alone in predicting IOM among diabetic patients with primary liver cancer.



**Figure 5 Studies on intraocular metastasis from different cancers.** Serological tumor markers were changed when different tumors had intraocular metastasis (IOM). The changes in serologic tumor markers during IOM of breast, lung, and colorectal cancer are shown here. ApoB: Apolipoprotein B; TC: Total cholesterol; TG: Triglyceride; HDL: High density lipoprotein; LDL: Low density lipoprotein; ApoA1: Apolipoprotein A1; Lp(a): Lipoprotein A; ALP: Alkaline phosphatase; AFP: Alpha-fetoprotein; CEA: Carcinoembryonic antigen; CA: Cancer antigen; CYFRA: Cytokeratin fragment; TPSA: Total prostate-specific antigen.

## ARTICLE HIGHLIGHTS

### Research background

The number of patients with primary liver cancer is increasing, and the development of metastasis is closely related to the clinical prognosis of patients.

### Research motivation

Intraocular metastases (IOM) are rare in primary liver cancer, but once they occur, they often predict a poor prognosis.

### Research objectives

To investigate the correlation between a diverse range of clinical characteristics and IOM in diabetic patients with primary liver cancer, and to determine potential risk factors in predicting IOM.

### Research methods

A total of 722 diabetic patients with primary liver cancer were evaluated for IOM. The general information and biochemical indices between the IOM and non-IOM groups were then statistically analyzed.

### Research results

There was no significant difference in general information between the two groups, but the contents of alpha-fetoprotein (AFP) and cancer antigen 125 (CA125) in the IOM group were significantly higher than those in the non-IOM group.

### Research conclusions

Elevated levels of AFP and CA125 are risk factors for IOM of primary liver cancer in diabetic patients.

## Research perspectives

We used a retrospective study to evaluate the risk factors for ocular metastasis in patients with diabetic primary liver cancer.

## REFERENCES

- 1 Massarweh NN, El-Serag HB. Epidemiology of Hepatocellular Carcinoma and Intrahepatic Cholangiocarcinoma. *Cancer Control* 2017; **24**: 1073274817729245 [PMID: 28975830 DOI: 10.1177/1073274817729245]
- 2 Bosetti C, Turati F, La Vecchia C. Hepatocellular carcinoma epidemiology. *Best Pract Res Clin Gastroenterol* 2014; **28**: 753-770 [PMID: 25260306 DOI: 10.1016/j.bpg.2014.08.007]
- 3 El-Serag HB. Hepatocellular carcinoma. *N Engl J Med* 2011; **365**: 1118-1127 [PMID: 21992124 DOI: 10.1056/NEJMr1001683]
- 4 Petrick JL, Freedman ND, Demuth J, Yang B, Van Den Eeden SK, Engel LS, McGlynn KA. Obesity, diabetes, serum glucose, and risk of primary liver cancer by birth cohort, race/ethnicity, and sex: Multiphasic health checkup study. *Cancer Epidemiol* 2016; **42**: 140-146 [PMID: 27148890 DOI: 10.1016/j.canep.2016.04.009]
- 5 Su Q, Sun F, Li J, Zhang H, Wang M, Zhou H, Qiao L. The correlation analysis of primary liver cancer with Type 2 diabetes. *Indian J Cancer* 2015; **52** Suppl 3: E148-E152 [PMID: 27453412 DOI: 10.4103/0019-509X.186557]
- 6 Xu QH, Zhu PW, Li B, Shi WQ, Lin Q, Min YL, Ge QM, Yuan Q, Shao Y. Carbohydrate antigen-125, calcium, and hemoglobin as predictive clinical indicator for ocular metastasis in male liver cancer patients. *Biosci Rep* 2020; **40**: BSR20194405 [PMID: 32090248 DOI: 10.1042/BSR20194405]
- 7 Razumilava N, Gores GJ. Cholangiocarcinoma. *Lancet* 2014; **383**: 2168-2179 [PMID: 24581682 DOI: 10.1016/S0140-6736(13)61903-0]
- 8 Lee JH, Cho HS, Lee JJ, Jun SY, Ahn JH, Min JS, Yoon JY, Choi MH, Jeon SJ, Lim JH, Jung CR, Kim DS, Kim HT, Factor VM, Lee YH, Thorgeirsson SS, Kim CH, Kim NS. Plasma glutamate carboxypeptidase is a negative regulator in liver cancer metastasis. *Oncotarget* 2016; **7**: 79774-79786 [PMID: 27806330 DOI: 10.18632/oncotarget.12967]
- 9 Natsuizaka M, Omura T, Akaike T, Kuwata Y, Yamazaki K, Sato T, Karino Y, Toyota J, Suga T, Asaka M. Clinical features of hepatocellular carcinoma with extrahepatic metastases. *J Gastroenterol Hepatol* 2005; **20**: 1781-1787 [PMID: 16246200 DOI: 10.1111/j.1440-1746.2005.03919.x]
- 10 Gupta R, Honavar SG, Vemuganti GK. Orbital metastasis from hepatocellular carcinoma. *Surv Ophthalmol* 2005; **50**: 485-489 [PMID: 16139041 DOI: 10.1016/j.survophthal.2005.06.014]
- 11 Malaviya L, Shields CL, Turaka K, Ehya H, Shields JA. Choroidal metastasis from hepatocellular carcinoma, diagnosed by fine needle aspiration biopsy and treated by iodine-125 brachytherapy. *Graefes Arch Clin Exp Ophthalmol* 2011; **249**: 1095-1098 [PMID: 21305314 DOI: 10.1007/s00417-011-1626-8]
- 12 Taake WH, Allen RA, Straatsma BR. Metastasis of a hepatoma to the choroid. *Am J Ophthalmol* 1963; **56**: 208-213 [PMID: 14061596 DOI: 10.1016/0002-9394(63)91851-8]
- 13 Ronot M, Purcell Y, Vilgrain V. Hepatocellular Carcinoma: Current Imaging Modalities for Diagnosis and Prognosis. *Dig Dis Sci* 2019; **64**: 934-950 [PMID: 30825108 DOI: 10.1007/s10620-019-05547-0]
- 14 Tei M, Wakasugi M, Akamatsu H. Choroidal metastasis from early rectal cancer: Case report and literature review. *Int J Surg Case Rep* 2014; **5**: 1278-1281 [PMID: 25460493 DOI: 10.1016/j.ijscr.2014.10.059]
- 15 Shah SU, Mashayekhi A, Shields CL, Walia HS, Hubbard GB 3rd, Zhang J, Shields JA. Uveal metastasis from lung cancer: clinical features, treatment, and outcome in 194 patients. *Ophthalmology* 2014; **121**: 352-357 [PMID: 23988200 DOI: 10.1016/j.ophtha.2013.07.014]
- 16 Levison AL, Erenler F, Zhao Y, Martin DF, Lowder C, Budd GT, Singh AD. Late-onset choroidal metastasis from breast cancer. *Retin Cases Brief Rep* 2018; **12**: 342-345 [PMID: 28045860 DOI: 10.1097/ICB.0000000000000516]
- 17 Chang SY, Tsai SH, Chen LJ, Chan WC, Tsao YP. Choroidal metastasis from esophageal squamous cell carcinoma. *Taiwan J Ophthalmol* 2018; **8**: 104-107 [PMID: 30038890 DOI: 10.4103/tjo.tjo\_80\_17]
- 18 Fountas A, Tigas S, Giotaki Z, Tsatsoulis A, Kalogeropoulos CD. Choroidal metastasis from papillary thyroid cancer: An unusual feature of a common disease. *Ann Endocrinol* 2018; **78**: 64-66 [PMID: 27887671 DOI: 10.1016/j.ando.2016.09.001]
- 19 Wu SQ, Li QS, Zhang Y, Zhu LW. Spontaneous rupture of the eyeball due to choroidal metastasis of gastric carcinoma: A case report. *Medicine (Baltimore)* 2019; **98**: e17441 [PMID: 31577766 DOI: 10.1097/MD.00000000000017441]
- 20 Essadi I, Lalya I, Kriet M, El Omrani A, Belbaraka R, Khouchani M. Successful management of retinal metastasis from renal cancer with everolimus in a monophthalmic patient: a case report. *J Med Case Rep* 2017; **11**: 340 [PMID: 29212524 DOI: 10.1186/s13256-017-1501-2]
- 21 Hazan A, Katz MS, Leder H, Blace N, Szlechter M. Choroidal metastases of choriocarcinoma. *Retin Cases Brief Rep* 2014; **8**: 95-96 [PMID: 25372318 DOI: 10.1097/ICB.0000000000000012]
- 22 Lin SC, Shih SC, Kao CR, Chou SY. Transcatheter arterial embolization treatment in patients with

- hepatocellular carcinoma and risk of pulmonary metastasis. *World J Gastroenterol* 2003; **9**: 1208-1211 [PMID: 12800225 DOI: 10.3748/wjg.v9.i6.1208]
- 23 **Ogawa M**, Yamamoto T, Kubo S, Uenishi T, Tanaka H, Shuto T, Tanaka S, Hirohashi K. Clinicopathologic analysis of risk factors for distant metastasis of hepatocellular carcinoma. *Hepatol Res* 2004; **29**: 228-234 [PMID: 15288016 DOI: 10.1016/j.hepres.2004.04.002]
  - 24 **Xiang ZL**, Zeng ZC, Tang ZY, Fan J, Zhuang PY, Liang Y, Tan YS, He J. Chemokine receptor CXCR4 expression in hepatocellular carcinoma patients increases the risk of bone metastases and poor survival. *BMC Cancer* 2009; **9**: 176 [PMID: 19508713 DOI: 10.1186/1471-2407-9-176]
  - 25 **Lin ZZ**, Jeng YM, Hu FC, Pan HW, Tsao HW, Lai PL, Lee PH, Cheng AL, Hsu HC. Significance of Aurora B overexpression in hepatocellular carcinoma. Aurora B Overexpression in HCC. *BMC Cancer* 2010; **10**: 461 [PMID: 20799978 DOI: 10.1186/1471-2407-10-461]
  - 26 **Kwak MS**, Lee JH, Yoon JH, Yu SJ, Cho EJ, Jang ES, Kim YJ, Lee HS. Risk factors, clinical features, and prognosis of the hepatocellular carcinoma with peritoneal metastasis. *Dig Dis Sci* 2012; **57**: 813-819 [PMID: 22147252 DOI: 10.1007/s10620-011-1995-1]
  - 27 **Morimoto Y**, Nouse K, Wada N, Takeuchi Y, Kinugasa H, Miyahara K, Yasunaka T, Kuwaki K, Onishi H, Ikeda F, Miyake Y, Nakamura S, Shiraha H, Takaki A, Yamamoto K. Involvement of platelets in extrahepatic metastasis of hepatocellular carcinoma. *Hepatol Res* 2014; **44**: E353-E359 [PMID: 24552350 DOI: 10.1111/hepr.12315]
  - 28 **Chen Y**, Gao SG, Chen JM, Wang GP, Wang ZF, Zhou B, Jin CH, Yang YT, Feng XS. Risk factors for the Long-Term Efficacy, Recurrence, and Metastasis in Small Hepatocellular Carcinomas. *Cell Biochem Biophys* 2015; **72**: 627-631 [PMID: 25663533 DOI: 10.1007/s12013-015-0514-y]
  - 29 **Lee CH**, Chang CJ, Lin YJ, Yen CL, Shen CH, Cheng YT, Lin CC, Hsieh SY. Nomogram predicting extrahepatic metastasis of hepatocellular carcinoma based on commonly available clinical data. *JGH Open* 2019; **3**: 38-45 [PMID: 30834339 DOI: 10.1002/jgh3.12102]
  - 30 **Liu JX**, Yuan Q, Min YL, He Y, Xu QH, Li B, Shi WQ, Lin Q, Li QH, Zhu PW, Shao Y. Apolipoprotein A1 and B as risk factors for development of intraocular metastasis in patients with breast cancer. *Cancer Manag Res* 2019; **11**: 2881-2888 [PMID: 31114339 DOI: 10.2147/CMAR.S191352]
  - 31 **Zhu PW**, Gong YX, Min YL, Lin Q, Li B, Shi WQ, Yuan Q, Ye L, Shao Y. The predictive value of high-density lipoprotein for ocular metastases in colorectal cancer patients. *Cancer Manag Res* 2019; **11**: 3511-3519 [PMID: 31118776 DOI: 10.2147/CMAR.S194637]
  - 32 **Lin Q**, Chen XY, Liu WF, Zhu PW, Shi WQ, Li B, Yuan Q, Min YL, Liu JM, Shao Y. Diagnostic value of CA-153 and CYFRA 21-1 in predicting intraocular metastasis in patients with metastatic lung cancer. *Cancer Med* 2020; **9**: 1279-1286 [PMID: 31218849 DOI: 10.1002/cam4.2354]
  - 33 **Charrière B**, Maulat C, Suc B, Muscari F. Contribution of alpha-fetoprotein in liver transplantation for hepatocellular carcinoma. *World J Hepatol* 2016; **8**: 881-890 [PMID: 27478538 DOI: 10.4254/wjh.v8.i21.881]
  - 34 **Sauzay C**, Petit A, Bourgeois AM, Barbare JC, Chauffert B, Galmiche A, Houesson A. Alpha-fetoprotein (AFP): A multi-purpose marker in hepatocellular carcinoma. *Clin Chim Acta* 2016; **463**: 39-44 [PMID: 27732875 DOI: 10.1016/j.cca.2016.10.006]
  - 35 **Liu Y**, Wang X, Jiang K, Zhang W, Dong J. The diagnostic value of tumor biomarkers for detecting hepatocellular carcinoma accompanied by portal vein tumor thrombosis. *Cell Biochem Biophys* 2014; **69**: 455-459 [PMID: 24500835 DOI: 10.1007/s12013-014-9817-7]
  - 36 **Bottoni P**, Scatena R. The Role of CA 125 as Tumor Marker: Biochemical and Clinical Aspects. *Adv Exp Med Biol* 2015; **867**: 229-244 [PMID: 26530369 DOI: 10.1007/978-94-017-7215-0\_14]
  - 37 **Yang WL**, Lu Z, Bast RC Jr. The role of biomarkers in the management of epithelial ovarian cancer. *Expert Rev Mol Diagn* 2017; **17**: 577-591 [PMID: 28468520 DOI: 10.1080/14737159.2017.1326820]
  - 38 **Yuan Q**, Song J, Yang W, Wang H, Huo Q, Yang J, Yu X, Liu Y, Xu C, Bao H. The effect of CA125 on metastasis of ovarian cancer: old marker new function. *Oncotarget* 2017; **8**: 50015-50022 [PMID: 28637006 DOI: 10.18632/oncotarget.18388]
  - 39 **Li Y**, Li DJ, Chen J, Liu W, Li JW, Jiang P, Zhao X, Guo F, Li XW, Wang SG. Application of Joint Detection of AFP, CA19-9, CA125 and CEA in Identification and Diagnosis of Cholangiocarcinoma. *Asian Pac J Cancer Prev* 2015; **16**: 3451-3455 [PMID: 25921161 DOI: 10.7314/apjcp.2015.16.8.3451]
  - 40 **Gillies RJ**, Pilot C, Marunaka Y, Fais S. Targeting acidity in cancer and diabetes. *Biochim Biophys Acta Rev Cancer* 2019; **1871**: 273-280 [PMID: 30708040 DOI: 10.1016/j.bbcan.2019.01.003]
  - 41 **Li X**, Wang X, Gao P. Diabetes Mellitus and Risk of Hepatocellular Carcinoma. *Biomed Res Int* 2017; **2017**: 5202684 [PMID: 29379799 DOI: 10.1155/2017/5202684]
  - 42 **Jenkins AJ**, Joglekar MV, Hardikar AA, Keech AC, O'Neal DN, Januszewski AS. Biomarkers in Diabetic Retinopathy. *Rev Diabet Stud* 2015; **12**: 159-195 [PMID: 26676667 DOI: 10.1900/RDS.2015.12.159]
  - 43 **Li X**, Jiao Y, Xing Y, Gao P. Diabetes Mellitus and Risk of Hepatic Fibrosis/Cirrhosis. *Biomed Res Int* 2019; **2019**: 5308308 [PMID: 31080822 DOI: 10.1155/2019/5308308]



Published by **Baishideng Publishing Group Inc**  
7041 Koll Center Parkway, Suite 160, Pleasanton, CA 94566, USA

**Telephone:** +1-925-3991568

**E-mail:** [bpgoffice@wjgnet.com](mailto:bpgoffice@wjgnet.com)

**Help Desk:** <https://www.f6publishing.com/helpdesk>

<https://www.wjgnet.com>

