



Reconstructive treatment of symptomatic vertebral artery dissecting aneurysms with Willis covered stent: Initial experience

Yi Gu^{a,1}, Li Chen^{a,1}, Yang Zhang^a, Mo Chen^a, YongDong Li^a, YueQi Zhu^a, HaiTao Lu^a, LiMing Wei^a, PeiLei Zhang^a, MinHua Li^a, BinXian Gu^a, Jin You^{b,**}, Wu Wang^{a,*}

^a Institute of Diagnostic and Interventional Radiology, Shanghai Jiao Tong University Affiliated Sixth People's Hospital, Shanghai, 200233, China

^b Zhejiang Shin-an International Hospital, 314031, China

ARTICLE INFO

Keywords:

Vertebral artery dissecting aneurysm
Endovascular treatment
Willis covered stent
Stent
Coil

ABSTRACT

Background: Symptomatic vertebral artery dissecting aneurysm (VADA) is a challenging disease with controversy on treatment strategy due to anatomic configuration and their nature. Moreover, the outcomes of reconstructive treatment have not been well established.

Objective: To evaluate the safety and efficacy of reconstructive endovascular treatment (EVT) for symptomatic VADAs with Willis covered stent.

Methods: We evaluated retrospectively 13 patients with symptomatic VADAs who treated with Willis covered stent, compared with stent-assisted coiling (SAC) on the characteristics, posttreatment course, angiographic and clinical follow-up outcomes at an average of 14.4 months (range, 3–48 months).

Results: A total of 33 patients with symptomatic VADAs were reviewed, 23 of these patients with ruptured VADAs. The technical successful rate is 100% respectively in Willis covered stent (Group A) and SAC (Group B, n = 20). The initial complete occlusion rate was significant higher in group A (100%) than group B (30%) ($p < 0.01$). Major procedure-related complications were not significant different in the two groups. Serial follow-up angiograms revealed 5 recurrent VADAs in group B and no recurrence in group A ($p > 0.05$). No obvious in-stent stenosis and no re-hemorrhage and delayed ischemic symptoms during the follow-up period. The final angiograms of all survived patients demonstrated the complete occlusion rate was higher in group A (100%) than group B (80%), but no significant statistical difference ($p > 0.05$). Clinical outcomes were favorable in 31 (93.9%), severe disability occurred in one in group B, and only one death in group A. The final clinical outcomes were also not significant difference in the two groups ($p > 0.05$).

Conclusions: Our initial result demonstrated reconstructive EVT with Willis covered stent provides a viable approach for selected symptomatic VADAs involving the intracranial and extracranial segments, which is similar to favorable results with SAC. However, an expanded clinical experiences and larger cohort studies are needed.

Introduction

Vertebral artery dissecting aneurysm (VADA) has been recognized as a leading cause of subarachnoid hemorrhage (SAH) and ischemic stroke of the posterior circulation, but there are no clear guidelines to demonstrate the real natural history in the literature.^{1,2} To date, various endovascular treatment (EVT) options have emerged as the treatment of choice due to perceived lower rates of treatment related morbidity as

well as their efficacy, including reconstructive techniques and deconstructive techniques.^{3–7} Compared with deconstructive techniques, reconstructive techniques were shown to be better in maintaining the vertebral artery or major branches (posterior inferior cerebellar artery, PICA; anterior spinal artery, ASA; posterior spinal artery, PSA). However, the rates of long-term occlusion, recurrence, and perioperative mortality are not different between deconstructive and reconstructive techniques in EVT of VADAs based on the recent meta-analysis.⁷ In addition,

* Corresponding author. Interventional Radiology, Zhejiang Shin-an International Hospital, 314031, China.

** Corresponding author. Institute of Diagnostic and Interventional Radiology, Shanghai Jiao Tong University Affiliated Sixth People's Hospital, 600 yishan road, xuhui district, Shanghai, 200233, China.

E-mail addresses: 286014943@qq.com (J. You), wangwangwuwu@hotmail.com (W. Wang).

¹ Contributed equally to the manuscript.

<https://doi.org/10.1016/j.jimed.2020.08.003>

Received 24 April 2020; Received in revised form 10 July 2020; Accepted 3 August 2020

Available online 16 August 2020

2096-3602/Copyright © 2020 Shanghai Journal of Interventional Medicine Press. Production and hosting by Elsevier B.V. on behalf of KeAi. This is an open access

article under the CC BY-NC-ND license (<http://creativecommons.org/licenses/by-nc-nd/4.0/>).

aneurysm recanalization remains a major shortcoming of reconstructive treatment, as well as deconstructive techniques leading to ischemic infarction and aneurysm formation of contralateral VA. With the rapid development of material and techniques, many clinical practices have proved the safe and effective of multiple stents reconstructive treatment with or without coil for VADAs.^{8,9} Endovascular covered stent and flow diverter device (FDD), with the ability to reconstruct the parent artery, has been suggested as an important addition to the EVT for VADAs.^{10,11} Willis covered stent (MicroPort, Shanghai, China) has become available for intracranial ICA pseudoaneurysms, aneurysms, recurrent aneurysms, and traumatic carotid cavernous fistulas.^{12,13} In the retrospective study, we present initial experience in 13 patients with 13 VADAs who have undergone EVT with Willis covered stent, compared with stent-assisted coiling (SAC) for 20 VADAs.

Materials and methods

Patients and study design

Between January 2010 and December 2017, 13 symptomatic VADAs in 13 patients were treated with Willis covered stent, and compared with SAC for symptomatic VADAs in the same period. We adopted EVT as the first-line treatment for intracranial aneurysms in our hospital since 1998.¹⁵ The study was designed and approved by our institutional review boards, and all patients gave their written informed consent to participate in the study.

All subjects met the following inclusion criteria: (1) acute clinical symptoms and signs relevant to VBDA such as SAH which was in grade I–grade III according to Hunt-Hess grading system, and recurrent ischemic stroke which antiplatelet or anticoagulant therapy is invalid; (2) definite VADA revealed by digital subtraction angiography (DSA), and described as irregular wall or string and pearl with pseudoaneurysm or fusiform aneurysm, and not involving the basilar artery; (3) the patient was willing to be followed up in accordance with the study protocol. Patient exclusion criteria were as follows: (1) clinical presentation was not related to VADA, or antiplatelet therapy is valid to VADA; (2) associated with traumatic VBDA, or iatrogenic VBDA, or other systemic diseases; (3) an extremely tortuous vessel proximal to the parent artery and/or lack of appropriate accessible routes, thereby rendering the patient unsuitable for EVT; (4) inability of the patient to undergo general anesthesia or EVT. Whether endovascular EVT with Willis covered stent or SAC is determined by two experienced interventional neuroradiologists, based on patient status, location of the VADA, composition of the related vessels, and collateral circulation, as well as choose of patients or family members. In the event of unsuccessful placement of a Willis covered stent, alternative treatment options included SAC and internal coil trapping.

Willis covered stent placement

Willis covered stent placement and peri-procedure management have been described in detail previously.^{12,13} Briefly, the stent consists of three parts: a bare stent, expandable polytetrafluoroethylene (ePTFE) membrane, and balloon catheter. The stent has been approved by China's Food and Drug Administration since 2013, which has been subject to improvement of the stent and the accumulation of more clinical data.

SAC treatment

Generally, endovascular SAC reconstruction used stent jailing technique and semi-jailing technique and a stent-within-a stent technique. A Neuroform3 stent was usually implanted as the first stent following by a Solitaire stent or Enterprise stent, and endovascular coiling had been placed inside the aneurysm sac before the stent deployment. Details of SAC treatment procedure were described previously.^{8,9,14} In the study, two types of microcatheters were used: Echelon 10 (EV3, Irvine, CA, USA) and Excelsior SL-10 (Stryker Neurovascular, Fremont, CA, USA).

Three types of coils were used: GDC (Stryker Neurovascular, Fremont, CA, USA), Helicoil, Microplex and Hydrocoil (Microvention Inc., Aliso Viejo, CA, USA), Nexus and Axium (EV3, Irvine, CA, USA) coils. Three types of stents were used: Neuroform3 (Stryker Neurovascular, Fremont, CA, USA), Solitaire AB (EV3, Irvine, CA, USA) stent, and Enterprise stent (Codman, Raynham, MA, USA).

Follow-up protocol

Follow-up protocols included clinical and angiographic follow-ups and head computed tomography angiography (CTA) and magnetic resonance (MR). DSA follow-up was recommended every year thereafter, and CTA follow-up would also be acceptable as far as the result of previous DSA follow-up was satisfactory. Follow-up studies were then conducted at 1 month, 3 months, 6–12 months, and 12 months post-procedure and annually thereafter. The initial and follow-up angiographic results were interpreted independently by 2 authors. In the case of disagreement, consensus was reached through discussion with the senior doctor. Clinical follow-ups included observing changes in the preliminary clinical presentation, and adverse events related to the device, procedure, or other diseases.

Postoperative outcome evaluation

Data on the technical success and the initial and final angiographic results, mortality, morbidity, and final clinical outcome were collected and estimated at the time of patient death, or at the end of follow-up. Initial aneurysm occlusion degree for B group was generally classified by Raymond scale¹⁵ as complete occlusion (class 1), and residual neck (class 2) and residual aneurysm (class 3). Corresponding to the aneurysm occlusion degree for A group was classified as complete occlusion of VADA without any endoleak (class 1), and incomplete occlusion of VADA with an endoleak (class 2) and residual aneurysm because covered stent did not completely cover VADA (class 3). Follow-up angiographic results of EVT were classified as stable occlusion, progressive occlusion, recurrence including coil compression and regrowth, and stenosis or occlusion of VA.^{12,14} However, when incomplete occlusion or recurrence was confirmed, the second EVT was recommended within 1–3 months. For clinical outcomes, the occurrence of postoperative ischemic events (stroke or TIA), rehemorrhage, vasospasm, and death were recorded. Outcome data were classified into good (0–2) and disabled (3–5), according to the Modified Rankin scale (mRS).¹⁶ The patients were clinically assessed before and after EVT and followed up every 3–6 months after discharge from the hospital. Each patient's clinical status at the last clinical follow-up was defined as the final outcomes. Patients who were not followed at our institution were interviewed by telephone.

Statistical analysis

Statistical analysis was performed using SPSS 26.0 (IBM, Chicago, IL, USA). Continuous variables are presented as mean with standard error of the mean. Comparisons between groups were performed using the *t*-test for continuous parameters and the chi-square test or Fisher's exact test for categorical parameters. A *p* value < 0.05 was considered significant different.

Results

A total of 39 patients with symptomatic VADAs were enrolled for participation in the period. Willis covered stent was implanted in 13 DAVAs (Group A), and SAC in 20 DAVAs (Group B) were included in the study. Other 6 DAVAs were excluded because 3 DAVAs treated with SAC lost contact, and others were treated by internal coiling trapping related to conditions of these patients suddenly became worse such as rehemorrhage before EVT. There are 23 patients with ruptured VADAs. All ruptured VADAs were treated within the first day of onset but 2 VADAs in

group A, who were treated with covered stent as the secondary treatment for residual filling of VADAs transferred from other hospitals within 4 weeks after SAH. All patients did not implement BOT test of the diseased VA before EVT in the study. In group A, concomitant lesions were found in two patients, and one with untreated aneurysm of the ipsilateral V3 segment, and another with multiple ruptured aneurysms of contralateral MCA treated with SAC. In group B, concomitant lesions were found in 4 patients, and two patients have a contralateral DAVA treated with only double stents placement, and one has a dissecting aneurysm of ipsilateral ICA with SAC, and another with a ruptured saccular aneurysm in the C7 segment of ipsilateral ICA only with coiling.

Baseline patient characteristics

For group A, patient demographics and VADAs characteristics are provided in Tables 1 and 2. These patients included 10 men and 3 women with an average of 51.15 ± 11.80 years (range: 33–70 years). 3 VADAs with recurrent ischemic stroke (Fig. 1) and 9 ruptured VADAs (Fig. 2), and one unruptured VADA associated with a ruptured aneurysm. The location as follows: 10 in the V4 segment (distal to PICA in 2 VADA, and proximal to PICA in 6 VADAs and no PICA in 2 VADAs), and 1 in the V3 segment, and 2 in the V2 segment. For group B, patient demographics and VADAs characteristics are provided in Table 2. The patients included 9 men and 11 women with an average of 57.45 ± 12.46 years (range: 36–80 years). 6 VADAs with recurrent ischemic stroke and 14 ruptured VADAs. The location as follows: 18 in the V4 segment (distal to PICA in 8 case, and proximal to PICA in 6 cases, and involve PICA in 4 cases), and 1 in the V3 segment, and 1 in the V2 segment. No significant difference was observed between these characteristics of these VADAs of the two groups (p > 0.05).

Primary procedural results

The technical successful rate is 100% in group A, as well as in group B. The comparison between the two groups was shown in Table 2. The initial angiographic results demonstrated the complete occlusion rate is 100% in group A, which is much higher than that of group B (30%). In

Table 2
Compared with Willis covered stent and SAC.

Characteristics	Willis covered stent (A group, n = 13)	SAC (B group, n = 20)	P value
Age	51.15 ± 11.80(33–70)	57.45 ± 12.46(36–80)	0.157
Sex,male	10 (76.9%)	9 (45%)	0.070
Onset			0.963
SAH	9	14	
Ischemic stroke	4	6	
Location			0.552
V4	10	18	
V3	1	1	
V2	2	1	
No. of stent			0.074
1	12	13	
2	1	7	
Immediate Raymond occlusion			<0.01
Class 1	13	6	
Class 2	0	11	
Class 3	0	3	
Angiographic follow-up time (Mons)	15.23 ± 14.01 (6–48)	12.45 ± 10.76 (3–48)	0.524
Recurrence	0	5	0.052
Complication			0.368
Spasm	6	2	
Thrombosis event	2	2	
Final mRS results			0.751
Not disabled (0–2)	12	19	
Disabled (3–6)	1	1	
Final Raymond occlusion			0.148
Class 1	12	16	
Class 2	0	3	

group B, residual neck and residual aneurysm were respectively achieved in 10 and 4 VADAs at the end of the initial EVT. In group A, all 13 VADAs were treated with single Willis covered stent but for one VADA, which there is a long diseased segment of VA that requires 2 covered stents to be

Table 1
Demographics, procedural characteristics, and follow-up outcomes of VADAs with endovascular Willis covered stent.

Patient No/ Sex/Age,y	Onset	Location	Relationship with PICA	VA condition	Stent Size, mm	Immediate angiographic result	Follow-up time, mons	Complication	Final angiographic result
1/M/38	SAH	L-V4	Distal	Dominant	3.5x10	Complete occlusion	–	Thrombosis event and rehemorrhage	No
2/F/55	Ischemic stroke	R-V3	Proximal	Non-dominant	3.5x10	Complete occlusion	24	Spasm	Complete occlusion
3/M/40	SAH	R-V4	No PICA	Dominant	4.0x13	Complete occlusion	38	Spasm	Complete occlusion
4/M/53	SAH	R-V4	Proximal	Codominant	3.5x16	Complete occlusion	18	No	Complete occlusion
5/M/33	Ischemic stroke	L-V4	Proximal	Codominant	3.5x16,3.5x10	Complete occlusion	6	Thrombosis event, Spasm	Complete occlusion
6/M/39	MCA aneurysm rupture	L-V2	Proximal	Codominant	3.5x16	Complete occlusion	16	No	Complete occlusion
7/F/41	Ischemic stroke	L-V2	Proximal	Codominant	3.5x10	Complete occlusion	48	No	Complete occlusion
8/M/65	SAH	L-V4	Proximal	Dominant	3.5x16	Complete occlusion	6	Spasm	Complete occlusion
9/M/51	SAH	L-V4	Proximal	Dominant	3.5x16	Complete occlusion	6	Spasm	Complete occlusion
10/F/72	SAH	L-V4	No PICA	Dominant	4.0x16	Complete occlusion	6	Spasm	Complete occlusion
11/M/62	SAH	L-V4	Distal	Dominant	3.5x10	Complete occlusion	12	No	Complete occlusion
12/M/58	SAH	L-V4	Proximal	Codominant	3.5x13	Complete occlusion	6	No	Complete occlusion
13/M/59	SAH	L-V4	Proximal	Dominant	3.5x13	Complete occlusion	12	No	Complete occlusion

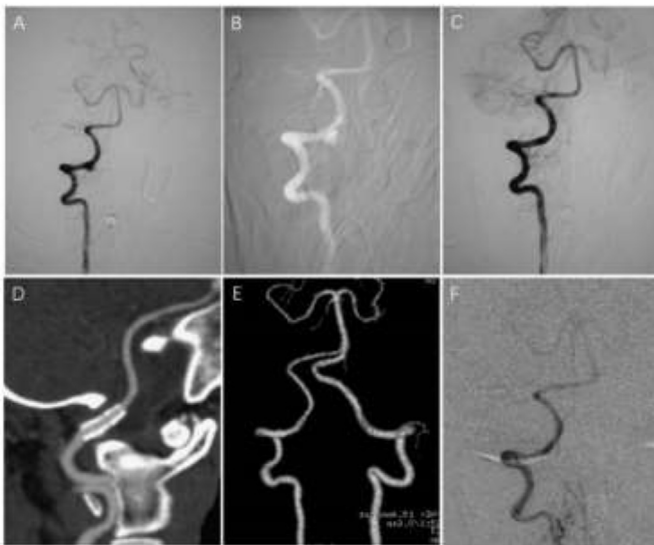


Fig. 1. A 55-year-old female suffered with repeated dizziness in recent 5 years. A, a nodominant right VA angiogram revealed a hemispherical dissecting aneurysm in the V3 segment; B, under the roadmap, Willis covered stent ($3.5 \times 10\text{mm}$) was implanted; C, immediate angiograms post EVT demonstrated the complete occlusion of the VADA; D and E, CTA of the one month follow-up demonstrated the stable occlusion of the VADA and patency of VA without any stenosis; F, the 24 months follow-up angiograms demonstrated the complete occlusion of the VADA without in-stent stenosis.

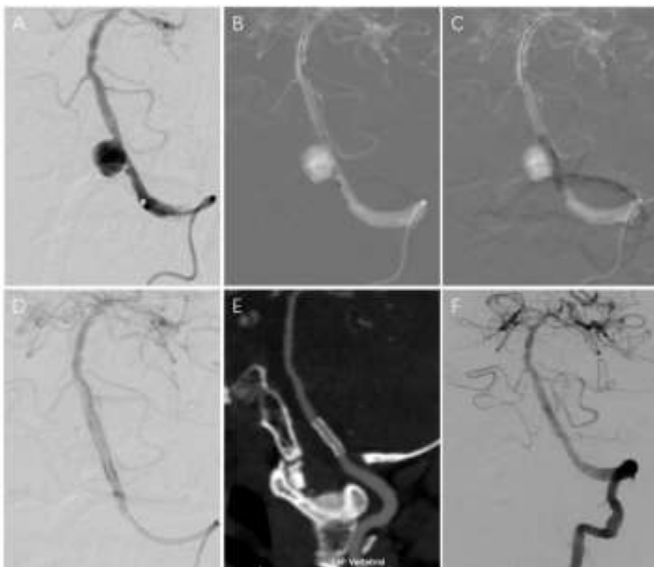


Fig. 2. A 65-year-old male suffered from SAH. A, a dominant left VA angiogram revealed a spherical dissecting aneurysm on the V4 segment proximal to PICA and the stenosis on the proximal to the aneurysm; B and C, under the roadmap, Willis covered stent ($3.5 \times 16\text{mm}$) was implanted; D, immediate angiograms post EVT demonstrated the complete occlusion of the VADA; E, CTA of the 1 month follow-up demonstrated the stable occlusion of the VADA and patency of VA without any stenosis; F, the 6 months follow-up angiograms demonstrated the complete occlusion of the VADA and reconstruction of the diseased VA with no in-stent stenosis.

treated using the telescopic technique. In group B, 13 VADAs were treated by SAC with single stent and 7 by SAC with double stents (Fig. 3). In addition, there are no significant difference for the initial occlusion results between the single stent group and double stents group ($p > 0.05$).

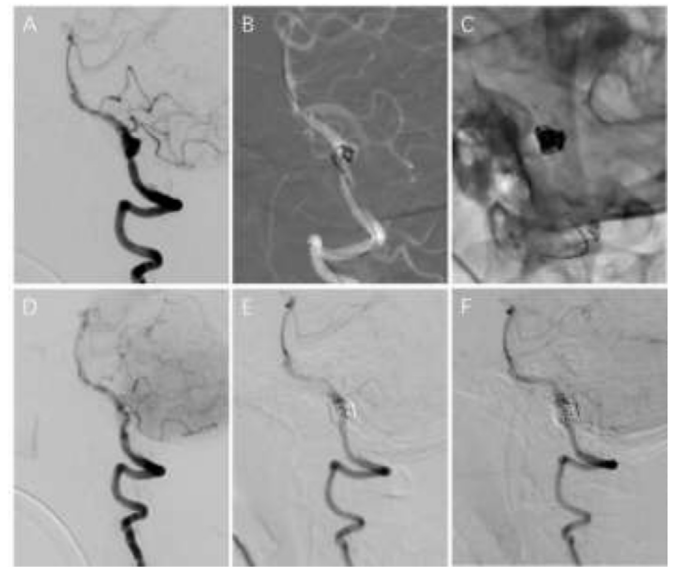


Fig. 3. A 59-year-old male suffered from SAH. A, a dominant left VA angiogram revealed an irregular dissecting aneurysm and the limited stenosis on the proximal of left PICA; B, under the roadmap, the VADA was treated with a Neuroform3 SAC using semi-jailing technique; C, a stent-within-a stent technique (SolitaireAB stent as the second stent) was used after SAC; D, immediate angiograms post EVT demonstrated the near complete occlusion of the VADA; E and F, the 6 months and 36 months follow-up angiograms demonstrated the complete occlusion of the VADA with re-cast of the coil, and the reconstruction of the diseased VA with no in-stent stenosis.

Procedural complications

Major complications occurred in 4 ruptured VADAs. In group A, one patient experienced acute in-stent mural thrombosis immediately after placement of a Willis covered stent within a Neuroform3 stent for VADA on the left V4 segment, which was placed two weeks ago. The thrombosis was speculated to be related to incomplete endothelialization of the first stent. Although this patient was managed with thrombolytic and anti-platelet therapies, he suffered with repeated cerebral infarction and fetal re-bleeding in the 12th day. In addition, another untreated aneurysm located on the ipsilateral V3 segment. Another patient experienced a transient neurological deficit due to severe spasm of VA related to second covered stent placement, without permanent neurological deficits after EVT. No new ischemic foci were found in the subsequent MR examination of this patient. There are also other 5 patients experienced spasm of VA without any permanent neurological deficits. In group B, one patient experienced a transient neurological deficit due to spasm of VA related to second stent placement, without permanent neurological deficits after EVT. Another patient suffered with permanent neurological deficit due to severe spasm of VA resulting from SAH, found in the subsequent MR examination. In the remaining 29 patients (11 in group A and 18 in group B), no morbidity or mortality occurred during or after EVT. Furthermore, cranial CT immediately post-EVT and at discharge confirmed that the procedures were uneventful, with no evidence of re-bleeding or ischemia.

Follow-up angiographic results and clinical outcomes

Serial follow-up angiograms with the average of 14.4 months (range, 3–48 months) demonstrated no recurrence in group A and 5 recurrent VADAs in group B, and no significant difference ($p > 0.05$). Moreover, all recurrent VADAs were initially treated by SAC with single stent for ruptured VADAs, 2 of these VADAs suffered with spasm of VA during

initial EVT and 3 VADAs involved PICA. Coil compression resulted in 2 of 5 VADAs and aneurysmal sac regrowth in other 3 VADAs, which came from initial incomplete occlusion of VADAs including residual neck in 2 VADAs and residual aneurysm in 3 VADAs. All recurrence occurred within 6 months after EVT, and 4 of these occurred within 3 months. These recurrent VADAs were retreated within the next 3 months. 2 of these recurrent VADAs were retreated with SAC and other 3 recurrent VADAs were retreated only with coiling (Fig. 4). Fortunately, complete occlusion was achieved in all retreated VADAs without any complications. The final angiograms demonstrated complete occlusion in all survived 12 patients (100%) in group A and in 16 of 20 (80%) in group B, and no significant difference in the two groups ($p > 0.05$).

According to the mRS, good outcomes achieved a total of 31 (93.9%) in the two groups. The final clinical outcomes were not significant difference in the two groups ($p > 0.05$). No obvious in-stent stenosis and no re-bleeding and delayed ischemic symptoms during the whole follow-up period.

Discussion

Although VADA is a rare disease and the annual occurrence rate has been stated to be 1–1.5/100,000 cases in the USA, and the biological behavior of most VADAs might be favorable, ruptured VADA patients usually show a high occurrence rate of rehemorrhage and disastrous neurological results within several weeks, and the special pathological and morphological features of VADAs make them challenging to treat with traditional options.^{2,3,17} To date, the natural history of VADAs is uncertain, with variable evolution and lacks a standard management protocol. This nonrandomized retrospective study was designed to compare the angiographic results and clinical outcomes of Willis covered stent with SAC in selected patients with symptomatic VADAs to verify that reconstructive endovascular with Willis covered stent is safe and efficacy. To our knowledge, this is the largest series reporting the mid- and long-term follow-up angiographic results of reconstructive endovascular covered stent placement for symptomatic VADAs, compared with SAC. Our results showed excellent initial and final complete occlusion rates with no recurrence. We found no significant differences in the clinical outcomes, overall mortality, morbidity between the two groups, although there has been one death in group A. Willis covered stent provides a viable approach for selected symptomatic VADAs maintaining patency of the VA.

Reconstructive SAC issues

Deconstructive internal coil trapping and reconstructive SAC or stent placement have emerged as EVT of choice recommended for selected VADAs treatment due to perceived lower rates of treatment-related morbidity as well as their efficacy.^{3–9,17} Although deconstructive internal coil trapping was thought to be the most reliable EVT for ruptured VADAs as the preferred treatment in which patients have sufficient collateral circulation, it does also have some drawbacks such as resulting into lateral medullary or cerebellar infarction, and the formation of new aneurysm of contralateral VA, even rupture, and failed to prevent recurrence and rehemorrhage of VADA. It is also applied to be the most effective option combined with reconstructive stent placement for some complex VADAs, which those patients lack sufficient collateral circulation and with PICA-origin VBDA and/or a dominant feeding pedicle to the ASA in the dissected segment and non-hemorrhagic type acute VADAs and some bilateral VADAs.^{4,7,9,18} In the late 1990s, Lylyk et al.¹⁹ and Sekhon et al.²⁰ first reported the effectiveness of SAC for VADAs. Since then, reconstructive SAC for VADAs has been increasingly reported with very encouraging results. Moreover, reconstructive SAC can preserve the parent vessel, which negates the need for revascularization when angiography reveals inadequate collateral flow or when the dissected segment involves these major branch vessels. Subsequently, Kim et al.⁴ and Chung et al.¹⁸ respectively reported the efficacy of reconstructive SAC for these special PICA-origin VBDA. In a meta-analysis comparing deconstructive with reconstructive EVT for VADAs, endovascular reconstructive result was as effective as deconstructive result with a lower periprocedural morbidity.⁶ Another study comparing SAC with trapping showed similar long-term outcomes and morbidity.⁵ Moreover, many reports have proved the complete occlusion rates in long-term follow-up angiograms were superior in multiple stent or SAC or stent placement alone for VADAs.^{3,5,8,9} Overlapping multiple stents are similar to the flow diverter, may divert more blood flow from the VADA sac by decreasing stent porosity, further straightening the parent vessel and improving endothelial healing, and leading to more favorable results.^{3,9,11,21}

In the study, 20 VADAs were treated with SAC with single and double stents as the control group. The results demonstrated that the initial completed occlusion rate achieved in only 30% of VADAs, and major complication leading to permanent neurological deficits in 5%, and recurrent rate in 25% (all recurrent VADAs treated with single stent-

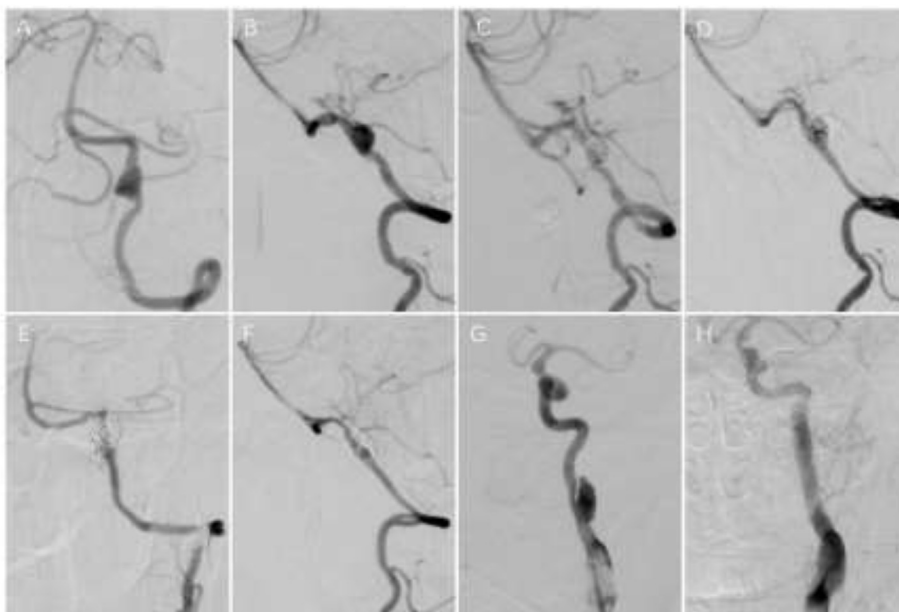


Fig. 4. A 48-year-old male suffered from SAH. A and B, dominant left VA angiograms revealed an irregular dissecting aneurysm involving the origin of left PICA, and the stenosis proximal to the aneurysm; C, immediate angiograms after SAC with single stent demonstrated complete occlusion of the VADA and spasm of VA; D, the 6 months follow-up angiograms demonstrated recurrence of the VADA; E and F, the 24 months follow-up angiograms post the second EVT with only coil embolization demonstrated the complete occlusion of the VADA and patency of left PICA. G and H, left ICA angiograms demonstrated concurrent dissecting aneurysm and complete occlusion after SAC with double stents at the 24 months follow-up.

assisted coiling), and stable occlusion rate in 45%, and progressive occlusion rate in 30%, and the final completed occlusion rate in 80%, and a favorable clinical outcome in 95%. According to several studies,^{1,6,8} the initial completed occlusion rate achieved in 30–53%, and major complication leading to permanent neurological deficits in 4–5%, and recurrent rate in 8.8–16.9%, and the final completed occlusion rate in 78–90%, and a favorable clinical outcome in 82.5–92%. Our data could be comparable with these relevant literatures but for the high recurrent rate, which may be associated with more ruptured VADAs in the study.

Despite the lack of randomized clinical experiments, the initial incomplete occlusion and the involvement of PICA and ruptured condition as the main reasons of recurrence after SAC were reported, as well as most recurrent VADAs treated initially by SAC with single stent.^{1,3,8,22} In the study, all 5 recurrent VADAs were from ruptured VADAs as the initial treatment by SAC with single stent and failed to achieve the complete occlusion, 3 of these VADAs involved PICA, and no recurrence by SAC with double stents. Fortunately, all recurrent VADAs were not experience rehemorrhage and other complications, and subsequent successful retreatment with coil embolization or SAC, resulting into the complete occlusion.

Table 3

Description of published studies documenting experience with endovascular covered stent of VADAs.

Reference	No. Patients	Onset	Location	VA condition	Endovascular Stent	Initial angiographic result	Complication	Follow-up time, mons	Final angiographic result
Chiaradio et al. Neurosurgery, 2002 ²³	1	SAH	R, V4, Distal of PICA	Codominant	Jostent	Complete occlusion	No	No	No
Islak et al. AJNR, 2002 ²⁴	1	SAH	L, V4*, Distal of PICA	Dominant	Coronary stent+Jostent	Near complete occlusion	No	4	Complete occlusion
Burbelko et al. AJNR, 2004 ²⁵	1	SAH	L, V4*, Distal of PICA	Dominant	Jostent	Complete occlusion	No	6	Complete occlusion
Felber et al. Neurosurgery, 2004 ²⁶	2	SAH/No	L, V4, Distal of PICA/R, V2	Dominant	Jostent	Complete occlusion	No/a recurrent aneurysm	48/60	Complete occlusion
Lv et al. Interv Neuroradiol, 2008 ²⁷	2	SAH	V4	–	Jostent	Complete occlusion	Technical failure in 1 case	6	Complete occlusion
He et al. J Neurosurg, 2009 ¹¹	6	SAH(5)/Chronic Headache	L(4)/R(2), V4, Distal of PICA(2), Proximal of PICA(4)	–	Jostent	Complete occlusion	Technical failure in 1 case	6-14 (mean,10.4)	Complete occlusion
Vulev et al. Interv Neuroradiol, 2012 ²⁸	1	Other aneurysm rupture	L, V4, Promixal of PICA	Codominant	Pericardium Covered Stent	Complete occlusion	No	3	Complete occlusion
Yoon et al. J Korean Neurosurg, 2012 ²⁹	1	SAH	L, V4, Promixal of PICA	Dominant	Jostent	Complete occlusion	No	2	Complete occlusion
Ronchey et al. J Cardiovasc Surg, 2014 ³⁰	1	Symptomatic	L, V2	Dominant	Viabahn stent-graft&	Complete occlusion	No	13	Complete occlusion
Inaraja Pérez et al. Ann Vasc Surg, 2015 ³¹	1	Symptomatic	R, V1	–	Covered stent#	Complete occlusion	No	No	Complete occlusion
Xiang et al. Interv Neuroradiol, 2019 ³²	12	SAH(2)/Symptomatic(8)/Other(2)	L(8)R(4),V4	–	Willis covered stent	Complete occlusion in 11 cases	No	4-15 (9.9 ± 4.0)	Complete occlusion in 9 cases
Current	13	SAH(9)/Symptomatic(4)	L(7)/R(3), V4(7), V3(1), V2(2), Distal of PICA(2), Proximal of PICA(8), No(3)	Dominant(7), Codominant(5), Non-dominant(1)	Willis covered stent	Complete occlusion	Permanent complication In 1 case	6-48 (mean,18.4)	Complete occlusion in 12 cases

V4*: Vertebrobasilar junction; Viabahn stent-graft&: 6 × 25mm, Gore and Associates; Covered stent#: a Biotronik PK Papyrus balloon expandable covered cobalt chromium stent (designed for coronary Perforations).

Covered stent issues

We reviewed the English literature describing covered stent treatment for VADAs. Including our series, we analyzed VADAs in 42 patients from 12 study series (Table 3).^{10,23–32} Currently, there are several covered stents specially designed for the coronary arteries that have been adapted for VADAs, such as the Jostent, which are off-label. Although they lack mechanical flexibility and their delivery profiles are stiff, 88.2% of VADAs have been treated successfully by non-Willis covered stents, with the initial complete occlusion rate of VADAs achieved in 100%, and no recurrence. All successful treated VADAs located respectively in the V4 segment (n = 12, 5 in the distal and 6 in the proximal to PICA, and the relationship with PICA is not clear in 1 DAVA), and the V2 segment (n = 2), and the V1 segment (n = 1). These previous reports suggest that the covered stent is a promising therapeutic alternative for EVT of VADAs by reconstruction of the intracranial and extracranial VA arterial wall. Recently, Xiang et al.³² reported 16 Willis covered stents were successfully implanted into the VA for 12 DAVAs. The technical success rate of stenting placement was 100%. Angiographic follow-up (9.9 ± 4.0 months) was performed in nine patients and demonstrated complete

stabilization of the obliterated aneurysm, and clinical follow-up (20.1 ± 9.6 months) demonstrated full recovery in 11 patients.

Willis covered stents (MicroPort, Shanghai, China) have become available for intracranial ICA pseudoaneurysms, aneurysms, recurrent aneurysms and traumatic carotid cavernous fistulas.^{12,13} The present study is the largest series report both initial and mid-/long-term angiographic follow-up results after reconstructive endovascular Willis covered stent placement used for EVT of symptomatic VADAs. Our study demonstrated that the technical success rate was excellent, as were the immediate and mid-/long-term results. The rate of complete occlusion with preservation of the VA was higher than that previously reported in the literature although there is one case death. This may be due to good longitudinal flexibility of Willis covered stent, and the physiological curvature of the VA seem to be more suitable for Willis stent placement, compared with that of the ICA. Compared with our previous reports about Willis covered stent placement for ICA aneurysms,^{12,33} it seems to be more suitable for VA aneurysms, based on the technical successful rate, and initial complete occlusion rate, and no endoleak, and no delayed recurrence and in-stent stenosis. In our previous report,³³ one recurrent VADA after SAC was treated with Willis covered stent, and subsequent two VADAs were treated with Willis covered stent before the prospective study began, viewed as our practical base. We believe this study adds to the existing literature.

Although symptomatic VADAs treated Willis covered stent are not significant difference in the initial technical successful rate, and thrombosis event perioperation, and the final complete occlusion rate, and the final clinical outcomes with SAC, the initial complete occlusion and stable occlusion rate was superior in Willis covered stent group, which may be key to prevent effectively rebleeding for ruptured VADAs. In the study, we report the initial experience that Willis covered stent treated most symptomatic VADAs of the V4 segment located on the proximal to PICA, and only two cases on the distal to PICA, and no case involved PICA. Unfortunately, there is one case suffered with fetal thrombosis event and rebleeding.

In the study, Willis covered stent is preferred in patients with symptomatic VADAs with the following characteristics: ① some ruptured VADAs, which were not involved an important branch vessel, such as PICA, and BA, etc; ② some VADAs, which were failure to be treated with SACE, or recurrent VADAs; ③ the patient was willing to be treated with Willis covered stent, and followed up in accordance with the study protocol.

Flow diverter device issues

In the past 8 years, several FDDs have been emerged as a new paradigm in EVT of intracranial aneurysms. They are rapidly becoming a suitable and preferred alternative to traditional EVT with stents and coils in selected cases.^{11,21,34–36} Compared with conventional intracranial stents, it has higher surface coverage and lower porosity. Several FDDs are in development as follows: The Pipeline embolization device (PED, Medtronic, Irvine, California, USA), The Silk device (SFD, Balt Extrusion, Montmorency, France), The Surpass (Stryker, Kalamazoo, Michigan, USA), FRED (Microvention, Tustin, California, USA) and Tubridge (Microport Scientific Corporation, Shanghai, China) devices. These FDDs comprise a high-attenuation braided mesh stent that it can change the interface of the parent artery and aneurysm sac, facilitating endoluminal reconstruction and aneurysm thrombosis rather than reducing endosaccular filling. Subsequent intrasaccular thrombosis and further neointimal growth over the FDD reconstructs the parent artery, eliminating the aneurysm/parent artery interface with a high rate of occlusion and acceptable morbidity and mortality. The literature on this subject is growing but consisted mainly of small series of less than 10 cases have reported on the safety and efficacy of the PED for reconstructive EVT of VADAs, which showed promising short- and mid-to long-term results with acceptable risks.^{11,35–38} Moreover, Cerejo et al.¹² reported their cases and reviewed only 11 published papers in the English literature to

show good results, a total of 55 intracranial VADAs of 53 patients treated with FDDs. In 20/53 (37.7%) the presenting symptom was acute SAH due to VADAs, while in 4/53 (7.5%) the presenting symptom was an ischemic stroke/transient ischemic attack. At available follow-up (range 5 days–45 months), only 10/53 (18.9%) aneurysms had residual filling. Peri-procedural complications were seen in 5/43 patients (11.6%). Only two patients required re-treatment, one owing to foreshortening of the device, and the other for in-stent stenosis. No postprocedural ruptures were noted. However, a recent meta-analysis from Kiyofuji et al.³⁹ Reviewed EVT outcomes of posterior circulation non-saccular aneurysms by FDDs, immediate complete or near complete occlusion of the aneurysm occurred only in 25% and long-term occlusion in 52%. Peri-procedural stroke occurred in 23% of cases. Good long-term neurologic outcome was achieved in 51%. Good neurologic outcome rate was higher in vertebral artery aneurysms (83%) than other locations (18–33%). In addition, they believe that FDD is a feasible and efficacious treatment for non-saccular aneurysms in the posterior circulation, but treatment outcomes of non-saccular aneurysms of the posterior circulation are highly variable and are highly dependent on patient selection.

Although many studies demonstrated the characteristics of the PED appear to be ideal for EVT of ruptured and unruptured VADAs, the major inherent limitations of FDDs are delayed aneurysm rupture and parenchymal hemorrhage after operation, which are poorly understood. Moreover, there is also the need for prolonged antiplatelet use, device migration, delayed parent vessel occlusion and the worsening of pre-existing mass effect, remain non-negligible. The therapeutic approach to these lesions requires a sophisticated understanding of their unique anatomy and hemodynamic features, an extensive comprehension of the treatment strategies, and a keen decision-making process to individualize the treatment for any specific lesions.

Innovations and limitations

This is the first appraisal of the safety and efficacy of Willis covered stent in selected symptomatic VADAs treatment with concise follow-up data, compared with SAC, based on mid- and long-term follow-up of 13 case series. The results are encouraging, though some limitations need to be noted. First, the number of cases is limited due to the rarity of indicated cases; second, our patients were highly selected which leads to selection bias; Third, the size of VADAs was not compared between the two groups in the study, which was replaced with the number of stent because VADAs were considered a wall defect disease of VA based on nature of ruptured VADAs; Moreover, in-stent stenosis could not be effectively evaluated due to the short follow-up time in most cases; The most important is that it is a non-randomized case series.

Conclusions

Our preliminary data, combined with a review of available evidence from the literature, show that reconstructive endovascular Willis covered stent appears to be a safe and effective treatment alternative for selected symptomatic VADAs, associated with good occlusion rates and favorable clinical outcomes, which can be comparable with that of SAC. However, Willis covered stent could not treated VADAs involved PICA and near the origin of BA, which will be treated by SAC or PED, although it is very suitable for EVT of acute ruptured VADAs. Moreover, an expanded clinical experiences and larger cohort studies are needed to elaborate stent-related complications and long-term follow-up outcomes.

Author contributions

Conception and design: Wu WANG and YongDong LI.
Acquisition of data: Wu WANG, Yi GU, Jin YOU, and Mo CHEN.
Analysis and interpretation of data: Wu WANG and Li CHEN.
Drafting the article: Wu WANG.
Critically revising the article: YongDong LI and MinHua LI.

Reviewed submitted version of manuscript: Wu WANG, Yi GU, Bin-Xian GU, YueQi ZHU, HaiTao LU, and PeiLei ZHANG, Approved the final version of the manuscript on behalf of all authors: Wu WANG.

Statistical analysis: Wu WANG and Jin YOU.

Administrative/technical/material support: Wu WANG, BinXian GU and MinHua LI.

Study supervision: Wu WANG.

Declaration of competing interest

The authors report no conflict of interest concerning the materials or methods used in this study or the findings specified in this paper.

Acknowledgements

This work was financially supported by the National Natural Science Foundation of China [grant numbers 81771951].

References

- Kim BM, Shin YS, Kim SH, et al. Incidence and risk factors of recurrence after endovascular treatment of intracranial vertebrobasilar dissecting aneurysms. *Stroke*. 2011;42(9):2425–2430.
- Kai Y, Nishi T, Watanabe M, et al. Strategy for treating unruptured vertebral artery dissecting aneurysms. *Neurosurgery*. 2011;69(5):1085–1091.
- Park SI, Kim BM, Kim DI, et al. Clinical and angiographic follow-up of stent-only therapy for acute intracranial vertebrobasilar dissecting aneurysms. *AJNR Am J Neuroradiol*. 2009;30(7):1351–1356.
- Kim MJ, Chung J, Kim SL, et al. Stenting from the vertebral artery to the posterior inferior cerebellar artery. *AJNR Am J Neuroradiol*. 2012;33(2):348–352.
- Nam KH, Ko JK, Cha SH, et al. Endovascular treatment of acute intracranial vertebral artery dissection: long-term follow-up results of internal trapping and reconstructive treatment using coils and stents. *J Neurointerventional Surg*. 2015;7(11):829–834.
- Sönmez Ö, Brinjikji W, Murad MH, et al. Deconstructive and reconstructive techniques in treatment of vertebrobasilar dissecting aneurysms: a systematic review and meta-analysis. *AJNR Am J Neuroradiol*. 2015;36(7):1293–1298.
- Guan J, Li G, Kong X, et al. Endovascular treatment for ruptured and unruptured vertebral artery dissecting aneurysms: a meta-analysis. *J Neurointerventional Surg*. 2017;9(6):558–563.
- Zhao KJ, Fang YB, Huang QH, et al. Reconstructive treatment of ruptured intracranial spontaneous vertebral artery dissection aneurysms: long-term results and predictors of unfavorable outcomes. *PLoS One*. 2013;26(6), e67169.
- Chung Y, Lee SH, Choi SK, et al. Triple stent therapy for the treatment of vertebral dissecting aneurysms: efficacy and safety. *World Neurosurg*. 2017;99:79–88.
- He M, Zhang H, Lei D, et al. Application of covered stent grafts for intracranial vertebral artery dissecting aneurysms. *J Neurosurg*. 2009;110(3):418–426.
- Cerejo R, Bain M, Moore N, et al. Flow diverter treatment of intracranial vertebral artery dissecting pseudo-aneurysms. *J Neurointerventional Surg*. 2017;9(11):1064–1068.
- Li MH, Li YD, Tan HQ, et al. Treatment of distal internal carotid artery aneurysm with the willis covered stent: a prospective pilot study. *Radiology*. 2009;253(2):470–477.
- Wang W, Li MH, Li YD, et al. Reconstruction of the internal carotid artery after treatment of complex traumatic direct carotid-cavernous fistulas with the Willis covered stent: a retrospective study with long-term follow-up. *Neurosurgery*. 2016;79(6):794–805.
- Li MH, Gao BL, Fang C, et al. Angiographic follow-up of cerebral aneurysms treated with Guglielmi detachable coils: an analysis of 162 cases with 173 aneurysms. *AJNR Am J Neuroradiol*. 2006;27(5):1107–1112.
- Raymond J, Guilbert F, Weill A, et al. Long-term angiographic recurrences after selective endovascular treatment of aneurysms with detachable coils. *Stroke*. 2003;34(6):1398–1403.
- Van Swieten JC, Koudstaal PJ, Visser MC, et al. Interobserver agreement for the assessment of handicap in stroke patients. *Stroke*. 1988;19(5):604–607.
- Peluso JP, Van Rooij WJ, Sluzewski M, et al. Endovascular treatment of symptomatic intradural vertebral dissecting aneurysms. *AJNR Am J Neuroradiol*. 2008;29(1):102–106.
- Cho DY, Choi JH, Kim BS, et al. Comparison of clinical and radiologic outcomes of diverse endovascular treatments in vertebral artery dissecting aneurysm involving the origin of PICA. *World Neurosurg*. 2019;121:e22–e31.
- Lylyk P, Ceratto R, Hurlvitz D, et al. Treatment of a vertebral dissecting aneurysm with stents and coils: technical case report. *Neurosurgery*. 1998;43(2):385–388.
- Sekhon LH, Morgan MK, Sorby W, et al. Combined endovascular stent implantation and endosaccular coil placement for the treatment of a wide-necked vertebral artery aneurysm: technical case report. *Neurosurgery*. 1998;43(2):380–384.
- Wakhloo AK, Gounis MJ. Revolution in aneurysm treatment: flow diversion to cure aneurysms: a paradigm shift. *Neurosurgery*. 2014;61(Suppl 1):111–120.
- Zhao KJ, Zhao R, Huang QH, et al. The interaction between stent(s) implantation, PICA involvement, and immediate occlusion degree affect symptomatic intracranial spontaneous vertebral artery dissection aneurysm (sis-VADA) recurrence after reconstructive treatment with stent(s)-assisted coiling. *Eur Radiol*. 2014;24(9):2088–2096.
- Chiaradio JC, Guzman L, Padilla L, et al. Intravascular graft stent treatment of a ruptured fusiform dissecting aneurysm of the intracranial vertebral artery: technical case report. *Neurosurgery*. 2002;50(1):213–217.
- Islak C, Kocer N, Albayram S, et al. Bare stent-graft technique: a new method of endoluminal vascular reconstruction for the treatment of giant and fusiform aneurysms. *AJNR Am J Neuroradiol*. 2002;23(9):1589–1595.
- Burkelo MA, Dzyak LA, Zorin NA, et al. Stent-graft placement for wide-neck aneurysm of the vertebrobasilar junction. *AJNR Am J Neuroradiol*. 2004;25(4):608–610.
- Felber S, Henkes H, Weber W, et al. Treatment of extracranial and intracranial aneurysms and arteriovenous fistulae using stent grafts. *Neurosurgery*. 2004;55(3):631–638.
- Lv X, Jiang C, Li Y, et al. Intracranial pseudoaneurysms, fusiform aneurysms and carotid-cavernous fistulas. Repair with percutaneous implantation of endovascular covered stents. *Intervent Neuroradiol*. 2008;29(4):435–440.
- Vulev I, Klepanec A, Bazik R, et al. Endovascular treatment of internal carotid and vertebral artery aneurysms using a novel pericardium covered stent. *Intervent Neuroradiol*. 2012;18(2):164–171.
- Yoon SM, Shim JJ, Kim SH, et al. Bilateral vertebral artery dissecting aneurysms presenting with subarachnoid hemorrhage treated by staged coil trapping and covered stents graft. *J Korean Neurosurg Soc*. 2012;51(3):155–159.
- Ronchey S, Serrao E, Kasemi H, et al. Endovascular treatment of extracranial vertebral artery aneurysm and aberrant right subclavian artery aneurysm. *J Cardiovasc Surg*. 2014;55(2):265–269.
- Inaraja Pérez GC, Rodríguez Morata A, Reyes Ortega JP, et al. Endovascular treatment of a symptomatic vertebral artery pseudoaneurysm. *Ann Vasc Surg*. 2015;29(5):1018.e5–1018.e8.
- Xiang S, Li G, He C, Ren J, et al. Reconstructive endovascular treatment of the V4 segment of a vertebral artery dissecting aneurysm with the Willis covered stent: a retrospective study. *Intervent Neuroradiol*. 2019 Oct;25(5):548–555.
- Li MH, Zhu YQ, Fang C, et al. The feasibility and efficacy of treatment with a Willis covered stent in recurrent intracranial aneurysms after coiling. *AJNR Am J Neuroradiol*. 2008;29(7):1395–1400.
- Kocer N, Islak C, Kizilkilic O, et al. Flow re-direction endoluminal device in treatment of cerebral aneurysms: initial experience with short-term follow-up results. *J Neurosurg*. 2014;120(5):1158–1171.
- Kühn AL, Kan P, Massari F, et al. Endovascular reconstruction of unruptured intradural vertebral artery dissecting aneurysms with the pipeline embolization device. *J Neurointerventional Surg*. 2016;8(10):1048–1051.
- Yeung TW, Lai V, Lau HY, et al. Long-term outcome of endovascular reconstruction with the Pipeline embolization device in the management of unruptured dissecting aneurysms of the intracranial vertebral artery. *J Neurosurg*. 2012;116(4):882–887.
- Narata AP, Yilmaz H, Schaller K, et al. Flow-diverting stent for ruptured intracranial dissecting aneurysm of vertebral artery. *Neurosurgery*. 2012;70(4):982–989.
- Mazur MD, Kilburg C, Wang V, et al. Pipeline embolization device for the treatment of vertebral artery aneurysms: the fate of covered branch vessels. *J Neurointerventional Surg*. 2016;8:1041–1047.
- Kiyofuji S, Graffeo CS, Perry A, et al. Meta-analysis of treatment outcomes of posterior circulation non-saccular aneurysms by flow diverters. *J Neurointerventional Surg*. 2018;10(5):493–499.